

### **Could steroids cause dysrhythmia in covid-19 patients? A case report**

#### **Abstract**

**Aim:** Steroid-induced dysrhythmia is a rare but severe side effect.

**Presentation of case:** After 24-48 hours of corticosteroid administration, bradyarrhythmia was detected in our three COVID-19 patients (a 38 and 67-year-old female and a 57-year-old male) who had no prior medical history of cardiac disease. Bradyarrhythmia improved following discontinuation of corticosteroids.

**Discussion:** Cardiac dysrhythmia is a rare side effect for steroids especially in Iranian patients. Our patients had no prior history of cardiac disease, and sinus bradycardia was observed while receiving intravenous methylprednisolone or dexamethasone

**Conclusion:** This side effect can occur with any corticosteroid, and all patients receiving high doses of corticosteroids, even for a brief period, should be closely monitored.

**Keywords:** COVID-19, Bradycardia, Corticosteroids

#### **Introduction**

Systemic glucocorticoids have been shown to be effective as an immunosuppressive agent in treating various conditions, including certain renal, neurological, pulmonary, gastrointestinal, and neoplastic diseases. While the most common adverse effects of corticosteroids, such as hyperglycemia, hypertension, hyperlipidemia, mood disorders, and osteoporosis, are well known, cardiac toxicities, such as atrial fibrillation/flutter, ventricular tachycardia, and sinus bradycardia, are less well understood [1]. Corticosteroid-induced bradycardia is a relatively uncommon occurrence that was first reported in 1986. While most bradycardia (defined as a heart rate less than 60 BPM) is associated with high intravenous steroid doses, several reports indicate that oral

steroids carry a similar risk of cardiac arrhythmia, including cardiac bradycardia arrhythmia [2]. Additionally, more severe arrhythmias and cardiac arrest were described. The majority of data available are case reports of bradycardia occurring during steroid treatment [3-5].

Coronavirus disease (COVID-19) is an infectious disease caused by a novel single-stranded RNA enveloped virus called Severe Acute Respiratory Syndrome-Coronavirus-2 (SARS-CoV-2). COVID-19's first case was reported in China on 8 December 2019. Recent evidence suggests a direct relationship between COVID-19 and cardiovascular complications such as heart attack, myocarditis, and arrhythmia. COVID-19's arrhythmogenic effect could be a result of cytokine storm and hyperinflammation [6]. Cardiac arrhythmia was considered a significant issue in 23 ICU patients (16.7%) in a clinical study with 138 patients with COVID-19 in Wuhan, China, but the specific types of arrhythmia were not recorded [7].

## **Presentation of case**

### ***Case 1***

*Patient information and clinical findings:* A 67-year-old woman from Iran (height 160 cm; weight 75 kg) with no prior medical history was transferred to the emergency department after presenting with a 6-day history of dry cough, fever, and myalgia. Her blood pressure was 120/70 mmHg, and her heart rate was 92 beats per minute during the examination. Electrolytes were within the normal range at the time of admission: sodium (142 mEq/L) and potassium (3.7 mEq/L). Additionally, creatinine (1.07 mg/dL), creatinine kinase (77 U/L), and troponin I (0.001 µg/L) were measured; the ESR was 85mm/h, the C-reactive protein (CRP) level was 60.2 mg/L, and the liver enzymes were normal. An electrocardiogram was ordered, and sinus rhythm was confirmed. The CT scan revealed severe bilateral involvement with a ground-glass opacity pattern consistent with COVID-19 with oxygen saturation 85% and the patient was admitted to the infectious disease department with a COVID-19 diagnosis. The patient was prescribed methylprednisolone (60 mg IV BID), and Vitamin C (1000 mg IV TDS).

*Timeline:* On the third day of hospitalization, the patient developed bradycardia (Figure 1) (heart rate 47 beats per minute) and tachypnea without respiratory distress; her blood pressure was normal at 100/70, and her laboratory findings were normal.

*Diagnostic assessment:* The patient's echocardiography revealed normal LV systolic function (EF: 55%) and other parameters. Without other medical conditions or medications that could be used to describe her bradycardia, it was concluded that the patient had experienced an episode of corticosteroid-induced bradycardia. Bradycardia as a favipiravir side effect is uncommon and was only reported in a preliminary report of a favipiravir observational study in Japan with a 0.1% event rate [8]. Using the Adverse Drug Reaction Probability (Naranjo) Scale, which is used to estimate the probability of adverse drug reactions [9], a score of 5 was calculated for the patient (there are previous conclusion reports on this reaction; bradycardia developed following the administration of methylprednisolone and improved upon discontinuation; this adverse effect was confirmed by evidence) indicating a possible causal association.

*Therapeutic intervention, follow-up, and outcome:* Following consultation with the clinical pharmacist, methylprednisolone was withheld for 24 hours. Her heart rate was 73 after 24 hours of abstinence (Figure 2). Subsequently, a lower dose of methylprednisolone was initiated.

## **Case 2**

*Patient information and clinical findings:* A 57-year-old male from Iran (height 170 cm; weight 83 kg) was referred to our hospital with dyspnea and myalgia consistent with COVID-19. The physical examination revealed no abnormalities. The ESR was 60 mm/h, the C-reactive protein (CRP) level was 43 mg/L, and the hemoglobin level was 14.1 g/dL in laboratory tests. Electrolyte levels, magnesium and calcium levels, thyroid function tests, troponin levels, and echocardiogram parameters were normal in this patient. On room air, the patient's pulse rate was 68 beats/min, blood pressure was 100/60 mmHg, and oxygen saturation was 83%. The medical history of the patients was negative for all diseases except hyperlipidemia. At the time of admission, the patient was taking atorvastatin 20 mg and omega-3 once daily.

*Timeline:* The patient was started on Dexamethasone 8 mg IV BID (all other medications were similar to the previous case). His pulse rate was 48 beats per minute 48 hours after dexamethasone administration.

*Diagnostic assessment:* Electrocardiographic examination revealed sinus bradycardia in the absence of atrioventricular block or other arrhythmias (Figure 3). Cardiac biomarkers were

normal, and echocardiography revealed normal LV systolic function (EF: 50–55%). As with the previous case, patients' Naranjo scores were calculated which was similar to the score of the first patient.

*Therapeutic intervention, follow-up, and outcome:* Dexamethasone was withheld for 24 hours due to persistent bradycardia, and his cardiac status was monitored via telemetry until the bradycardia episode resolved (Figure 4).

### **Case 3**

*Patient information and clinical findings:* A 38-year-old Iranian woman (height, 166cm; weight, 75 kg) was transferred to the emergency department with a past medical history of rheumatoid arthritis and a 4-day history of nausea, vomiting, dyspnea, and myalgia. Additionally, the CT scan revealed moderate to severe involvement. On presentation to the emergency department, the patients' blood pressure was 125/78 mmHg, pulse rate was 62 BPM, and oxygen saturation level was 88% on room air. Physical examination and ECG were both normal. The blood test revealed mild anemia, a sodium level of 141 mEq/L, a potassium level of 3.9 mEq/L, and a calcium level of 8.8 mEq/L. Echocardiography demonstrated normal left ventricular function with a 55% ejection fraction. Her previous medications were hydroxychloroquine 200 mg once daily, sulfasalazine 500 mg twice daily and calcium-D once daily. After one day of hospitalization, the patient's blood oxygen saturation decreased (80%) and corticosteroid (methylprednisolone 60 mg IV BD) was started for her.

*Timeline:* Daily heart rate and blood pressure readings were taken, and the patient developed bradycardia 48 hours after initiating methylprednisolone. Because the patient was already receiving hydroxychloroquine, the bradycardia could not have been caused by this medication.

*Diagnostic assessment:* A 12-lead electrocardiogram (ECG) revealed significant sinus bradycardia with a heart rate of 51 BPM (Figure 5). As with the previous case, the patient's Naranjo score was determined to be 5

*Therapeutic intervention, follow-up, and outcome:* Methylprednisolone was discontinued, and bradycardia resolved after 24 hours (Figure 6).

## Discussion

Corticosteroids are used to treat various inflammatory conditions, and their side effects vary according to the dose, duration, and route of administration. In COVID-19, it was reported that a short-course (e.g., up to ten days) therapeutic agent conferred survival benefits on a subset of patients (e.g., sustained persistence of ground-glass opacities) [10].

Cardiac dysrhythmia is a rare side effect for steroids especially in Iranian patients. In Iran, steroid use is very common and before covid-19 pandemic, we have not seen this side effect related to steroids. Corticosteroid-induced bradycardia can be asymptomatic or symptomatic, with asymptomatic bradycardia occurring more frequently [1, 11].

Stroeder et al. (2015) identified intravenous methylprednisolone and intravenous dexamethasone as the most likely causes of bradycardia in publications following a review of the literature [5].

While steroid-induced bradycardia is reversible after cessation of use, it is reasonable to treat patients conservatively when cessation of these drugs worsens the underlying disease [12]. Corticosteroid therapy and underlying cardiac and renal disease are predisposing risk factors for the development of bradycardia [13].

In our cases, patients developed bradycardia between 24 and 48 hours after initiating corticosteroid therapy. Covid-19 can also cause self-limiting bradycardia, However, as patients' heart rates dropped after starting the steroid and returned to baseline upon cessation of the agent; it increased the possibility of steroid-induced bradycardia. When dealing with a drug side effect, the first step is to discontinue the suspected drug and, if the complication does not resolve, use another agent (e.g. atropine). In a literature review recovery was attained by cessation of the steroid treatment and a small number of patients required intervention [14]. The delay in onset, which ranged between 1 and 7 days after the start of drug administration, was a frequently reported finding in studies [2, 15, 16].

Although the precise mechanism by which corticosteroids cause this adverse effect is unknown, several hypotheses have been advanced that corticosteroids may cause a sudden electrolyte imbalance, resulting in cardiac arrhythmias, including bradycardia. Another hypothesis is that corticosteroids alter sodium and water physiology, increasing plasma volume and activating low-

pressure baroreceptors [15]. Furthermore, bradycardia may occur as an idiosyncratic reaction to dexamethasone [17].

Our patients had no prior history of cardiac disease, and sinus bradycardia was observed while receiving intravenous methylprednisolone or dexamethasone, implying that this adverse effect was induced by intravenous methylprednisolone or dexamethasone. As a result, special attention should be paid to high-risk patients, who should have their heart rates closely monitored.

Electrolytes, particularly potassium, should be monitored before treatment, and any potassium deficiency should be corrected [18].

## Conclusion

Increased reporting of adverse effects of steroids, such as bradycardia, will occur during the COVID-19 pandemic due to the widespread use of corticosteroids in treatment protocols during the disease's inflammatory phase. This adverse effect can occur with any type of corticosteroid, and all patients receiving high doses of corticosteroids, even for a brief period, should be closely monitored for bradycardia.

### COMPETING INTERESTS DISCLAIMER:

Authors have declared that no competing interests exist. The products used for this research are commonly and predominantly use products in our area of research and country. There is absolutely no conflict of interest between the authors and producers of the products because we do not intend to use these products as an avenue for any litigation but for the advancement of knowledge. Also, the research was not funded by the producing company rather it was funded by personal efforts of the authors.

## References

1. Vasheghani-Farahani, A., et al., *Incidence of various cardiac arrhythmias and conduction disturbances due to high dose intravenous methylprednisolone in patients with multiple sclerosis*. Journal of the neurological sciences, 2011. **309**(1-2): p. 75-78.
2. Al Shibli, A., I. Al Attrach, and M.A. Hamdan, *Bradycardia following oral corticosteroid use: case report and literature review*. Arab journal of nephrology and transplantation, 2012. **5**(1): p. 47-49.

3. Cansu, D.Ü., E. Bodakçi, and C. Korkmaz, *Dose-dependent bradycardia as a rare side effect of corticosteroids: a case report and review of the literature*. Rheumatology international, 2018. **38**(12): p. 2337-2343.
4. Pudil, R. and Z. Hrnčir, *Severe bradycardia after a methylprednisolone minipulse treatment*. Archives of internal medicine, 2001. **161**(14): p. 1778-1779.
5. Stroeder, J., C. Evans, and H. Mansell, *Corticosteroid-induced bradycardia: case report and review of the literature*. Canadian Pharmacists Journal/Revue des Pharmaciens du Canada, 2015. **148**(5): p. 235-240.
6. Samidurai, A. and A. Das, *Cardiovascular complications associated with COVID-19 and potential therapeutic strategies*. International journal of molecular sciences, 2020. **21**(18): p. 6790.
7. Wang, C.J., C.Y. Ng, and R.H. Brook, *Response to COVID-19 in Taiwan: big data analytics, new technology, and proactive testing*. Jama, 2020. **323**(14): p. 1341-1342.
8. James Ives, M., *Preliminary report of favipiravir observational study in Japan released [Internet]. News-Medical.net, [cited 23 July 2020]*, 2020.
9. Naranjo, C.A., et al., *A method for estimating the probability of adverse drug reactions*. Clin Pharmacol Ther, 1981. **30**(2): p. 239-45.
10. Zha, L., et al., *Corticosteroid treatment of patients with coronavirus disease 2019 (COVID-19)*. Medical Journal of Australia, 2020. **212**(9): p. 416-420.
11. van der Gugten, A., M. Bierings, and J. Frenkel, *Glucocorticoid-associated Bradycardia*. Journal of Pediatric Hematology/Oncology, 2008. **30**(2): p. 172-175.
12. Taylor, M.R. and D. Gaco, *Symptomatic Sinus Bradycardia After a Treatment Course Of High-dose Oral Prednisone*. The Journal of Emergency Medicine, 2013. **45**(3): p. e55-e58.
13. Hsu, D.T., *Steroids and Bradycardia: How Slow Can You Go?* Journal of Pediatric Hematology/Oncology, 2008. **30**(2): p. 119-120.
14. Üsküdar Cansu, D., E. Bodakçi, and C. Korkmaz, *Dose-dependent bradycardia as a rare side effect of corticosteroids: a case report and review of the literature*. Rheumatology International, 2018. **38**(12): p. 2337-2343.
15. Akikusa, J.D., et al., *Sinus bradycardia after intravenous pulse methylprednisolone*. Pediatrics, 2007. **119**(3): p. e778-e782.
16. Tvede, N., L.P. Nielsen, and V. Andersen, *Bradycardia after high-dose intravenous methylprednisolone therapy*. Scandinavian journal of rheumatology, 1986. **15**(3): p. 302-304.
17. Li, J., et al., *Sinus bradycardia rare but expected complications of chemo regimen involving dexamethasone: case report*. Open Journal of Blood Diseases, 2016. **7**(1): p. 47-50.
18. Sinha, A. and A. Bagga, *Pulse steroid therapy*. The Indian Journal of Pediatrics, 2008. **75**(10): p. 1057.

**Figure**

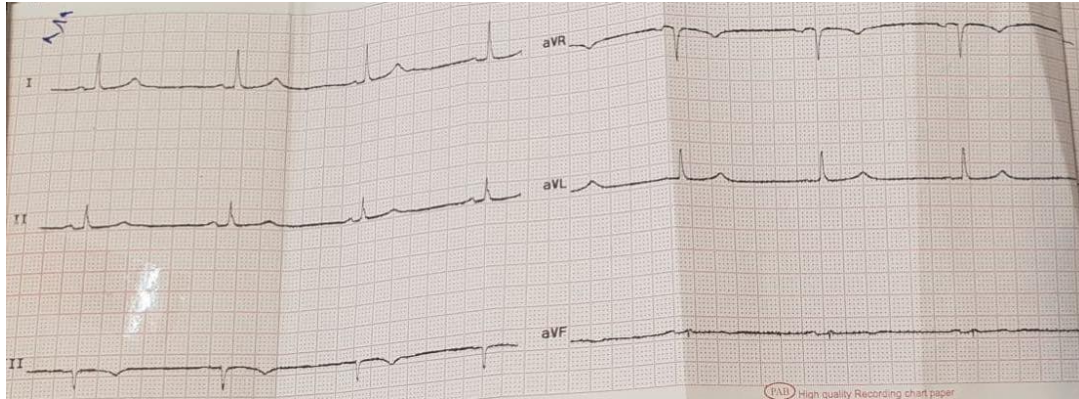


Figure 1.

The patient ECG showing isolated bradycardia

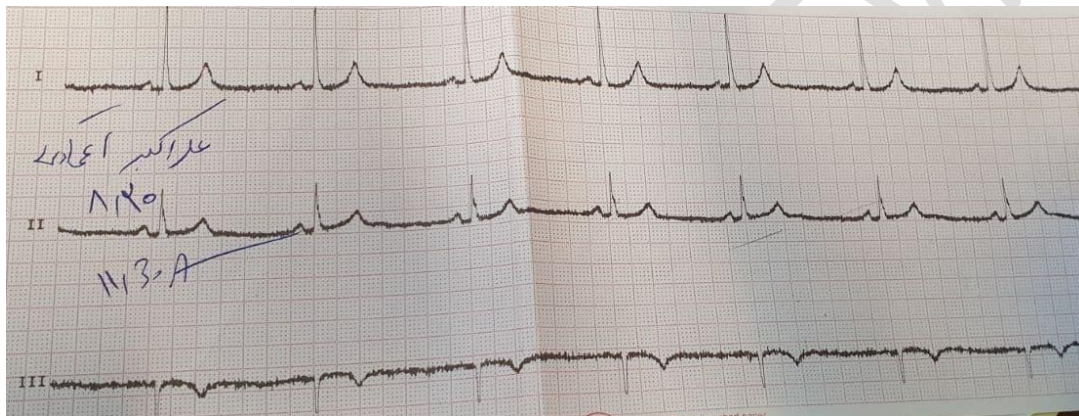


Figure 2.

ECG after hold of methylprednisolone

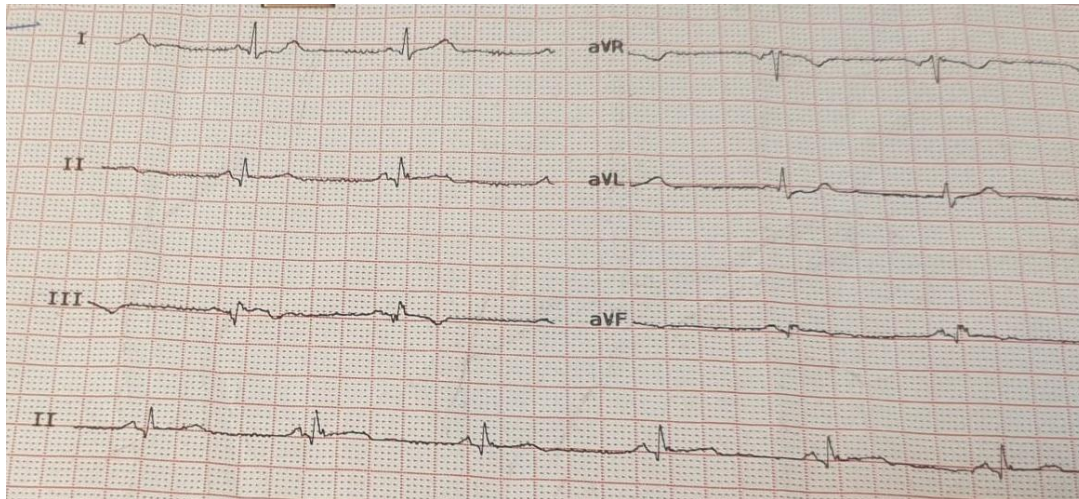


Figure 3.

The patient ECG showing isolated bradycard

UNDER PEER REVIEW

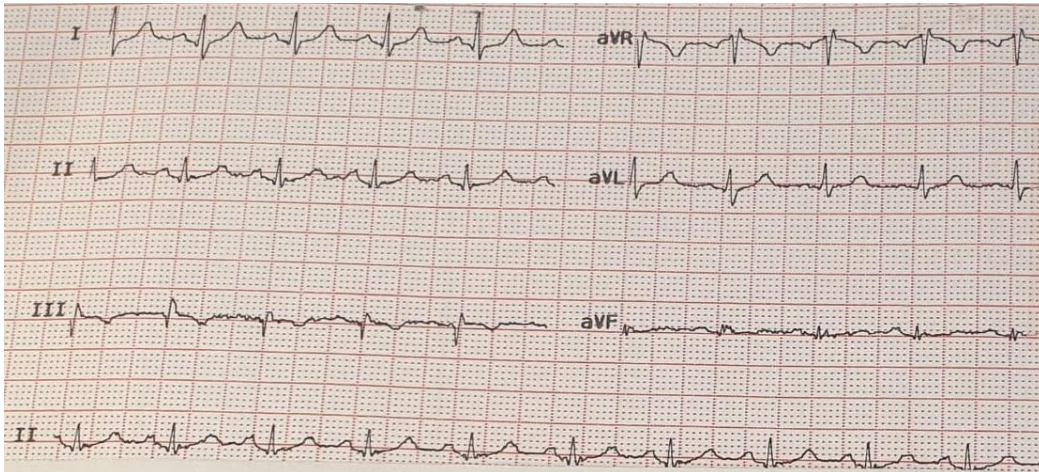


Figure 4.

ECG after hold of dexamethason

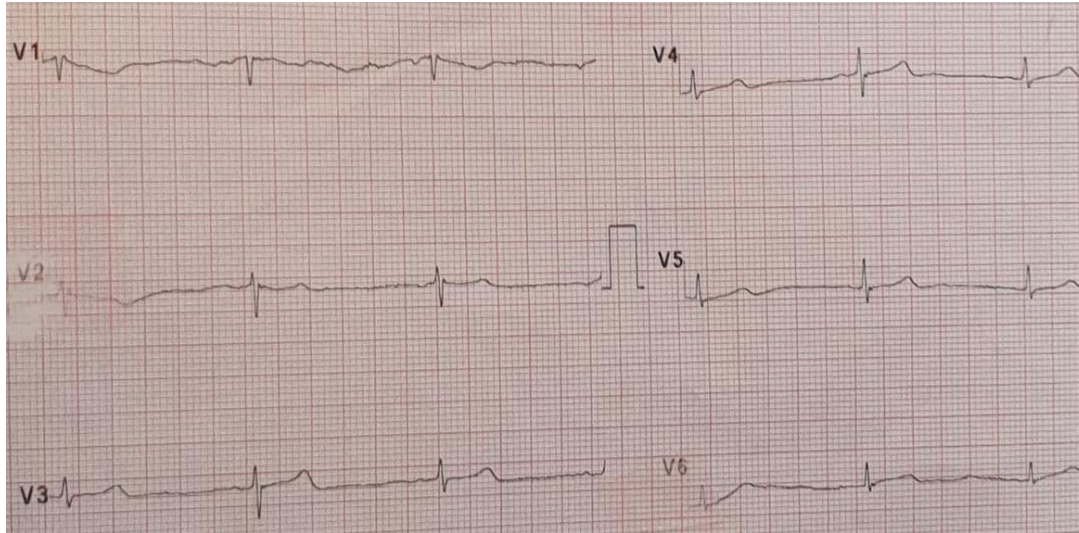


Figure 5.

The patient ECG showing isolated bradycard

UNDER PEER REVIEW

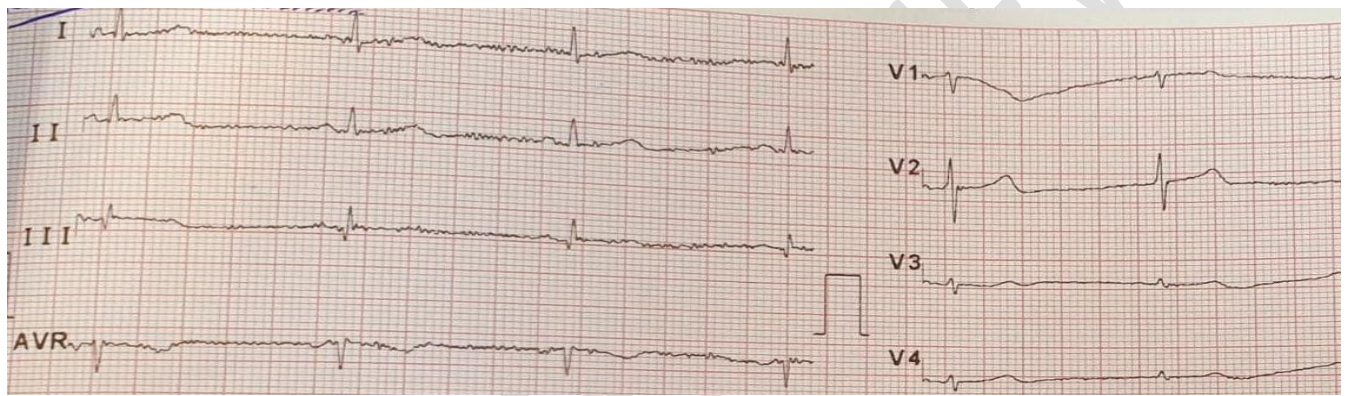


Figure 6.  
ECG after hold of methylprednisolone