

## Review Article

### Transcatheter Closure of Atrial Septal Defect

#### Abstract

**Background:** Over the past decade, percutaneous atrial septal defect (ASD) closure has been the preferred treatment option in many clinical programs for ASD. Percutaneous ASD closures with advanced device architecture and distribution have established user experience and process security. The ability to diagnose has also improved. The devices have evolved from the larger fixtures to the reset zone, being easily eliminated with little residual mesh material and comfortable fitting with the surrounding structures. Biodegradable technology has been introduced and will be considered as a future option. The emergence of the use of the ASD closure device over the last forty years includes improvements that reduce the incidence of adverse effects reported over the years. Issues reported in the literature include thrombus formation, air tightness, device insertion, abrasion, residual shunts and nickel hypersensitivity. Modern tools hold medium and long-term data with excellent results. Multi-sized devices securely close simple and complex ASDs that can re-scan, reset, and detect percutaneous advanced delivery procedures. In this review, the most widely used tools and distribution processes are discussed and the tools that show promise for the future.

**Summary:** As the field of TC-ASD and congenital interventional cardiology develops, real-world design studies provide valuable developmental information on aspects of care where there is disagreement about best practices and more research is needed.

*Keywords:* Transcatheter Intervention, ASD, congenital, Amplatze.

#### Introduction

Atrial septal defect (ASD) is defined as continuous communication between the right and left atria. ASD is one of the most common congenital defects in adults, accounting for 7-10% of all congenital heart problems in adults. ASD Closure (The percutaneous transcatheter) has become the preferred management strategy over heart surgery open. In 1976, i-King and Mills did. the first successful closure of the percutaneous ASD. The process is enhanced with easy-to-use delivery systems and devices. The use of new percutaneous obturators is associated with lower levels of complications and better long-term results. The risk of device fixation, thrombus formation, bleeding, erosion, and leakage is reduced through user experience and improvement of product quality. Each device has its own technical difficulties and measurement requirements to overcome the learning curve. The devices most used by the United States Food and Drug Administration (FDA) are approved to block ASDs by Amplatzer (St Jude Medical, Inc., Saint Paul, MN, USA) and Gore Helex (WL Gore & Associates, Inc., Newark, DE, USA) Lock devices. Operators trained in the percutaneous treatment of structural heart disease can navigate the inferior vena cava and right atrium using a variety of devices and delivery sheets. The goal is to use the correct size device in the

wrong location to avoid a large bypass between the two chambers by using a combination of angiographic and echocardiographic guidance techniques (1).

### **Indications**

ASD closure is indicated when there is a significant left-to-right shunt, which is defined as a significant increase in right heart rate due to an increase in volume, regardless of symptoms. The explanations for locking Secundum devices on Secundum ASD are described in detail in other articles and are therefore not described in detail in this paper. Transpharyngeal echocardiography under general anesthesia has been a specialized form of photography for over 10 years, now working with the latest innovations imaging orientation techniques. Intracardiac echocardiographies, as well as the latest transthoracic echocardiography, were introduced as one of the most widely used imaging techniques. The advantage of both is that general anesthesia is not required. Small defects in right ventricular fluid volume are not considered closed unless right-to-left circulation causes significant hypoxemia and / or complex embolism (2).

### **Contraindications**

ASD closure should not be performed under conditions where pulmonary artery resistance exceeds 8 wood units. Patients with pulmonary arterial pressure less than two-thirds of systemic artery pressure, pulmonary vascular resistance less than two-thirds of systemic resistance, or a positive response to a pulmonary vasodilation test may be able to prevent ASD. Ventilators can be considered for this group of patients (2).

### **Complications**

Arrhythmia is the next most common disease. In patients who experience atrial fibrillation or supraventricular tachycardia after insertion of the ASD device, the possible explanation is enlargement of the intrauterine septum through the middle aspect of the device. Prompt evidence of thrombus formation in the left atrial disc and spontaneous differentiation in the echocardiogram immediately after the procedure was diagnosed in a 67-year-old patient with systemic hypertension. To prevent this problem, our goal now is to introduce an oral treatment that prevents infertility in all patients the day before the procedure. We are not starting anticoagulant treatment because we do not have the means to identify high-risk patients who need it. The bursting of a balloon is an unexpected event because it seems to be related to the balloon itself. The problem was controlled by detecting a balloon that was presented differently on a long wire and removed through a basket catheter (3).

Other complications (iliac vein dissection, inguinal hematoma, bleeding from the retropharynx) have been associated with misuse of the person during the procedure. The main problem reported in Patient 34, namely, sudden death, is very troublesome and requires further study in another serious series. We cannot understand how a device installed 1.5 years ago can cause sudden death. We are committed to reporting the incident to the 34-year-old health board for no other reason. Peripheral embolization in 19 patients was clearly

associated with the presence of blood clots in the device seen in TTE. Hyper frozen condition was found. The patient suffers from a serious gastrointestinal infection. This problem is important because it tells us that the end of the machine is not complete after six months, and that other factor, such as infection, can cause the formation of blood clots in the device during combination therapy (3).

## **Patients and Methods**

### **Patient preparation**

#### **Anesthesia**

Trans catheter aortic valve implantation may be done below aware sedation or wellknown anesthesia. popular anesthesia is desired if TEE echocardiography is carried out (3).

#### **Positioning**

The patient stays inside the supine function during the procedure (3).

#### **Trying out and medicinal drugs**

Patients are pretreated with aspirin (81-325 mg) daily and clopidogrel 300-mg loading dose at least one hour previous to the process and persevered at 81-mg oral daily dose. After the system, aspirin (at the least 81 mg every day) is continued indefinitely, and clopidogrel eighty one mg each day is sustained for 1-6 months (4).

#### **Adjunctive antacids are to be considered**

Routing laboratory tests previous to the manner include entire blood cellular (CBC) count number, global normalized ratio (INR), partial thromboplastic time (PTT), albumin and transaminase levels, renal characteristic checking out, and 12-lead electrocardiography (ECG). Cardiac biomarker stages (ie, CK and CK-MB) also are examined within forty eight hours of the manner. To decrease the hazard of prosthetic valve infection, prophylactic intravenous antibiotic therapy at least 1 hour before the method is likewise endorsed. The authors use cefuroxime 750 mg IV 1 hour preprocedure, and the dose is repeated 6 and 12 hours after the system. In sufferers who're allergic to penicillin (or cephalosporins), vancomycin may be considered (4).

#### **Monitoring & observe-up**

The patient should be found with a transient pacemaker in a cardiovascular ICU for up to forty eight hours to monitor for any conduction gadget abnormalities. If no conduction gadget disturbances are detected, the patient is monitored for an additional seventy two hours after which discharged. The affected person must continue taking aspirin 81-325 mg every day and clopidogrel 75 mg day by day for as a minimum three months following the procedure. Both transthoracic echocardiography (TTE) and transesophageal echocardiography (TEE) can be used to guide the manner and examine for complications, as wished. Continuous invasive hemodynamic monitoring must be used for the duration of the system (5).

## **Working Room**

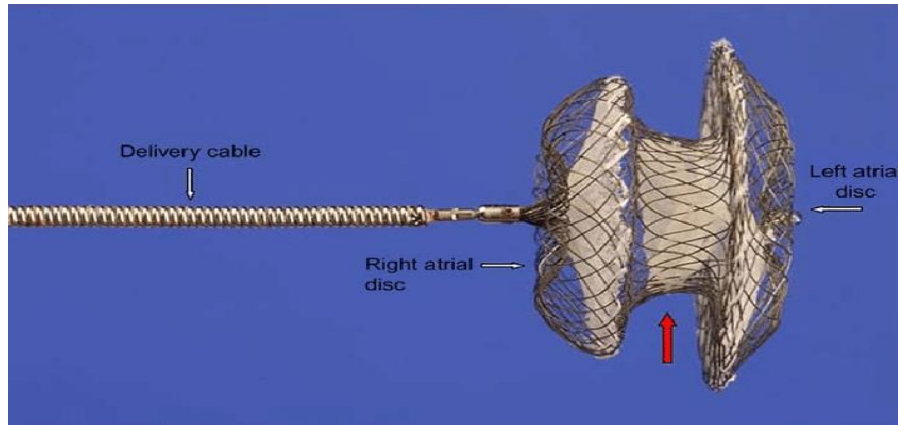
The process can be executed inside the cardiac catheterization laboratory or in a hybrid operating room. A set fluoroscopy unit is required. In addition to storing the reference images. Cardiopulmonary bypass equipment should be available easily in case of complications. The room must additionally be prepared with substances required to treat vascular and coronary complications (5).

## **Current Devices**

### **Amplatzer septal occluder (ASO)**

The ASO device has been approved by the FDA to switch off ASD since 2001 and has a very wide range of uses (Figure 1). ASO is clearly visible on TEE and fluoroscopy. Based on ease of deployment, support and protocol implementation, ASO has multiple outlet data for all ASD disconnection devices over the past 20 years. Its direct administration and proven success with both simple and complex lesions have made it very popular in the closure of ASD. The ASO can also be used to seal a closed patent foramen closure. The device is very successful due to its ease of use and can be reset before end use. The device used corresponds to the layout of the surrounding structures. The structure of the device is a double stretchable intervertebral disc with a large left atrial disc and an output size of 4mm connector. The structure is a metallic nitinol structure and is recyclable. There are 26 disc sizes from 4 mm to 38 mm. The left ASO / left target combination includes an 18/18 mm, 25/18 mm, 30/30 mm, 35/25 mm combination combination. The delivery envelope sizes range from 6F to 12F (6).

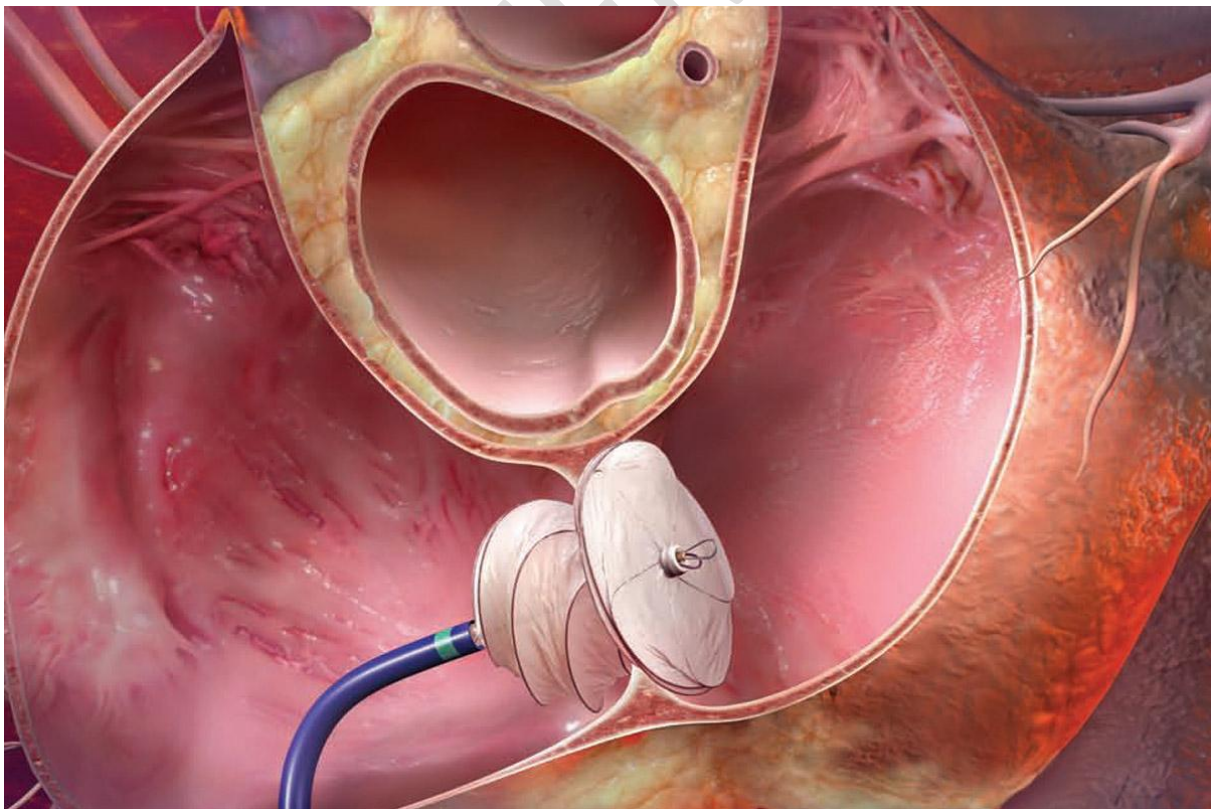
In cases with severe ASD, where the ASO device can be difficult to install, the Hausdorf envelope can be used more easily. The biggest risk may be device erosion or a lack of purple color associated with the size of the device. It is not clear what the actual rate of erosion of the device is; 240 incidents have been reported with an international installation rate of 240,000 machines (0.1%), but also an estimated 0.2% -0.5%. It is believed that this mechanism is caused by a collision between the wire mesh of the atrial disc and the aorta or atrial wall. TTE can detect aortic atrial fistula or pericardial effusion, but the incidence is so rare that it is not clear whether conventional TTE monitoring is appropriate. Surgical removal of the device and closure of the damaged pelvis are reported. The FDA requires that manufacturers conduct research to better understand the effectiveness of ASO and its ability to improve erosion (6).



**Figure 1 Amplatzer septal occluder (ASO) (6).**

### **Gore Helix septal occluder**


In 2006, the FDA approved banning the ASD device. The device features a Nitinol coated corkscrew coating of Gore-Tex (extended polytetrafluoroethylene) protective coating. Delivery success rates are higher with worse cases of 3.6%. No case of corrosion has been reported on the Gore Helix device, which is compatible with the PTFE material which is compatible with wire mesh. The Gore Helix device has an interesting and reproducible engineering design, but requires a central learning curve to extract the disks and understand its architecture (Figure 2) (7).



**Figure 2 Gore Helix septal occlude (7).**

### **Gore septal occluder (GSO)**

The Gore Helex device was developed at GSO (WL Gore & Associates, Inc.) with a flexible petal design, platinum core instead of solid nitinol, dispensing handle and unprotected coating (Figure 3). These factors play an important role in the introduction and alignment of the surrounding structure. Excellent delivery efficiency (89%) with an acceptable small residual shunt reported by GSO. Proponents of the GSO claim that the ASD has a GSO advantage over the ASO in the event of a complex deficit. Due to the increasing rate of erosion in this environment, missing margins in some facilities are considered ASO barriers. GSO has a soft disk with minimal impact resistance, which is a protective feature against corrosion. Preliminary research shows that GSO has potential benefits from a safe, efficient, redesigned, and re-imaging viewing environment. The remaining shunts can be compared with existing devices with a verified record (8).



**Figure 3 Gore septal occluder (GSO) (8).**

### **Cera septal occluder**

Cera is a new low-cost ASD double-disc occluder (Liftech Scientific Corporation, Shenzhen, People's Republic of China) (Figure 4). Cera is not FDA approved. The structure consists of an expanded nitinol framework coated with bioceramic titanium nitride (TiN). The left disc is shorter than the right disc with a diameter of 4 mm. The shorter processing time and ASO technical learning curve makes it easier to migrate to Serra. However, long-term safety data for 18 months are not available. Thus, despite the initial promising results of lucrative cost savings, caution should be exercised when using long-term data constraints and lucrative cost-saving devices. Randomized controlled trials may provide additional information about these comparative tests (9).



**Figure 4 Cera septal occlude (9).**

### **Clamshell, CardioSEAL, and Starflex**

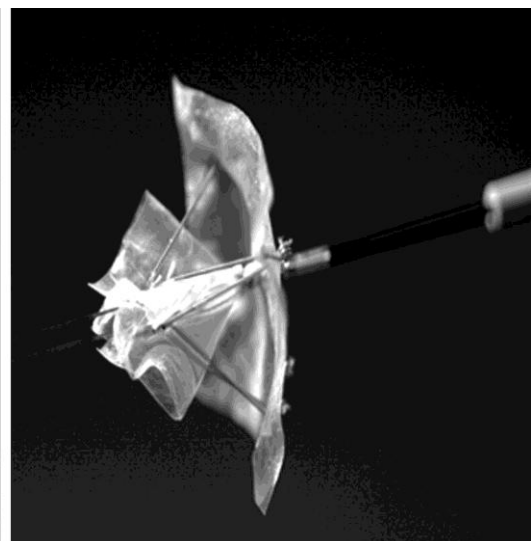
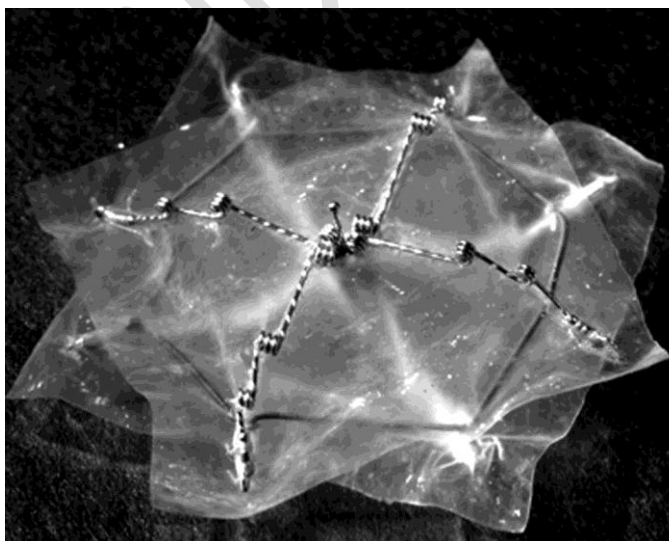
Twenty-five years ago the first Clamshell device was upgraded to CardioSEAL, which was later upgraded to Starflex (NMT Medical, Boston, MA, USA) (Figure 5). The breakdown of the device was much higher with Clamshell, made of stainless steel, and Dacron. CardioSEAL is made of a different alloy steel and is not prone to breakage. Starflex provided a framework where a small amount of cracking was detected based on the flexibility of the steel anchor points. Starflex also provided enhanced delivery and delivery. These devices are no longer manufactured due to industry input delivery, device size, and problem risk. CardioSEAL and Starflex devices have played a key role in establishing early safety, efficacy, and effectiveness in percutaneous ASD closure against surgical closure. Use of these devices has been associated with a higher risk of left atrial fibrillation, which can lead to stroke, and is detected in TEE at 1 month in 7% -23% of implants (10).



**Figure 5 Starflex Device (10)**

### **Biostar**


Biodegradable technology has the potential to transform percutaneous interference processes. BioStar (BIO-STAR, NMT Medical, Boston, MA, USA), a non-perishable ASD closure device, was tested in 33 children. BioStar has a Starflex structure without a polyester disc (Figure 6). BioStar contains a porcine collagen matrix in a cobalt-based alloy framework. Bioengineered collagen forms and degrades 90% of the structure, leaving approximately 10% of the rest of the healthy native tissue. The results of the 7-month follow-up showed safety and efficacy with a reported delivery success rate of 97% and a comparable level of remission (11).



**Figure 6 Biostar (11).**

**Figulla Flexible Occlutech septal occluder (FSO)**

FSO is a flexible nitinol compound that forms the left and right discs (Occlutech GmbH, Jena, Germany) (Figure 7). This device is very similar to ASO in that it does not have micro screws to connect, which gives it more flexibility. There are many cases of copyright infringement between companies. Nitinol gap discs are filled with polyester pads with a disc to the left of the ball, which is smaller than the disc to the right. This difference can improve the alignment of the right septum and the small, flexible profile of the left. The ball and socket method of delivery increases flexibility during labor. This helps with large ASDs and missing tires, inexperienced operators despite. The angle created between the left and right discs corresponds to a high alignment after the launch. These unique characteristics make it an attractive choice for complex errors that result in the erosion of ASO (12).



**Figure 7 Figulla Flexible Occlutech septal occluder (FSO) (12).**

**Results**

The average extended size measured with a balloon catheter was 18.6 +/- 6.7 mm (diameter 7.1-37.2 mm). ASO referrals were successful in 191 patients (97%) and failed at 6. There was no significant difference between the 2 groups in the success rate of ASD closure (110/114 vs 81/83). Device resuscitation was required for 28: 21 patients in group I and 7 in group II (21/114 vs 7/83, P> .05) The estimated range of characteristic range in these 28 patients was significantly greater than those who did not require device reset (27.3 +/- 5.7 vs 17.1 +/- 5.5 mm, P <.01). Three patients experienced serious complications: 1 had a complete temporary atrioventricular block, 1 had a tamponade requiring fluid flow, and 1 had a device removed that required emergency surgery. One had distal embolism up to the end of the finger. Echocardiography 1 day, 3 months, 6 months, 12 months, and 24 months after the procedure

showed residual intensity 37/11 (19%), 15/189 (8%), 11/176 (6%), 7/131 (5%), and 3/72 (4%) patients, respectively (13).

## **Discussion**

Since the Food and Drug Administration approved ASOs in 2001, 200,000 ASOs have been applied worldwide, including 46,000 in the United States. However, data are not available on major ASDs managed using ASO. Atrial septal defect (ASD) is one of the most common congenital heart problems that develops later in life. It is characterized by malformation in the intrathecal septum, which causes venous return to flow from the left atrium (LA) to the right atrium (RA). The heart rate depends on the size of the shunt and the combined conduction, ranging from irregularity to right-sided volume load, pulmonary arterial hypertension, and atrial arrhythmias. The traditional method of closure is surgery, which has been performed for more than 50 years and the current expectation has not reached death. Recently, advances in catheter-based technology have made device closure the first way to close the ostium secundum ASD. The ASD device shutdown was first reported in 1976 by King et al. It has the benefit of saving the patient from open heart surgery and cardiopulmonary bypass and allows for shorter hospital stays and quicker recovery (14).

## **Summary and Conclusion**

A wide range of atrial septal closure devices facilitate percutaneous closure of simple and complex septal defects. Safety studies and feasibility studies show the success of high-level distribution, as well as solid factors that prioritize problems. A wide range of sizes caters to the needs of many people with disabilities with very few contradictions. The introduction of decomposing technologies and nickel-free products can reduce long-term success. Delivery methods that reduce air embolism and provide flexibility are an added benefit to avoid problems. The continuous development of ASD technology and the long-term success of existing devices ensure that percutaneous transcatheter ASD closure remains a popular procedure. ASO ASD is a safe and effective device for closing the transcatheter. 1 Rim deficiency, especially the front upper rim, does not affect the chances of successful ASD closure.

## **COMPETING INTERESTS DISCLAIMER:**

Authors have declared that no competing interests exist. The products used for this research are commonly and predominantly use products in our area of research and country. There is absolutely no conflict of interest between the authors and producers of the products because we do not intend to use these products as an avenue for any litigation but for the advancement of knowledge. Also, the research was not funded by the producing company rather it was funded by personal efforts of the authors.

## References

- 1) Baspinar O, Kervancioglu M, Kilinc M, Irmet A. Bioabsorbable atrial septal occluder for percutaneous closure of atrial septal defect in children. *Tex Heart Inst J*. 2012;39(2):184–189.
- 2) Behjati M, Rafiei M, Soltani MH, Emami M, Dehghani M. Transcatheter closure of atrial septal defect with amplatzer septal occluder in adults: immediate, short, and intermediate-term results. *J Tehran Heart Cent*. 2011;6(2):79–84.
- 3) Boutin C, Musewe NN, Smallhorn JF, Dyck JD, Kobayashi T, Benson LN. Echocardiographic follow-up of atrial septal defect after catheter closure by double-umbrella device. *Circulation*. 1993;88(2):621–627.
- 4) Butera G, Romagnoli E, Carminati M, et al. Treatment of isolated secundum atrial septal defects: impact of age and defect morphology in 1,013 consecutive patients. *Am Heart J*. 2008;156(4):706–712.
- 5) Crawford GB, Brindis RG, Krucoff MW, Mansalis BP, Carroll JD. Percutaneous atrial septal occluder devices and cardiac erosion: a review of the literature. *Catheter Cardiovasc Interv*. 2012;80(2):157–167.
- 6) El-Said H, Hegde S, Foerster S, et al. Device therapy for atrial septal defects in a multi-center cohort: acute outcomes and adverse events. *Catheter Cardiovasc Interv*. 2015;85(2):227–233.
- 7) Freixa X, Ibrahim R, Chan J, et al. Initial clinical experience with the GORE septal occluder for the treatment of atrial septal defects and patent foramen ovale. *EurIntervention*. 2013;9(5):629–635.
- 8) Godart F, Houeijeh A, Recher M, et al. Transcatheter closure of atrial septal defect with the figulla ASD occluder: a comparative study with the Amplatzer Septal Occluder. *Arch Cardiovasc Dis*. 2015;108(1):57–63.
- 9) Jones TK, Latson LA, Zahn E, et al. Results of the US multicenter pivotal study of the HELEX septal occluder for percutaneous closure of secundum atrial septal defects. *J Am Coll Cardiol*. 2007;49(22):2215–2221.
- 10) Kaya M, Akpek M, Celebi A, et al. Initial clinical experience with the GORE septal occluder for the treatment of atrial septal defects and patent foramen ovale. *EuroIntervention*. 2014;10:626–631.
- 11) Morgan G, Lee KJ, Chaturvedi R, Benson L. A biodegradable device (BioSTAR) for atrial septal defect closure in children. *Catheter Cardiovasc Interv*. 2010;76(2):241–245.
- 12) Nugent AW, Britt A, Gauvreau K, Piercey GE, Lock JE, Jenkins KJ. Device closure rates of simple atrial septal defects optimized by the STARFlex Device. *J Am Coll Cardiol*. 2006;48(3):538–544.
- 13) Pavlovic M, Buellesfeld L, Meier B. Tools and techniques: PFO/ASD closure. *EuroIntervention*. 2014;7(3):66–69.
- 14) Prokselj K, Kozelj M, Zadnik V, Podnar T. Echocardiographic characteristics of secundum-type atrial septal defects in adult patients: implications for percutaneous closure using Amplatzer septal occluders. *J Am Soc Echocardiogr*. 2004;17(11):1167–1172.

UNDER PEER REVIEW