

Degeneration in Renal cells of Fresh Water Fish (*Channa punctatus*) under Exposure of Nigrosine Black (Acid Black-2), a Tanning Industry Dye.

Abstract:

Nigrosine Black (Acid Black-2) is popularly used in tanning industries and a huge amount of this dye comes out with effluent of tanning industries, this dye reached near water bodies, and what impact produced on their aquatic life not study yet, Hence a study was a plan to find out the impact of Nigrosine black dye on the renal cell of freshwater fish *Channa punctatus*. Sub-acute and chronic exposure to Nigrosine Black produced significant renal cellular degeneration in fish *C.punctatus*. The 1/20th LC₅₀ (96h) of the Nigrosine Black produced degenerating changes in the kidney tissues of fish. Renal corpuscles were revealing swollen and contained some degenerated RBC and thmbrocytes, which appeared to be cellular debris in Bowman space, due to the rapid destruction of the nuclei of erythrocytes. The liberated hemoglobin and other cytoplasmic materials were also observed, while 1/20th of LC₅₀ (96hr) of Nigrosine Black produced renal degeneration in Bowman's capsule and swelling in the glomerulus in the intoxicated fish along with renal tubules atrophy, degeneration as compared to the control group of fish. The low dose of Nigrosine Black Toxicity in fish produced nephropathy, and nephrosis. While the high dose of Nigrosine black dye produces Glomerulonephritis in experimental fish.

Keyword- Renal cell, cellular degeneration, Nigrosine Black, Renal corpuscles, thmbrocytes, Bowman's capsule

INTRODUCTION

In Indian tanning industries, about 700000 tons of hides have processed every year by 3000 tanneries. Among these tanneries, few large firms are reported and more than 90 percent of tanneries are small to medium-sized. Small and medium-size tanning industries are processed less than two to three tons of skin/per day. These tanneries are processed sheep goat cow and buffalo hides and use vegetable and chrome tanning techniques. The thick concentration of tanning industries is located in India along the bank of the Ganga River System at Jajmau area in city Kanpur of Uttar Pradesh while in South India these industries are located around the Palar River System.

Most of the Indian tanneries are using old techniques and production methods and these techniques are responsible for a high load of effluent pollutants. So, a tannery needs 130 tons of dye instead of 100 tons of dye. These 30 tones dyes go out as effluent that contaminates soil and water bodies located around the tanning industries. Olivera *et al.*, (2006) reported the presence of Azo dyes in drinking water in Brazil and produced mutagenicity in aquatic animals. Cavallin *et al.*, (2015) observed the effect of wastewater treatment plant effluents on fish reproduction and they conclude that wastewater containing compounds has affected the endocrine system especially hypothalamic-pituitary-gonadal axis function.

Pickering *et al.*, (1984) investigated acute and chronic toxicity of dyes and pigment receiving effluent to fathead minnow and they found that effluent is lethal to the embryos and larvae of fish.

Bomberger and Boughton (2004) reported the waste from the manufacture of dyes and pigments is a large source of aquatic pollution.

Some workers also studied the toxic effect of different dyes on freshwater fish Rai *et al.*, (2005); Barot and Bahadur (2013, 2014, 2015, and 2015a); Kaur *et al.*, (2015) in fishes and King (2015) in Human. Otavio *et al.*, (2017) studied ecotoxicology risk assessment of the leather industries using Acid Black-210 dye and they conclude this dye is safe from the ecotoxicological point of view.

Yoshifumi *et al.*, (2017) observed the lethal and sub lethal effects of Aniline and chlorinated Aniline on Zebra fish embryos and larvae and they were found that Aniline showed delayed lethal effect on the fish embryo. Srivastava *et al.*, (2018) revealed alterations in the activity of a certain enzyme in the gill of a *Labeo rohita* when exposed to an Azo dye, Eriochrome Black -T. Vigneshpriya *et al.*, (2020) found out that green dye exposure to *Labeo rohita* brings out alteration in hematology, biochemistry, enzymology, and histopathology parameters in experimental fishes.

Alaguprathana and Poonkothi (2021) were observed histoarchitecture alteration in the cell of the kidney when they exposed to methyl orange dye solution. Pathophysiological alteration in RBC of freshwater fish *Channa punctatus* under Nigrosine Black dye was observed by Srivastava (2022).

The effluent brought out by tanning industries contains many dyes and exerts a severe impact on the ecosystem. The released effluent from tanning industries contains investigating dye that contaminates the water stream, river, and underground water system as well as the ecosystem nearby. The effluent which contains the dye Nigrosine Black will cause a variety of toxic effects on aquatic organisms in recipient water. Kidney, gill, and skin play a major role in osmoregulation, ion

salt balance, and excretion in freshwater fishes. If these dyes affect the renal system, it will negatively impact the fish's health and well-produced high mortality among them. There are copies of literature available on the various impacts of dyes on the different organs of fish but no study is present on the impact of Nigrosine Black on the renal system of freshwater fish. Hence keeping this point of view, we decided to investigate the Impact of Nigrosine Black (Acid Black -2) a tanning industry dye on the histoarchitecture of renal cells in freshwater fish *Channa punctatus*.

MATERIALS AND METHOD

Test animal

According to USEPA, (1985), because of their surroundings, fishes are excellent study models for studying the effects of water and sediment borne pollutants. There are several other good reasons for studying toxicity in fish.

1. As many of disease are related to environmental quality.
2. Various pollutants have toxic potential.
3. Fishes are easy to obtain. There is a wide range of knowledge and its economic interest facilitates the search for research resources.

Our test animal model is freshwater fish *Channa punctatus* (Bloch.) fulfill all the criteria as out lined above. It is easy to available and acclimatizes due to its air breathing habitat and hardy in nature. The fish live generally in low oxygen contained, polluted freshwater bodies and can be cultured for its economic and food value.

Collection of Freshwater Fish *Channa punctatus* and acclimatization.

Fishes of both sexes with varying weight ($150\text{gm}\pm 3.45$) approx. 4 inches in length were collected from a local fish farmer from Jyoti fish Farm, Kanpur city, and disinfected by dipping them in 0.01% KMNO₄ solution. After collection, the fish were maintained in glass aquaria for about 10 days for acclimatization. Fish were kept in a large size aquaria (3`x1.5`x1.5`) containing 80 liters of water in each. Commercial fish food was supplied daily with water that was 1/10th of their body weight. The water was changed daily with aeration.

(Photograph -1 and 2)



Photo 1 and 2 showing test animal *Channa punctatus* is acclimatized ten days prior to experiment.

Test chemical:

The test chemical is used in the present study is Nigrosine black dye (Acid Black-2), procured from a local vendor in Kanpur city and it has the following chemical property (PUBCHEM 2022).

Chemical Properties of Test Chemical.

Appearance	Black Powder
CAS Number	8005-03-6
IUPAC Name	Disodium(6e)-4-Amino-3-(4-Nitrophenyl)Diazenyl-5-Oxo-6-(Phenylhydrazinylidene)Naphthalene-2,7-Disulfonate
Melting Point	275° C
Molar Mass	616.49g/mol
Molecular Formula	C ₂₂ H ₁₄ N ₆ Na ₂ O ₉ S ₂
NFPA 704	H-0,F-1,R-0,C-NA
RTECS Number	GC4762250
Solubility	Soluble 10-50 mg/ml at 64 °F (NTP)

Uses: Nigrosine is used in the dyeing of leather, wood, and textiles, manufacturing of ink, shoe polish cream, carbon paper, and toner.

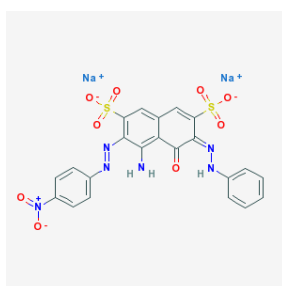


Fig 1: Molecule Structure Image of Nigrosine black

Table 1: Physico - Chemical Parameters of water, which was used in aquaria and their Methods of Analysis.

Parameter	Method Of Analysis	Range	References
pH	Digital pH meter	7.36 ± 1.97	
Total hardness	EDTA titrimetric method	283.22 ± 4.57 mg/l	APHA (2005)
Dissolved oxygen	Winkler method	10.2 ± 0.44 mg/l	APHA(2005)
Turbidity	Nephelometric	281 ± 3.85 mg/l	APHA (2005)
Temperature	Digital thermometer	28.87 ± 1.47 ^o C	APHA (2005)

Experiment design, Dose, and schedule of Experiment.

Dose and schedule of experiment was followed as **Srivastava (2022)**

1. 1/5th concentration of LC₅₀ i.e. 378 mg/liter for 56 days exposure (sub-acute).
2. 1/20th concentration of LC₅₀ i.e. 94.5 mg / liter for 80 day exposure (chronic).
3. Exposed fish in normal water used as controlled with the whole duration of the treated experiment.

All parameters for study in fish will measure at 7, 21, and 35 days for sub-acute toxicity while 20, 40, 60, and 90 days for chronic toxicity test along with control. Each group had 10 fish.

Histological Study

All treated and control fish was sacrificed according to the schedule of the experiment. Tissues of treated and control animals were preserved in 10 per cent saline formaldehyde solution and the procedure for histology was as follows (Kolomer *et al.*,1960)
 Tissue fixation → washing → Dehydration → Cleaning → Wax embedding → Wax Block Making → Wax block cutting → Wax ribbon making → Wax ribbon → de-waxing
 Hydration → Staining (Haemotoxyline + Eosin) → Mounting. Histologically prepared slides were seen under microscope for identification of pathological lesion in renal tissues of kidney in experimental fish.

Kidney Histology of Control Group Fish

The histopathology of the control group fish kidney shows that the nephron is an excretory part and it is inter-fused into hematopoietic tissue. The anterior region of the kidney has more hematopoietic tissues but the number of nephrons increased caudally with reduced hematopoietic tissue. Nephrons are arranged in a chaotic manner and different parts of nephrons are scattered virtually anywhere. A nephron of control fish has the following parts.

1. Glomerulus
2. Different tubules (Neck segment, proximal and distal tubules)
3. Collecting ducts: - These are differentiated from tubules by their cuboidal epithelium manner, large diameter and presence of smooth muscle fibers with connective tissue.

The glomerulus is a complex structure and its components are the fenestrated capillary endothelium, Glomerulus basement membrane, podocytes, and parietal epithelium cells. These parietal epithelial cells lined the bowman`s space. Some plasma filtrates were also seen in bowman`s space. The entire glomerular tuft is supported by mesangial cells. The capillaries branches of the renal artery are seen in the glomerulus. Few melanomacrophages (Mnc`s) were also present in between hematopoietic and lymphoid tissues of the control group fish`s kidneys. Eosinophilic granules cell (EGC) was also revealed (**Photograph 3**).

Neck renal tubules were small in size with low cuboidal epithelium and their brush border has long cilia. The central canal of neck tubules has a small diameter in comparison with proximal tubules. The nuclei of neck tubules were oval in shape and located basally (**Photograph 3**).

The proximal convoluted tubule (1st segment) was large in comparison with neck tubules and small in comparison with distal tubules in terms of diameter. The anterior region of proximal tubules epithelium was cuboidal to columnar in shape and their nuclei are large in size and round in shape. The nuclei were located in the center of the cell and a few were located at the base portion of the cell. The Brush border of proximal tubules was distinct and the central canal was large in comparison with neck tubules (**Photograph 3**).

The posterior proximal convoluted tubule (2nd segment) epithelium was tall columnar in shape and their nuclei are oval in shape and it was located centrally in the cell. Their brush boarder was prominent (**Photograph 3**).

Distal convoluted renal tubules have columnar was wide in diameter. The epithelium has oval shape nuclei and is located at the base of the cell. There was no brush boarder in distal convoluted renal tubules (**Photograph 3**).

Histology of Fish Kidney Exposed in to 1/5th LC₅₀ of Nigrosine Black

In the present study, the exposure of 1/5th of LC₅₀ of Nigrosine black (378 mg/liter) produced vacuolization of the epithelial cells of tubules. The nuclei of proximal renal tubules showed vacuolation and some of them were pycnotic. There were mild degenerations of the cells membrane also present on the 7th day of the experiment. **(Photograph 4)**

Exposure to 1/5th LC₅₀ of Nigrosine black for 21 days in experimental fish produced more vacuolization in the different renal cells. There was hyperplastic growth of cells and the nuclei of the cells were displaced to the periphery. The cells of the renal corpuscles showed cytoplasmolysis. The nucleus of cells showed lysis leading to a gap in between the cells. Due to the lysis of the cell membrane of adjacent cells, there was an aggregation of the nuclei leading to the syncytial condition. **(Photograph 5)**

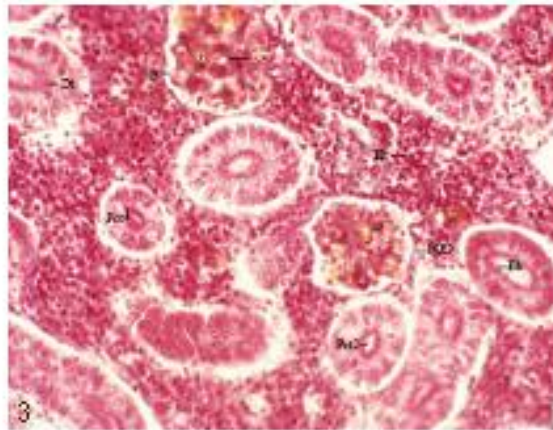
In experimental fish that were exposed to 1/5th LC₅₀ of Nigrosine black for 35th days, the toxicant produced significant pathological changes in the kidneys of experimental fish. There were large vacuoles found in the interstitial cells. Most of the cells showed cytoplasmolysis in the multinucleated condition. **(Photograph 6)**

Histology of Fish Kidney Exposed into 1/20th LC₅₀ of Nigrosine Black.

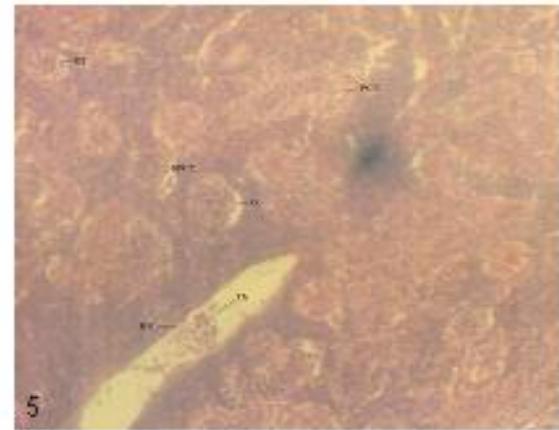
The present study found that on the 20th day of the experiment, 1/20th of LC₅₀ Nigrosine black (94.5 mg/l) exposure to experimental fish produced mild histopathological changes in the kidney. The distal and collecting tubules (convoluted) of the kidney showed mild degeneration and have a large lumen due to hypertrophy **(Photograph 7)**.

After the 40th day of experiment, the cells of the kidney were showing vacuolization, shrinkage and breakage of tissue. Swollen nuclei in degenerated tubular epithelium were also observed in the kidney of fish exposed to 1/20th LC₅₀ of Nigrosine Black **(Photograph 8)**.

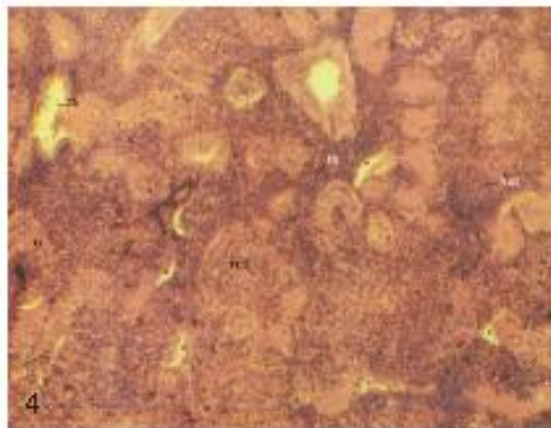
Within the 60th days of the experiment, the kidney of fish showed that the cell boundaries were disrupted and hence the cells became indistinct. Glomerulus disorganization, pycnotic nuclei, degeneration and atrophy of renal tubules, Intercellular spaces formation were also observed in experimental fish **(Photograph 9)**.



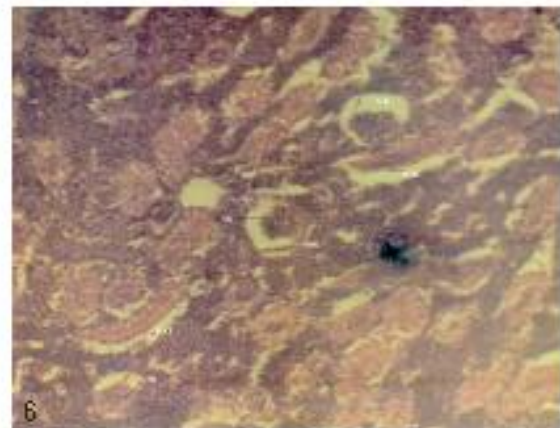
Photograph-3 Showing TS. kidney of *C. punctatus* in control group with standard structure Glomeruli (G) Bowman space (B), Brush border (Bb), Erythrocyte (E), Distal convoluted tubules (DT), Proximal convoluted tubules (Pct-1) and (Pct-2), Haematopoietic tissue (Ht), Podocytes cells (POD) X400.



Photograph 5 showing T.S. Kidney of *C. punctatus* exposed 1/5 LC of Nigrosine black dye. Shrinkage in renal peripheral tubules is seen at 21 day of experiment along with thrombocyte in blood vessels X400

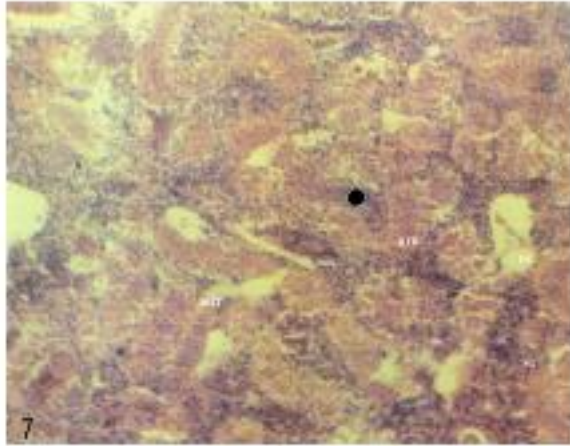


Photograph-4 showing T.S. Kidney of *C. punctatus* exposed 1/5 LC of Nigrosine black dye. Mild degeneration in renal peripheral tubules is seen at 7 day of experiment along with thickening of renal tubules. X400

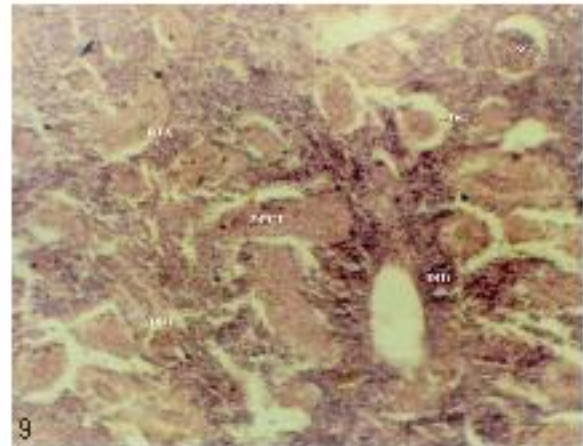


Photograph 6 showing T. S. Kidney of *C. punctatus* exposed 1/5 LC of Nigrosine black dye. Thickening of parietal epithelium cell line of Bowman's capsule, increased space between glomerulus and Bowman's space (SB) Shrunken glomerulus (SG), Necrosis in renal tubules, renal tubule atrophy (RTA) were seen at 35 day of experiment. X400

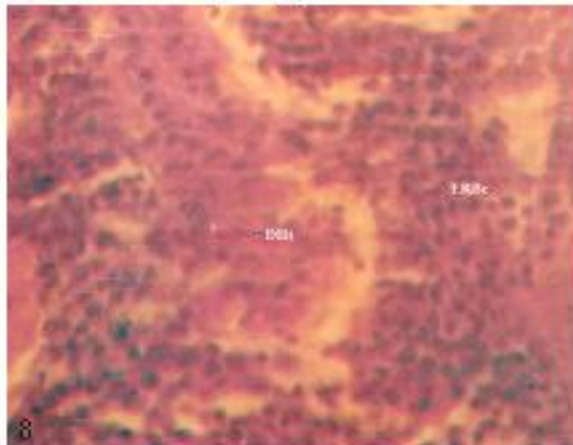
1 Degeneration and atrophy of renal tubules, degeneration in the glomerulus, disorganization of the glomerulus, severe necrosis, and highly pycnotic nuclei were observed at the 90th days of the experimental fish that were exposed to 1/20th LC 50 of Nigrosine black with the variable degree. (Photograph- 10)



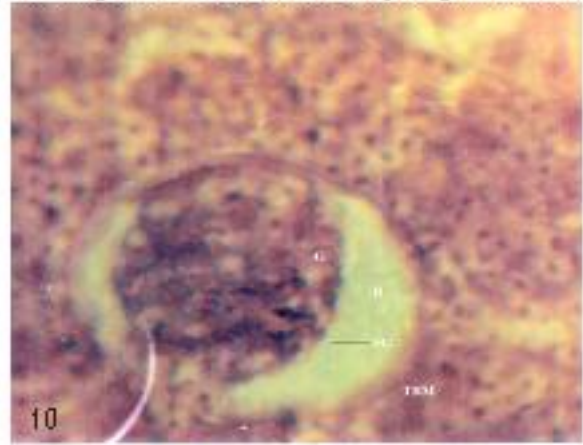
Photograph-7 showing TS. Kidney of *C. punctatus* exposed 1/20th LC₅₀ of Nigrosine black dye. Mild renal tubules degeneration (RTD) , renal tubules atrophy (RTA), Degenerated Glom erulus (DG), shrunk glomerulus (SG), were seen at 20th day of experiment . X400



Photograph 9 showing TS. Kidney of *C. punctatus* exposed 1/20th LC₅₀ of Nigrosine black dye. Renal tubules atrophy (RTA), degenerated proximal convoluted tubules (DPCT), Degenerated glomerulus (DG) Degeneration of hematopoietic tissue were seen at 60th day of experiment . X900



Photograph-8 showing TS. Kidney of *C. punctatus* exposed 1/20th LC₅₀ of Nigrosine black dye. Degeneration in hematopoietic tissues (DH) and fragmented Red blood cells (FRBC) were seen at 40th day of experiment . X400



Photograph-10 showing T.S. Kidney of *C. punctatus* exposed 1/20th LC₅₀ of Nigrosine black dye. Increase space between Glomerulus and bowman parietal epithelium cell line (TBM), Shrink Glomerulus (SG) and thick parietal membrane were seen at 90th day of experiment . X1000

DISCUSSION

Fish kidney is a composite organ with three distinct function i.e. excretory, hematopoietic and endocrine. In Nigrosine black dye exposed fish kidney were showed a lot of histopathological variation which indicate alteration in renal function of toxicated fish. In any renal disease they affected any of the four major structural component of kidney i.e. glomerulus, tubules, interstitial tissue and blood vessels separately, because these all structure

are interdependent hence that disease in one functional unit almost affected neighboring structure (Frank *et al.*, 2009)

The kidney of the Nigrosine black dye exposed group fish showed highly significant histopathological alteration like fatty change in the renal tubular cells. The most common changes found in the kidneys of both exposure groups were severe degeneration and necrotic changes in the tubules of renal tissues. However, intra-renal hematopoietic tissue also showed significant changes like distortion of the continuity for the parenchyma of renal tissues and increased lymphocytes in the kidney. Dose and time duration enhance the quantity of hemosiderin pigment was also observed indicating the erythrocyte disruption and accumulation of this pigment in melanomacrophages. In addition to necrotic and degenerative changes in the focal areas of the epithelium and necrosis of the renal tubules, there was atrophy of glomeruli and widening of the space between the Bowman's capsule and declinator glomeruli. The fatty change in the renal tubular cell was significantly increased over time. In fish, as in higher vertebrates, the kidney performs an important function to maintain homeostasis. Kidney tissues are the main organs that are affected by water contaminants (Thophon *et al.*, 2003; Mela *et al.*, 2007). In the present study, the kidneys often show cloudy swelling in the tubular cells after exposure to Nigrosine Black. Cengiz (2006) observed degeneration in the renal canal, pycnotic nuclei in hematopoietic tissue, and glomerulus degeneration. Similar kidney changes have been reported in Nile Tilapia (Benli *et al.*, 2008).

In the present study, the exposure of 1/10th and 1/20th LC₅₀ of Nigrosine black dye toxicant to experimental fish showed mild changes in intra-renal hematopoietic tissue like distortion of the continuity of the renal parenchyma and increased lymphocyte in the kidney. The cells showed hyperplastic condition and there was an aggregation of the cells also. Along with time duration the hemosiderin pigment that indicating the erythrocyte disruption and accumulation of this pigment in melanomacrophages. Cytoplasmolysis was observed in the corpuscles of kidney cells. Declinator and necrotic changes in renal tubular epithelium and focal areas of necrosis, there was atrophy of glomeruli, and widening of the space between the Bowman's capsule and glomerulus were also revealed.

The results of the present study are different from the above-mentioned results of various authors and there is no study is seen in past and current literature cited for Nigrosine black toxicity. This is the first study about the toxicity of Nigrosine Black on the kidneys tissues of fish.

Changes in the kidneys of the tilapia have been observed in a wide variety of fish exposed to heavy metals, and these changes have been described by Oliveira Ribeiro *et al.*, (2002); Thophon *et al.*, (2003) and Gupta and Srivastava (2006). Some authors (Venkatram *et al.*,2010; Rantilla *et al.*, 2017; Florence *et al.*, 2018; Millena *et al.*, 2018; Priyatha and Chitra 2019; Malik *et al.*,2020; Bilal *et al.*, 2021; Alaguprathana and Poonkothai 2021; Shahid *et al.*, 2021; and Bilal *et al.*,2021)were also reported cyto- nephrotoxicity in fishes under exposure of different industrial effluents and dyes. The present result shows that the Nigrosine black dye directly affects the aquatic life of freshwater fish. Therefore, a scientific method of detoxification is necessary to improve the health of these economical fish in any stressful environmental conditions. However, the high concentration of the analyzed dye in the whole body tissue examined can explain the role of these problems. Fish contaminated with Nigrosine black dye undergo pathological changes, resulting in inhibition of metabolic processes, hematological changes, and reduced fertility and survival. From this study, it can be concluded that dye tends to accumulate in polluted environments along with fish. Since practically all dyes tested were found to be in high concentration, the government should maintain laws that ensure that industries have standard waste treatment plants before discharging their waste into water bodies.

CONCLUSION

- The low dose of Nigrosine Black has produced an alteration in the histology of kidney tissue especially proximal tubules, distal tubules, Collecting duct, and glomeruli but it was not severe.
- Changes in Glomerular structure indicate an alteration in blood flow as well as flow-through tubules and composition of filtrate after which it affected the tubular epithelium.
- Occlusion of the tubular lumen may increase as the pressure in Bowman's space increases-resulting in glomerular atrophy.
- As a consequence, a disorder of one component of the kidney will sooner or later have severe implications for another component of the kidney as well.
- The low dose of Nigrosine Black Toxicity in fish produced nephropathy, and nephrosis.
- While the high dose of Nigrosine black dye produces Glomerulonephritis in experimental fish.

- These histological alterations (nephropathy, nephrosis, and Glomerulonephritis) may also affect the hematopoietic and endocrine function of experimental fish. There is a need to further investigation of these factors under Nigrosine Black toxicity in fishes.
- Thrombocyte accumulation in renal tissue also indicates extensive hemorrhage due to glomerulonephritis.

UNDER PEER REVIEW

REFERENCES

- Alaguprathana, M. and Poonkothai, M. Haematological, biochemical, enzymological and histological responses of *Labeo rohita* exposed to methyl orange dye solution treated with *Oedogonium subplagiostomum* AP1. *Environ Sci Pollut Res* **28**, 17602–17612 (2021). <https://doi.org/10.1007/s11356-020-12208-7>
- Alaguprathana, M.; and Poonkothi. M. (2021) Haematological, biochemical, enzymological, and histological responses of *Labeo rohita* exposed to methyl orange dye solution treated with *Oedogonium subplagiostomum* AP1. *Environ. Sci. Pollut. Res.* 28,17602 -17612. <https://doi.org/10.1007/s11356-020-12208-7>
- American Public Health Association. (1926). *Standard methods for the examination of water and wastewater* (Vol. 6). American Public Health Association.
- Barot. J. and Bahadur. A. (2013) Behavioural and histopathological effect of Azo dye on kidney and gill of *Labeo rohita* fingerlings. *Journal of Environmental Biology*, Vol.34,147-152.
- Barot. J. and Bahadur. A. (2014) Toxic effect of Azo dye (C.I. Direct Green 6) on blood parameters of freshwater fish *Labeo rohita* (Hamilton) *Journal of Cell and Tissue Research* Vol.14(2) 4251-4254. www.tcrjournal.com
- Barot. J. and Bahadur. A. (2015) Evaluation of Azo dye toxicity using some hematological and histopathological alteration in fish *Catla catla* . *World Academy of Science, Engineering and Technology International journal of biological food, Veterinary, and Agricultural Engineering*. Vol: 9, No: 5, <https://www.researchgate.net/publication/326914598>
- Barot. J. and Bahadur. A. (2015) Toxic impacts of C.I. acid orange 7 on behavioral, haematological and some biochemical parameters of *Labeo rohita* fingerlings. *International Journal of Scientific Research in Environmental Sciences*.3(8), pp.0284-0290

- Benli Aysel Çağlan Karasu , Gülten Köksal, Ayhan Ozkul (2008) Sublethal ammonia exposure of Nile tilapia (*Oreochromis niloticus* L.): effects on gill, liver and kidney histology. *Chemosphere*. 72(9):1355-8. DOI: [10.1016/j.chemosphere.2008.04.037](https://doi.org/10.1016/j.chemosphere.2008.04.037).
- Bilal Hussain, Hassan Sardar, Muhammad Sajad, HiraYaseen, Sulman Shafeeq, K.A.Al-Ghanim, Ahmed Mustafa, Shahid Mahboob.(2021) Assessment of Cyto-Nephrotoxicity and Growth Performance In *Labeo Rohita* Induced by Fluorescein Dye Y and B. *Journal of King Saud University - Science*, Volume 33, Issue 8, 101672, <https://doi.org/10.1016/j.jksus.2021.101672>
- Bilal Hussain, HiraYaseen; Khalid-Al-Ghanim; F.Al-Misned; Muhammad Qasim; N.Al-Mulhm; Shahid Mahboob (2021) A study on risk assessment of effect of hematoxylin dye on cytotoxicity and nephrotoxicity in freshwater fish: Food and water security prospective research. *Saudi Journal of Biological Sciences*. Volume 28, Issue 4, 2267-2271 <https://doi.org/10.1016/j.sjbs.2021.01.019>
- Bomberger. D and Boughton. R. (2004) Wastes from the manufacture of dye and pigments: volume 1. Azo dyes and pigments (benzidine and its congeners subsector) U.S Environmental Protection Agencies, Washington, D.C., EPA/600/2/-84/111A. http://cfpub.epa.gov/si/si_public_comments.cfm
- Borgia V.J. Florence.; Thatheyus A.J. ; Murugesan A.G. ; Catherine S.; Alexander P. and Geetha. I,(2018) Effects of effluent from electopating industry on the immune response in the freshwater fish, *Cyprinus carpio*. *Fish & Shellfish Immunology*. Volume 79, 86-92. <https://doi.org/10.1016/j.fsi.2018.05.010>
- Cavallin. J., K. Jensen., M. Khal., Dan Villeneuve., J. Mayasich., K. Lee., A. Schroeder., E. Eid., K. Nelson., R. Milsk ., B. Blackwell., J. Berninger., C. Lalone., L. Lee., M. Hughes., C. Blanksma., R. Jhonson and G. Ankley. (2015) Assessment of wastewater treatment plant effluent effects on fish reproduction. *Society of Environmental Toxicology and Chemistry*. Duluth, MN, March 09-11.

- Ceger P.,D.G.Allen,N. Choksi , A. Daniel , W. Eckel , J. Hamm , E. Harwood , T.Johnson , N. Kleinstreuer , C. Sprankle , J. Truax , M. Lowit (2021) Retrospective Evaluation of the Acute Fish Toxicity Test for Pesticide Registration. NICEATM Abstract: [11th World Congress on Alternatives and Animal Use in the Life Sciences](#),
- Frank Genten., Eddy Terwinghe, and Andri Danguy.(2009) in book : Atlas of fish histology Science Publishers, Enfield, NH, USA. <https://www.taylorfrancis.com/books/mono/10.1201/9780367803599/atlas-fish-histology-andr%C3%A9-danguy-franck-genten-eddy-terwinghe>
- Gupta Pallavi and Neera Srivastava (2006) Effects of sub-lethal concentrations of zinc on histological changes and bioaccumulation of zinc by kidney of fish *Channa punctatus* (Bloch). *Journal of Environmental Biology*. 27(2) 211-215
- Kaur Kirandeep., Kaur Arvinder, and Kaur Rajvir (2015) Cytogenotoxicity of Azo dye acid blue-113(ab-113) to *Channa punctatus* (Bloch.). *Journal of Environmental Research and Development* Vol.9 No.03,547-554.
- Kaur, R., Kaur, A., and Kaur, K. (2019) Ultra-morphology of the scale as an indicator of the stress of Acid Black-1 (AB-1, C.I.:20470) and zinc(Zn). *Environ.Sci. Pollut. Res.* 26,17121-17134. <https://doi.org/10.1007/s11356-019-05067-4>
- King-Thom Chung (2016) Azo dye and human health: A review. *Journal of Environmental Science and Health, Part C. Environmental Carcinogenesis and Ecotoxicology Reviews*. Volume 34(4).233-261.
- Kolmer. J.A.;Spaulding E.H. and Robinson, H.W. (1951) In: *Approved laboratory techniques* Vth Ed. Scientific Book Agencies Calcutta, India. <http://www.worldcat.org/title/approved-laboratory-technic/oclc/646503>
- Malik, D.S., Sharma, A.K., Sharma, A.K., Thakur, R. and Sharma, M. (2020). A review on impact of water pollution on freshwater fish species and their aquatic environment. In: *Advances in Environmental Pollution Management*:

Wastewater Impacts and Treatment Technologies, Volume 1, Eds. Kumar, V., Kamboj, N., Payum, T., Singh, J. and Kumar, P., pp. 10-28, <https://doi.org/10.26832/aesa-2020-aepm-02>

Mela M, Neto F.F, Yamamoto FY, Almedia R., Grotzner.S.R., Ventura.D.F., Ribeiro.C.A.de.O. (2014) Mercury distribution in target organs and biochemical responses after subchronic and trophic exposure to Neotropical fish *Hoplias malabaricus*. *Fish Physiol Biochem* 40: 245-256 DOI: [10.1007/s10695-013-9840-4](https://doi.org/10.1007/s10695-013-9840-4)

Millena Bruna Lunardelli . T. Cabral.; Carlos E.D.Vieira.; Luciana. F.Oliveira.; Wagner E.Risso.; Paulo C.Meletti.; Claudia B.R. Martinez (2018) Chromium accumulation and biomarker responses in the Neotropical fish *Prochilodus lineatus* caged in a river under the influence of tannery activities. *Ecotoxicology and Environmental Safety*. Volume 153, 188-194. <https://doi.org/10.1016/j.ecoenv.2018.02.023>

Murugesan, A.G., Ramathilaga, A., Samson Ponselvan, J.K. Michael.R. Dinakaran Immunotoxicity of Tannery Effluent to the Freshwater Fish *Cyprinus carpio* . *Bull Environ Contam Toxicol* **88**, 639–643 (2012). <https://doi.org/10.1007/s00128-011-0511-9>

OECD, T. (1986). OECD guidelines for the testing of chemicals. *Genetic Toxicology: Mouse Heritable Translocation Assay. Adopted on, 23*.

Oliveira Ribeiro CA, Belger L, Pelletier E, and Rouleau.C (2002) Histopathological evidence of inorganic mercury and methyl mercury toxicity in the arctic charr (*Salvelinus alpinus*). *Environ Res* 90: 217-225. DOI: [10.1016/s0013-9351\(02\)00025-7](https://doi.org/10.1016/s0013-9351(02)00025-7)

Olivera, D.P., P.A. Cannerio., C.M. Rech., M.Y. Zanoni., L.D. Claxton., and G. Umbuzeiro. (2006) Mutagenic compounds generated from the chlorination of dispersed azo-dye and their presence in drinking water. *Environmental Sci. and Techno*. American Chemical Society, Washington, DC, 40(21):6682-6689,

- Otavio Pelegriano Rocha.; Cibele Aparecida Cesila.; Elisa Maria Christovam.; Silvia Berlanga de Moraes Barros.; Maria Valnice Boldrin Zanoni.; and Danielle Plamade Oliveira. (2017). Ecotoxicological Assessment of the “Acid Black 210” dye. *Toxicology*. vol.376(1).113-119. <https://doi.org/10.1016/j.tox.2016.04.002>
- Pickering. Q., G.M. Shaul, and K. Dostal. (1984) Acute and Chronic toxicity to the Fathead Minnow, *Pimephales promelas* of effluents from a treatment plant receiving dyes and pigment processing wastewater. U.S. Environmental Protection Agency, Washington, D.C., EPA/600/D-84/161(NTIS PB84210517) http://cfpub.epa.gov/si/si_public_comments.cfm
- Priyatha C. V. and Chitra K. C.(2019) Sublethal Toxicity of Acid Orange 7 in the Freshwater fish, *Anabas testudineus* (Bloch, 1792), and the Role of Vitamin C as Antioxidant in the Prevention of Oxidative Stress. *International Journal of Scientific Research in Biological Sciences* Vol.6, Issue.2, pp.92-101, <https://doi.org/10.26438/ijsrbs/v6i2.92101>
- PubChem (2022) Acid Black 2; SID 459281445; <https://pubchem.ncbi.nlm.nih.gov>.
- PubChem[internet]. Bethesda (MD): National Library of Medicine (US), National center for biotechnology information;(2004). PubChem Substances Record for SID 135331703, 8005-03-6, Source: ChemIDplus. <https://pubchem.ncbi.nlm.nih.gov/substance/135331703>
- Rai. H.; Bhattacharya, M.; Singh, J.; Bansal, T.K.; Vats, P.; Banerjee, U.C. (2005) removal of dyes from the effluent of textile and dyestuff manufacturing industries: A review of emerging techniques with reference to biological treatment. *Critical review in environmental Science and Technology*, Vol.35, pp.219-238, ISSN.
- Rantilla Amwele, H., Papirom, P., Chukanhom, K., Beamish, F. W. H., & Petkam, R. (2017). Tissue Alterations in *Oreochromis niloticus* Following Chronic Exposure to Metal Complex Dark Green Azo Acid Dye and Anionic Surfactant Oil. *Environment and Natural Resources Journal*, 15(1), 41–50. DOI <https://ph02.tci-thaijo.org/index.php/ennrj/article/view/80745>

- S. Shahid , T. Sultana , S. Sultana , B. Hussain , M. Irfan, K. A. Al-Ghanim , F. A-Misned and Shahid Mahboob.(2021) Histopathological alterations in gills, liver, kidney and muscles of *Ictalurus punctatus* collected from pollutes areas of River. *Braz. J. Biol.* 81 (3) <https://doi.org/10.1590/1519-6984.234266>
- Shahid. S.; Sultana. T.; Sultana S.; . Hussain .B; Irfan . M.; Al-Ghanim .K. A.; Misned .F. A; and Shahid Mahboob. (2021) Histopathological alterations in gills, liver, kidney and muscles of *Ictalurus punctatus* collected from pollute areas of River. *Braz. J. Biol.* 81 (3). <https://doi.org/10.1590/1519-6984.234266>
- Srivastava, Jyoti. Prakash. (2022). Pathophysiologic Mechanism of Erythrocyte Morphological Alteration in Freshwater Fish *Channa punctatus* Under Exposure of Nigrosine Black (Acid Black-2 a Tanning Industry Dye). *International Journal of Environment, Agriculture and Biotechnolog*,7(1), 162–167. <https://doi.org/10.22161/ijeab.71.19>
- Srivastava. A.; Kumari. U.; and Nigam, A.K (2018) Alterations in the activity of certain enzymes in the gills of a carp *Labeo rohita* exposed to an Azo dye, Eriochrome black T: A biochemical investigation. *Fish Physiol. Biochem.* 44, 629-637 .<https://doi.org/10.1007/s/10695-017-0458-9> .
- Thophon. S , M Kruatrachue, E S Upatham, P Pokethitiyook, S Sahaphong, S Jaritkuan (2003) Histopathological alterations of white seabass, *Lates calcarifer*, in acute and subchronic cadmium exposure. *Environ Pollut.* 121(3):307-20. doi: [10.1016/s0269-7491\(02\)00270-1](https://doi.org/10.1016/s0269-7491(02)00270-1)
- USEPA (1985) Standard evolution procedure: Acute Toxicity Test for Freshwater Fish. Report no. 540/9 - 85006. 1 -17. NSCCEP. <https://nepis.epa.gov/Exe/ZyPURL.cgi?>
- Venkatram reddy, Velma Paul , and B. Tchounwou (2010) Chromium-induced biochemical, genotoxic and histopathologic effects in liver and kidney of goldfish, *carassius auratus*. *Mutation Research/Genetic Toxicology and Environmental Mutagenesis* Volume 698, Issues 1–2, DOI: [10.1016/j.mrgentox.2010.03.014](https://doi.org/10.1016/j.mrgentox.2010.03.014)

Vigneshpriya. D.; N. Krishnaveni.; S. Renganathan and R. Sri. Sakthi priyadarshani (2020) Impact of untreated and *Sargasuum wightii*-treated brilliant green dye exposure on Indian major carp *Labeo rohita* Ham.: haematology, biochemistry, enzymology, and histopathology. *International Journal of Phytoremediation*.22:8,819-826.
<https://doi.org/10.1080/s/15226514.2019.1710816>

Walia G. K., D. Handa. H. Kaur and R. Kalotra. (2013) Erythrocyte Abnormalities In a Freshwater Fish, *Labeo Rohita* Exposed To Tannery Industry Effluent. *International Journal of Pharmacy and Biological Sciences*. Volume -3, Issue 1;Jan-Mar .287-295.

WHO, (1966) environment health criteria No 180 USA.

Yoshifumi Horie.; Takahiro Yamagishi.; Masaaki Koshio.; Taisen Iguchi.; Norihisa Tatarazako. (2017) Lethal and sublethal effects of aniline and chlorinated aniline on zebrafish embryos and larvae. *Journal of Applied Toxicology*.Vol.37. (7) 836-841. <https://doi.org/10.1002/jat.3431>