

Haematological and Histopathological Examinations of African Catfish (*Clarias Gariepinus*) Exposed to Sub- Lethal Concentrations of Paraquat.

Abstract

The study was designed to investigate the sub-lethal effects of paraquat on haematological parameters and histopathology of the gills, skin and liver of *Clarias gariepinus* juveniles of mean weight (38.26 ± 1.20 g) and length (17.50 ± 1.55 cm). The fish were exposed to 10, 20, 30, 40 and 50% of the 96hrsLC₅₀ value of 107mg/l estimated from the 96 hours acute toxicity test for 30 days. Blood samples were collected into heparinized tubes for the analyses of some haematological parameters following the procedures of Ochei and Kolhalkar (2003) while the gills, skin and liver were also removed for histological examinations following the methods of Bancroft and Cooks (1994). The result revealed a significant reduction ($P < 0.05$) in the values of red blood cell (RBC), haemoglobin (Hgb), packed cell volume (PCV), mean cell volume (MCV), mean cell haemoglobin (MCH) and mean cell haemoglobin concentration (MCHC) from those of control. It was also observed that the white blood cell (WBC) and platelets (Plt) were however increasing significantly ($P < 0.05$) from those of the control as the test concentrations increased. The histology of the gills revealed some alterations such as epithelial proliferation, vacuolation of the mucus, and hyperplasia of epithelial tissue of the gill filament, lifting and necrosis of the secondary lamellae. The skin showed mucous cell proliferation, erosion of the epithelial lining, hypertrophy and necrosis of epithelial cells and widening of the epidermal and dermal layers. The liver exhibited cellular proliferation, sinusoid enlargement, congestion of the central vein, paranchymatous degeneration, vacuolar degeneration, pyknotic nucleic degeneration, lesions and necrosis with severity as concentration of paraquat increases. The gills and skin were observed to be the most effected tissues in this study. The study also revealed that paraquat was toxic to *C. gariepinus* and causes some haematological and histopathological alterations in the fish blood and tissues at concentrations higher than 30mg/l. Therefore, the use of paraquat by farmers should be regulated particular in area close to aquatic environment.

Keywords: Sub-lethal, Blood, Tissues, Paraquat and African catfish,

Introduction

The widespread use of various pesticides and their impact on the environment are now a worldwide phenomenon [1]. The effects of agricultural chemicals use and their residues on non – target organisms have not been seriously considered in Nigeria [2]. Indiscriminate use of pesticides, careless handling, accidental spillage, discharge of untreated effluent or runoff from farm lands into waterways have harmful effects on fish population and other aquatic life and may contribute to long term effects on the environment [3]. Herbicides are widely used all over the world to control the harmful effects of weeds on agricultural productions and fish farm however, usually accompanied by deleterious environmental and public health effects [4]. Although herbicide are designed to control plant pests by inhibiting photosynthesis but significantly large concentrations can be toxic to animal through necrosis [5]. Many modern herbicides are developed to be as selective against target organisms as possible, but it is rarely possible to achieve perfect control of one organism without the wider environment being exposed and susceptible non-target species affected [6]. Recently, the use of herbicides in agricultural practices is on the increase due to its availability, affordability and efficiency thereby causing ecological imbalance due to damage to non- target organisms [7] [8]. Water pollution by pesticides is a serious problem to all aquatic faunas, floras and man [9]. Aquatic organisms including fish are frequently

being exposed to wide varieties of environmental pollutants which may lead to deleterious effects such as decreased growth, alterations of physiological processes and ultimate death [10]. Direct and indirect contamination of aquatic environment with pesticides may cause fish kills, reduce fish productivity and elevates concentration of undesirable chemicals in edible fish tissues [11]. Ladipo *et al* [12] reported that herbicides accumulate in aquatic system and may cause adverse effect on the zooplankton community which are major source of food for young fishes. Fish and other aquatic fauna may be harmed directly and indirectly by contamination of herbicides in water, resulting to morbidity and mortality. It is imperative to find out the detrimental effects of pollutants especially herbicides on fish since they form important food chain. Fish are vital indicators of the effects of toxic compounds in aquatic toxicity [13], and are also important source of protein and essential fatty acids requirement in human diet.

Paraquat (1, 1-dimethyl-4, 4-bipyridinium dichloride) is one of the most common contact and non-selective herbicide for exterminating vegetative pests. It is used for controlling terrestrial weeds and aquatic plants in different countries and its presence is reported in many water bodies of the world [14] [15]. It is an herbicide widely used for broadleaf weed control [16]. Paraquat is moderately to highly toxic to many species of aquatic life including rainbow trout, bluegill, and channel catfish and Its toxicity to fish varies with the species, size, and the softness or hardness of water. At high levels, paraquat inhibits the photosynthesis of some algae in stream water and toxic to human beings when swallowed [17] [18]. According to Food and Agricultural Organization [19], approximately that 3,000,000 people are poisoned and 200,000 die yearly around the world from pesticide poisoning and majority of them are from developing countries. Studies have shown that Paraquat has the potential to impede the growth and weight of *Oreochromis niloticus* [20], negatively impact on the blood plasma activities of *Clarias gariepinus* [21] and induce respiratory stress, erratic swimming and instant death of fish [22]. Reports have also been may available on impaired physiological processes in *Clarias gariepinus* by significantly increasing the level of white blood cells, glucose, aspartate aminotransferase, and alanine aminotransferase [4], impacts on the immune and growth of the rainbow trout, *Oncorhynchus mykiss* [23]. Paraquat inhibits the photosynthetic ability of some algae in stream water thus disrupting the food web necessary for ecological balance [17]. Paraquat toxicity in fish especially *C. gariepinus* is not as much as reported for glyphosate [24]. Knowledge of toxicity of paraquat to *C. gariepinus* can be very helpful in predicting and preventing damage to aquatic life receiving waters as well as in regulating its use on farm lands.

Haematological parameter is widely used as a measure of stress and can be employ to evaluate the impacts of xenobiotics to organism [24]. Dethloff *et al* [25] reported that, the physiological responses of a fish to contaminated environment are reflected through the haematological parameters such as haemoglobin, haematocrit, blood counts, glycemia and ion concentration. Fish histology is the study for the interaction

between the environmental factors on the structure and functions of organs. Research on histology is important, especially in the field of problem induced by aquaculture conditions, aquatic pollution and diseases. Histological examinations which show pathological alterations upon exposure to toxicants have been useful to assess disease problems [26], nutritional stress [27], environmental stress [28] as well as physiological adaptations to water quality changes [29]. Histopathology, behavioral changes and acute toxicity were reported by Ayoola [30] after exposing African catfish (*Clarias gariepinus*) to glyphosate. Some information is available on the histopathological effects of pesticides on the organs of African catfish, *C. gariepinus* ([9]; [30], [31], [32] [2]. Histopathological changes of gills such as hyperplasia and hypertrophy, epithelial lifting, aneurysm and increase in mucus secretion have been reported after the exposure of fish to a variety of noxious agents in the water, such as pesticides, phenol and heavy metal [33].

Clarias gariepinus is an economically important freshwater fish and its culture is considerably increasing in Nigeria. They are highly esteemed group of fish with popular delicacy relish throughout Africa belonging to the family claridae. It is a prominent cultured species because of its fast growth rate, commands high market value and can tolerate difficult aquatic condition [34]. This study is aimed to investigate the sub-lethal concentrations of paraquat on *C. gariepinus* juveniles using haematological and histopathological alterations as indices for measurement.

Materials and Methods

Experimental fish and Chemical: One hundred and eighty (180) apparently healthy juveniles of *C. gariepinus* were procured from University of Calabar fish farm and transported to the wet labouratory of Fisheries Department CRUTECH, Obubra campus. The mean body weight and the length of the species were 38.26 ± 1.20 (g) and 17.50 ± 1.55 (cm) respectively. They were acclimated for 14 days during which they were fed with Copen feed at 3% body weight twice daily and terminated 24 hours prior to the commencement of the experiment [35]. Paraquat (1, 1-dimethyl-4, 4-bipyridinium dichloride) was procured from a local agro-chemical dealer shop at Ofatura - Adun, Obubra.

Sub – Lethal Toxicity Test

Sub lethal concentrations of 0.011, 0.021, 0.032, 0.043 and 0.053mg/l, determined from 10, 20, 30, 40 and 50% of the 96hrLC₅₀ value (0.107mg/l) was exposed to the other group of juveniles according to the method of [2]. The concentrations were obtained from the serial dilution of a stock solution of 200mg/l (1ml in 5 litres of tap water). Each treatment was in triplicate and lasted for 30 days during which the juveniles were fed twice daily to satiety. To avoid variations in the paraquat concentration, the test solutions were renewed daily in

other to maintain the strength of the toxicant. After 30 days of exposure three fish were sampled from each group for haematological and histopathological analysis.

Haematological analyses

Blood samples were collected from both control and experimental fish by puncturing the posterior caudal vein using a disposable 1.0mL syringe and 0.5mm needle. Blood was immediately transferred into anticoagulant bottles containing Ethylene diamine-tetra-acetic acid (EDTA) for analysis. Red blood cell (RBC), white blood cell (WBC) and platelets (Plt) were determined using Neubauer haemocytometer and the total cells expressed as 10^{12} cells/L for RBC and 10^9 cells/L for WBC and Plt following the methods of Ochei and Kolhakater [36]. Haemoglobin concentration were estimated using cyan methaemoglobin method and expressed as g/100mg/l according to Blaker and Silverton [37], while pack cell volume was done using a micro haematocrit method and expressed in (%) according to Ochei and Kolhakater [36]. Other parameters were calculated using the appropriate formulae according to Lee *et al* [38].

Mean cell volume (MCV) = $PCV \div RBC (10^{12} \text{ cells/l}) \times 100$ expressed in femtolitre (10^{-15}).

Mean cell haemoglobin (MCH) = $Haemoglobin \div RBC \times 10$ expressed in picogram (10^{-12} /g).

Mean cell haemoglobin concentration (MCHC) = $Haemoglobin \div PCV \times 100$ expressed in gram/100ml.

Histological procedures.

Three (3) fish each whose blood was sampled were dissected and the gills, liver and skin removed and preserved in 10% formaldehyde for 5 days. The tissues were removed from the fixative and rinsed in tap water for 5 minutes, dehydrated in ascending ethanol concentrations (70%, 80% and 90% alcohol) for 2 minutes, infiltrated in a wax miscible agent (xylene) for 2 minutes and then embedded in paraffin using standard protocols according to Bernet *et al* [39]. The fish tissues were then cut into sections of 5 μ m thickness using a rotary microtome (Leica RM 2235 Germany). The cut samples were dried in a hot air oven to remove moisture and then mounted on a glass slide. The sections were de-waxed in a wax-miscible agent, rehydrated through descending concentrations of ethanol (90%, 80% and 70% alcohol) for 2 minutes. The tissues were placed in haematoxylin solution for 3 minutes and aqueous eosin for 3 minutes, then mounted on a slide and covered with coverslip [40]. The tissues were examined, and microphotographs taken using a digital binocular compound LED microscope with a digital camera (Nikon 9000). Photomicrographs of the various sections showing the effects of paraquat on the cell structure of the target organ were made at x200, x300 and x400 magnifications.

Data analysis

Data obtained from the haematological examinations was subjected to analysis of variance (ANOVA) using statistical package for the social sciences (SPSS) version 20, where differences exist Turkey's Honest significant different (HSD) was used to separate the difference among treatments [41].

Results

Haematological parameters.

Haematological parameters of white blood cell (WBC), red blood cell (RBC), haemoglobin (Hgb) pack cell volume (PCV), platelets (Plt) and erythrocytes indices (MCV, MCH and MCHC) were analyzed as measure of the effects of paraquat on *C. gariepinus*. The mean values of the haematological parameters is shown in table 1. The result shows that the values of WBC ($5.20 - 14.55 \times 10^9$ Cells/L) and Plt ($6.40 - 13.67 \times 10^9$ Cells/L), were increasing with increase in concentrations. The values of red blood cell ($7.76 - 2.07 \times 10^{12}$ Cell/L), haemoglobin (21.47 – 8.89g/l) and PCV (60.46 – 26.84%), MCV (93.99 – 77.43fl), MCH (36.83 – 23.25pg) and MCHC (45.08 – 35.10g/l) decreased from control to the highest concentration (53.5mg/l). The analysis of variance (ANOVA) revealed that fish exposed to 10% of 96hrLC₅₀ value (10.7mg/l) were not significantly different ($p > 0.05$) from the control in all the parameters investigated. Whereas significant differences ($p < 0.05$) were observed with fish exposed to 40% (42.8mg/l) and 50% (53.1mg/l) from the control, those exposed to 30% (32.1mg/l) did not produce significant changes ($p > 0.05$) on the observed parameters except WBC and RBC which were different from the control.

Table 1: Haematological parameters of *C. gariepinus* exposed to paraquat

Conc (mg/l)	Haematological parameters							
	WBC (10 ⁹ Cells/L)	RBC (10 ¹² Cells/L)	Hgb (g/L)	PCV (%)	Plt (10 ⁹ Cells/L)	MCV (fl)	MCH (pg)	MCHC (g/L)
0.0	5.20±2.09 ^d	7.76±0.54 ^a	21.47±3.00 ^a	58.46±5.05 ^a	6.40±1.04 ^{bc}	93.99± 1.54 ^a	36.83±1.72 ^a	45.08±0.70 ^a
10.7	6.89±1.68 ^{cd}	6.29±0.47 ^{ab}	18.58±0.83 ^{ab}	53.76±2.63 ^a	6.86±1.35 ^{bc}	91.03±2.76 ^a	33.13±2.49 ^a	43.73±1.31 ^{ab}
21.4	9.65±1.87 ^{bc}	4.73±0.87 ^{bc}	13.81±1.47 ^{bc}	48.94±1.80 ^{ab}	7.97±2.56 ^{bc}	89.03±3.02 ^{ab}	28.41±0.65 ^{ab}	40.25±0.90 ^{abc}
32.1	12.27±0.26 ^{ab}	3.59±0.50 ^{cd}	12.56±1.37 ^{bcd}	46.48±5.73 ^{ab}	9.02±3.52 ^{abc}	86.90±1.72 ^{ab}	25.17±0.97 ^b	37.59±0.61 ^{bc}
42.8	12.43±0.49 ^{ab}	2.63±0.28 ^d	11.05± 0.91 ^d	43.15±0.91 ^{abc}	11.75±4.76 ^{ab}	68.65±0.82 ^c	22.96±0.71 ^b	35.60±0.52 ^c
53.5	14.55±0.96 ^a	2.07±0.18 ^d	8.89± 0.53 ^d	38.84±0.82 ^{bc}	13.67±2.75 ^a	77.34±6.99 ^{bc}	23.25±1.27 ^b	35.10±0.87 ^c

Means with the same superscript row are not significant at ($P < 0.05$). Conc.= concentration, PCV = packed cell volume , RBC= red blood cell counts Hgb = haemoglobin, MCV =mean cell volume MCH= mean cell haemoglobin MCHC= mean haemoglobin concentration, WBC =white blood cell count, Plt = platelet., fl = fentolitre, pg = picogram

Histopathology of the gills, liver and skin

The results of the photomicrographs showing the vertical sections through the gills is presented in figures 1A – 1D. The control (0.0mg/l) slide showed a normal morphology which consist of two distinct epithelial surfaces, filament, primary and secondary lamellae. Single squamous epithelial cells and mucus cells are scattered on both sides of the gill lamellae. The gill filament have numerous small folds which increased the total surface

area of the gill for gaseous exchange (Fig 1A). Alteration in the gill structure was observed for fish exposed to various concentration in plates 1B – 1D. The incidence observed include epithelial proliferation, vacuolation, and hyperplasia of the mucus and epithelial tissue of the gill filament, lifting and necrosis of the lamellar. At low concentration the gill showed cellular infiltration slight vacuolation and dilation of the lamellae. The severity increase with increasing concentration with the highest concentration showing complete degeneration, detachment and necrosis of the lemallae and epithelial cell of the gill filament.

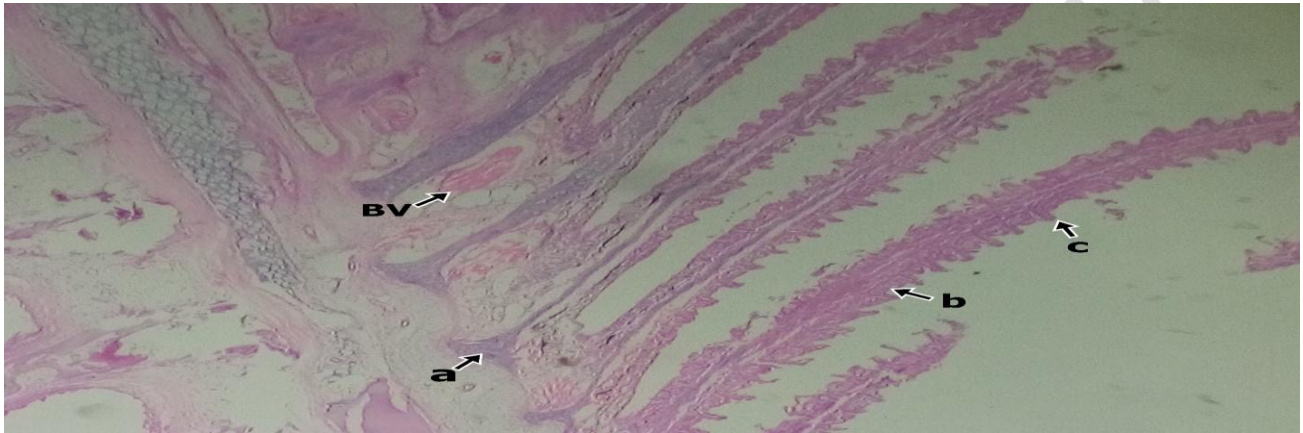


Figure 1A. Photomicrograph of the gill of *C. gariepinus* X 400 of control (0.0mg/l) showing normal histology (a) gill filament, (b) primary and (c) secondary lamellae. The blood vessel (BV), mucous and epithelial cell are well arranged.

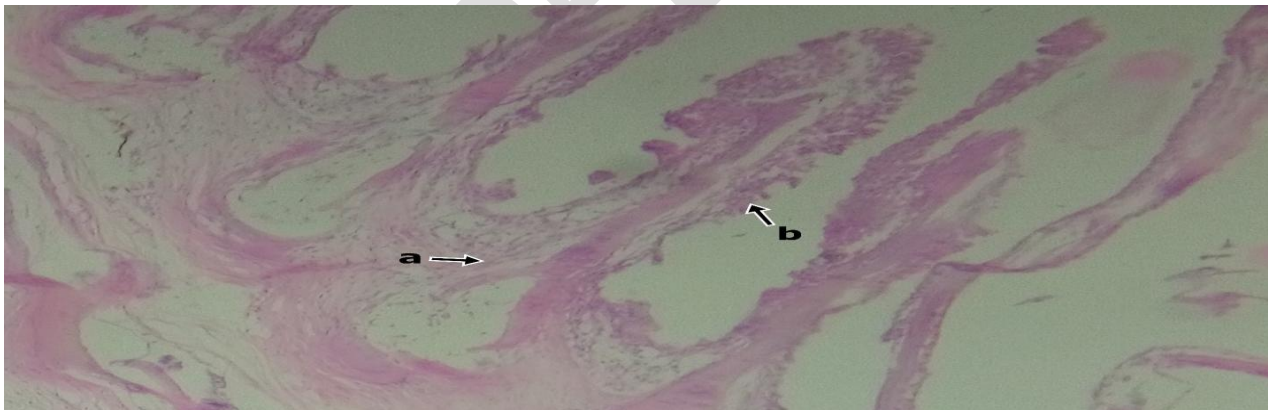


Figure 1B: Photomicrograph of the gill of *C. gariepinus* X 400 exposed to (10.7mg/l) of paraquat showing moderate erosion of (a) primary and (b) secondary lamellae. There was also mild vacuolization, alteration of gill filament and vasodilation.

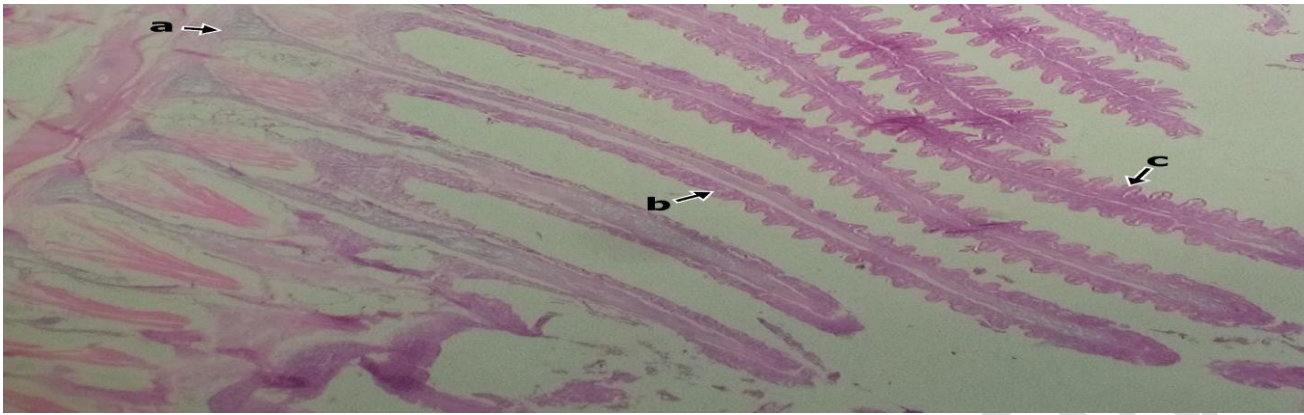


Figure 1C: Photomicrograph of the gill of *C. gariepinus* X 400 exposed to (32.1mg/l) showing severe degeneration of (a) gill filament, (b) primary (b) secondary lamellae resulting to decrease in the size of the gills and interlamellae spaces.

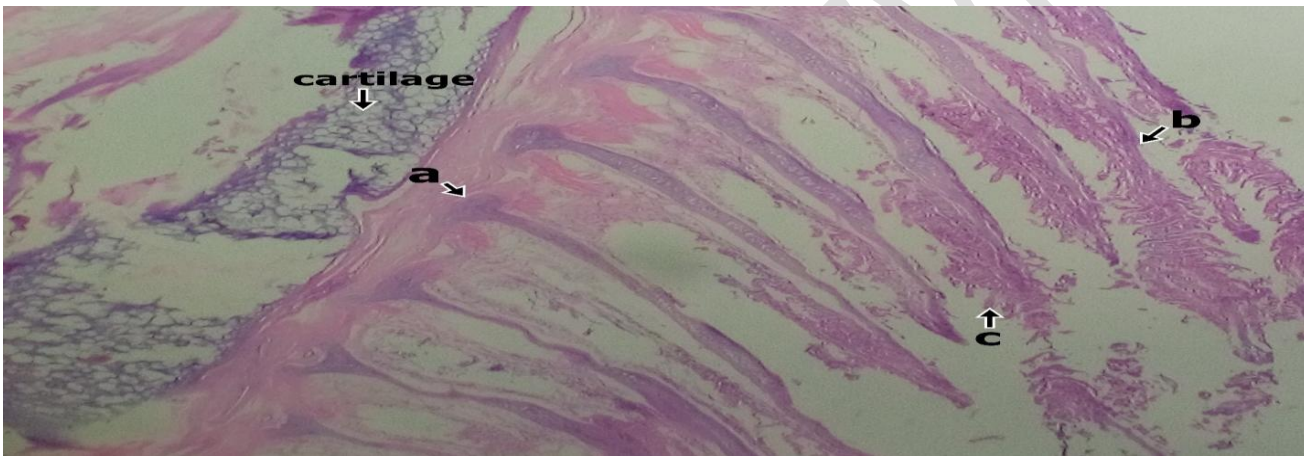


Figure 1D: Photomicrograph of the gill of *C. gariepinus* X 400 exposed to (53.5mg/l) showing complete degeneration of (a) gill filament, (b) primary (b) secondary lamellae. Cellular necrosis, epithelial hyperplasia and rupture was observed.

The result of the photomicrographs of the sections through the liver of *C. gariepinus* exposed to various concentrations of paraquat is presented in figures 2A – 2D. The control (plate 8) showed no histopathological alteration and the cells are normal and systematically arranged. It shows a typical parachymatous appearance with a polygonal hepatocytes cells. The sinusoids are thin strip with sparse connective tissues with a well-structured central veins (CV). This was an indication of active secretory nature Fig 2A. Alteration such as cellular proliferation, sinusoid enlargement, congestion of the central vein, parachymatous degeneration, vacuolar degeneration, pyknotic nucleic degeneration, legions and necrosis were observed in figures 2B - 2D. Severity depends on increasing concentration, with severe necrosis of the hepatocytes, rupture of the sinusoid and destruction of the central vein observed in fish exposed to the highest concentration (53.5mg/l).

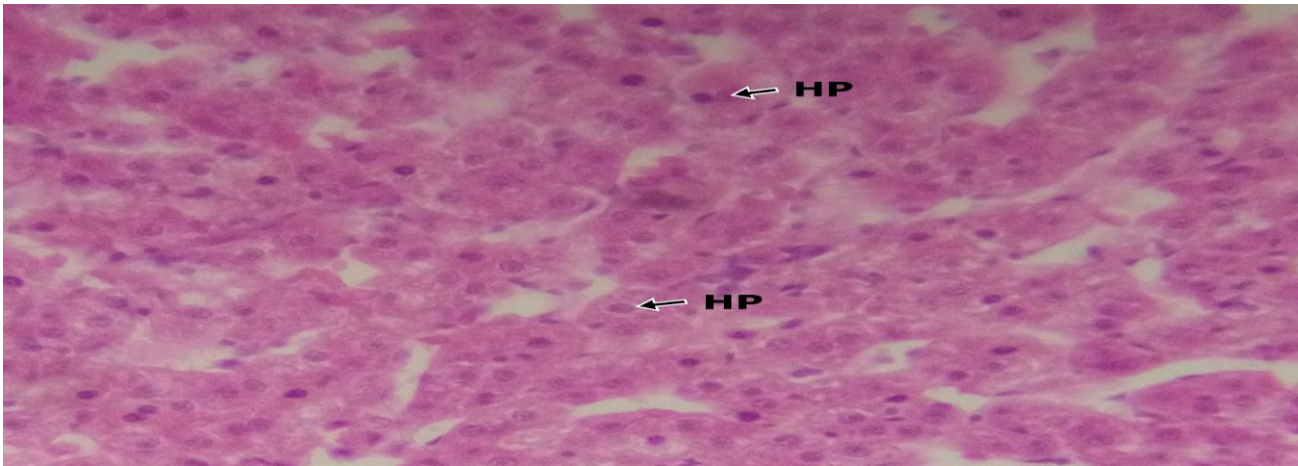


Figure 2A: Section of the liver exposed to 0.00mg/l (control) showing normal histology without any form of alteration or lesions in hepatocyte (HP).

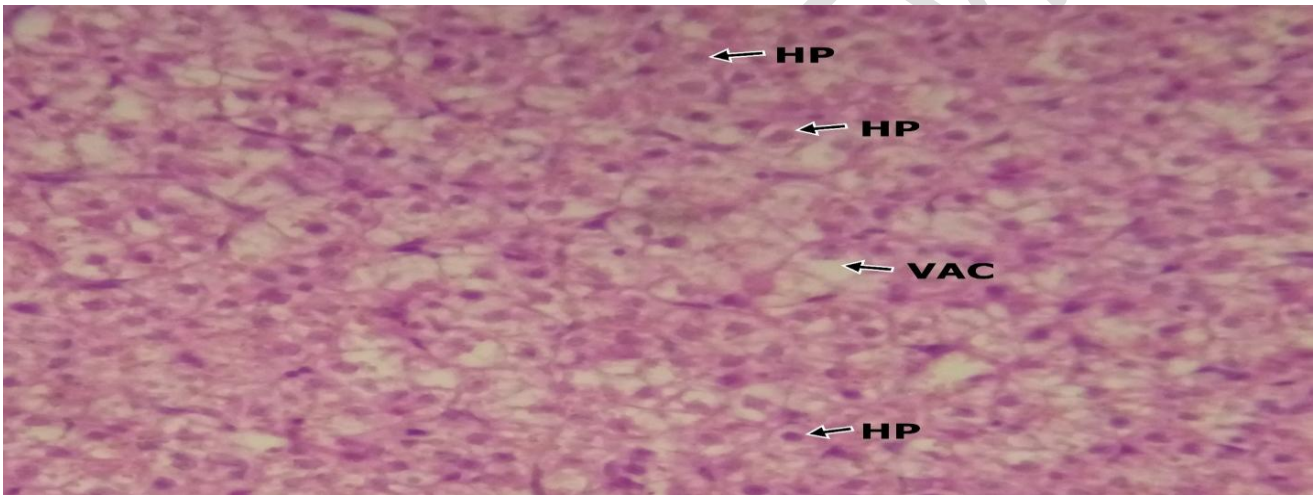


Figure 2B: Section of the liver exposed to 10.7mg/l showing commencement of cellular disarrangement with pyknotic nuclei and slight vacuolation (VAC) of hepatocyte (HP).

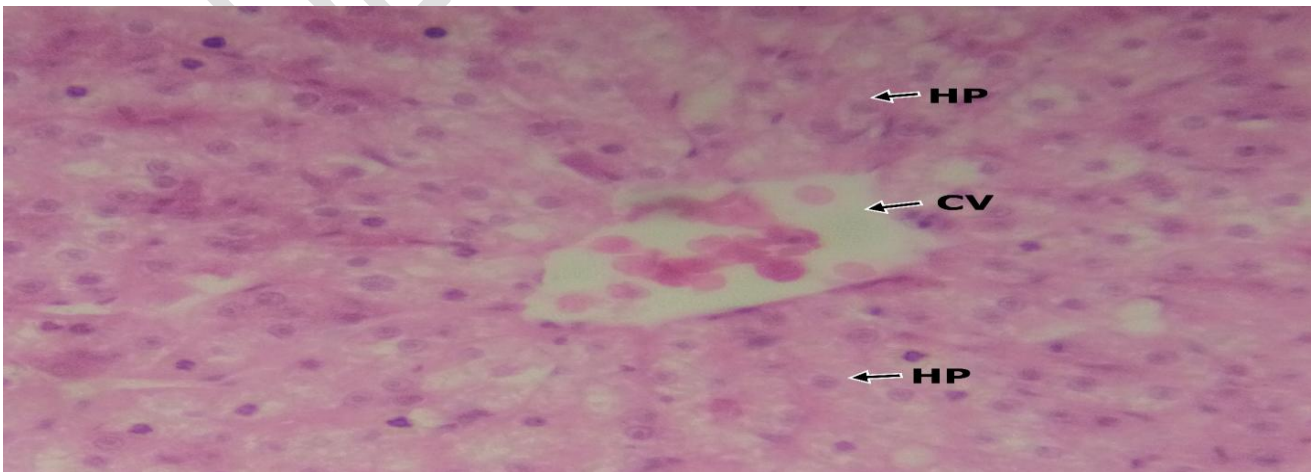


Figure 2C: Section of the liver exposed to 32.1mg/l showing moderate to severe vacuolation of the hepatocytes (HP), inflammation of the central veins (CV) and disintegration of the sinusoids.

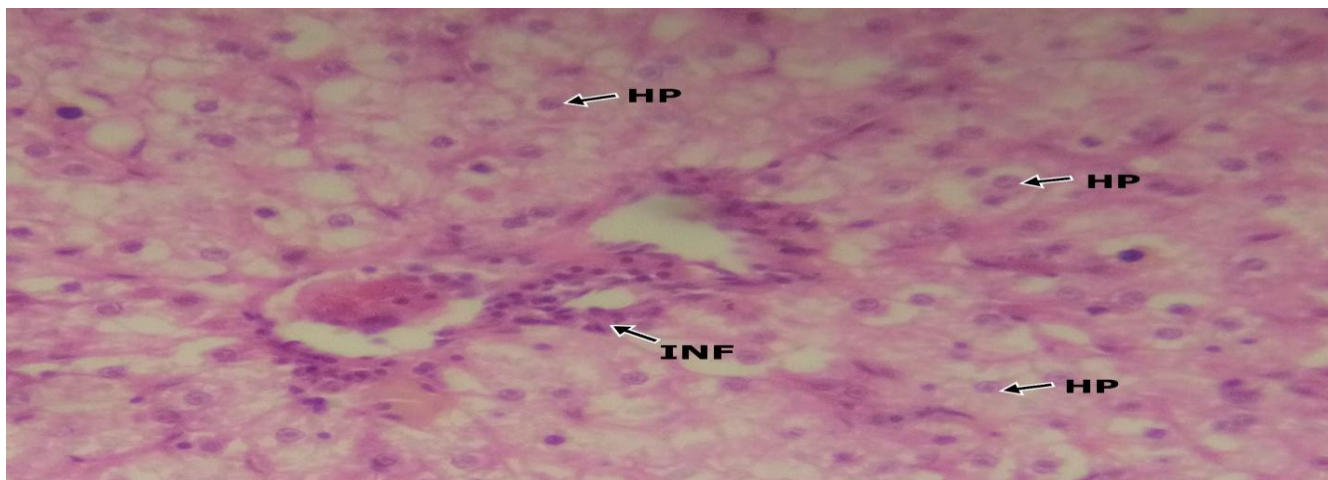


Figure 2D: Section of the liver exposed to 54.5mg/l showing severe degeneration of the central vein, (CV), vacuolation, necrosis of the hepatocytes, destruction of the sinusoids and parachymatous cells.

The result of the photomicrographs showing the sections through the skin of *C. gariepinus* exposed to various concentrations of paraquat is presented in figures 3A - 3D. Fish exposed to the control (0.0mg/l) showed normal histology of the skin consisting of well distinct epidermis and dermis. The epidermis is thick and composed of epithelial cells with a few mucous cells. The squamous epithelial cell lining the surface of the epidermis and the basement layer separating it from the dermis are intact. The dermis is less compact consisting of collagenous tissues arranged in a regular pattern (Fig. 3A). Exposure to various concentrations showed alteration in the architecture of the skin whose severity depends on the concentration. Mucous cell proliferation, erosion of the epithelial lining and hypertrophy and necrosis of cells were the major alterations observed (3B - 3D).

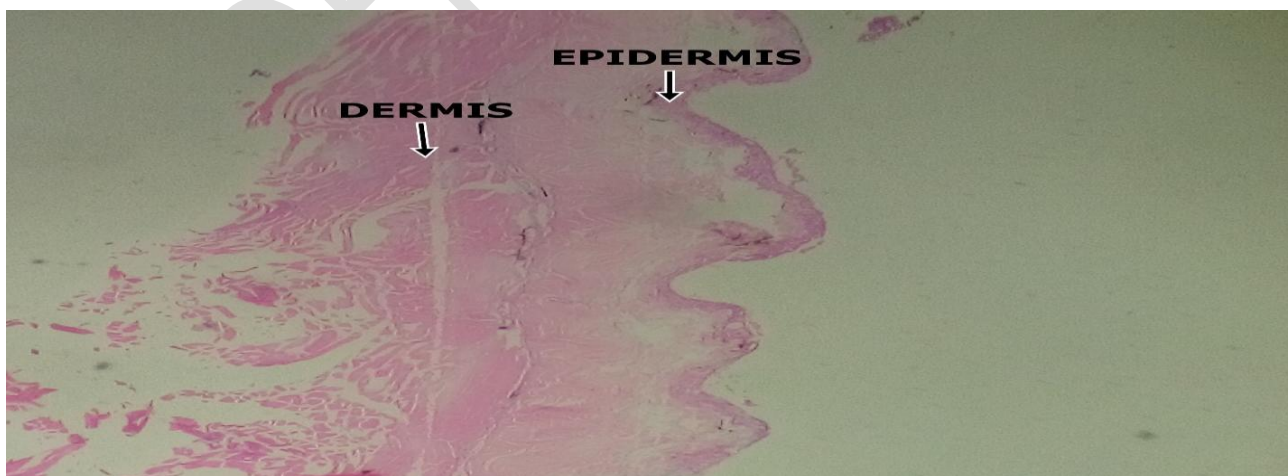

Figure 3A: Photomicrograph of the skin of *C. gariepinus* X 400 of control (0.0mg/l) showing normal histology with we structured epidermal layer, dermis, mucous cell and epithelia surface.

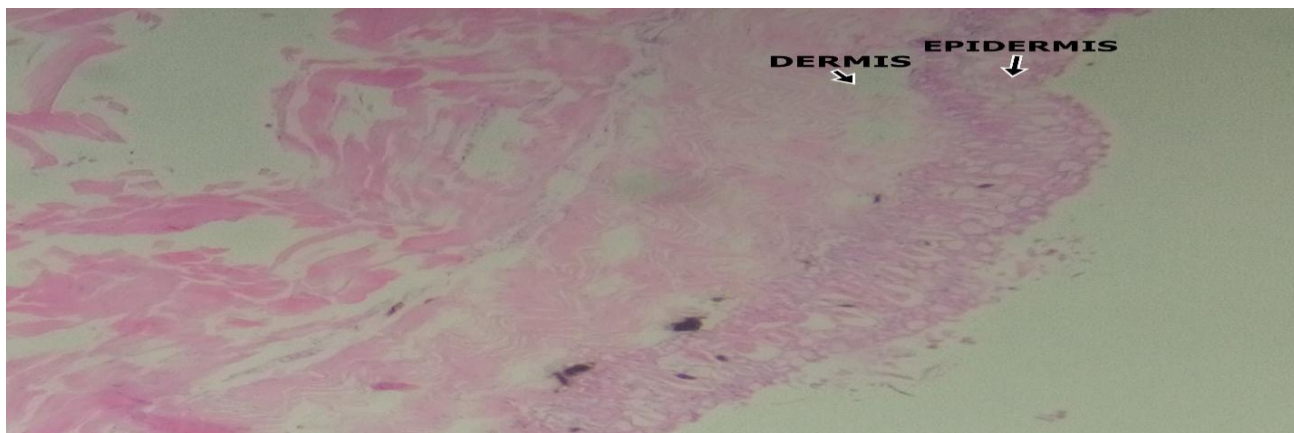


Figure 3B: Photomicrograph of the skin of *C. gariepinus* X 400 exposed to (10.7mg/l) of paraquat showing commencement of hypertrophy and proliferation of the mucous cells with slight erosion of the epidermal epithelium. Widening of the epidermal and dermal layers.

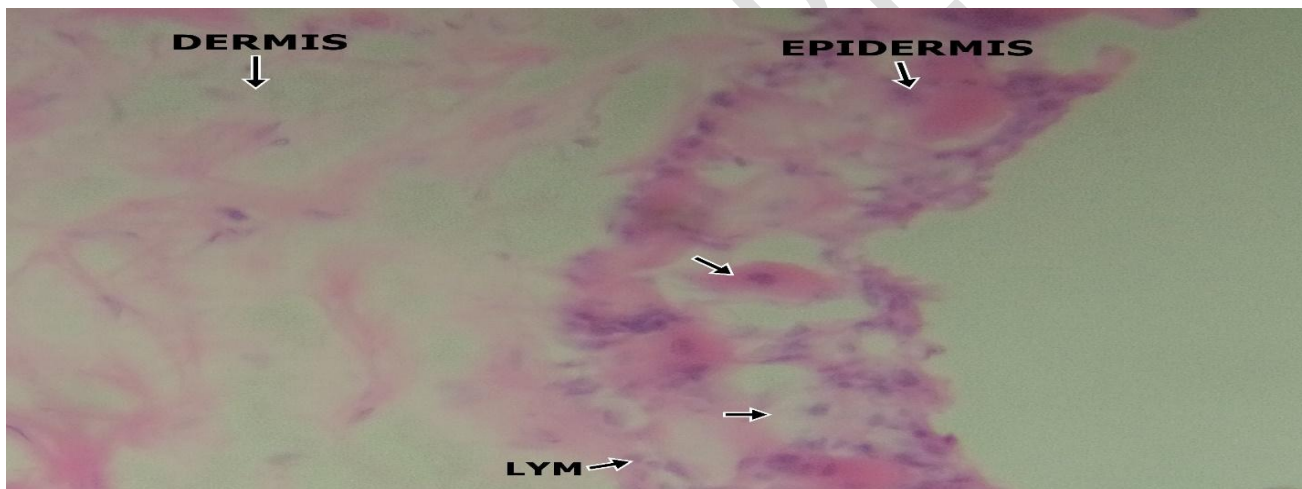


Figure 3C: Photomicrograph of the skin of *C. gariepinus* X 400 exposed to (32.1mg/l) of paraquat showing severe hypertrophy and proliferation of the mucous cells with complete erosion of the epidermal epithelium.

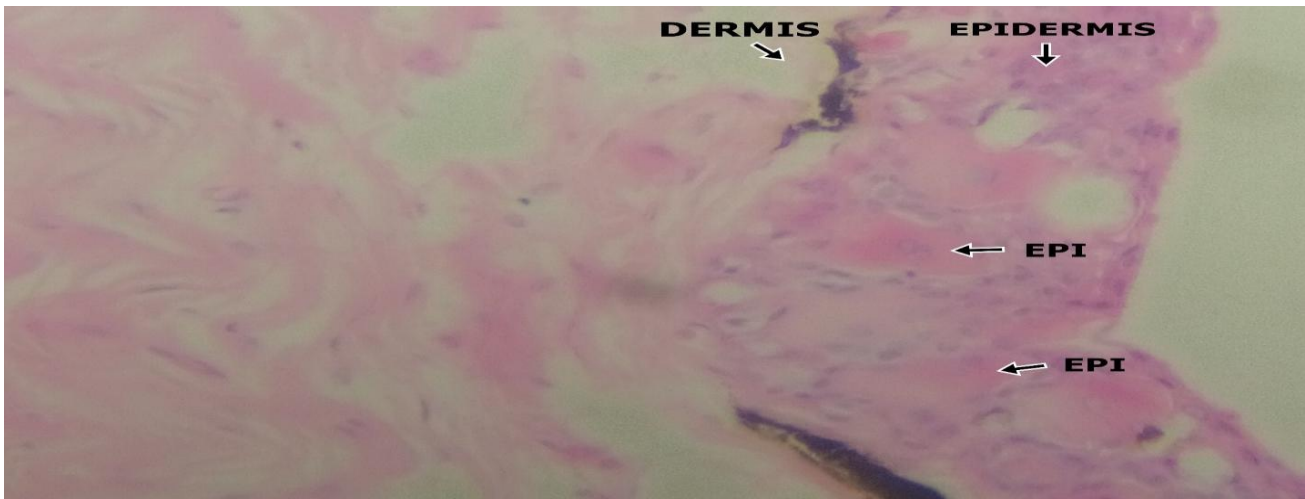


Figure 3D: Photomicrograph of the skin of *C. gariepinus* X 400 exposed to (53.5mg/l) of paraquat showing severe hypertrophy and proliferation of the mucous cells with complete erosion of the epidermal epithelium. There is also severe widening of the epidermal and dermal layers.

Discussions

Haematological parameters

Haematological parameters of fish are considered a suitable tool for evaluating the effects of pollutants [42]. Haematological studies have provided reliable information on health status, metabolic disorders and chronic stress status before and after clinic examination of specimens [43]. Cyriac *et al.* [44] have reported the changes in several haematological parameters as indicators of metal exposure. The variations in blood profiles of the fish during period of pesticide exposure suggested that there are change in oxygen carrying capacity and osmotic disturbances in fish blood. Similar changes in the blood profiles of some fishes exposed to various toxicants have been reported [24], [45], [46]. The gradual changes in the haematological parameters of *C. gariepinus* juveniles recorded in this study is an indication that paraquat has effects on the blood of the exposed fish. This study recorded a decreased in the values of RBC, Hgb, PCV, MCV, MCHC and MCH while those of WBC and Plt increased with increasing concentration of paraquat. The observation in this study was in agreement with those of Ahmad [47] who exposed *C. gariepinus* to Malathion, Hashemi *et al* [48] and Sanudi *et al* [24] on *Cyprinus carpio* exposed to paraquat and glyphosate respectively. The continuous decrease in the values of RBC of *C. gariepinus* treated with paraquat indicates an impairment of erythropoietic process. The decline in the RBCs could also be due to anaemic after exposure, which might be attributed to malfunction of RBC and haemoglobin synthesis [49]. Similar inhibition and damage in RBC and other erythrocytes indices have been reported for *Cyprinus carpio* exposed to Roundup [50]. Velisek *et al.* [51] reported a significant reduction in RBCs when rainbow trout (*Oncorhynchus mykiss*) were exposed to

verapamil. The significant reduction in the Hgb and PCV across the paraquat treated fish specimens when compared with the control in this study was in line with those reported by many other researchers [46], [45], [4]. The reduction in Hgb and PCV could be due to the adverse effect of paraquat on inhibiting the haemopoietic activity and increased breakdown of RBC membranes. Nwani *et al* [4] reported that Hgb biosynthesis when adversely affected could limit the oxygen carrying capacity of the fish blood which may culminate in sudden death. The decrease in the values of these blood parameters is an indication of immune suppression induced by the paraquat. According to Sanudi *et al*. [24], reduction in Hgb of *Cyprinus carpio* exposed to glyphosate was due to interference on chemosynthesis, destruction in blood forming system and disruption in synthesis of iron. The death of fish exposed to glyphosate resulting from continuous reduction in Hgb and PCV with increasing concentration may be due to acute anaemia and asphyxiation. Hashemi *et al* [48] reported that lower PCV values of *C. gariepinus* were attributed to anaemia resulting from shrunken red blood cells, asphyxiation and death. The red blood indices such as MCV, MCH and MCHC are important in the diagnosis of anaemia in most animals including fish. Significant increase or decrease in these indices may indicate macrocytic and microcytic anaemia [52]. The reduction in size and quantity of haemoglobin of red blood cells is measured by the indices MCV, MCH, MCHC which can be a sign of anaemia in fish [53]. The presence of a large percentage of immature red blood cells in the bloodstream may be a reason for reduction of MCV, MCH and MCHC in this study may be due to decreased production of haemoglobin after exposure to paraquat. During the anaemia, MCHC values reduced because large cells had less haemoglobin concentration [54]. Reduced MCV could be linked with shrinkage of RBCs either due to hypoxia or microcytic anaemia (shrinkage of RBCs) as earlier reported by Ogueji *et al* [55], Yaji *et al* [56] and Okey [45]. Mean cell haemoglobin concentration reduction resulted from increased production and secretion of reticulocytes that had a larger size but less haemoglobin content compared to mature red blood cells [57]. Similar observations were also previously reported in *C. gariepinus*, which was exposed to acute and sub lethal concentrations of paraquat [58]. This however differ from the studies of [45], [59] who reported increase in MCV, MCH and MCHC of African catfishes exposed to clove anaesthetics and neem extracts respectively.

The increase in the levels of WBC and Platelet (thrombocytes) observed in this study was in agreement with several researchers who have exposed fish to various herbicides [60], [2], [61], [9]. Platelets are one of the indispensable component of blood playing major role in clotting of blood by absorbing various factors for blood clotting and delivering them to the site of injury of hemorrhage [62]. According to Ndimele *et al* [61], WBC and platelets increased in *Clarias gariepinus* as a result of acute exposure to Endosulfan. White blood cells have been reported to be involved in immune function regulation in many organisms [4]. Significant increase in the values of WBC with a corresponding increase in concentration of paraquat recorded in this study agrees with the findings of Ogueji *et al*. [46] and Saravanan *et al*. [50]. This increase infers an immune system response to the toxic effect of paraquat. The increase can also be attributed to increase in the production

of leucocytes in haematopoietic tissues. According to Kori-Siakpere *et al.* [58], high WBC count means a release of more cells to maintain homeostasis while low WBC count is a common stress response. Therefore, increasing or decreasing numbers of WBCs are normal physiological reactions to toxicants and these show the response of the immune system under toxic conditions. Khan *et al* [60] stated that higher WBC counts has implication in immune responses and the ability of the animal to fight infection. Measurable increase in the WBC of fish is a function of immunity response to vulnerable illness and disease [47]. The increase in WBC and Plt reported in this study agreed with the report of Olufayo and Adeyanju [59] who worked on the haematological effects of neem leaves (*Azadirachta indica*) on *H. bidorsalis* and Akinrotimi *et al.* [63] who worked on the blood of *C. gariepinus* exposed at clove seed anaesthetic. This increase may be as a result of the physiological reaction inform of defense mechanism to the stress induced by the toxicant to counter the effects on the increasing concentration of the herbicide and also self-mechanism against the destruction of blood cells.

Histopathological responses

The histopathological examination of the gill, liver and skin of *C. gariepinus* to paraquat indicated that the gills and skin were the organ most affected. Damages of the gills indicated that the lethal concentrations of paraquat caused impairment in gaseous exchange efficiency of the gills this was similar to the observation of Rahman *et al* [64], [65]. The observed effects of moderate to severe epithelial proliferation, fusion of lamellae, vacuolation, blood congestion, malignancy and hyperplasia of the gill filament in this study agrees with those of several researchers who investigated the effects of herbicide on fishes [60], [66], [67], [68]. Ladipo *et al* [12] reported no to moderate areas of lesion, necrosis, malignancy, pigment and inclusion bodies with no obvious cellular abnormalities and inflammation in gills and liver of *C. gareipinus* juveniles exposed to 20 – 80mg/l of paraquat dichloride herbicide. This study observed a more severe effects of damage to the gills than earlier reported by Ladipo *et al* [12] with much lower concentrations (10.7 – 53.5mg/l) of paraquat. Omitoyin *et al* [1] observed major effects of herbicide on the gills of *C. gariepinus* to include oedema, epithelial lifting, and thickening of the primary lamellar epithelium and fusion of secondary lamellae.

Damages of the gills indicated that impairment in gaseous exchange efficiency of the gills Oedematous of the lamella and hyperplasia were observed and this is similar to the observation of Omoniyi *et al* [69]. The early fusion of secondary lamellae due proliferation of mucous and epithelial cells and was considered a defense response to insecticide exposure rather than a direct effect of the toxicants. This is because mucous cells contain mucins, polyanions composed of glycoproteins that can be effective in trapping toxicants and aid in the prevention of toxicant entry into the gill epithelium [70]. Epithelial lifting and hyperplasia lowered the rate of gaseous exchange due to its natural mechanism to increase the pollutant-blood diffuse distance [71], along with necrosis and excessive mucus secretion, oxygen deficiency occurred. Ayoola [9] had earlier reported filament cell proliferation, lamellar fusion, lamellar cell hyperplasia and epithelial lifting in *C. gariepinus*

juveniles exposed to glyphosate. The major effects observed on the gills were Oedema, epithelial lifting, and thickening of the primary lamellar epithelium and fusion of secondary lamellae.

The skin and the gills, which constitute the external boundary tissue of the fish, are normally not keratinized and covered by a layer of slimy mucous [72] but the amount of the mucous secreted is usually much more when these tissues are challenged. In this study the observed proliferation and hypertrophy of the mucous cells, erosion of the epithelial lining and widening of the epidermal and dermal layers agrees with the findings of Abalaka *et al* [73] on *C. gariepinus* exposed to *Adenium obesum* extract, Chandra and Banerjee, [74] on *C. batrachus* exposed to Sodium arsenate. The observed proliferated mucous cells within the skin of the affected fish were for the continuous secretion of mucous, which helps to protect and clean up these respiratory surfaces in facilitating the removal of trapped toxicants from them [74]. The protective role of increased mucous secretion reduce due to the rapid exhaustion of the mucous cells with the extensive loss of mucous following prolonged exposure, resulting to the erosion of the superficial cells of the skin of the exposed fish [74] as observed in this study. Das and Mukherjee, [75] reported that continuous exposure of these respiratory surfaces (skin and gill) to toxicants resulted in the observed erosion of the epithelial lining and widening of the epidermal and dermal layers in *Labeo rohito* exposed to hexachlorocyclohexane.

Liver is one of the vital organs in the body that plays a major role in carbohydrates, proteins and fats metabolism. According to Hinton and Laurant [76] the liver is the main detoxification center of the body which is carried out by the hepatocytes, and alteration in liver cells is the main indicator of toxic environment. In this study the liver of the exposed fish showed vacuolation and hyperplasia of hepatocytes, necrosis, blood congestion, pyknosis and parachymatous degeneration with mild lesions on fish treated with 53.5mg/l of paraquat for 30 days. Similar findings were reported in *C. gariepinus* [9] *Clarias gariepinus* [30] and *Trichogaster trichopterus* [77] where the lesions in liver started to develop lower than 2 mg/L of paraquat. The liver of the exposed fish had vacuolated cells showing evidence of fatty degeneration. Necrosis of some portions of the liver tissue that were observed probably resulted from the excessive work required by the fish to get rid of the toxicant from its body during the process of detoxification and similar to the observation of Rahman *et al* [64]. The inability of the fish to regenerate new liver cells may also have led to necrosis. Multiple pyknosis and necrosis of hepatocytes were observed in exposed liver, thus preventing detoxification and inability to generate new cells [9]. Nwani *et al* [68] reported vacuolar degeneration of hepatocytes and disintegration of the sinusoids in the liver of *C. gariepinus* juveniles exposed paraquat dichloride. Necrosis of some portions of the liver tissue that were observed probably resulted from the excessive work required by the fish to get rid of the toxicant from its body during the process of detoxification by the liver. The inability of fish to regenerate new liver cells may also have led to necrosis. These vacuolar degeneration and necrosis of the hepatocytes were in agreement with Cengiz [78], Mishra and Mohanty [79] and Rahman *et al.*, [64] with

the exposure of deltamethrin, chromium and diazinon. The findings in this study shows that paraquat is toxic to *C. gariepinus* and causes histopathological changes in fish organs. Accumulation of most of the pesticides and their byproducts in hepatocytes results in significant histopathological modification and variation in liver [80].

Conclusion

The toxic effects of paraquat on the haematological and histopathology of gills, skin and liver of *C. gariepinus* was investigated. The study was useful to predict possible effects of now frequently and extensively used herbicides on the aquatic life. The study revealed a significant increase in WBC and Plts values, while those of RBC, Hgb, PCV, MCV, MCH and MCHC all decreased with increasing concentration of paraquat. Alterations were observed in the tissues investigated with the gills and skin most affected. The study revealed that paraquat was toxic to *C. gariepinus* and causes some haematological and histopathological alterations in the fish tissues. Therefore, indiscriminate use of paraquat by farmers should be discouraged particular in area close to aquatic environment.

COMPETING INTERESTS DISCLAIMER:

Authors have declared that no competing interests exist. The products used for this research are commonly and predominantly use products in our area of research and country. There is absolutely no conflict of interest between the authors and producers of the products because we do not intend to use these products as an avenue for any litigation but for the advancement of knowledge. Also, the research was not funded by the producing company rather it was funded by personal efforts of the authors.

References

1. Omitoyin, B.O., Ajani, E.K., Adesina, B.T. and Okuagu, C.N.F. (2006). Toxicity of Lindane (Gamma Hexachloro-CycloHexane) to *Clarias gariepinus* (Burchell 1822). World Journal of Zoology, vol. 1, no. 1, pp. 57-63.
2. Al-Otaibi, A. M., Al-Balawia, H. F. A., Ahmada, Z. and Sulimana, E. M. (2019). Toxicity bioassay and sub-lethal effects of diazinon on blood profile and histology of liver, gills and kidney of catfish, *Clarias gariepinus*. Braz. J. Biol. 79(2): 326-336
3. Akhtar MH (1986). The disposition of 14C agrochemical residues in plant and animal tissues when consumed by animals. In: Green halgh, T. and Roberts, T. R., (eds). Pesticide Science and biotechnology. Proceedings of the 6 th international congress of pesticide chemistry Ottawa, Canada, August 1986, pp.10-15.

4. Nwani, C.D., Ekwueme, H.I., Ejere, V.C., Onyeke, C.I., Chukwuka, C.O., Somdare, P.O. and Nwadinigwe, A.O. (2015). Physiological effects of paraquat in Juvenile African catfish *Clarias gariepinus* (Burchell, 1882). *Journal of Coastal Life Medicine*, 3(1):35-43. [http:// doi.org 10.12980/JCLM.3.2015JCLM-2014-0113](http://doi.org/10.12980/JCLM.3.2015JCLM-2014-0113), (2015)
5. Solomon, K.R., K. Dalhoff, D. Volz and G. van der Kraak, 2013. Effects of herbicides on fish. *Fish Physiol.*, 33: 369-409.
6. Malik A, Ojha P, Singh K. 2008. Levels and distribution of persistent organic pesticide residue in water and sediments of Gomti River (India): a tributary of the Ganges River. *Environmental Monitoring and Assessment*. 148(1-4):421–435.
7. Okey, I. B., Ayotunde, E. O. and Patrick, B. U. (2021). Behavioural Responses and Mortality of *Clarias gariepinus* Juveniles Exposed to Acute Concentrations of Paraquat. *Sumerianz Journal of Agriculture and Veterinary*, 4(2):49-54
8. Annett R, Habibi HR, Hontela A. 2014. Impact of glyphosate and glyphosate-based herbicides on the freshwater environment. *Journal of Applied Toxicology*. 34(5):458–479.
9. Ayoola S.O. (2008). Histopathological effects of glyphosate on juvenile African catfish (*Claria gariepinus*). *Am. Env. J. Agric. Environ. Sci.* 4:362-367.
10. Olurin, K., Olojo, E., Mbaka, G. and Akindele, A.(2006). Histopathological responses of the gill and liver tissue of *Clarias gariepinus* fingerlings to the herbicide, glyphosate. *Afr. J. Biotechnol.* 5, 2480–2487. Cataldi, E., S. Cataudella, G. Monaco, A. Rossi and L. Tancioni. 1987. A study of the histology and morphology of the digestive tract of the sea bream *Sparus aurata*. *J. Fish Biol.* 30(2): 135-145.
11. Nwamba, H. O., Achikanu, C. E., and Chukwu, G. P., 2018. "The impact of dichlorvos -pesticide on African catfish *Clarias gariepinus*." *Oceanogr Fish Open Access J.*, vol. 8, p. 555745.
12. Ladipo M. K., Doherty V. F. and Oyebadejo S. A. (2011). Acute Toxicity, Behavioural Changes and Histopathological Effect of Paraquat Dichloride on Tissues of Catfish (*Clarias gariepinus*). *International Journal of Biology* Vol. 3, No. 2; April 2011
13. Gluszcak L, Loro VL, Preto A, Moraes BS, Raabe A, Duarte MF, da Fonseca MB, de Menezes CC, de Sousa Valladao DM. 2011. Acute exposure to glyphosate herbicide affects oxidative parameters in Piava (*Leporinus obtusidens*). *Archives of Environmental Contamination and Toxicology*. 61:624–630.
14. Gao R, Choi N, Chang SI, Kang SH, Song JM, Cho SI, Lim DW, Choo J. 2010. Highly sensitive trace analysis of paraquat using a surface-enhanced Raman scattering microdroplet sensor. *Analytical Chimica Acta*. 681:87–91.
15. Ismail BS, Sameni M, Halimah M. 2011. Evaluation of herbicide pollution in the Kerian Ricefields of Perak Malaysia. *World Applied Science Journal*. 15(1):5–13.
16. Chia, L.S., McRae, D.G. and Thompson, J.E. (1982). Light-dependence of paraquat- initiated membrane deterioration in bean plants. Evidence for the involvement of superoxide. *Plant Physiology*. 56: 492-499.
17. Kenneth, A.H. (1990). *The Biochemistry and Uses of Pesticides*, 2nd Edition, Wiley-Blackwell publishing, U.S.A, pp. 10-11.
18. Ogomba, E.N., I.R. Inyan and I.K. Azuma, 2011. Effect Paraquate Dichloride on some Metabolic and Enzyme Parameters of *Clarias gariepinus*. *Current Res. J. Biol Sci.*, 3: 186-190.

19. FAO, Food and Agricultural Organisation. (2000). The state of world fisheries and aquaculture. FAO/WHO. Residues in food. Report of Joint FAO/WHO food standards programme, Vol. 2B. Rome: FAO; p. 61–81.
20. Babatunde, M.M. and Oladimeji, A., A. (2014). Effect of paraquat on weight and behavior of *Oreochromis niloticus*. Environmental Research Journal. 8(2):44-47.
21. Seiyaboh, E.I., Inyang, I.R., Gijo, A.H. and Adobeni, G.D. (2013). Acute Toxicity of Paraquat Dichloride on Blood Plasma Indices of *Clarias gariepinus*. Journal of Environmental Science, Toxicology and Food Technology. Vol: 7 (6): PP 15-17.
22. Doherty V. F., Ladipo M. K., and Oyebadejo S. A. (2011). Acute Toxicity, Behavioural Changes and Histopathological Effect of Paraquat Dichloride on Tissues of Catfish (*Clarias Gariepinus*). International Journal of Biology. Vol. 3, No. 2.
23. Amir, T., Jafar, R., Vahid, N. and Najmeh, S. (2014). Effect of acute and chronic toxicity of paraquat on immune system and growth performance in rainbow trout, *Oncorhynchus mykiss*. Aquaculture Research. 45: 1737–1743.
24. Sanudi, F., Indulkar, S. and Mzengereza, K. (2020). Impact of Glyphosate Herbicide on Haematological Parameters of Koi Carp, *Cyprinus carpio* (Linnaeus, 1758) Fingerlings. J. Fish. Aquat. Sci., 15: 7-11.
25. Dethloff, G.M., Bailey, H.C. And Maier, K.J. (2001). Effect of dissolved copper on selected haematological, biochemical and immunological parameters of wild rainbow trout (*Oncorhynchus mykiss*). Archives of Environmental Contamination and Toxicology, vol. 40, no. 3, pp. 371-380. <http://dx.doi.org/10.1007/s002440010185>. PMID: 11443368.
26. Chen, M.F. and M.E. Kumlin. 1989. Enteric septicemia of channel catfish in California. California fish and Game. 75: 141-147.
27. Williams, J.A. and B.B. Nickol. 1989. Histological structure of the intestine and pyloric caeca of the green sunfish, *Lepomis cyanellus* Rafinesque. J. Fish. Biol. 35: 359-372.
28. Srivastava, V.M.S., R.S. Tripathi and A.K. Saxena. (1982). Chromium induced histopathological changes in fishes of *Puntius sophore* (Hamilton). J. Biol. Res. 2: 67-68.
29. Adebayo, I.A., Akin-Obasola, B.J. And Bajulaye, O.M. (2013). Toxicological effect of diazinon on African catfish (*Clarias anguillaris*). IOSR Journal of Environmental Science. Toxicology and Food Technology, vol. 3, no. 1, pp. 64-71. [http:// dx.doi.org/10.9790/2402-0316471](http://dx.doi.org/10.9790/2402-0316471)
30. Ayoola, S.O. And Ajani, E.K., (2008). Histopathological effects of cypermethrin on juvenile African catfish (*Clarias gariepinus*). World Journal of Biological Research, vol. 1, pp. 1-14.
31. Ikele, C.B., Mgbenka, B.O. And Oluah, N.S. (2011). Histopathological effects of diethyl phthalate on *Clarias gariepinus* juveniles. Animal Research International, vol. 8, no. 3, pp. 1431-1438
32. Ogueji, E. O., Ibrahim, B.U. and Auta, J. (2013). Histopathology of liver and gill of *Clarias gariepinus* (Burchell 1822) with swollen abdomen following exposure to acute and sub lethal concentrations of chlorpyrifos-ethyl. International Journal of Basic and Applied Sciences, 2 (3) (2013) 223-229
33. Nowak B (1992). Histological changes in gills induced by residues of endosulfan. Aquat Toxicol 23.63-8.
34. Olojo, E.A.A., Olurin, K.B., Mbaka, G and Oluwemimo, A.D. Histopathology of the gill and liver tissues of the African catfish *Clarias gariepinus* exposed to lead. African Journal of Biotechnology 4(1): (2005) 117-122.

35. Reish, D.L. and Oshida, P.S (1987). Manual of methods in aquatic environment research, Part 10: short-term static bioassays. Rome: Food and Agriculture Organization of the United Nations: p. 62.
36. Ochei J O, Kolhatkar A A, (2003). Medical Laboratory Science: Theory and practice. Tata McCraw – Hill publishing company limited 7 west Patel Nagar, New Delhi, India
37. Blaker, F. J and Silverton, R. E (1985). Introduction to Medical Laboratory Technology. Sixth edition. Robert Hartnoll LTD, Bodmin, Cornwall
38. Lee RG, Foerster J, Jukens J, Paraskevas F, Greer JP, Rodgers GM, (1998). Wintrobe's-Clinical Hematology. Tenth Edn, Lippincott Williams and Wilkins, New York, USA.
39. Bernet D, Schmidt H, Meir W, Burkhardt-Holm P, Wahli T (1999). Histopathology in fish: proposal for a protocol to assess aquatic pollution. Journal of Fish Diseases 22:25-34.
40. Bancroft, J.D., Cook, H.C., 1994. Manual of Histological Techniques and Their Diagnostic Application. Churchill Livingstone, London, pp. 289–305.
41. Wahua, T. A.T. (1999). *Applied statistics for scientific studies*. Afrika Link Books. Aba, Nigeria
42. Roche, H. and Boge, G., (1996). Fish blood parameters as a potential tool for identification of stress caused by environmental factors and chemical intoxication. Marine Environmental Research, vol. 41, no. 1, pp. 27-43. [http://dx.doi.org/10.1016/0141-1136\(95\)00015-1](http://dx.doi.org/10.1016/0141-1136(95)00015-1)
43. Bahmani, M., Kazemi, R. and Donskaya, P. (2001) A Comparative Study of Some Hematological Features in Young Reared Sturgeon. Fish Physiology and Biochemistry, 24, 135-140. <https://doi.org/10.1023/A:1011911019155>
44. Cyriac, P.J., Antony, A. and Nambisan, P.N. (1989). Hemoglobin and hematocrit values in the fish *Oreochromis mossambicus* (Peters) after short term exposure to copper and mercury. Bulletin of Environmental Contamination and Toxicology, vol. 43, no. 2, pp. 315-320. <http://dx.doi.org/10.1007/BF01701764>. PMID: 2775899.
45. Okey, IB (2019). Anaesthetic Effects of clove (*Eugenia caryophyllata*) on Some Haematological and Biochemical Parameters of *Heterobranchus bidorsalis* Juveniles. Journal of Agriculture and Aquaculture, 1(1): 1 – 14
46. Ogueji, E.O., Iheanacho, S.C., Nwani, C.D., Mbah, C.E., Okeke, O.C. and Ibrahim, B.U. (2017). Toxicity of diazepam on lipid peroxidation, biochemical and oxidative stress indicators on liver and gill tissues of African catfish *Clarias gariepinus* (Burchell, 1822), International Journal of Fisheries and Aquatic Studies, 5(3): 114-123.
47. Ahmad, Z., (2012). Toxicity bioassay and effects of sub lethal exposure of malathion on biochemical composition and haematological parameters of *Clarias gariepinus*. African Journal of Biotechnology, vol. 11, pp. 8578-8585.
48. Hashemi, R.A., Jaddi, Y., Sadeghi, M.A., Ghiamati, S. and Motazedi, M. (2017) Study of Toxicology Effects of Herbicide Paraquat on Hematological Parameters of Mesopotamichthys sharpeyi. Open Journal of Marine Science, 7, 258-270. <https://doi.org/10.4236/ojms.2017.72018>
49. Jenkins, F., J. Smith, B. Rajanna, U. Shameem, K. Umadevi, V. Sandhya and R. Madhavi, (2003). Effect of sub-lethal concentrations of endosulfan on hematological and serum biochemical parameters in the carp *Cyprinus carpio*. Bull. Environ. Contam. Toxicol., 70: 993-997.
50. Saravanan, M., Kumar, K.P. and Ramesh, M. (2011). Haematological and biochemical responses of freshwater teleost fish *Cyprinus carpio* (Actinopterygii: Cypriniformes) during acute and chronic sublethal exposure to lindane. Pesticides Biochemistry and Physiology, 100: 206-211.

51. Velisek, J., Wlasow, T., Gomulka, P., Svobodova, Z., Dobsikova, R., Novotny, L. and Dudzik, M. 2006. Effects of cypermethrin on rainbow trout (*Oncorhynchus mykiss*). *Veter. Med.* 51: 469–476
52. Dacie, J.V., Lewis, S.M., “Practical hematology”. 11th edition, New York: Churchill Livingstone, pp 41, (2011)
53. Koprucu, S.S., Koprucu, K., Ural, M.S., Ispir, U. and Pala, M. (2006) Acute Toxicity of Organophosphorous Pesticide Diazinon and Its Effects on Behavior and Some Hematological Parameters of Fingerling European Catfish (*Silurus glanis* L.). *Pesticide Biochemistry and Physiology*, 86, 99-105.
54. Okomoda, V., G. Ataguba and V. Ayuba, (2013). Hematological response of *Clarias gariepinus* fingerlings exposed to acute concentrations of Sunsate®. *J. Stress Physiol. Biochem.*, 9: 271–278
55. Ogueji, E.O., Nwani, C.D., Iheanacho, S.C, Mbah, C.E., Okeke, C.O., Yaji, A. (2018). Acute toxicity effects of ibuprofen on behaviour and haematological parameters of African catfish *Clarias gariepinus* (Burchell, 1822)”, *African Journal of Aquatic Science*, 43(3): 293-303, <http://dx.doi.org/10.2989/16085914.2018.1465393>, (2018)
56. Yaji, A.J., Iheanacho, S.C. and Ogueji, E.O. (2018). Haematology and biochemical responses in *Oreochromis niloticus* exposed to sub-acute doses of Aronil in a flow through bioassay. *Egyptian Journal of Aquatic Biology and Fisheries*, 22(3): 89-98, <http://dx.doi.org/10.21608/ejabf.2018.8770>, (2018)
57. Lermen, C.L., Lappe, R., Crestani, M., Vieira, V.P., Gioda, C.R., Schetinger, M.R.C., Baldisseretto, B., Moraes, G. and Morsch, V.M. (2004) Effect of Different Temperature Regimes on Metabolic and Blood Parameters of Silver Catfish *Rhamdia quelen*. *Aquaculture Research*, 239, 497-507.
58. Kori-Siakpere, O., Adamu, K.M. and Madukelum, I.T. (2007) Acute Haematological Effect of Sublethal of Paraquat on the African Catfish, *Clarias gariepinus* (Osteichthyes: Clariidae). *Research Journal of Environmental Sciences*, 1, 331-335. <https://doi.org/10.3923/rjes.2007.331.335>
59. Olufayo MO and Adeyanju A A, (2012). Haematological effect of sub-lethal concentration of Neem leaves (*Azadiracthta indica*) on *Heterobranchus bidorsalis*. *Forest Product Journal* 5:37-41.
60. Khan, N., S. Tabassam, M.S. Ahmad, F. Norouz, A. Ahmad, S. Ghayyur, A.U. Rehman and M.F. Khan (2018). Effects of sub-lethal concentration of cypermethrin on histopathological and hematological profile of rohu (*Labeo rohita*) during acute toxicity. *Int. J. Agric. Biol.*, 20: 601–60
61. Ndimele, P., A. Jenyo-Oni, C. Kumolu-Johnson, K. Chukwuka and S. Onuoha, 2015. Effects of Acute Exposure to Endosulfan (Organochlorine Pesticides) on Hematology of African Mud Catfish, *Clarias gariepinus*. *Bull. Environ. Contam. Toxicol.*, 95: 164–170
62. Singh, N.N. and A.K. Srivastava, (1981). Effects of endosulfan on fish carbohydrate metabolism. *Ecotoxicol. Environ. Safety*, 5: 412–417
63. Akinrotimi OA, Gabriel UU, Deekae SN, (2014). Anaesthetic efficacy of sodium bicarbonate and its effects on the blood parameters of African catfish *Clarias gariepinus* (Burchell, 1822). *Journal of Aquatic sciences* 29: 233-246.
64. Rahman MZ, Hossain Z, Mullah MFR, Ahmed GU (2002). Effect of Diazinon 60EC on *Anabus testudineus*, *Channa punctatus* and *Barbades gomnotus*. *NAGA. The ICLARM Quarterly*, 25: 8-11.
65. Aguigwo, J.N., 2002. The Toxic Effect of Cymbush Pesticide on growth and survival of African catfish, *Clarias gariepinus* (Burchell 182 2). *Journal of Aquatic Sciences*, vol. 17, no. 2, pp. 81-84. <http://dx.doi.org/10.4314/jas.v17i2.19916>.

66. Ogunwole, G. A., Uju, S. and Saliu, J. K (2018). Paraquat Toxicity on Selected Biomarkers in *Clarias gariepinus*. Journal of Environmental Science, Toxicology and Food Technology (IOSR-JESTFT) 12 (5): 66-75
67. Hassan M, Shah Norhan NA, Shah Norhan H, Karim NU. (2015) Behavioral and Histopathological Changes of Common Carp (*Cyprinus carpio*) Exposed to Paraquat. J Fisheries Livest Prod 3: 131. doi: 10.4172/2332- 2608.1000131. Gartner LP, Hiatt JL (2013) Color Atlas and Text of Histology. Lippincott Williams and Wilkins.
68. Nwani, C.D, Somdare P.O, Ukonze, J.A, Ejere, V.C, Nwadinigwe, A.O, Nwani, J.C, Odo, G.E, Ugbor, O.N. (2016) Subchronic exposure to fenthion induces haematological changes in liver tissue of African catfish *Clarias gariepinus*, Journal of Aquatic Animal Health, 28 (4): 229-234. <http://dx.doi.org/10.1030108997659.2016.1194907>, (2016).
69. Omoniyi I, Agbon AO, Sodunke SA, (2002). Effect of lethal and sub-lethal concentrations of Tobacco (*Nicotiana tobaccum*) leaf dust extract on weight and haematological changes in *Clarias gariepinus* (Burchell). Journal of Applied Science and Environmental Management, 6, 37- 41.
70. Perry, S.F. and Laurent, P. Environmental effects on fish gill structure and function. In: eds. J.C Rankin, F.B Jesen, Fish Ecophysiology, Chapman and Hall. London: (1993) pp 231-264.
71. Karan V, Vitorovic S, Tutundzic V, Poleksic V (1998). Functional enzymes activity and gill histology of carp after copper sulfate exposure and recovery. Ecotoxicology and Environmental Safety 40, 49-55
72. El-Sayyad, H., Zaki, V.H., El-Shebly, A.M. and El-Badry, D.A., (2010). Studies on the effects of bacterial diseases on skin and gill structure of *Clarias gariepinus* in Dakahlia Province, Egypt. Ann. Biol. Res. 1 (4), 106–118.
73. Abalaka, S. E., Fatihu, M. Y., Ibrahim, N. D. and Ambali, S. F. (2015). Gills and skin histopathological evaluation in African sharptooth catfish, *Clarias gariepinus* exposed to ethanol extract of *Adenium obesum* stem bark. Egyptian Journal of Aquatic Research. 41: 119 – 127.
74. Chandra, S. and Banerjee, T.K., (2004). Histopathological analysis of the respiratory organs of *Channa striata* subjected to air exposures. Vet. Arhiv 74 (1), 37–52.
75. Das, B.K. and S.C. Mukherjee, (2003). Toxicity of cypermethrin in *Labeo rohita* fingerlings: biochemical, enzymatic and haematological consequences. Comparative Biochem. Physiol. Part C: Pharmacol. Toxicol., 134: 109–121
76. Hinton, D.E, and Lauren, D.J. (1990). Liver structural alterations accompanying chronic toxicity in fishes: potential biomarkers of exposure. In: Biomarkers of Environmental Contaminations (edited by J. F. McCarthy and L. R. Shugart), pp. 17-57. Lewis Publisher, Boca Raton, Florida.
77. Banaee, M., Davoodi, M.H. and Zoheiri, F. (2013). Histopathological changes induced by Paraquat on some tissues of gourami fish (*Trichogaster trichopterus*). Open Vet J. 3: 36-42.
78. Cengiz, E.I. and E. Unlu, 2006. Sublethal effects of commercial deltamethrin on the structure of the gill, liver and gut tissues of mosquitofish, *Gambusia affinis*: a microscopic study. Environ. Toxicol. Pharmacol., 21: 246–253
79. Mishra AK, and Mohanty B (2008) Acute toxicity impacts of hexavalent chromium on behavior and histopathology of gill, kidney and liver of the freshwater fish, *Channa punctatus* (Bloch). Environmental Toxicology and Pharmacology 26: 136-141.

80. Sharma, V., D. Anderson and A. Dhawan, 2012. Zinc oxide nanoparticles induce oxidative DNA damage and ROS-triggered mitochondria mediated apoptosis in human liver cells (HepG2). *Apoptosis*, 17: 852–870

UNDER PEER REVIEW