

Myxoid degenerated giant rectal schwannoma masquerading as tailgut cyst: A rare case report

Abstract

Background

Colorectal schwannomas are rare tumors often detected incidentally and frequently misdiagnosed on preoperative evaluation. They can grow to a large size and create a significant mass effect. A rare case of large rectal Schwannomas mimicking tailgut cyst and managed by a laparoscopic approach is described in the present report.

Case presentation

A 48- year-old gentleman presented with urinary retention and constipation. Examination revealed an ill-defined hard mass in the left iliac fossa extending to the pelvis. Imaging revealed an 18x12x 9 cm cystic lesion suggestive of a tailgut cyst. The patient underwent Hand-assisted laparoscopic excision of the lesion. The tumor showed spindle cells with myxoid degeneration on microscopic examination and S-100 positivity in immunohistochemistry suggestive of Schwannoma. His postoperative course was uneventful, and there is no evidence of tumor recurrence at eight months of follow-up.

Conclusion

Rectal Schwannoma with myxoid degeneration can mimic tailgut cyst and pose a diagnostic challenge. Hand-assisted laparoscopic approach is feasible for excision of large rectal schwannomas.

Keywords – Giant rectal schwannoma; myxoid degeneration; tailgut cyst; Hand-assisted laparoscopic excision

Introduction

Schwannomas are extremely rare tumors of the nerve sheath, developing from Schwann cells, which produce insulating myelin sheath to cover peripheral nerves. In the gastrointestinal tract, they present as spindle cell tumors originating from Auerbach's myenteric plexus. It accounts for approximately 2-6% of all mesenchymal tumors. Gastrointestinal tract schwannoma frequently occurs in the stomach (83%) followed by the small bowel (12%) [1]. The rectum is a rare site for Schwannoma. Schwannoma is often detected incidentally, and a definite diagnosis is made on the pathological examination of the surgical specimen and immunohistochemistry. Complete resection is the preferred treatment to reduce recurrence [2]. The open approach was commonly used to treat rectal Schwannoma. The present report describes a rare case of myxoid degeneration of Schwannomas mimicking tailgut cyst managed by laparoscopic approach.

Case Report

A 48-year-old gentleman initially presented with urinary retention for five months and constipation for two months duration. There was no history of vomiting, abdominal pain, melena, bony pain, breathlessness, or chest pain. The patient was moderately built and nourished with good performance status. Abdominal examination revealed an ill-defined mass in the left

iliac fossa extending into the pelvis. Rectal examination revealed a hard mass extrinsically compressing the rectal wall in the anterior and lateral aspects. Hemogram was within normal limits and serum carcinoembryonic antigen (CEA) level was not elevated (CEA 1.8 ug/L). MRI pelvis revealed 18x 12x 9 cm lobulated T2 hyperintense and T1 hypointense cystic lesion in the pelvis compressing and displacing the rectum anterolaterally to the left. Anteriorly, the lesion was abutting the prostate and urinary bladder (Figure 1). A provisional diagnosis of tailgut cyst was made based on the imaging findings and the patient was planned for laparoscopic excision.

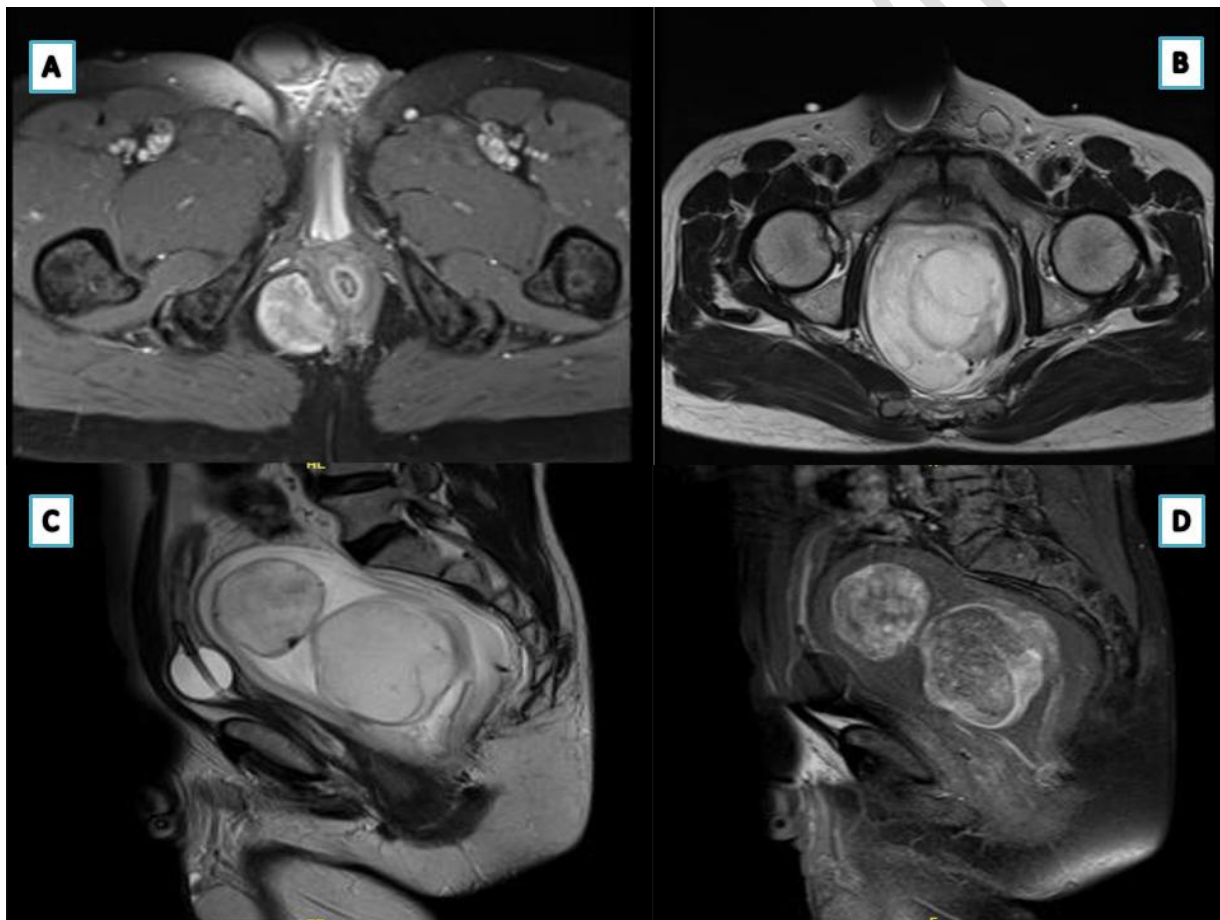


Figure 1. MRI pelvis: [A] cystic lesion originating from the posterior lateral part of the rectum. [B] Large cystic lesion compressing the rectum. [C, D] The sagittal section shows a large cystic lesion with 2 daughter cysts seen within the cyst, compressing the urinary bladder anteriorly.

The intraoperative evaluation revealed a large tense lesion occupying the space between bladder and rectum, limiting laparoscopic dissection. Attempted aspiration of the cyst failed due to thick gelatinous content (Figure 2).

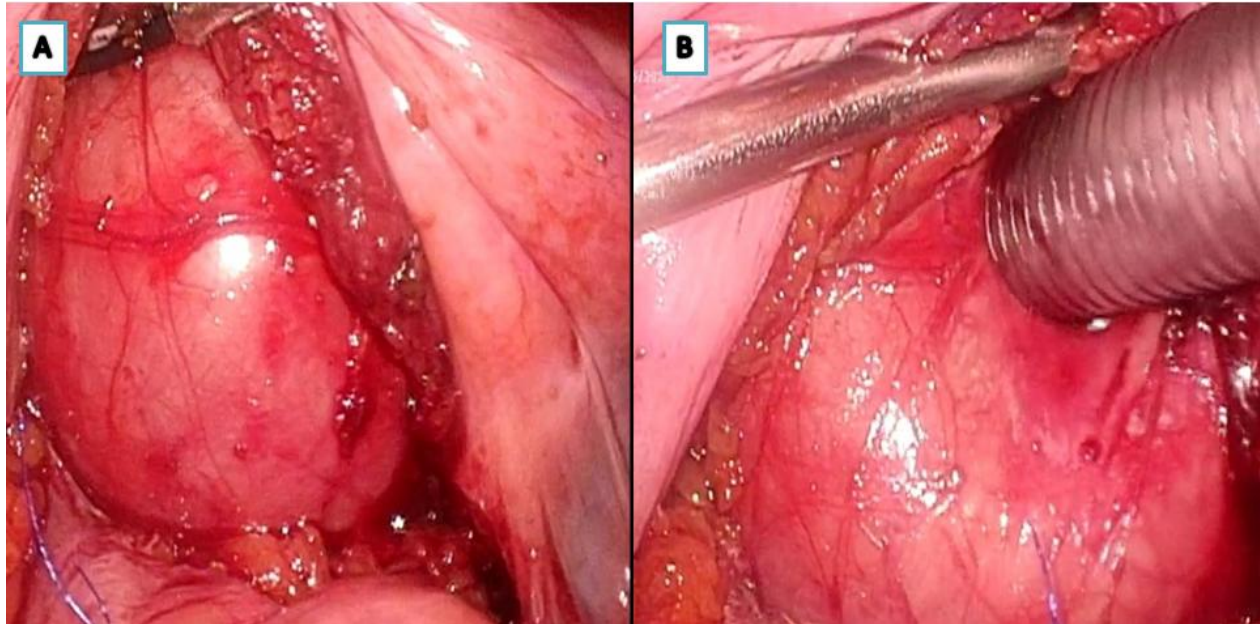


Figure 2. [A] The laparoscopic intraoperative picture showed a large cystic lesion. [B] Attempting of aspiration revealed thick gelatinous material which was not amenable to aspiration.

An intraoperative frozen section was sent from the cyst wall, which didn't show any atypical cells suggestive of malignancy. Hence, a hand-assisted laparoscopic cyst excision was performed. The cyst was completely removed in a piecemeal fashion and the lowermost extent of the cyst was noted at the level of the pelvic floor. Microscopic examination revealed a gelatinous area with sheets of benign spindle-shaped cells arranged in short fascicles admixed with focal myxoid change and thick-walled blood vessels. tumor cells showed diffuse positivity for S100 and negative for CD117. The microscopic and immunohistochemistry findings were suggestive of benign Schwannoma with myxoid degeneration (Figure 3). The patient is asymptomatic at eight months follow-up with no clinical evidence of recurrence.

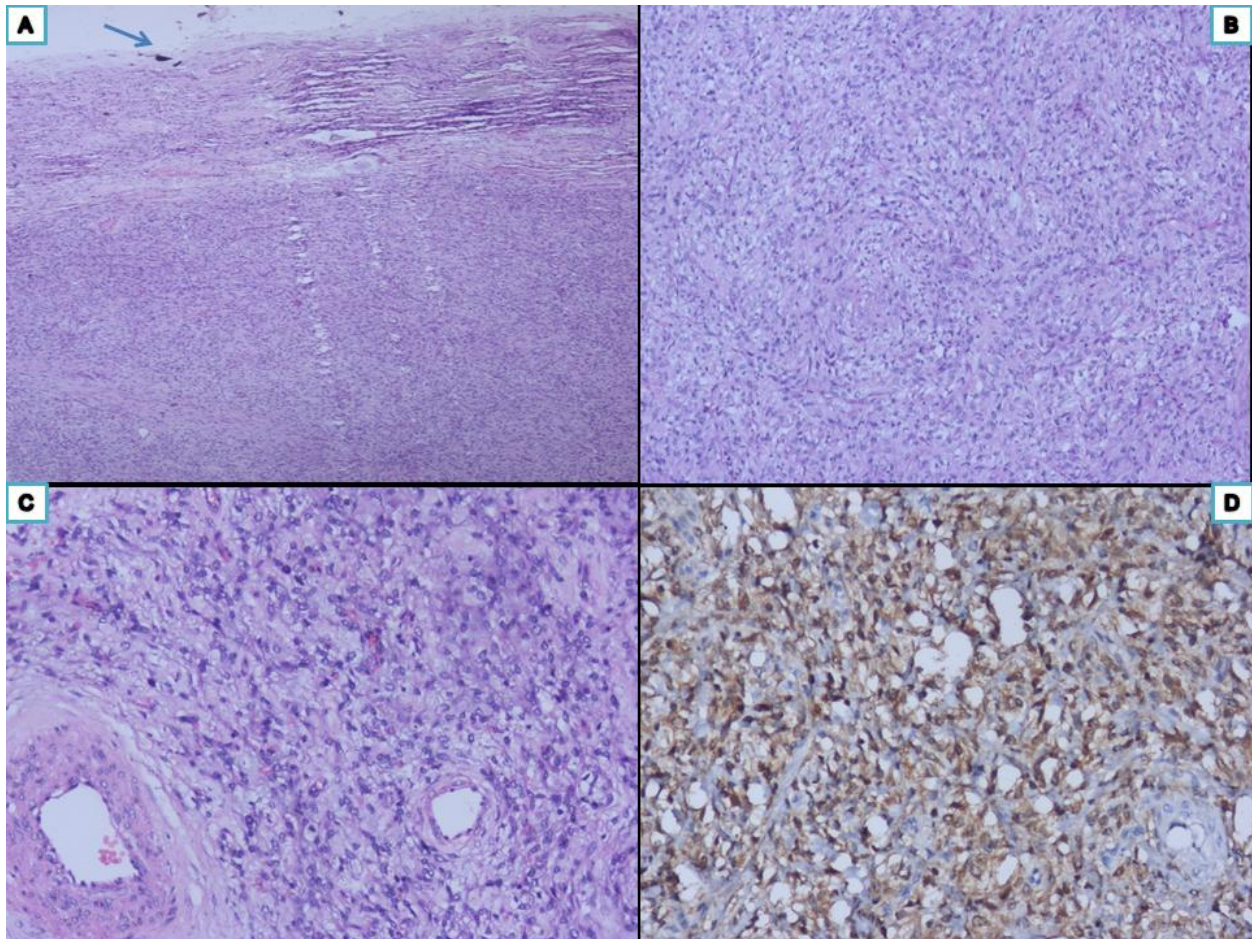


Figure 3. Histopathological sections show [A] tumor with overlying capsule [arrow] [H&Ex40]. [B] Sheets and fascicles of tumor cells [H&Ex100]. [C] Tumor cells are round to oval in shape with minimal nuclear atypia along with adjacent thick-walled vessels [H&Ex100]. [D] Immunohistochemistry with S 100 show strong nuclear and cytoplasmic positivity [DABX100].

Discussion

The gastrointestinal autonomic nerve tumors (GANTs) were first described and defined by Herrera et al. in 1984 [3]. Schwannomas belong to GANT which is a subcategory of gastrointestinal stromal tumor (GIST) [4, 5]. Schwannomas located in the colon and rectum are unrelated to Von Recklinghausen's disease [1]. They can appear in any age group but are most frequently seen in the sixth decade of life [6]. This neurogenic tumour is usually benign and has

indolent growth. Although they are generally asymptomatic, they may present with bleeding, obstruction, tenesmus, and rectal pain [1]. In the present report, the patient presented with features of lower urinary tract obstruction and constipation because of a large tumour compressing the bladder neck, and rectum.

MR imaging features that suggest the diagnosis of a neurogenic tumour include the presence of a fusiform-shaped mass with an entering and exiting tail representing the host nerve [7]. Typically, the Schwannomas of the gastrointestinal tract are homogenous. However, in our case, the imaging revealed a heterogeneous cystic lesion and hence a preoperative diagnosis of a tailgut cyst was made [8]. Furthermore, the schwannomas are often diagnosed on histopathological examination of operative specimens and immunohistochemistry, as a preoperative diagnosis is difficult [9]. Macroscopically, schwannomas are well-delimited, solid tumors that range in size from less than 1 cm to a very large tumour up to 28 cm that presents with an increase in abdominal girth [10, 11]. Longstanding tumors may develop degenerative changes such as hemorrhage, calcification and fibrosis, but cystic degeneration is rare [12-14]. Microscopically, schwannomas are encapsulated neoplasms and two histological growth patterns have been described: Antoni A and Antoni B. In Antoni A type, there is a dense growth of fusiform cells, compactly arranged in palisades to form Verocay bodies. In Antoni B, the fusiform cells are more loosely distributed with rounded or elongated nuclei, with a greater quantity of myxoid stroma and xanthomatous histiocytes [6, 9]. Immunohistochemistry plays an essential role in diagnosis with diffuse positive immunostaining for S-100 and Leu7 antigen is suggestive of Schwann cell origin [15]. Myxoid degeneration observed in the present patient is a rare finding in Schwannoma.

Complete surgical resection is the best therapeutic option for Schwannoma. Lymph node dissection is not recommended because of less risk of malignant transformation [4]. The surgical approach varies with the size and location of the tumour. When the tumour is diagnosed preoperatively, the endoscopic approach is feasible for small tumors [16, 17]. Minimally invasive surgery like laparoscopic wedge resection and laparoscopic right hemicolectomy were reported for colonic schwannomas [18, 19]. However, an open approach is frequently used for large rectal schwannomas. Recently, Feifei et al. reported the feasibility of robot-assisted retro rectal schwannoma excision in 12 patients. However, the largest size of the tumour in that series was 4.6x 3.6x 4.1 cm. [20]. In the present report, an 18x 12 cm tumour was resected using the hand-assisted laparoscopic method.

Conclusion

Rectal Schwannoma with myxoid degeneration can mimic tailgut cyst and pose a diagnostic challenge. Degenerative changes and the rarity of the tumor are important reasons for misdiagnosis in the case of rectal Schwannoma. Immunohistochemistry helps in the definitive diagnosis of Schwannoma in doubtful cases. Surgical resection is the mainstay of treatment for Schwannoma. A hand-assisted laparoscopic method is a feasible approach for the excision of large tumors with a low risk of malignancy.

Ethics approval

The Institute Research Ethics Committee approval was obtained.

Consent to participate

Informed consent was obtained from patient.

Consent to publish

The authors affirm that human research participants provided informed consent for publication of the images

References

1. Bohlok A, El Khoury M, Bormans A, Galdon MG, Vouche M, El Nakadi I et al. Schwannoma of the colon and rectum: a systematic literature review. *World J Surg Oncol*. 2018 Jul 3. <https://www.ncbi.nlm.nih.gov/pmc/articles/PMC6029403> DOI: 10.1186/s12957-018-1427-1
2. Suzuki T, Suwa K, Hada T, Okamoto T, Fujita T, Yanaga K. Local excision of rectal schwannoma using transanal endoscopic microsurgery: A case report. *Int J Surg Case Rep*. 2014 Nov 11;5(12):1193–6. DOI: 10.1016/j.ijscr.2014.11.020
3. Herrera GA, Pinto de Moraes H, Grizzle WE, Han SG. Malignant small bowel neoplasm of enteric plexus derivation (plexosarcoma). Light and electron microscopic study confirming the origin of the neoplasm. *Dig Dis Sci*. 1984 Mar; 29(3):275–84. DOI: 10.1007/BF01296263

4. Maciejewski A, Lange D, Włoch J. Case report of schwannoma of the rectum--clinical and pathological contribution. *Med Sci Monit Int Med J Exp Clin Res.* 2000 Aug; 6(4):779–82.
5. Daimaru Y, Kido H, Hashimoto H, Enjoji M. Benign schwannoma of the gastrointestinal tract: a clinicopathologic and immunohistochemical study. *Hum Pathol.* 1988 Mar; 19(3):257–64. DOI: 10.1016/s0046-8177(88)80518-5
6. Miettinen M, Sarlomo-Rikala M, Lasota J. Gastrointestinal stromal tumours. *Ann Chir Gynaecol.* 1998; 87(4):278–81.
7. Nyapathy V, Murthy UK, Chintamani J, Sridhar DY. A case report of a giant presacral cystic schwannoma with sigmoid megacolon. *J Radiol Case Rep.* 2009; 3(12):31–7. doi: 10.3941/jrcr.v3i12.225
8. Yang DM, Park CH, Jin W, Chang SK, Kim JE, Choi SJ, et al. Tailgut Cyst: MRI Evaluation. *Am J Roentgenol.* 2005 May 1; 184(5):1519–23. DOI: 10.2214/ajr.184.5.01841519
9. Miettinen M, Shekitka KM, Sobin LH. Schwannomas in the colon and rectum: a clinicopathologic and immunohistochemical study of 20 cases. *Am J Surg Pathol.* 2001 Jul; 25(7):846–55. DOI: 10.1097/00000478-200107000-00002
10. Schwartz DA. Malignant schwannoma occurring with *Schistosoma japonicum*: a case report. *Southeast Asian J Trop Med Public Health.* 1982 Dec; 13(4):601–5.
11. Cleveland BR, Cunningham PJ. Giant neurilemmoma of the transverse mesocolon. Case report. *Am Surg.* 1966 Jul; 32(7):461–3.

12. Kashyap S, Pushker N, Meel R, Sen S, Bajaj MS, Khuriajam N, et al. Orbital schwannoma with cystic degeneration. *Clin Experiment Ophthalmol*. 2009 Apr; 37(3):293–8. DOI: 10.1111/j.1442-9071.2009.02029.x
13. Jaiswal A, Shetty AP, Rajasekaran S. Giant cystic intradural schwannoma in the lumbosacral region: a case report. *J Orthop Surg Hong Kong*. 2008 Apr; 16(1):102–6. DOI: 10.1177/230949900801600124
14. Schindler OS, Dixon JH, Case P. Retroperitoneal giant schwannomas: report on two cases and review of the literature. *J Orthop Surg Hong Kong*. 2002 Jun; 10(1):77–84. DOI: 10.1177/230949900201000114.
15. Das Gupta TK, Brasfield RD. Tumors of peripheral nerve origin: benign and malignant solitary schwannomas. *CA Cancer J Clin*. 1970 Aug; 20(4):228–33. DOI: 10.3322/canjclin.20.4.228
16. Nonose R, Lahan AY, Santos Valenciano J, Martinez CAR. Schwannoma of the Colon. *Case Rep Gastroenterol*. 2009 Sep 22; 3(3):293–9. doi: 10.1159/000237736
17. Hornick JL, Bundock EA, Fletcher CDM. Hybrid schwannoma/perineurioma: clinicopathologic analysis of 42 distinctive benign nerve sheath tumors. *Am J Surg Pathol*. 2009 Oct; 33(10):1554–61. DOI: 10.1097/PAS.0b013e3181accc6c
18. Matsumoto T, Yamamoto S, Fujita S, Akasu T, Moriya Y. Cecal schwannoma with laparoscopic wedge resection: report of a case. *Asian J Endosc Surg*. 2011 Nov; 4(4):178–80. DOI: 10.1111/j.1758-5910.2011.00089.x

19. Kim HJ, Kim CH, Lim SW, Huh JW, Kim YJ, Kim HR. Schwannoma of ascending colon treated by laparoscopic right hemicolectomy. *World J Surg Oncol*. 2012 May 15; 10:81. DOI: 10.1186/1477-7819-10-81
20. Pu F, Zhang Z, Chen Z, Cai K, Wang B, Wu Q, et al. Application of the da Vinci surgical robot system in presacral nerve sheath tumor treatment. *Oncol Lett*. 2020 Nov; 20(5):125. doi.org/10.3892/ol.2020.11984

UNDER PEER REVIEW