

**TORSION OF PARAOVARIAN CYST IN 11 YEAR OLD GIRL: CASE
REPORT**

Abstract

Para ovarian cysts are cystic tumours encountered in-between ovarian hilum and fimbria within mesosalpinx and broad ligament, usually diagnosed in 3rd - 4th decade of life. Large pelvic cyst in young adolescent shortly after menarche present a challenge in diagnosis and management. When such cyst presents as acute abdomen due to torsion, a high index of suspicion is required to differentiate from other common diagnosis including acute appendicitis, especially in a peripheral setting with limited imaging facilities. Early diagnosis and surgery are required to alleviate symptoms as well as to maintain the vitality of adnexal organ for future reproductive function. This case report describes a para ovarian cyst in 11 year old girl presented as acute abdomen at a peripheral hospital and managed with laparoscopic detorsion and para ovarian cystectomy.

Key Words: Adolescent Paraovarian cyst torsion, Acute abdomen, Laparoscopic detorsion

Introduction

Para ovarian cysts (PC) are cystic tumours located between ovarian hilum and fimbriae within mesosalpinx and broad ligament[1]. These lesions are usually benign, accounting 5% to 20% of all adnexal tumours and originate from Mullerian

(paramesonephric) or Wolffian (mesonephric) ducts or mesothelium[2].The peak incidence of PC is third and fourth decade of life and the exact incidence of these type of cyst in adolescent is not known as it remains asymptomatic (80%) and an incidental finding on ultrasound[3,4]. These patients may present with abdominal pain, nausea and vomiting; or with complications including torsion, bleeding, perforation and malignant transformation[3,4]. PC in adolescent are having a relatively higher rate of torsion than in adults; may be due to long infundibulo-pelvic ligament[1,5,6].

Presenting as acute abdomen, differential diagnosis includes acute appendicitis, ectopic pregnancy, torsion ovarian cyst, and leiomyoma. Incidence of acute appendicitis outweighs all other differential diagnosis and is the most common surgical condition in children who present with abdominal pain[7]. There are no clinical or imaging criteria sufficient to confirm the preoperative diagnosis of adnexal torsion[8].

Ultrasound is the foremost investigative tool for the diagnosis and unilocular cystic mass in pelvis can easily be identified. However, being operator and patient dependant, accurate determination of origin of cyst may be suboptimal, especially in patients of acute abdomen. Moreover, it may be misdiagnosed as ovarian cysts, lymphocoele or peritoneal inclusion cysts[9]. Computed tomography (CT) and MRI are better in diagnosis. However, availability of the same are restricted in peripheral settings and evacuation to advanced centres consumes vital time for management.

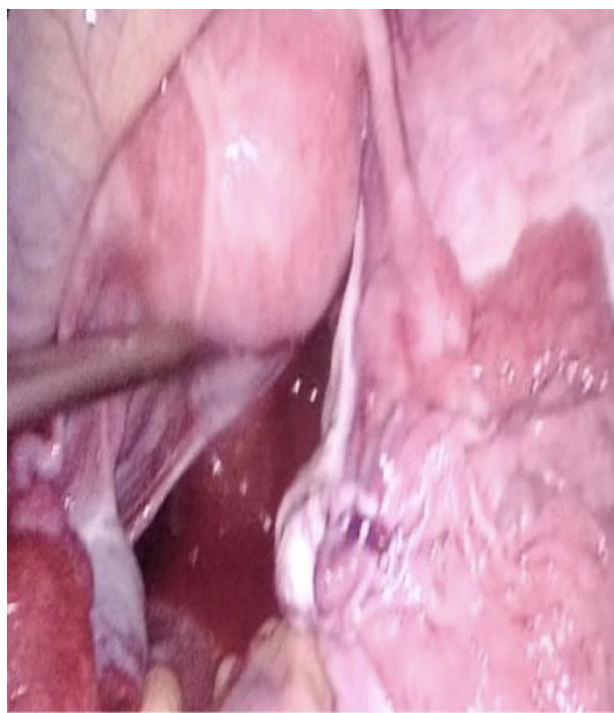In this case report, a paraovarian cyst in 11 year old girl presented as acute abdomen and managed with laparoscopic detorsion and cystectomy is described. Informed consent was obtained from patient's mother (legal guardian) for publication of this case report.

Case report:

11/y adolescent female presented to emergency with history of pain right lower abdomen for 08 hours. It was acute onset pain, continuous, VAS 10/10 and non-radiating. It was associated with nausea and 03 episodes of non-bilious vomiting. There was no history of anorexia, fever, bloating of abdomen, obstipation, constipation, haematuria, dysuria, graveluria, discharge per vaginum. She attained menarche at 10 years of age, regular and was on day 27 of menstrual cycle on presentation. She has never been sexually active, abused or experienced abdominal trauma. No history of similar episodes in the past. Remaining medical and surgical history was unremarkable.

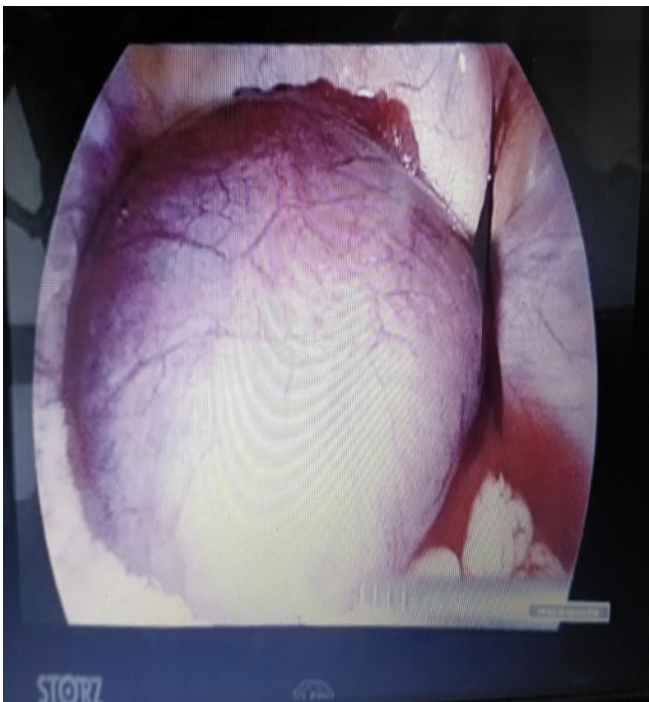
On examination, patient was afebrile, normotensive, had tachycardia and was agitated with pain. BMI 25.78 Kg/M². Abdomen was nondistended. Tenderness was present in McBurney's point with rebound tenderness positive. Voluntary guarding was present limiting further examination. Bowel sounds were present. Other systemic examination was within normal limits. Secondary sexual characters were consistent with age. Per vaginum examination was not done. Haematological investigations revealed raised TLC counts with shift to left. Alvarado (MANTRELS) score 7/10. Transabdominal ultrasonography was suboptimal in view of agitated patient, however, revealed cystic lesion in right adnexa.

Analgesia provided no relief and patient was taken up for Emergency Diagnostic Laparoscopy. Anaesthesia risks included



patient's full stomach status with consequent aspiration risk upon induction of anaesthesia. After explaining risks of the surgery, consent was taken from father of the child. General anaesthesia with endotracheal intubation was done. Umbilical 10mm port was introduced post Veress pneumoperitoneum, followed by right and left lumbar 5mm ports. 15x15cm para-ovarian cyst was detected in right adnexa extending till contralateral medial umbilical ligament, supra uterine in position, bluish in colour. 720° Torsion of cyst along with right ovary was present. Fallopian tube was seen stretched along the cystic wall. Right ovary was bluish in appearance with minimal serosanguinous fluid present in adnexa. Both ovaries were bulky looking with no obvious morphological changes. Other intra-abdominal organs were grossly normal.

Fig 1:



De-torsion was done by rotating cyst 720° laparoscopically. Viability of ovary was confirmed with return of pink colour. Cyst wall was dissected laparoscopically free of

Cyst with thinned out fimbria and serosanguinous adnexal collection

Preserved fallopian tube and ovary after cystectomy

outer layer by blunt dissection following incision between round ligament and tube using tissue cutting scissors. Complete excision was achieved, 560ml serosanguinous fluid drained and cyst was delivered through right lumbar 5mm port without damaging the fallopian tube.

Grossly, specimen was 15x15cm globular tissue with maximum wall thickness of 0.3 cm. External surface showed areas of congestion. On cutting open, unilocular cyst noted with few areas of haemorrhage within no areas of irregular wall thickening or necrosis. Microscopically, fibrocollagenous cyst wall lined by single layer of flattened cuboidal to columnar cells present. No areas of nuclear atypia or stratification noted. No mitotic figures seen. Sub-epithelium showed areas of congestion. No endometrial glands noted. No granulomas seen. Opinion: Simple serous cyst.

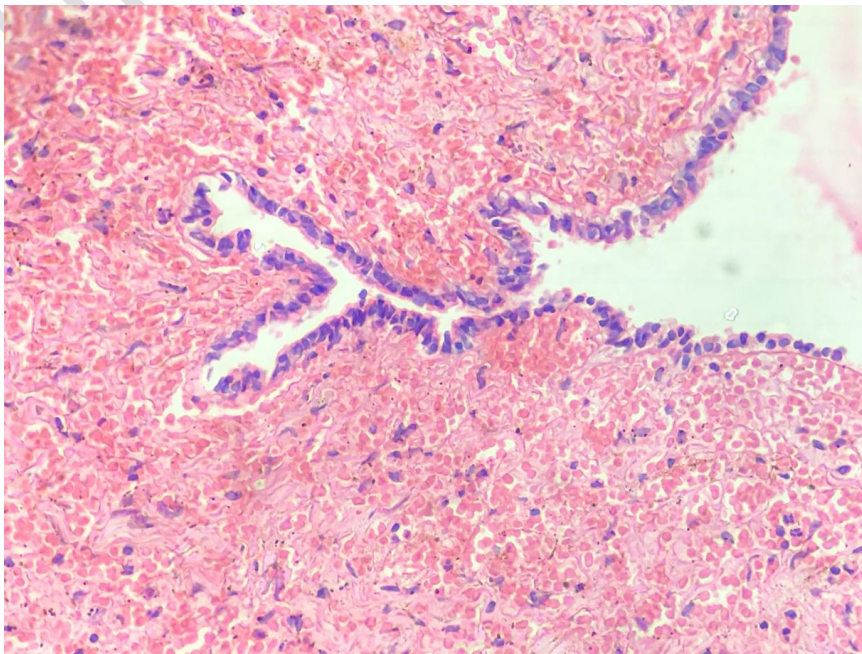


Fig 2: Fibro-collagenous cyst wall lined by single layer of flattened cuboidal cells. Sub-epithelium shows areas of congestion

Patient was discharged on post op day 03 and follow up at 06 months showed normal clinical, paraclinical and ultrasound findings.

Discussion

Para-ovarian cysts have been described with average age of 15.4 +/- 2.8 yrs[10] and at 11 years of age, it remains extremely rare entity. Torsion of para ovarian cyst is more common in pregnant females probably due to rapid growth spurt and enlargement[11] and we believe rapid growth spurt is also a contributing factor in adolescents in addition to theory of long infundibulo-pelvic ligaments for development and torsion of paraovarian cysts. Large para ovarian cysts seen in younger patients are usually benign and mesothelial in origin[12].

Acute appendicitis, ectopic pregnancy, torsion ovarian cyst and leiomyoma are few differential diagnoses of para ovarian cyst torsion. Clinical diagnosis of the case mimics acute appendicitis due to low suspicion of paraovarian cyst at such an early age. Guarding of abdomen delayed identification of cyst despite large size and ultrasound was suboptimal due to patient being agitated. Further imaging adds

details, but in peripheral settings where evacuation is time consuming, early surgery aids in preserving reproductive function of the patient. Minimally invasive laparoscopic surgery offers ideal diagnostic and therapeutic modality saving cost and time and is the recommended line of treatment in such a case.

Although the viability of an ovary declines as time elapses from the onset of pain to surgical detorsion, the dual blood supply of ovary makes it resilient to vascular injury, and the exact duration of vascular interruption needed to cause irreversible damage to the ovary is unknown[13]. Although two retrospective studies suggest that a sharp decrease in ovarian function occurs 72 hours after the onset of symptoms, the ovary is resilient, and function may persist much longer[13,14]. Ovary was preserved in our case despite torsion of 720⁰ and onset of visible cyanotic changes and follow up ultrasound colour doppler at post-operative day 4 confirmed viability of ovary.

Signs indicating possible need for surgery in patients with acute abdomen are absent bowel sounds, bilious vomiting, bloody diarrhoea, elevated temperature >100.4F, rebound tenderness, rigidity and guarding[7]. Supported by USG, laparoscopy has become the gold standard in surgical management for Ovarian as well as para-ovarian cysts in adults with laparotomy reserved only for suspicion of malignancy[15]. This line of approach is diagnostic as well as therapeutic and provides fast post-operative recovery when compared to laparotomy. In our case, patient was started orally in post-operative evening, oral paracetamol was given for analgesia and discharged on post-operative day 2. No pain abdomen or recurrence of cyst was observed at the end of one year.

Conclusion

Paraovarian cysts are extremely rare entity, especially in adolescent girls as young as 11 years and may mimic acute appendicitis. Being an uncommon surgical emergency with no definitive diagnostic signs, its diagnosis is often delayed, which results in causation of irreversible damage to the fallopian tube and ovary. Surgeons should be aware of this condition, so that an early diagnosis can be made and a conservative surgery, if possible, with salvage of the fallopian tube and ovary can be done. Laparoscopic access provides adequate exposure of the lesion with early post-operative recovery.

References

1. An incidental diagnosis of a giant paraovarian cyst in a female teenager: A case report: Mărginean et al. LWW journals, Medicine: November 2018 - Volume 97 - Issue 48 - p e13406
2. Vlahakis-Miliaras E, Miliaras D, Koutsoumis G, et al. Paratubal cysts in young females as an incidental finding in laparotomies performed for right lower quadrant abdominal pain. *Pediatr Surg Int* 1998;13:141–2.
3. Betancor L, Eduvigis C, Vázquez Rueda F, et al. Quiste paratubárico en la infancia. Manejo laparoscópico. *Prog Obstet Ginecol* 2011;54:376–8.
4. Abad P, Obradors J, Ortuño P, et al. Torsion of paraovarian cyst in pediatrics [in Spanish]. *Cir Pediatr* 2005;18:46–8
5. Okada T, Yoshida H, Matsunaga T, et al. Paraovarian cyst with torsion in children. *J Pediatr Surg* 2002;37:937–40.
6. Said MR, Bamigboye V. Twisted paraovarian cyst in a young girl. *J Obstet Gynaecol* 2008;28:549–50.
7. Ashcraft KW. *Pediatric surgery*. 3d ed. Philadelphia: Saunders, 2000.

8. American College of Obstetricians and Gynaecologists recommendation Number 783 (Reaffirmed 2021)
9. Kajiyama A, Edo H, Takeya C, et al. Spontaneously ruptured paraovarian tumor of borderline malignancy with extremely elevated serum carbohydrate antigen 125 (CA125) levels: a comparison of the imaging and pathological features. *Am J Case Rep* 2017;18:919–25.
10. Tamar Tour, Noam Smorgick, Nataly Sharon, Marina Pekar-Zlotin, Yaakov Melcer. Adnexal torsion with paraovarian cysts in pediatric and adolescent populations: A retrospective study. *J Pediatr Surg* 2021 Feb; 56(2): 324-327
11. Puri M, Jain K, Negi K (2003) Torsion of para ovarian cyst: A cause of acute abdomen. *Indian J Med Sci* 57: 361-362
12. Grant EC (1992) Benign conditions of the ovaries.
13. Rossi BV, Ference EH, Zurakowski D, Scholz S, Feins NR, Chow JS, et al. The clinical presentation and surgical management of adnexal torsion in the pediatric and adolescent population. *J Pediatr Adolesc Gynecol* 2012; 25: 109 – 13
14. Hubner N, Langer JC, Kives S, Allen LM. Evolution in the management of pediatric and adolescent ovarian torsion as a result of quality improvement measures. *J Pediatr Adolesc Gynecol* 2017;30:132 – 7 .
15. Yuen PM, Yu KM, Yip SK, et al. A randomized prospective study of laparoscopy and laparotomy in the management of benign ovarian masses. *Am J Obstet Gynecol* 1997;177:109–14.