

***Free lipoma in the sac of right inguinal hernia:
A case report.***

Abstract:

A 31-year-old man who was previously healthy, presented at the surgical outpatient clinic with a right inguinal hernia. On laparoscopy, a free lipoma was found inside the hernial sac.

Introduction:

Peritoneal loose bodies (PLBs) are usually seen during laparotomy, laparoscopy, or autopsy. It is generally agreed that the source of these bodies is the epiploic appendices via sequential processes of torsion, infarction, saponification, or calcification (1). Usually the PLBs are small (less than 1 cm) but Giant loose bodies (more than 5 cm) are very rare and only a few cases have been reported in the literature (1). However, these bodies may grow to larger sizes and cause some symptoms such as intestinal obstruction and urinary retention (2). The PLBs are misinterpreted as intraabdominal tumours or foreign bodies and unnecessary surgical interventions are usually done (3). However, surgical exploration may be the imperative method for definite management in some instances (4). One of these PLBs is a lipoma. Intraperitoneal lipoma is extremely rare (5)

Case history:

A 43-year-old male patient who is previously healthy, presented at the outpatient clinic by a picture of an uncomplicated right side inguinal hernia. He was scheduled for laparoscopic hernia repair (TAPP repair). On laparoscopy, a free mass like lipoma was found inside the hernia sac, which was extracted easily by forceps and sent for histopathology. The gross picture of histopathological examination revealed a yellow adipose tissue fragment measuring 6.6 x 2.3 x .7 cm and microscopically showed mature fat cells with fat necrosis. The patient had a postoperative smooth course, and he was discharged home on the 1st postoperative day. On follow-up, after 15 days the patient was completely asymptomatic.

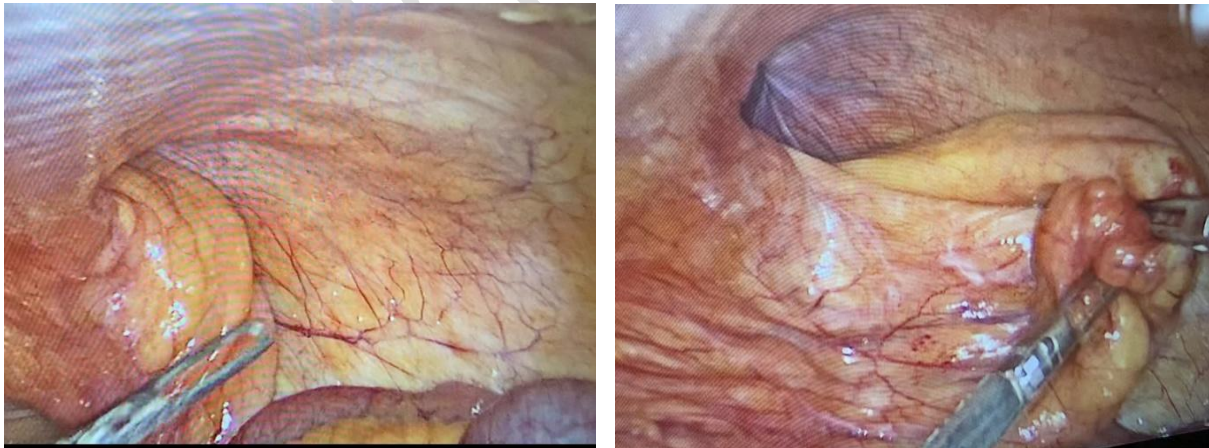

Fig 1: Before seeing the lipoma

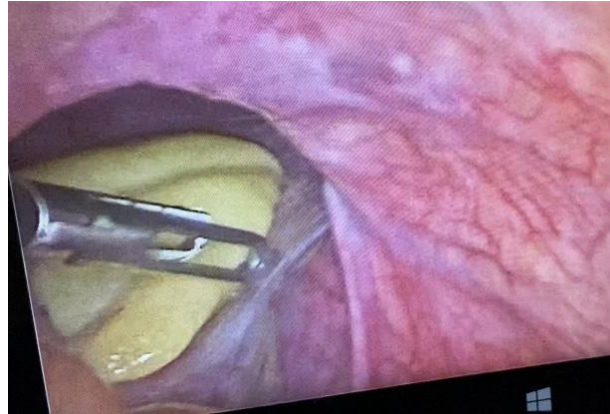
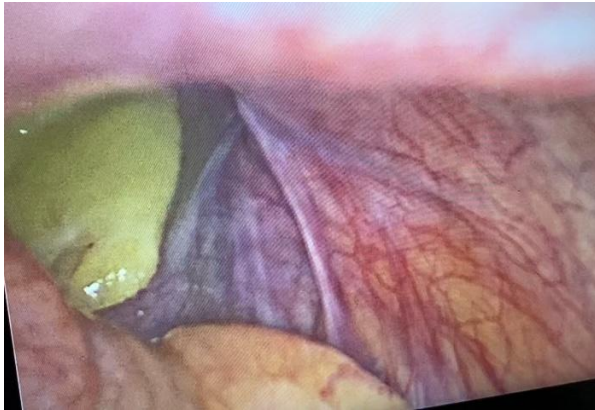

Fig 2: Seeing the lipoma

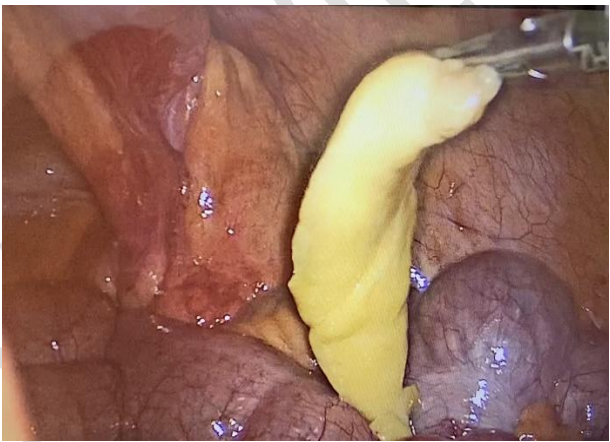
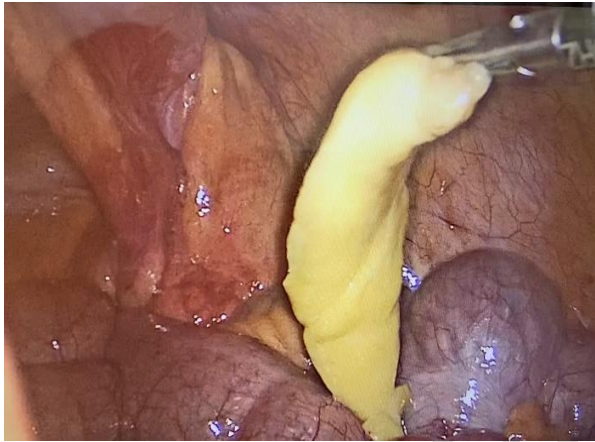
Fig 3: During extraction

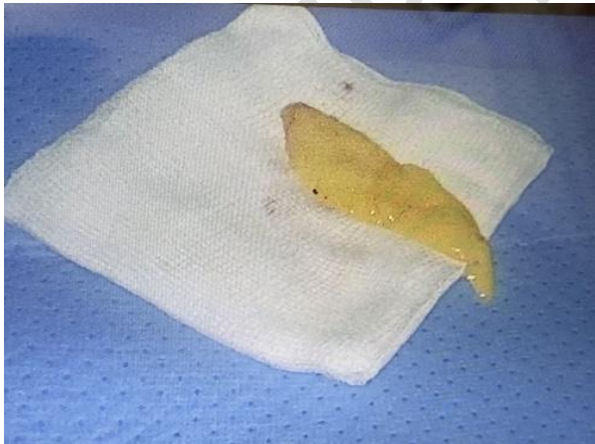

Fig 4: Outside the abdomen

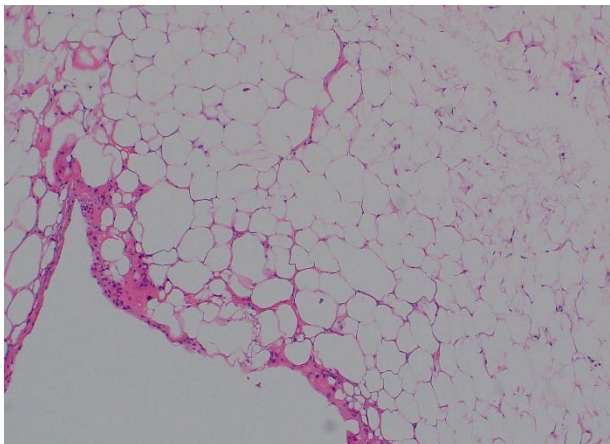


Fig 5: The histopathology

Discussion:

Giant loose bodies (peritoneal mice) are very rare and only a few cases have been reported in the literature (1). The pathogenesis of loose bodies has not been fully explained; however, the current theory suggests that it is a sequential process that starts with the torsion of an epiploica, followed by ischemia, saponification, or calcification. The pedicle of these epiploica atrophies leading to its detachment from the colon surface to become a loose body (1 -7). Pre-operative diagnosis of these lesions is difficult as these lesions are usually asymptomatic and found during exploration of the abdomen for some other pathology. Grossly, lipomas usually are oval, yellow, soft, and capsulated. Lipomas generally grow slowly, and are mobile masses, which do not infiltrate the surroundings (6). In our case, the lipoma was found free in the sac of the inguinal hernia.

Conclusions:

Peritoneal loose bodies are seldom found. Usually, they are small. Giant loose bodies are very rare and only few cases have been reported in the literature. The hypothesis of their development is unclear. No specific treatment is required in asymptomatic patients. However, if these bodies become associated with complications like intestinal obstruction or the diagnosis is in doubt, then surgical intervention will be required.

References

1. Desai HP, Tripodi J, Gold BM, Burakoff R. Infarction of an epiploic appendage: review of the literature. *J Clin Gastroenterol* 1993; 16: 323-5.
2. Takabe K, Greenberg JJ, Blair SL. Giant peritoneal loose bodies. *J Gastrointest Surg* 2006; 10: 465-8.
3. Gayer G, Petrovitch I. CT diagnosis of a large peritoneal loose body: a case report and review of the literature. *Br J Radiol* 2011; 84:83–5.
4. Obaid M, Gehani S. Deciding to remove or leave a peritoneal loose body: a case report and review of literature. *Am J Case Rep* 2018; 19:854–7.
5. Prando A, Wallace S, Marins JL, Pereira RM, de Oliveira ER, Alvarenga M. Sonographic features of benign intraperitoneal lipomatous tumors in children--report of 4 cases. *Pediatr Radiol*. 1990; 20(8):571-4.
6. Nomura H, Hata F, Yasoshima T, Kuwahara S, Naohara T, Nishimori H, Nakasjima F, Yanai Y, Ono K, Hirata K: Giant peritoneal loose body in the pelvic cavity: report of a case. *Surg Today* 2003, 33(10):791-793.