

Ameloblastic carcinoma of the maxilla: a rare case misdiagnosed as benign ameloblastoma

Keywords: ameloblastic carcinoma, benign ameloblastoma, odontogenic tumor.

Abstract:

Introduction: Ameloblastic carcinomas are rare odontogenic tumors, and when discovered in maxillary sinus, they are considered even rarer. Because of rarity, there is limited information about the clinical behavior of such patients.

Presentation of case: We report a case of a 58-year-old man presented at our institution with 3 months history of reappearing for painful left maxillary swelling. Medical history shows that he had been diagnosed one year earlier for benign ameloblastoma of maxillary sinus and treated by maxillary curettage. Our clinical examination and radiological investigations shows a locally advanced tumor compatible with ameloblastic carcinoma of maxillary sinus.

Histological re-evaluation of the initial specimen confirmed the diagnostic of ameloblastic carcinoma. Treatment consisted of chemo-radiotherapy, the patient underwent three cure of chemotherapy. The evolution was clinically marked by decreasing tumoral volume. He was lost of vu before undergoing radiotherapy.

Conclusion: Ameloblastic carcinoma may represent a serious diagnostic challenge. It should be considered in the differential diagnosis of benign ameloblastoma even if it's rare.

Introduction:

Ameloblastic carcinoma is an extremely rare malignant tumor of the maxilla. It is the malignant counterpart of ameloblastoma. In the last update of the WHO classification, published in 2017, it is defined as a rare odontogenic malignancy that combines cytological features of malignancy and the histological pattern of an ameloblastoma, in either the primary or a metastatic lesion (1).

Ameloblastic carcinoma are 3 time more frequent in mandible than in the maxilla (2,3), and It represents less than 1% of all ameloblastomas (4), most case arise de novo, but some arise in some preexisting ameloblastomas.

In comparison to ameloblastic carcinomas of the mandible, maxillary ameloblastic carcinomas have not been well studied because of the lack of available data and rarity of well documented reports.

Since few cases have been reported in the literature, the incidence of the tumor, as well as the criteria for classification, is not precisely defined. Furthermore, treatment modalities are still debated and there is lack of information regarding certain characteristics of the disease, (3)

The following case describes a rare case of ameloblastic carcinoma of the maxilla in a 58 year-old man, which was originally misdiagnosed as a benign ameloblastoma.

Case report:

A 58-year-old man presented at our institution with 3 months history of reappearing for painful left maxillary swelling. The swelling was initially slow growing and painless until last month, when its growth became rapid and was coupled with severe pain. He presented also left nasal obstruction with aqueous rhinorrhea and concomitant left exophthalmos.

The patient complains also of intermittent headache without fever or other symptoms.

Moreover he had no pharmacological allergies, no psychosocial problems, smoking and no family genetic disease.

In investigation of his medical history, the patient declares been treated one year earlier for maxillary tumor in other hospital by ENT specialist. In his medical file was noticed, that patient benefited for surgery by left maxillary curettage with resection of a mass in nasal cavity; the histopathological analysis for the specimen showed a fragmented friable greyish-white tumor, largest fragment measured 3cm. they concluded to an ulcerating ameloblastic tumor with infiltration of left maxillary sinus and left nasal cavity.

The CT scan at time (Figure1) showed a voluminous heterogenic tumor process of the left maxillary sinus compatible with ameloblastoma; the tumor measured 8.5×7×6cm with extension to the homolateral nasal cavity, and lyse of posterior maxillary wall without a clear extension to the infra temporal fossa.

The physical examination found an asymmetric face (Figure2), with trismus (maximum opening diameters: 20 mm), hypoesthesia of the left hemi face area, and left exophthalmos although there was no cervical lymphadenopathy, no facial palsy or other cranial nerve deficit.

A blondeau scan with 3D reconstruction was performed (Figure3.4) showed, a voluminous process of left maxillary sinus locally advanced, with calcification, central necrosis and extension to those following structure:

- Homolateral nasal cavity
- Homolateral orbit

- Infra temporal fossa
- Ethmoidal, frontal and sphenoidal sinus
- Alveolar maxillary process

Those result challenged us for the diagnosis of ameloblastoma, so we decide to reanalyzes the initial specimen by anatomopathological professor in our institution.

The histopathological analysis of two blocs includes in paraffin with hematoxylin eosin coloration (Figure5.6.7) showed malpighian mucus massively infiltrated by a tumoral proliferation agenced in lobuls, with spindle cells, inversed polarity, atypical nuclei and high mitotic index, also noted area of classical architecture for ameloblastoma concluding to ameloblastic carcinoma.

Other complementary test were done searching for metastasis including CT scan of chest was performed and showed no sign of metastasis.

Regarding the locally advanced stage of this ameloblastic carcinoma, especially the invasion of orbit and infratemporal fossa, we decide in a Multidisciplinary Consultation Meeting to refer the patient to oncological department for chemo radiotherapy.

The patient underwent 3 séances of chemotherapy with clinically decreasing in tumoral volume. The follow-up was essentially clinical every week for 2 month without questionnaire or pre-established scale.

The patient adhered well to the treatment received with a good tolerance to chemotherapy.

The patient was scheduled for chemoradiotherapy complications.

At the time of this report, the patient had been followed-up for four months; however he was lost of vu before undergoing radiotherapy.

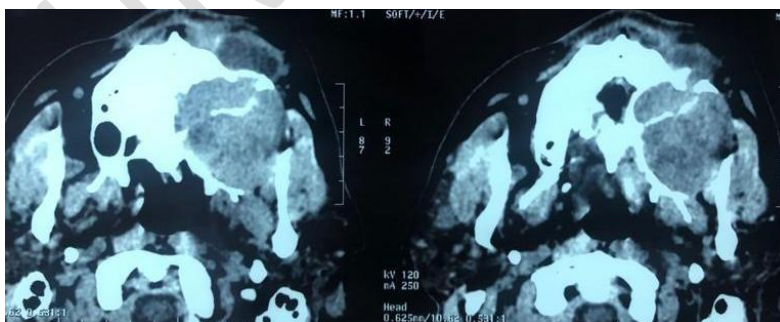


Figure 1: Axial CT scan showed voluminous mass of the left maxillary sinus

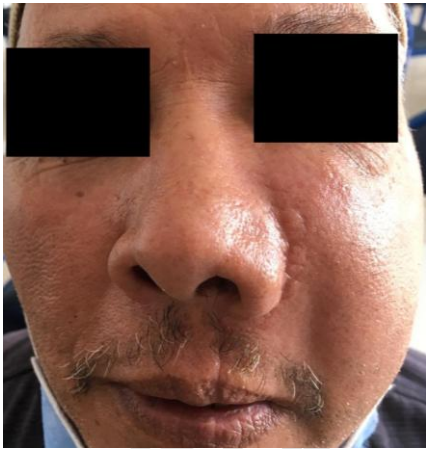

Figure 2: photo at presentation showed left hemi facial swelling.

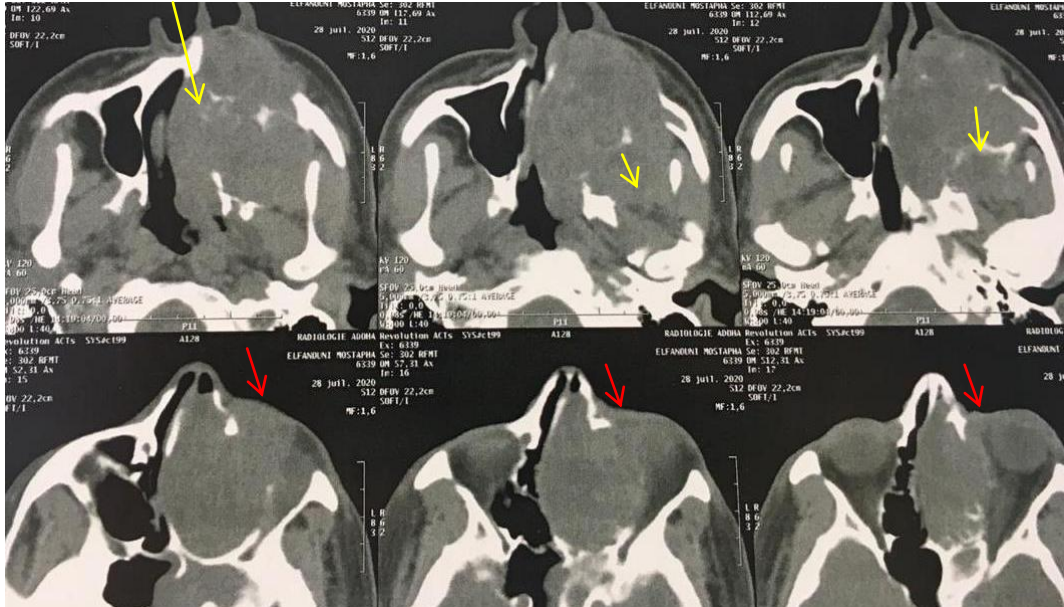


Figure 3: multiples CT scan images showed a heterogeneous multicystic mass with the invasion of: nasal cavity, infra temporal fossa (yellow arrow), orbit (red arrow)

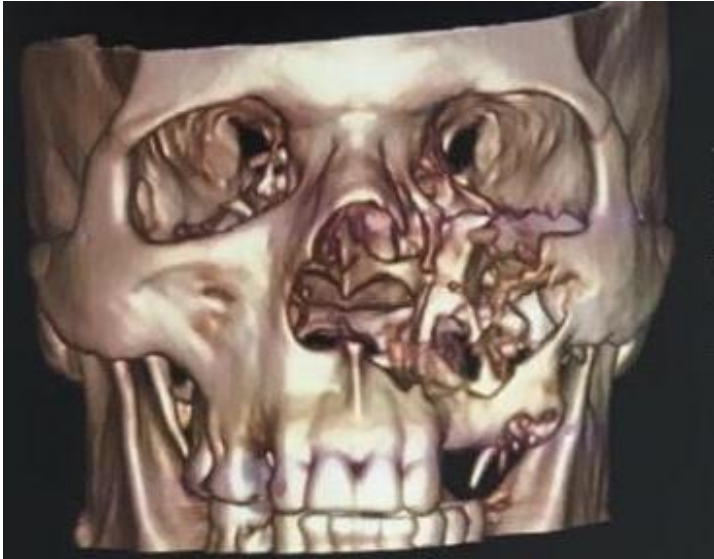

Figure 4: 3D reconstruction image showed, lyse of the anterior maxillary wall, orbital floor and maxillary alveolar process.

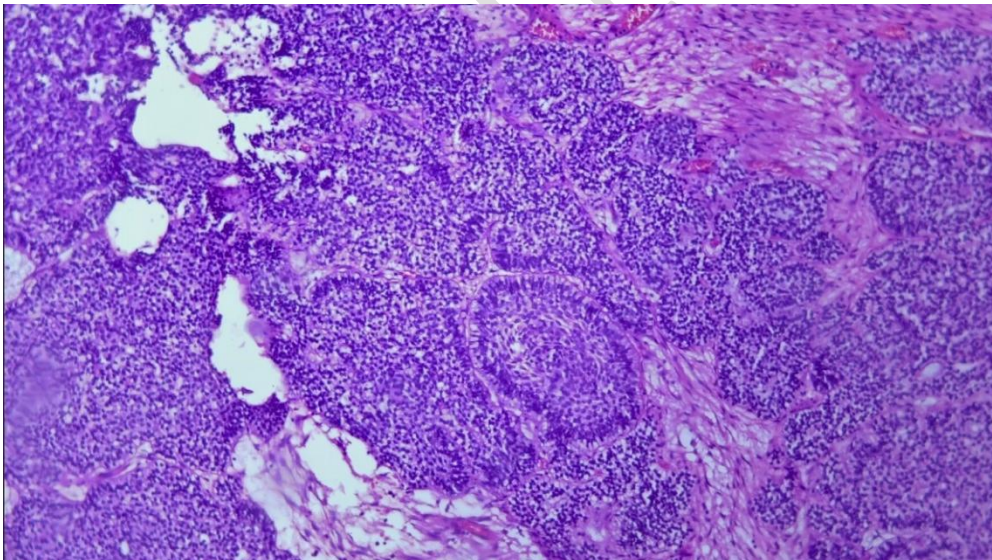


Figure 5: Hematoxylin eosin x 100 : Area of classical architecture of ameloblastoma ; peripheral basaloid layer and stellar reticulum-like central epithelium.

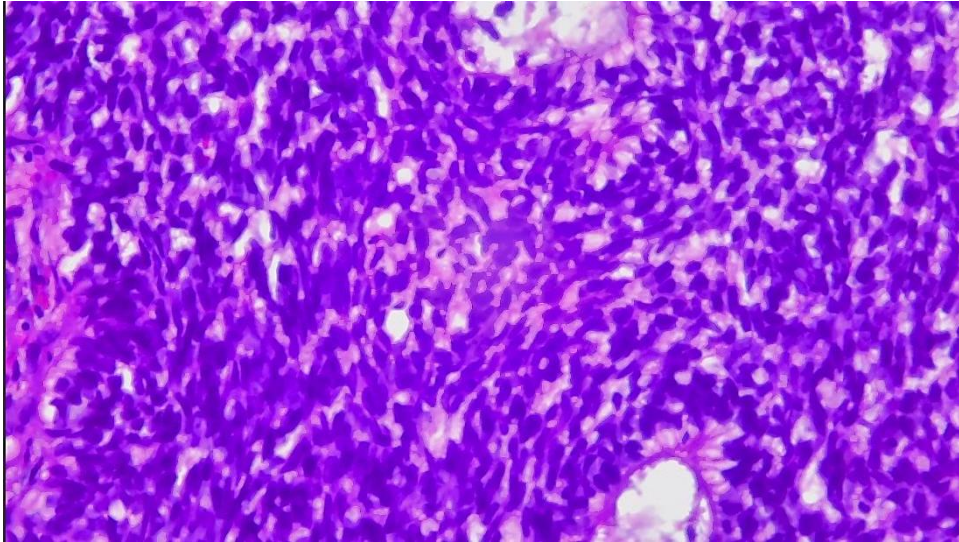


Figure 6: Hematoxylin eosin x 400 : Spindle cells with high grade features, hyperchromatism, atypical nuclei, and increased mitotic index,

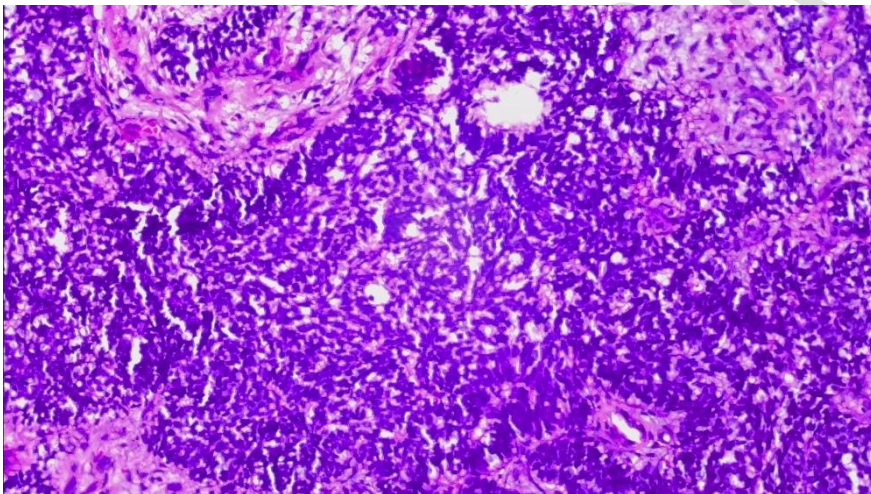


Figure 7: Hematoxylin eosin x 200 : Loss of architectural features of ameloblastoma : areas of spindle cells with loss of polarity.

Discussion:

Ameloblastoma is the commonest benign odontogenic tumor of the jaw, whereas ameloblastic carcinoma is a rare lesion, moreover maxillary sinus represent are very rare localization, with an overall of 26 cases reported in date (3).

The pathogenesis of ameloblastic carcinoma is controversial, with many genes being associated with malignant transformation; methylation of p16 in AC observed by Khojasteh et al. in 2013, mitochondrial apoptosis-inducing factors have been considered to play a role in malignant transformation in benign ameloblastomas (5,6).

The classification of odontogenic tumor is in general a hotly debated subject, many author suggested that is no needed to classify ameloblastic carcinoma as primary or secondary type (7–9), moreover the latest WHO 2017 classification of head and neck tumors (1) classify the ameloblastic carcinoma as single entity, leaving out any unproven references to histogenesis or precursor lesions.

The clinical presentation of ameloblastic carcinoma is variable, such as a cystic lesion with benign clinical features or a large tissue mass with ulceration, bone resorption, and tooth mobility. Painful swelling, cortical bone expansion with erosion and rapid growth are the most common presenting symptoms.

Ameloblastic carcinoma is 3 time more frequent in man than woman, it does not seem to show any age-group predilection. a median age of 56 years (mean 53 years, range 13–88 years) had been reported (10).

The radiographic appearance of the ameloblastic carcinomas described in the literature is generally consistent with that of ameloblastomas. Radiographic differential diagnosis of AC includes also odontogenic keratocyst, odontogenic myxoma, and calcifying epithelial odontogenic tumour (8).

CT is the most useful diagnostic imaging modality, demonstrating expansile, lytic, unilocular or multilocular cystic lesions with or without soft tissue extension. In addition to CT, MRI has been recommended in evaluation of patients with maxillary ameloblastoma, because of its potential to more precisely evaluate the soft tissue extent of the lesion (11) following those criteria, the CT scan image of our patient was in favor of ameloblastic carcinoma by showing

a multilocular cystic lesions with lytic potential and extension to soft tissues such as orbit and infra temporal fossa.

Histologically, the presence of sheets, islands, or trabeculae of epithelium and the absence or rare presence of stellate reticulum-like areas should alert the pathologist to the possibility of ameloblastic carcinoma. Round to spindle-shaped epithelial cells with little or no differentiation toward the columnar cells of ameloblastoma further suggest this malignant process. Moreover the presence many clear cells strongly suggests an ameloblastic carcinoma. Other malignancy criteria are important to diagnosis ameloblastic carcinoma such as hyperchromatism, large or atypical nuclei, increased mitotic index, necrosis, and calcification, and particularly neural and vascular invasion.

In our case, the neoplasm was initially diagnosed as an ameloblastoma; based on the earlier histological analysis; however, it was later proven to represent an ameloblastic carcinoma based on a histological re-evaluation.

The clinical course of ameloblastic carcinoma of maxilla is reported to be aggressive, with extensive local destruction, frequent recurrences and distant metastatic spread, when compared to mandibular counterparts (10,12). This criterion seems to be the major factor of prognosis, with preferentially a hematogenic spreading way.

When metastasis occurs, the favored site is the lung, followed by the cervical lymph nodes, brain and bony (12).

The treatment of choice for AC includes wide surgical resection with 2-3 cm of bony margins with or without cervical lymph node dissection (13,14). Radiotherapy and chemotherapy seem to be of limited value; however, many authors suggest that those methods need to be considered when there is a locally advanced or metastatic disease not amenable to surgical resection.

The radiotherapy may also be considered as a treatment option in incomplete resection cases (9,15,16).

The initial surgical approach was strongly associated with the risk of recurrence. Milman and al (10) showed in their cohort study that only (6.1 %) recurred of 33 patients managed with initial radical surgery as compared to (52 %) of 21 patients managed with limited surgery (excision with a narrow margin, enucleation or curettage).

Our patient was initially treated by maxillary curettage, which increased his chances for recurrence of ameloblastic carcinoma. In addition, he presented with an advanced stage that was inaccessible for radical surgery.

Ameloblastic carcinomas of the maxilla are aggressive odontogenic tumors. There is not yet a clear consensus on their management treatment, but there is a need for early detection, adequate and aggressive treatment to improve survival rate as well as the quality of life. We note the importance of a meticulous radiological and histological examination for ameloblastomas that appears with aggressive behavior in order to not misdiagnose an ameloblastic carcinoma.

UNDER PEER REVIEW

Ethical approval

I certify that this kind of manuscript does not require ethical approval by the Ethical Committee of our institution.

Consent

Written informed consent was obtained from the patient for publication of this case report and accompanying images. A copy of the written consent is available for review by the Editor-in-Chief of this journal on request.

Registration of research studies

This is a Case report that does not require a research registry.

References:

1. EI-Naggar AK., Chan J.K.C.G , Randis J..R , Takata T., Slootweg P. WHO Classification of Head and Neck Tumours (4th edition). Lyon; 2017.
2. Deng L, Wang R, Yang M, Li W, Zou L. Ameloblastic carcinoma: Clinicopathological analysis of 18 cases and a systematic review. *Head Neck*. 2019;41(12):4191–8. doi: 10.1002/hed.25926
3. Kruse AL, Zwahlen RA, Grätz KW. New classification of maxillary ameloblastic carcinoma based on an evidence-based literature review over the last 60 years. *Head Neck Oncol*. 2009 Dec;1(1):31. doi: 10.1186/1758-3284-1-31
4. Lee SK, Kim YS. Current concepts and occurrence of epithelial odontogenic tumors: I. Ameloblastoma and adenomatoid odontogenic tumor. *Korean. J Pathol* 2013;47(3):191–202. doi: 10.4132/KoreanJPathol.2013.47.3.191.
5. Khojasteh A, Khodayari A, Rahimi F, et al. Hypermethylation of p16 tumor-suppressor gene in ameloblastic carcinoma, ameloblastoma, and dental follicles. *J Oral Maxillofac Surg* 2013;71: 62-65. doi: 10.1016/j.joms.2012.04.033.
6. Kallianpur S, Jadwani S, Misra B, et al. Ameloblastic carcinoma of the mandible: Report of a case and review. *J Oral Maxillofac Surg Med Pathol* 2014; 18: 96. doi: 10.4103/0973-029X.141336
7. Hall JM, Weathers DR, Unni KK. Ameloblastic carcinoma: an analysis of 14 cases. *Oral Surg Oral Med Oral Pathol Oral Radiol Endod* 2007;103(6):799–807. doi: 10.1016/j.tripleo.2006.11.048

8. Kumaran PS, Anuradha V, Gokkulakrishnan S, Thambiah L, Jagadish AK, Satheesh G. Ameloblastic carcinoma: a case series. *J Pharm Bioallied Sci* 2014;6(Suppl1):S208–11. doi: 10.4103/0975-7406.137473
9. Chaisuparat R, Sawangarun W, Scheper MA. A clinicopathological study of malignant odontogenic tumours. *Histopathology* 2012;61(1):107–12. doi: 10.1111/j.1365-2559.2012.04200.x.
10. Milman T, Ying G-S, Pan W, LiVolsi V. Ameloblastoma: 25 Year Experience at a Single Institution. *Head Neck Pathol.* 2016 Dec;10(4):513–20. doi: 10.1007/s12105-016-0734-5
11. McClary AC, West RB, McClary AC, Pollack JR, Fischbein NJ, Holsinger CF, Sunwoo J, Colevas AD, Sirjani D. Ameloblastoma: a clinical review and trends in management. *Eur Arch Otorhinolaryngol.* 2015;. doi:10.1007/s00405-015-3631-8.
12. Dhir K, Sciubba J, Tufano RP. Ameloblastic carcinoma of the maxilla. *Oral Oncol.* 2003 Oct;39(7):736–41. doi: 10.1016/s1368-8375(03)00036-8.
13. Casaroto AR, Toledo GL, Toledo Filho JL, et al. Ameloblastic carcinoma, primary type: case report, immunohistochemical analysis and literature review. *Anticancer Res* 2012; 32: 1515-1525. URL:<https://ar.iarjournals.org/content/32/4/1515>
14. Avon SL, McComb J, Clokie C. Ameloblastic carcinoma: case report and literature review. *J Can Dent Assoc* 2003;69(9):573-6. URL: <http://www.cda-adc.ca/jcda/vol-69/issue-9/573.html>
15. França DC, Moreira JM, De Aguiar SM, et al. Ameloblastic carcinoma of the maxilla: A case report. *Oncol Lett* 2012; 4:1297-1300. doi: 10.3892/ol.2012.937
16. Kar IB, Subramanyam RV, Mishra N, et al. Ameloblastic carcinoma: A clinicopathologic dilemma – Report of two cases with total review of literature from 1984 to 2012. *Ann Maxillofac Surg* 2014; 4: 70. doi:10.4103/2231-0746.133070