

Case study

COMPLICATED PARASTOMAL HERNIA: IATROGENIC PERFORATION IN THE EFFERENT LOOP

ABSTRACT

BACKGROUND: The complication of a parastomal hernia is extremely rare. Only some perforation in the proximal colon of a colostomy have been previously reported. Moreover, the extraperitoneal approach is infrequent to the treatment of this type of hernias. We observed a case of perforation, whose etiology was probably iatrogenic, in the efferent loop of a right transverse colostomy.

CASE REPORT: A 62-years-old male who underwent a right transverse colostomy for a traumatic section of the colon 20 years ago, went to the Emergency Service for a subocclusive case. An incorrect management of a rectal catheter through the colostomy might have developed a perforation in the efferent loop of the colostomy. An extracavitary approach was made for avoid the midline dough to he presented a catastrophic abdomen because of previous surgeries. The relevance of this case report is based on the diagnostic difficulty, the hernia content, the possible associated iatrogenesis and the vital risk for the patient, as well as the treatment carried out.

DISCUSSION AND CONCLUSIONS: Parastomal hernia has an important prevalence and this condition implies high frequency to the Emergency Department. It is crucial to the current guidelines the use of prophylactic mesh in terminal stomas to prevent it. In addition, all sanitary personnel must know the basis management of a stoma to avoid possible iatrogenic complications. The peristomal approach during the surgery was critical to prevent a higher morbidity and mortality post intervention, being possible to make a right hemicolectomy through this way.

KEY WORDS: colostomy, parastomal hernia, iatrogenic perforation

1. INTRODUCTION

An ostomy is defined as the anastomosis between a segment of the gastrointestinal tract and the skin of the anterior abdominal wall ^[1]. Despite the fact that in the last years its prevalence has been reduced, the creation of an ostomy continues being a very common procedure in surgery, both in elective and emergency surgery. Mostly, stomas usually involving terminal ileum or distal colon, and they can be permanent or reversible. The most frequent indication is the surgical treatment of colorectal cancer ^[2]. Stomas have their own morbidity and mortality, although they rarely produce a vital emergency for the patient.

The principal complication after the generation of an ostomy is the appearance of a parastomal hernia ^[3]. Parastomal hernia is an incisional hernia of the abdominal wall that develops in the vicinity of a stoma and through its aponeurotic orifice ^[4]. The majority of parastomal hernias happened at least within the first 2 years since the ostomy was performed, however, some studies have reported that some parastomal hernias might happen after 20 years ^[4]. Other morbidity associated to a stoma varies between 21 and 70% and, before the hernia, the most frequent is the ischemia, skin irritation, retraction and prolapse ^[5]. Several studies unequivocally demonstrate that the incidence of the parastomal hernia is quite variable, which depends on multiple factors such as how is defined, type of stoma, patient characteristics and the follow-up measurements among other factors ^[5, 6]. European Hernia Society observed an incidence of parastomal hernia between 33 and 44% in 12 months follow-up, whereas the incidence increased to 58% after 7 years ^[6]. When other diagnostic methods were used such as the radiological technique, prevalence increased up to 78% ^[4]. There is no consistent evidence showing differences in the prevalence depending on the type of stoma because of there is no direct comparatives, although the scientific literature suggests higher incidence of parastomal hernia in patients with a terminal colostomy ^[6].

Here we describe a case of perforation, whose etiology was probably iatrogenic, in the efferent loop of a right transverse loop colostomy. Based on the all the aforementioned studies, the relevance of this case report is based on the diagnostic difficulty, the hernia content, the possible associated iatrogenesis and the vital risk for the patient, as well as the treatment carried out.

2. CASE REPORT

This case-report study included a 62-years-old male patient with a medical history of chronic obstructive pulmonary disease(COPD), Type 2 diabetes(T2D) and dyslipidemia. As for the surgical history, the patient suffered a traumatic section of the colon 20 years ago and in consequence, a left colostomy was performed. Subsequently, a reconstruction of the intestinal transit was attempted but the patient presented massive hemoperitoneum, requiring a new intervention and it was done a right transverse loop colostomy. For the following years, the patient was subdued to multiple interventions, a total of 7, in order to repair the abdominal wall without prosthesis, although we lack reports.

This patient arrived to the Emergency Department because of abdominal pain, vomiting and absence of stool emission due to the colostomy of several days of evolution. Upon examination, we targeted a catastrophic abdomen with multiple uncomplicated midline hernias and the presence of an incarcerated parastomal hernia that seemed to produce a subocclusive condition. Prior to our assessment, a nasogastric tube was placed at the Emergency Department and a rectal enema was applied using a Nelaton catheter by emergency nursing. The analytical data were normal, without organic dysfunction. An abdominal Computed Tomography(CT) scan was performed and it was identified the presence of the parastomal eventration with stenosis at the end of de afferent loop, near de hernia orifice, with dilation of the caecum of up to 9 centimeters located partially in the hernia sac. Moreover, it was described slight retrograde distension of small intestine(figure 1A and 1B).

Based on his medical antecedents and the radiological findings, he was hospitalized with the diagnosis of subocclusive process for surveillance, despite the fact that the patient had improved clinically and the evacuation of a small amount of liquid stool by the colostomy with the symptomatic treatment received in the Emergency Department.

After 24 hours and without tolerance to oral diet, the patient requested voluntary discharge. At 48 hours after voluntary discharge, he returned to the Emergency Department presenting significant decline in general condition and complete intolerance to oral diet due to incoercible vomiting. Upon examination, the abdomen was still bland but the parastomal hernia changed, being in that moment painful on palpation. In blood analysis, it showed frank worsening with an acute renal failure, leukocytosis with neutrophilia and elevation of the rest of acute phase reactants(C-reactive protein, procalcitonin). The patient was hospitalized

again, maintaining the suspicion of unsolved subocclusive condition, to continue with conservative treatment. A nasogastric tube was placed again and digestive rest was indicated. Nephrology assessment was requested for renal dysfunction of probable prerenal etiology, with 9 mg/dL creatinine.

During the next 48 hours the patient developed a torpid evolution, tending to hypotension and anuria. It was decided to repeat the abdominal CT scan to rule out the presence of new complications, comparing the results with the previous measurement. In the first CT scan, the caecum was interposed between the hernia sac and the peritoneal cavity (Fig. 1A and 1B), while in the second study, it was inside the sac, along with the rest of the ascending colon and the distal ileum. In addition, it described rarefaction of the fat next to the colic segment, adjacent to the stoma, forming an inflammatory plastron with apparent loss of wall continuity and presence of free gas that accumulates in the upper portion of the hernia sac (Figure 1C and 1D). These findings suggest a perforation in the end of the colostomy due to a possible necrosis of the colon near the stoma.

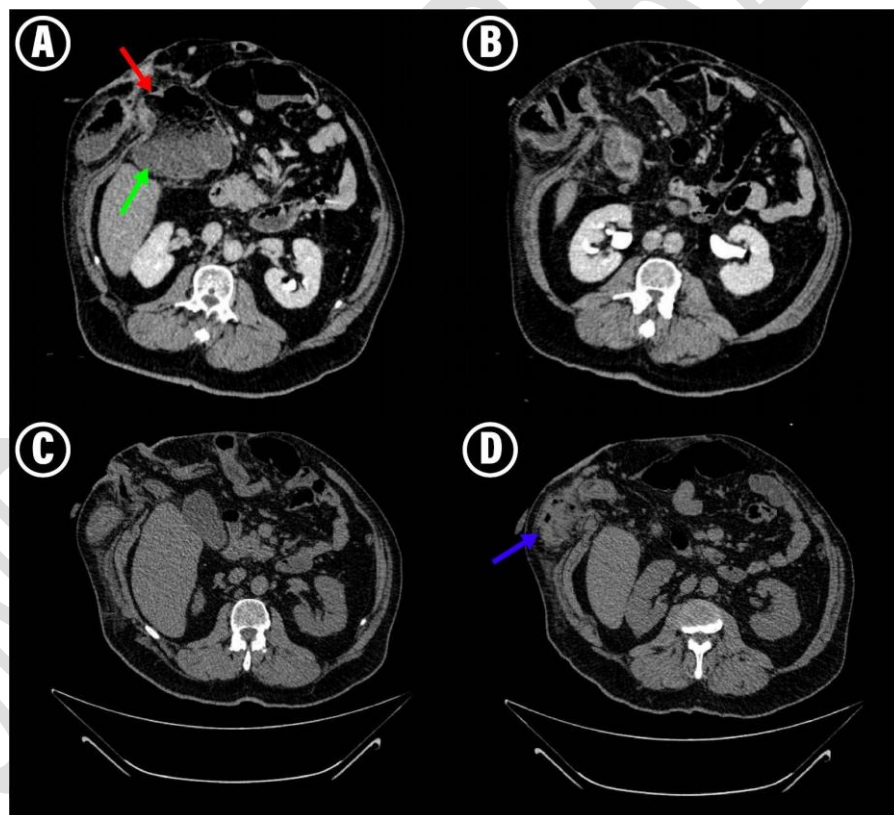


Figure 1. **A** and **B** are scan images from the first abdominal computed tomography (CT) scan showing non-complicated parastomal hernia with an important dilation of the caecum (green arrow) and a stenosis of the afferent loop (red arrow). **C** and **D** are from the second CT scan, performed 3 day later. Panel D shows the complicated hernia with presence of free gas in SCT and an important rarefaction of the fat (blue arrow)

Urgent surgery was performed using a peristomal approach, which consists in avoiding the midline because of the catastrophic condition of the abdomen with more than 10 wall defects. Without accessing to the abdominal cavity, the hernia sac was dissected from the subcutaneous cell tissues(SCT) until it reached the herniated orifice. Once externalized and isolated, it was safely opened without contaminating the abdominal cavity.

The sac contained the entire right colon, part of the transverse and some centimeters of the distal ileum(Fig. 2). A perforation of one centimeter in the efferent loop colostomy was found, with fecaloid material coming out through, causing necrotizing cellulitis of the right hypochondrium and flank SCT, and reaching the lumbar fossa.

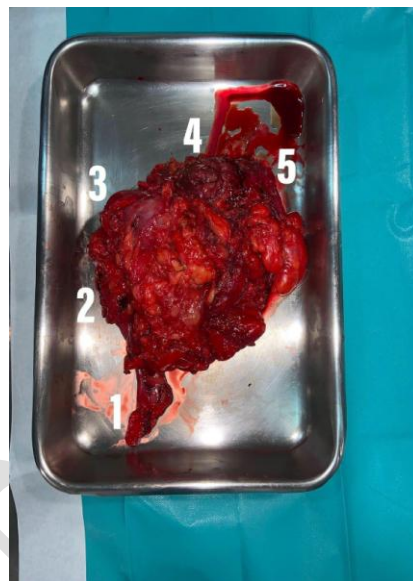


Figure 2. Surgical resection (1 cecal appendix, 2 ascending colon, 3 liver angle, 4 colostomy afferent loop, 5 efferent loop with drilling location)

Resection of all herniated content was conducted, performing right hemicolectomy with latero-lateral manual isoperistaltic anastomosis and making a definitive ileostomy in a healthy (infection free) area away from the defects of the wall. Also, a mucosal fistula was done in the transverse remnant. Abundant SCT washes were performed along with debridement of necrotic tissue. It was decided not to close the skin incision, placed a vacuum-assisted closure(VAC) system in SCT for reevaluated in 48 hours. In this period of time, the cellulite did not progress. The patient was checked in the operating room and there was no progression of devitalized tissue, so the VAC system was removed and a polypropylene macroporous mesh was put preaponeurotic fixed with a monofilament,

nonabsorbable polypropylene suture [4]. An aspiration drainage was placed in SCT of right flank.

After the surgical intervention, the patient entered to the Intensive Care Unit, where he presented a good evolution, being discharged after 5 days after an extubation without incidents and a progressive improvement of the analytical data, with decrease in the parameters of sepsis and a normalization of coagulation and renal function.

Once in hospitalization unit of Coloproctology, there was an episode of significant digestive bleeding through the ileostomy with a 2 - point - decrease in hemoglobin from his basal levels without other hemodynamic repercussions. An emergency endoscopy was performed, showing at the gastric level two ulcers with fibrin background (Grade III of the Forrest classification). It was also explored endoscopically through the ileostomy up to 35 centimeters, showing clots and traces of red blood that were aspirated without identifying other lesions or active bleeding points. Not finding clear source of bleeding, it was decided to perform an Angio CT scan that ruled out active bleeding. Surveillance was decided and the patient did not return to digestive bleeding, remaining stable and without further decreases in hemoglobin.

In the next days, the debit of the aspiration drain located in SCT turned purulent. After performing local cures and abundant washes every 12 hours, evolving satisfactorily with remission of local infection and without mesh reject, absence of signs of phlogosis and healthy granulation tissue. It also showed correct tolerance to oral diet and with good functioning of ileostomy and the rest of the vital functions.

3. DISCUSSION AND CONCLUSIONS

The colon drilling in the efferent loop of a colostomy constituted a vital emergency to our patient. It is an extremely rare complication and we did not find previous bibliographic references. After a meticulous analysis of the facts and their chronology, we came to the conclusion that it could be caused for an iatrogenic use of the rectal catheter through the stoma, prior to assessment by the Digestive Surgery staff.

Usually, the large intestine is a low mobile portion that does not generate hernia complications. In our case report, parastomal hernia contents totally the right colon included the caecum, the ascending colon, part of the transverse colon and some centimeters of the

distal ileum. Thanks to the 2 abdominal CT scans performed at the Hospital we observed a

UNDER PEER REVIEW

quick evolution of the hernia, which allow us to observe initially an important caecum dilation and, later, it was introduced in the hernia sac with others intestinal portions. This hernia progression could be explained by several factors: the high BMI of the individual, the presence of COPD, generalized weakness of the abdominal wall, and others factors present in that moment like a constipation / subocclusive episode, the latter might be the most probable cause of this case report study together with close by an excessive stomal manipulation.

The surgical approach selected was peristomal. It is something unusual and added more technical complexity. We thought it was the best approach because we avoided the midline what it had added to the surgery more morbidity and mortality. A massive adhesiolysis should have been carried out (with possible associated iatrogenesis), increase surgical time in a patient with a septic condition, as well as contamination of the abdominal cavity when the perforation was contained in the hernia sac, extracavitary. Through this approach, we managed to perform a right hemicolectomy, with the preparation of a terminal ileostomy in an accepted terrain and a wide debridement of the infected and necrotic SCT with success and without serious secondary postoperative complications.

The complications of a parastomal hernia are, generally rare and they do not usually constitute vital emergencies for the patient. However, the reference groups in the field suggest the use to perform a prophylaxis of the hernia with mesh when a permanent stoma is present ^[6]. We do not have previous reports of this patient, so we do not know the evolution time of the parastomal hernia. In this case, due to multiple risk factors for eventration like COPD, T2D, overweight, lack of integrity of the abdominal wall and the fact than the stoma was though like definitive without of reconstruction ^[4], the hernia prevention would have been indicated.

European Hernia Society Guide about the prevention and the treatment of the parastomal hernias recommend, with high evidence grade, to use prophylactic synthetic meshes, made with a non-absorbable material, in patients who need a terminal colostomy, regardless if he has associated risk factors to develop a parastomal hernia.

In the presence of a subocclusive or constipation case like this report, a correct management of the stoma from the first attention of the patient it is essential to avoid possible iatrogenic complications such as the one described in this case report. The inappropriate use of a rectal catheter in Emergency Department derived in a serious complication potentially fatal for our patient. It is necessary to train all health staff, especially

the nursing teams of both the Emergency and Primary Care Services, and the rest of the hospitalization units, in the proper management of stomas, given their high prevalence in the general population and the high morbidity associated that frequently require urgent or ambulatory care.

CONSENT FOR PUBLICATION

Informed written consent for publication was obtained from the patient prior to collecting data

REFERENCES

1. Cataldo PA. Technical tips for stoma creation in the challenging patient. *Clin Colon Rectal Surg.* 2008; 21:17
2. Mates IN, Gheorghe M, Tomsa R, Sumedrea EL. Paracolostomy evisceration: short review and new case report. *Chirurgia.* 2020; 115: 95-101
3. De Ruiter P, Bijnen AB. Successful local repair of paracolostomy hernia with a newly developed prosthetic device. *Int J Colorectal Dis.* 1992; 7:132
4. Morales-Conde S, Barreiro F, Hernández-Granados P, Feliu X. Cirugía de la pared abdominal. Guía clínica de la Asociación Española de Cirugía 2º Ed. Madrid: Arán; 2013
5. Basnayake, O., Jayarajah, U., et al. Spontaneous rupture of a parastomal hernia with evisceration of small bowel: a case report. *BMC Surgery.* 2019; 19:43
6. Antoniou, SA., Agresta, F. et al. European Hernia Society guidelines on prevention and treatment of parastomal hernias. *Hernia.* 2018; 22: 183 - 198
7. Doughty D. Principles of ostomy management in the oncology patient. *J Support Oncol.* 2005; 21:17

8. Whittaker M, Goligher JC. A comparison of the results of extraperitoneal and intraperitoneal techniques for construction of terminal iliac colostomies. *Dis Colon Rectum*. 1976; 19:342
9. Sha NR, Craft RO, Harold KL. Parastomal hernia repair. *Surg Clin North Am*. 2013; 93: 1185
10. Vonk-Klaassen SM, de Vocht HM, den Ouden ME, Eddes EH, Schuurmans MJ. Ostomy-related problems and their impact on quality of life of colorectal cancer ostomates: a systematic review. *Qual Life Res*. 2016; 25(1):125-33.
11. Malik T, Lee MJ, Harikrishnan AB. The incidence of stoma related morbidity - a systematic review of randomised controlled trials. *Ann R Coll Surg Engl*. 2018;100(7):501-508.
12. Duchesne JC, Wang YZ, Weintraub SL, Boyle M, Hunt JP. Stoma complications: a multivariate analysis. *Am Surg*. 2002; 68(11):961- 6; discussion 966.
13. Carne P, Robertson G, Frizelle F. Parastomal hernia. *Br J Journal*. 2003; 90(7): 784-793
14. Pilgrim CH, McIntyre R, Bailey M. Prospective audit of parastomal hernia: prevalence and associated comorbidities. *Dis Colon Rectum*. 2010; 53: 71-76
15. Jänes A, Cengiz Y, Israelsson LA. Randomized clinical trial of the use of a prosthetic mesh to prevent parastomal hernia. *Br J Surg*. 2004; 91: 280-282

UNDER PEER REVIEW