

## **Myocarditis Post COVID-19 Vaccine ;Case report**

### **Abstract:**

COVID-19 mRNA vaccines have serious side effects, including myocarditis; it's an uncommon but dangerous side effect following mRNA-based COVID-19 immunization. Herewith we report a 45-year-old female presenting with myocarditis seven days after the second dose of Pfizer-BioNTech vaccine, yet to recover three months later with guideline-directed medical treatment. COVID-19-associated myocarditis was evaluated and treated similarly to typical myocarditis with reduced ejection fraction heart failure, after exhausting other possible different etiologies. Here we illustrate various causes of myocarditis, contrasting diagnostic approaches, prognosis, and solidating management guidelines.

### **Introduction:**

Inflammation of the myocardium causes myocarditis, with associated necrosis and/or degeneration, frequently resulting from different infectious or non-infectious triggers <sup>(1)</sup>. The clinical presentation and course of myocarditis are variable, with some patients not requiring therapy. In contrast, others are afflicted with serious cardiac failure necessitating a heart transplant or leading to Death <sup>(2)</sup>. Most myocarditis findings demonstrate a male preponderance and a median age of 42 for individuals with lymphocytic myocarditis <sup>(3,4,5,6)</sup>. The etiology of myocarditis often remains undetermined; many infectious agents, systemic diseases, drugs, and toxins can cause the condition <sup>(7)</sup>. COVID-19 mRNA vaccines, including Pfizer- BioNTech and Moderna, have serious side effects, including myocarditis. Myocarditis is an uncommon but dangerous side effect, especially in teenage and young men following mRNA-based COVID-19 immunization <sup>(8)</sup>. COVID-19 vaccine-associated myocarditis cases were first evaluated and treated similarly to typical myocarditis cases. Supportive care was a cornerstone of treatment

with particular cardiac or critical care treatments, indicated by the patient's clinical status<sup>(9,10,11)</sup>.

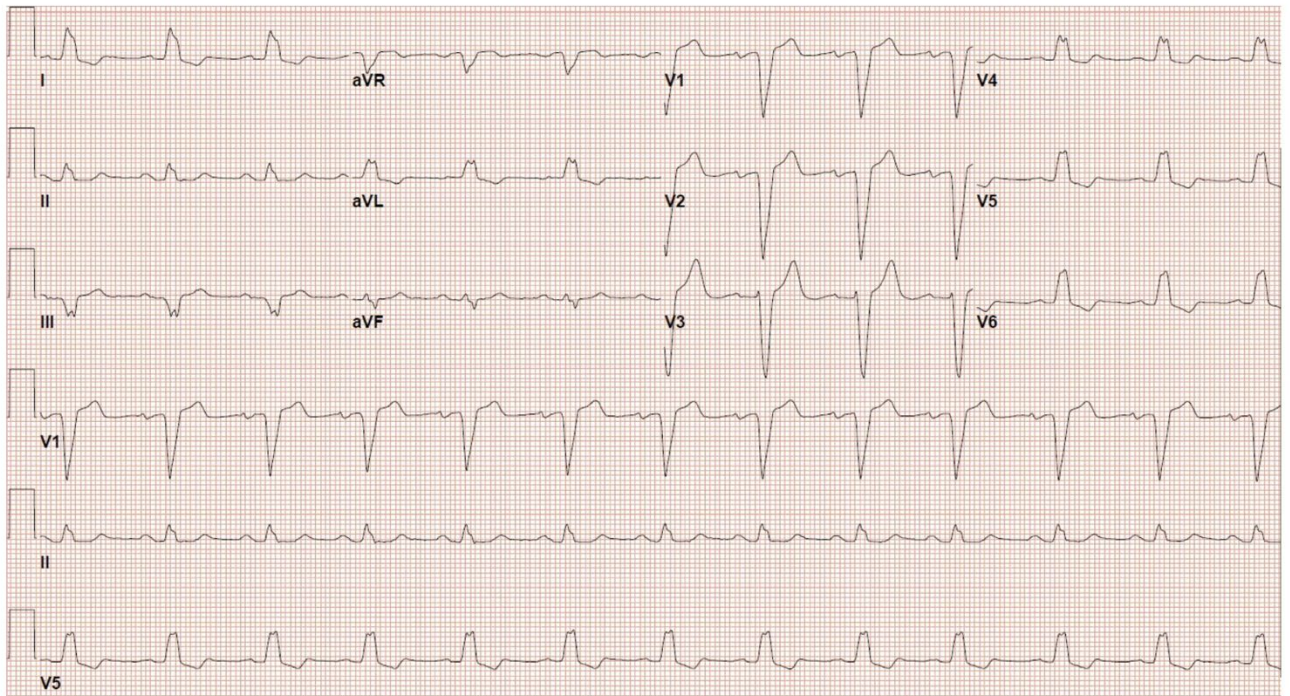
### **Case report:**

45-year-old female medically free, presented to the outpatient cardiology clinic, with palpitation and dyspnea for three months, worsened for which she sought medical attention. These symptoms were associated with orthopnea, abdominal distention, and lower limb swelling. However, she denied chest pain. These symptoms and signs were noticed after receiving the second dose Pfizer COVID-19 vaccine. The collection of symptoms and signs necessitated urgent admission for further workup and optimal medical care. Her vital signs revealed Blood pressure of 102/73 mmHg, heart rate of 84 beats per minute, regular respiratory rate, temperature, and O<sub>2</sub> saturation of 97% on room air; the rest of the physical examination was unremarkable, apart from mild inspiratory fine crackles at the bases of lungs, and bilateral lower limb edema. Electrocardiogram (ECG) (figure 1) showed normal sinus rhythm, with left bundle branch block, while Echocardiogram reported severely dilated cardiomyopathy.

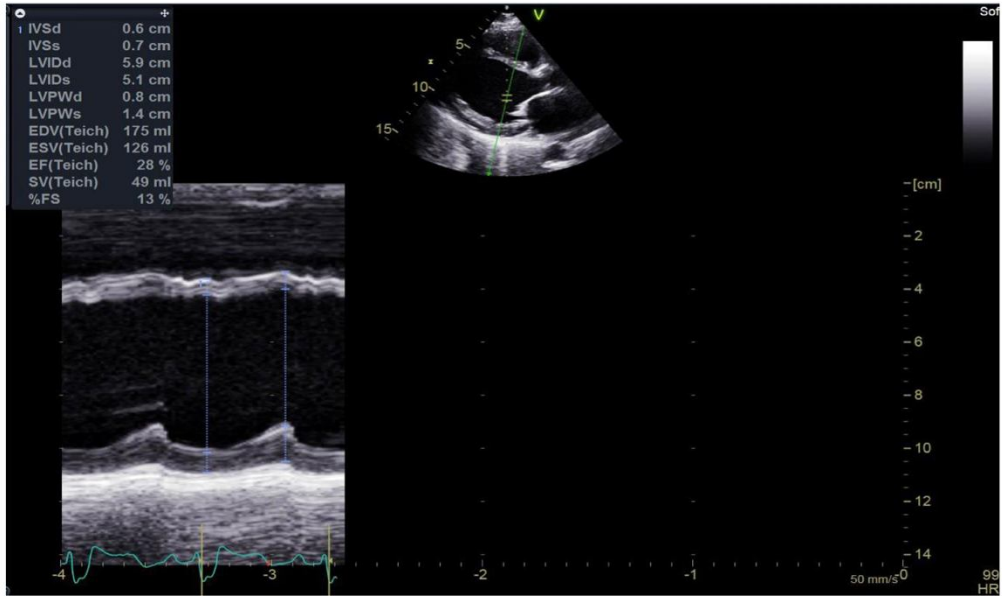
(Figure 2A) with an Ejection fraction of 28%, diastolic dysfunction, moderate mitral insufficiency, severe tricuspid insufficiency, and severe pulmonary hypertension. Laboratory panel, including cardiac markers, thyroid function, complete cell count, renal function, electrolytes, connective tissue work-up, and viral serology within normal limits. BNP 791.4 m/mol

Myocardial perfusion imaging was done to exclude the possibility of ischemia-induced cardiomyopathy. There was no evidence of stress-induced ischemia. However, both post-stress and rest scans showed significantly reduced left ventricular function with global hypokinesia and dilated cardiac cavity (figure 3). Delayed Myocardial enhancement was reported on Cardiac MRI (CMR), validating the diagnosis of myocarditis. Heart failure with reduced ejection fraction (HF-rEF) guidelines directed medical therapy (GDMT) was initiated achieving symptom control and a euvolemic state with an intravenous diuretic.

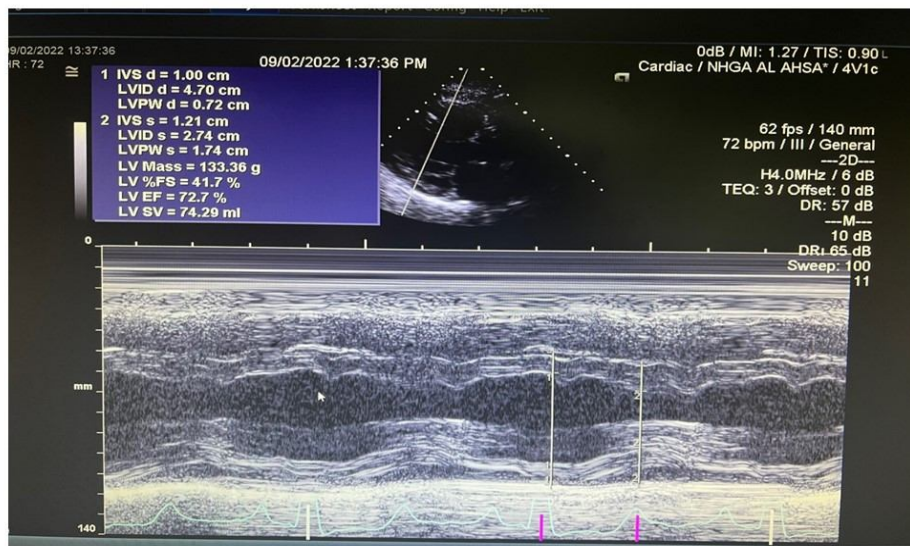
The patient dramatically improved clinically and was discharged home, and was seen on regular bases as an outpatient, with close monitoring of GDMT regimen, renal, and electrolyte status. She responded favorably to treatment, and a follow-up Echocardiogram three months later showed restoration of Left ventricular size, function, and valvular lesions (figure 2B). She is continued on Heart failure with a preserved ejection fraction (HF-pEF) regimen.



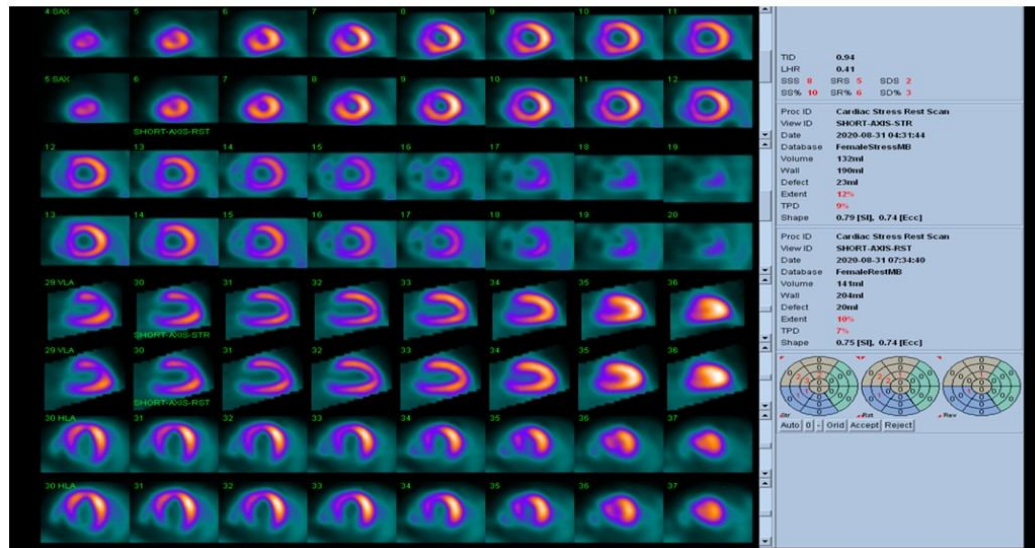
**Figure 1:** ECG, with NSR and LBBB/LAD.



**Figure 2A:** M-mode across the LV, Dilated LV with reduced EF.



**Figure 2B:** M-Mode across the LV; Normal LV dimension with normal EF.



**Figure 3:** Myocardial perfusion study; dilated LV in rest and post stress images, no perfusion defect.

### **Discussion:**

In 1995, myocarditis was defined by the World Health Organization (WHO)/International Society and Federation of Cardiology (ISFC) as an inflammatory disease of the heart muscle, diagnosed by established histological, immunological, and immunohistochemical criteria <sup>(12)</sup>. The clinical manifestation of myocarditis varies with a broad spectrum of symptoms ranging from asymptomatic courses to presentations with signs of myocardial infarction to devastating illness with cardiogenic shock. Chest pain, cardiac arrhythmias, and acute or chronic heart failure (HF) can occur during the disease <sup>(13)</sup>. Our patient came with acute heart failure presentation in the form of orthopnea, ascites, and lower limb swelling.

Various causes such as infectious agents, systemic diseases, drugs, and toxins can be the etiology of myocarditis. Viral myocarditis is often considered when accompanied by a clinical picture of recent febrile illness, often with prominent myalgias, followed by rapid onset of cardiac symptoms <sup>(14)</sup>.

Numerous published studies of myocarditis following COVID-19 mRNA vaccinations

(Pfizer-BioNTech, Comirnaty, Moderna Spikevax) have demonstrated that these events typically present as chest pain, fever, or shortness of breath in adolescent and young adult males, within two to seven days after their second dose. Up to and including March 4, 2022, there were 1,886 reports of myocarditis/pericarditis to the Public Health Agency of Canada and Health Canada. Of these reported cases, 1,192 occurred following a Pfizer-BioNTech Comirnaty COVID-19 vaccine for a reporting rate of 2.18 events per 100,000 administered doses. (15,16,17).

Our patient started to have the symptoms after the second dose of the Pfizer-BioNTech vaccine by seven days which is like the most published studies.

Cardiotropic viruses such as enteroviruses (specifically Coxsackie group B) may cause direct cardiotoxic injuries, cytokine activation, cytoskeletal damage, and autoimmune responses <sup>(7)</sup>. HIV disease has been recognized as a fundamental cause of DCM, with an estimated incidence of 1.6%. HIV type 1 (HIV-1) virus infects myocardial cells in a patchy distribution, leading to cytokine activation and progressive tissue damage <sup>(18)</sup>. Giant cell myocarditis (GCM) is a rare disorder of unknown etiology. GCM often presents with an aggressive clinical course, progressing over days to weeks. Rapidly progressive heart failure is observed in 75% of affected patients <sup>(5)</sup>.

Eosinophilic endomyocardial disease (i.e., Loeffler endomyocardial fibrosis) is a significant complication of idiopathic hypereosinophilic syndrome due to direct toxic damage caused by eosinophil granule proteins within the heart <sup>(19)</sup>. Systemic autoimmune disorders such as sarcoidosis, systemic lupus erythematosus, or polymyositis causes of myocarditis often respond poorly to medical therapy and cardiac transplantation, and their prognoses are often unfavorable <sup>(14)</sup>. Immune checkpoint inhibitor side-induced myocarditis is a common cardiovascular side effect, with an approximate incidence of 1.9% amongst patients treated and a median onset of 34 days after starting ICI <sup>(20)</sup>.

Leukocytosis is a common inflammatory marker of myocarditis (often lymphocytic), although the presence of eosinophilia may suggest hypersensitivity (eosinophilic) myocarditis <sup>(1)</sup>. Elevated acute phase reactants such as erythrocyte sedimentation rates or ultrasensitive C-reactive protein are good monitors of clinical progression or response to therapy. Still, they have low specificity for myocarditis <sup>(21)</sup>. Cardiac troponins, creatine kinase, and myoglobin levels are

elevated in many cases of acute myocarditis; however, cardiac markers and enzymes are not specific for cardiac inflammatory processes. Highly elevated cardiac markers and enzymes may help rule in acute cases, but their absence does not exclude myocarditis<sup>(22,23)</sup>. Rheumatologic screening to send for antinuclear antibodies and rheumatoid factor is indicated if clinically suspected systemic lupus erythematosus, Polymyositis, Wegener granulomatosis, or Scleroderma<sup>(24)</sup>. A blood workup screening was ordered for our patient for all suspected viral infections and autoimmune diseases, which returned negative. Inflammatory and cardiac markers were standard as well.

A 12-lead ECG should be performed in all patients with clinically suspected myocarditis. The sensitivity of the ECG for myocarditis is low (approximately 47%). The ECG often reveals sinus tachycardia, although the presence of non-specific ST-segment and T-wave abnormalities may represent focal or global ischemia<sup>(1,24)</sup>. All patients with clinically suspected myocarditis should undergo a standard transthoracic echocardiogram at presentation to exclude alternative causes of heart failure, detect the presence of intracardiac thrombi and associated valvular disease, and quantify the degree of left ventricular (LV) dysfunction to monitor response to therapy. It should be repeated during hospitalization if there is a worsening of the patient's hemodynamic status<sup>(7,25)</sup>. Nuclear imaging antimyosin scintigraphy (indium III monoclonal antimyosin antibody) facilitates the identification of myocardial inflammation with high sensitivity of 91% and negative predictive value of 93%; however, low specificity (32%)<sup>(7)</sup>.

Our patient's ECG upon diagnosis showed normal sinus rhythm, with left bundle branch block. At the same time, Echocardiogram reported severely dilated cardiomyopathy (figure 2A) with an Ejection fraction of 28%, diastolic dysfunction, moderate mitral insufficiency, severe tricuspid insufficiency, and severe pulmonary hypertension. Myocardial perfusion imaging was done to exclude the possibility of ischemia-induced cardiomyopathy. There was no evidence of stress-induced ischemia. However, both post-stress and rest scans showed significantly reduced left ventricular function with global hypokinesia and dilated cardiac cavity (figure 3).

Coronary angiography is often indicated to rule out coronary artery disease as the cause of new-onset heart failure because the clinical presentation of myocarditis may mimic myocardial infarction (i.e.pseudoinfarct pattern), especially if there are focal wall motion abnormalities and

localizing electrocardiographic changes <sup>(24)</sup>. CMR imaging has evolved as a non-invasive tool to support the diagnosis of myocarditis as recommended by the American Heart Association scientific statement as Class IIB, level of evidence C <sup>(26)</sup>, which was conducted in our patient and supported myocarditis as a primary diagnosis and cause of patient's presentation. Endomyocardial biopsy (EMB) is not a routine practice. Still, it remains the gold standard in diagnosing myocarditis, identifying the underlying etiology and the type of inflammation (e.g., giant cell, eosinophilic myocarditis, sarcoidosis). Results frequently impact the therapy of the patient <sup>(4)</sup>. EMB should be considered in patients with rapid deterioration of the cardiac function of unknown etiology who do not respond to standard medical therapy <sup>(7)</sup>. EMB was not considered in our patient as her clinical condition improved, and she responded to treatment.

The outcome and prognosis of myocarditis depend solely on etiology, clinical presentation, and disease stage. Patients are usually advised to abstain from vigorous exercise for up to six months or longer after the onset of symptoms, so exercise restriction during the acute phase of myocarditis is recommended. The length of activity restriction can be based on the recovery of LV function. However, the duration of abstinence from competitive sports after recovery from acute myocarditis is still a matter of debate <sup>(27)</sup>.

Patients who present with myocarditis with acute dilated cardiomyopathy should be treated according to the current guidelines of the American Heart Association, the American College of Cardiology, and the European Society of Cardiology. Standard heart failure therapy consists of diuretics, angiotensin-converting enzyme inhibitors, b blockers, and aldosterone antagonists <sup>(9)</sup>. Anticoagulation to prevent thromboembolic events is usually recommended in patients with apical aneurysms with thrombus (e.g., Chagas disease, atrial fibrillation, and prior embolic episodes) <sup>(28)</sup>. For arrhythmia management, the first-line therapy consists of b-blockers, amiodarone, and sotalol. Permanent pacemakers are used for heart block or bradyarrhythmia <sup>(29)</sup>. The insertion of implantable cardioverter-defibrillators (ICDs) is indicated for patients in the chronic phase with persistently low ejection fraction and those with malignant arrhythmias that are refractory to medical therapy. Cardiac resynchronization therapy with defibrillator function is indicated for patients with impaired LV function (ejection fraction  $\leq$  35%) and left bundle branch block in New York Heart Association (NYHA) functional class II-IV <sup>(9)</sup>.

In cardiogenic shock due to acute myocarditis, particularly in fulminant myocarditis, where the hemodynamic status of the patient is severely compromised, inotropic therapy with milrinone, dobutamine, or mechanical circulatory support, including extracorporeal membrane oxygenation (ECMO) or mechanical assist devices (LV assist devices) for hemodynamic support and afterload reduction may provide a bridge to transplant or recovery <sup>(27)</sup>.

The large majority of patients with myocarditis will recover entirely. The prognosis of patients with myocarditis depends on a series of factors such as clinical presentation, clinical parameters, and EMB findings. Patients with acute myocarditis and preserved LV function have a good prognosis with a high rate of spontaneous improvement <sup>(13)</sup>. In clinical practice, the current myocarditis guidelines recommend discharging patients when cardiac markers have normalized. High-risk patients may be observed slightly longer and followed as outpatients in shorter intervals, as we have recently shown that disease activity may continue despite normalization of cardiac marker <sup>(30)</sup>. One- to three-month clinical follow-up examinations are recommended after diagnosis to adjust standard heart failure medication. Serial echocardiographic assessment of ventricular structure and function is often performed, although there are no definitive guidelines regarding the required intervals of echocardiographic estimates after myocarditis <sup>(9,24,27)</sup>. Our case improved clinically and was seen on regular out-patient follow-up, closely monitoring GDMT regimen, renal, and electrolyte status.

### **Conclusion**

COVID-19 mRNA vaccinations (Pfizer-BioNTech, Comirnaty, Moderna, and Spikevax) have demonstrated myocarditis as an apparent side effect, with profound heart failure symptoms

and signs. Most of these patients with myocarditis recover completely. While the outcome and prognosis of myocarditis depend solely on etiology, clinical presentation, and disease stage, adopting Heart failure reduced ejection fraction management guidelines substantially impacts myocarditis outcomes. This case adds another case of COVID-10 myocarditis to the literature, with complete restoration of Left ventricular size, function, and valvular lesions after three months of treatment.

### **CONSENT**

Written informed consent was obtained from the patient for publication.

### **ETHICAL APPROVAL**

The study was approved by King Abdullah International Medical Research Center (KAIMRC) .

### **References:**

1. Cooper LT Jr. Myocarditis. *N Engl J Med.* 2009;360(15):1526-1538. doi:10.1056/NEJMra0800028
2. Dasgupta S, Iannucci G, Mao C, Clabby M, Oster ME. Myocarditis in the pediatric population: A review. *Congenit Heart Dis.* 2019;14(5):868-877. doi:10.1111/chd.12835
3. Caforio AL, Calabrese F, Angelini A, et al. A prospective study of biopsy-proven myocarditis: prognostic relevance of clinical and aetiopathogenetic features at diagnosis. *Eur Heart J.* 2007;28(11):1326-1333. doi:10.1093/eurheartj/ehm076
4. Magnani JW, Danik HJ, Dec GW Jr, DiSalvo TG. Survival in biopsy-proven myocarditis: a long-term retrospective analysis of the histopathologic, clinical, and hemodynamic predictors. *Am Heart J.* 2006;151(2):463-470. doi:10.1016/j.ahj.2005.03.037
5. Cooper LT Jr, Berry GJ, Shabetai R. Idiopathic giant-cell myocarditis--natural history and treatment. Multicenter Giant Cell Myocarditis Study Group Investigators. *N Engl J Med.* 1997;336(26):1860-1866. doi:10.1056/NEJM199706263362603
6. Kyto V, Saukko P, Lignitz E, et al. Diagnosis and presentation of fatal myocarditis.

Hum Pathol 2005;36:1003–1007.

7. Caforio AL, Pankuweit S, Arbustini E, et al. Current state of knowledge on aetiology, diagnosis, management, and therapy of myocarditis: a position statement of the European Society of Cardiology Working Group on Myocardial and Pericardial Diseases. *Eur Heart J*. 2013;34(33):2636-2648d. doi:10.1093/eurheartj/eh210
8. Oster ME, Shay DK, Su JR, et al. Myocarditis Cases Reported After mRNA-Based COVID-19 Vaccination in the US From December 2020 to August 2021. *JAMA*. 2022;327(4):331-340. doi:10.1001/jama.2021.24110
9. Yancy CW, Jessup M, Bozkurt B, et al. 2013 ACCF/AHA guideline for the management of heart failure: a report of the American College of Cardiology Foundation/American Heart Association Task Force on Practice Guidelines. *J Am Coll Cardiol*. 2013;62(16):e147-e239. doi:10.1016/j.jacc.2013.05.019
10. Law YM, Lal AK, Chen S, et al. Diagnosis and Management of Myocarditis in Children: A Scientific Statement From the American Heart Association [published correction appears in *Circulation*. 2021 Aug 10;144(6):e149]. *Circulation*. 2021;144(6):e123-e135. doi:10.1161/CIR.0000000000001001
11. US Centers for Disease Control and Prevention. Clinical considerations: myocarditis and pericarditis after receipt of mRNA COVID-19 vaccines among adolescents and young adults. Accessed August 24, 2021. <https://www.cdc.gov/vaccines/covid-19/clinical-considerations/myocarditis.html>
12. Richardson P, McKenna W, Bristow M, et al. Report of the 1995 World Health Organization/International Society and Federation of Cardiology Task Force on the Definition and Classification of cardiomyopathies. *Circulation*. 1996;93(5):841-842. doi:10.1161/01.cir.93.5.841
13. Kindermann I, Kindermann M, Kandolf R, et al. Predictors of outcome in patients with suspected myocarditis [published correction appears in *Circulation*. 2008 Sep 16;118(12):e493]. *Circulation*. 2008;118(6):639-648. doi:10.1161/CIRCULATIONAHA.108.769489
14. Rroku A, Kottwitz J, Heidecker B. Update on myocarditis - what we know so far and where we may be heading [published online ahead of print, 2020 Apr 22]. *Eur Heart J Acute Cardiovasc Care*. 2020;2048872620910109. doi:10.1177/2048872620910109
15. Shay DK, Shimabukuro T, DeStefano F. Myocarditis occurring after immunization with mRNA-based COVID-19 vaccines.
16. Jain SS, Steele JM, Fonseca B, Huang S, Shah S, Maskatia SA et al. COVID-19 Vaccination–Associated Myocarditis in Adolescents.
17. Government of Canada. COVID-19 vaccine safety in Canada [Internet]. Ottawa, ON: Government of Canada; 2022 [2022 Mar 13].
18. Heymans S, Eriksson U, Lehtonen J, Cooper LT Jr. The Quest for New Approaches in Myocarditis and Inflammatory Cardiomyopathy. *J Am Coll Cardiol*. 2016;68(21):2348-2364. doi:10.1016/j.jacc.2016.09.937
19. Kindermann I, Barth C, Mahfoud F, et al. Update on myocarditis. *J Am Coll Cardiol*. 2012;59(9):779-792. doi:10.1016/j.jacc.2011.09.074

20. Mahmood SS, Fradley MG, Cohen JV, et al. Myocarditis in Patients Treated With Immune Checkpoint Inhibitors. *J Am Coll Cardiol.* 2018;71(16):1755-1764. doi:10.1016/j.jacc.2018.02.037
21. Ekström K, Lehtonen J, Kandolin R, Räisänen-Sokolowski A, Salmenkivi K, Kupari M. Long-term outcome and its predictors in giant cell myocarditis. *Eur J Heart Fail.* 2016;18(12):1452-1458. doi:10.1002/ejhf.606
22. Lauer B, Niederau C, Köhl U, et al. Cardiac troponin T in patients with clinically suspected myocarditis. *J Am Coll Cardiol.* 1997;30(5):1354-1359. doi:10.1016/s0735-1097(97)00317-3
23. Smith SC, Ladenson JH, Mason JW, Jaffe AS. Elevations of cardiac troponin I associated with myocarditis. Experimental and clinical correlates. *Circulation.* 1997;95(1):163-168.
24. Fung G, Luo H, Qiu Y, Yang D, McManus B. Myocarditis. *Circ Res.* 2016;118(3):496-514. doi:10.1161/CIRCRESAHA.115.306573
25. Felker GM, Boehmer JP, Hruban RH, et al. Echocardiographic findings in fulminant and acute myocarditis. *J Am Coll Cardiol.* 2000;36(1):227-232. doi:10.1016/s0735-1097(00)00690-2
26. Mahrholdt H, Wagner A, Deluigi CC, et al. Presentation, patterns of myocardial damage, and clinical course of viral myocarditis. *Circulation.* 2006;114(15):1581-1590. doi:10.1161/CIRCULATIONAHA.105.606509
27. Kindermann I, Barth C, Mahfoud F, et al. Update on myocarditis. *J Am Coll Cardiol.* 2012;59(9):779-792. doi:10.1016/j.jacc.2011.09.074
28. Makrides CA. Resolution of left ventricular postinfarction thrombi in patients undergoing percutaneous coronary intervention using rivaroxaban in addition to dual antiplatelet therapy. *BMJ Case Rep.* 2016;2016:bcr2016217843. Published 2016 Oct 26. doi:10.1136/bcr-2016-217843
29. Farinha IT, Miranda JO. Myocarditis in Paediatric Patients: Unveiling the Progression to Dilated Cardiomyopathy and Heart Failure. *J Cardiovasc Dev Dis.* 2016;3(4):31. Published 2016 Nov 8. doi:10.3390/jcdd3040031
30. Berg J, Kottwitz J, Baltensperger N, et al. Cardiac Magnetic Resonance Imaging in Myocarditis Reveals Persistent Disease Activity Despite Normalization of Cardiac Enzymes and Inflammatory Parameters at 3-Month Follow-Up. *Circ Heart Fail.* 2017;10(11):e004262. doi:10.1161/CIRCHEARTFAILURE.117.004262

UNDER PEER REVIEW