

**Recurrent Kounis Syndrome due to Amoxicillin induced anaphylaxis: *A case report*****Abstract**

Kounis syndrome is the occurrence of Acute Coronary Syndrome during an allergic, anaphylactoid or anaphylactic reaction. It is thought to be due to the mast cell activation and degranulation. Patients can present with features of Acute coronary syndrome during or after a hypersensitivity reaction.

Here we report a case of a 60-year-old gentleman presenting with fascial swelling, rash, shortness of breath associated with severe tightening left sided chest pain and dizziness. This occurred 5 minutes after taking Amoxicillin. Serial ECGs taken showed dynamic ischemic changes with a rising Troponin I titer. He was subsequently managed for both the anaphylaxis and the non-ST elevation myocardial infarction. Subsequent history revealed that he had a similar episode following Amoxicillin four years ago.

This case report highlights the importance identifying Kounis Syndrome as an important differential diagnosis amongst patients presenting with chest pain. This syndrome which can be easily diagnosed clinically if missed can lead to mismanagement of a relatively easily treatable cause of acute coronary syndrome.

**Keywords**

Kounis syndrome, coronary vasospasm, acute coronary syndrome, anaphylaxis, amoxicillin

## Introduction

Kounis Syndrome is the concurrence of acute coronary syndrome with conditions associated with mast cell activation, such as allergies or hypersensitivity and anaphylactic or anaphylactoid insults [1]. Since its first description in 1991, it has been extensively studied and expanded. Three variants have been described with different pathophysiology: Due to coronary vasospasm (Type 1), plaque erosion and rupture (Type 2) and stent thrombosis with histological infiltration by eosinophils and mast cells of the thrombus (Type 3) [2].

Recognizing this syndrome as a separate clinical entity is crucial in clinical practice as it has a unique management. Certain drugs used in Acute coronary syndrome such as Beta blockers may be harmful in Kounis Syndrome.

This case report aims to highlight the importance of early recognition of this syndrome amongst patients presenting with chest pain. To the best of our knowledge, recurrent acute coronary syndrome due to Kounis syndrome due to the same agent is very limited in literature.

## Case Report

A 60-year-old male presented with sudden onset rash, swelling of face and lips five minutes after taking amoxicillin for an infected wound. He also complained of an ischemic type of chest pain. He had a 30-pack year smoking history and regular alcohol consumption but no other vascular risk factors. He had a similar episode four years back where he developed chest pain and a rash few minutes after taking amoxicillin. He had documented ECG changes suggestive of an ischemic event during the previous episode. He has no history of other allergies.

On examination he had fascial and lip swelling with a generalized erythematous rash. He had bilateral rhonchi on auscultation. His blood pressure was 90/60 and had a tachycardia of 110 bpm.

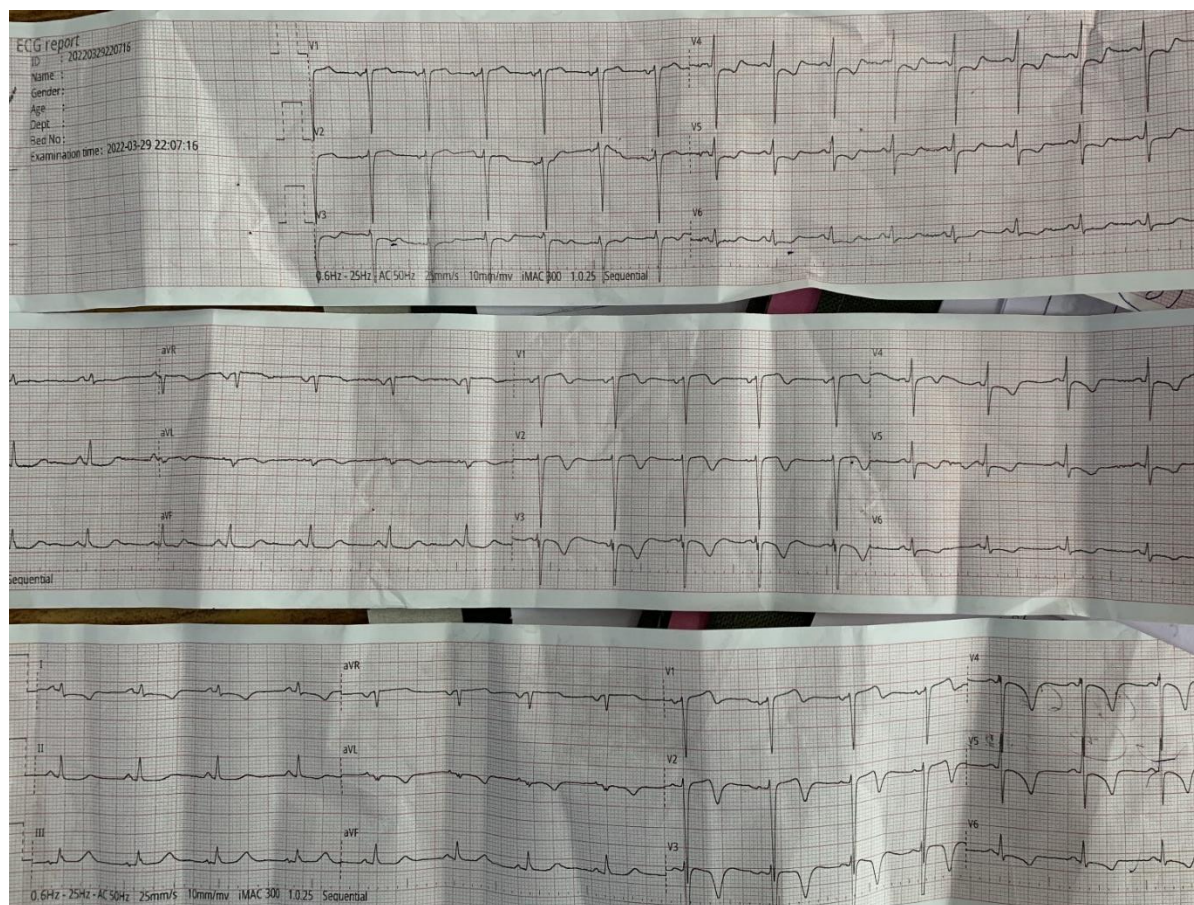
ECG showed deepening T inversions from V1- V6 (Figure 1). Troponin I was 0.07

(more than the 99<sup>th</sup> percentile). 2D echo showed a mild hypokinesia of anterior wall with a EF of 50-55% and grade 1 MR.

A diagnosis of Kounis Syndrome was made with anaphylaxis to amoxicillin.

Patient was managed with IM Adrenaline 0.5ml (1:1000), IV hydrocortisone 200mg and iv chlorpheniramine 10mg. He received Stat doses of Aspirin 300mg, Clopidogrel 300 mg and Atorvastatin 40mg and was continued with Aspirin 75mg nocte, Clopidogrel 75mg nocte, Atorvastatin 40mg nocte, subcutaneous enoxaparin 60mg twice daily for 6 doses. He also received prednisolone 10mg and chlorpheniramine 4mg for five days.

Patient had an uneventful recovery. He did not give consent for coronary angiogram.



**Figure 1: Serial ECG taken during admission**

## Discussion

Kounis Syndrome was first described in 1991 by Kounis and Zavras as a syndrome of allergic angina pectoris [3]. Postmortem examination of coronary artery specimens in 20 patient who died of myocardial infarction by Kovanen et al. in 1995 revealed higher levels of mast cell degranulation at sites of

plaque rupture and erosion as compared to adjacent or distant sites [4]

Various triggers have been implicated with Kounis syndrome including drugs, food and environmental agents. Studies show that Nonsteroidal anti-inflammatory drugs is the most frequently trigger (60.7%), followed by drugs for cardiovascular disease (19.6%), antibiotics (17.6%), and anesthetics (9.8%)

[5] Amongst drugs the commonest implicated is amoxicillin/clavulanic.

Although the diagnosis is clinical coronary angiogram could be performed which will show coronary artery vasospasm in the acute setting. Further allergic reactions could be proved by high serum tryptase levels and eosinophilia in blood. We did not perform Tryptase levels as an obvious clinical diagnosis of anaphylaxis could be made. Eosinophilia was not observed in our patient.

Management will depend on the Type of Kounis Syndrome. Type 1 will require only the management of the allergy/anaphylaxis while other types would additionally require the standard management of acute coronary syndrome. Since an angiogram was not performed in the acute setting, we assumed the patient to have Type 2 Kounis syndrome

due to multiple risk factors in this patient for coronary artery disease.

Case reports of acute coronary syndrome following adrenaline injection were found on literature review. This was thought to be unlikely as our patient was symptomatic with ECG changes prior to administration of adrenaline and since only a therapeutic dose of adrenaline was used.

### **Conclusion**

Kounis syndrome remains underdiagnosed in the emergency setting. It should be an important differential diagnosis amongst patients admitted with chest pain. This case report highlights the need to add the management of Kounis syndrome in the management guidelines of acute coronary events.

**References**

[1] NG Kounis, Andreas Mazarakis, Grigoios Tsigkas et al. Kounis Syndrome: A new twist on an old disease. *Future Cardiology* 2011; 7(6): 805-824

[2] NG Kounis. Kounis Syndrome (Allergic angina and allergic myocardial infarction): a natural paradigm? *International Journal of Cardiology* 2006; 110,7-14

[3] NG Kounis, GM Zavras. Histamine – induced coronary artery spasm: the concept of allergic angina. *Br. J. Clin. Practice* 1991; 45,121,128

[4] PT Kovanen, M Kaartinem, T Paavonen. Infiltrates of activated mast cells at the site of coronary atheromatous erosions or rupture in myocardial infarction. *Circulation* 92 1995; 1083

[5] Abdelghany M, Subedi R, Shah S et al. Kounis syndrome: A review article on epidemiology, diagnostic findings, management and complications of allergic

acute coronary syndrome. *International Journal of Cardiology* 2017;232:1-4