

Case study

Right atrial mass, concomitant right atrium and liver hemangioma

Abstract :

Introduction:

Tumors of the heart comprise 0.2% of all human tumors, Right atrial masses are rare cardiac tumors. We herein present a concomitant heart and liver tumor. Patients concern : Our patient was a 49-year-old man with dyspnea at rest of 2 months' duration.

primary diagnoses, interventions, and outcomes: transthoracic echocardiography revealed normal right ventricular size with mild-to-moderate right ventricular systolic dysfunction, mild right atrial enlargement with a homogenous, oval-shaped mass (4 × 2.71 cm) featuring a translucent rim. Pulmonary computed tomography (CT) angiography yielded no filling defects and findings in favor of pulmonary emboli or tumoral lesions. Abdominopelvic sonography showed fatty liver (grade I) and a heterogeneous, hyperechoic ill-defined mass (128 × 98 mm) in the right lobe of the liver. Abdominopelvic intravenous contrast CT illustrated an infiltrative tumoral lesion in the liver lobe with heterogeneous, nodular enhancement at an early phase. Abdominal magnetic resonance imaging demonstrated a large, lobulated mass lesion, 15 × 12 × 10 cm in size, in the right lower lobe of the liver with heterogeneous high-signal intensity in T2, as well as peripheral nodular enhancement after contrast injection, followed by centripetal progression of the enhancement, in favor of a cavernous hemangioma. The patient underwent open-heart surgery in our center and right atrial mass extracted. The pathology examination reported a benign vascular lesion, compatible with a hemangioma with venous and capillary features

Conclusion: concomitant right atrium and liver hemangioma as a primary benign tumor is rare and it must be considered in patients with both heart and liver mass.

Key words: Hemangioma, benign cardiac mass, concomitant heart and liver tumor

INTRODUCTION

Tumors of the heart comprise 0.2% of all human tumors, and they are often a consequence of metastasis from another organ. Indeed, secondary cardiac tumors are 20% to 40% times more frequent than primary cardiac tumors, of which 75% are benign.¹⁻⁴ Right atrial masses are rare cardiac tumors. We herein present a concomitant heart and liver tumor.

Patient's Information:

Our patient was a 49-year-old man with dyspnea at rest of 2 months' duration. He did not have exertional dyspnea, nor did he complain of chest pain. His past medical history indicated no other diseases such as dyslipidemia, hypertension, and diabetes mellitus.

Clinical Findings:

In physical examination, heart sounds were S1, S2, and normal, and the lungs were clear. Other findings were unremarkable. Admission lab data were normal, as was the electrocardiogram. The following procedures were performed in our center.

Time Line: Additionally, he reported no weight loss, dyspepsia, or constitutional problems. His referral to our cardiac center was because of echocardiographic data obtained elsewhere.

Diagnostic Assessments:

Transthoracic echocardiography revealed normal left ventricular size with preserved tissue (left ventricular ejection fraction: 50%–55%), normal right ventricular size with mild-to-moderate right ventricular systolic dysfunction (tricuspid annular plane systolic excursion: 18 mm), mild right atrial enlargement with a homogenous, oval-shaped mass (4 × 2.71 cm) featuring a translucent rim, mild-to-moderate mitral regurgitation, mild-to-moderate tricuspid regurgitation with an unmeasurable tricuspid gradient, and a mean pulmonary pressure of 22 mm Hg.

Pulmonary computed tomography (CT) angiography yielded no filling defects and findings in favor of pulmonary emboli or tumoral lesions.

Coronary CT angiography visualized no epicardial coronary artery lesions.

Abdominopelvic sonography showed fatty liver (grade I) and a heterogeneous, hyperechoic ill-defined mass (128 × 98 mm) in the right lobe of the liver. The gall bladder and the common bile duct were normal.

Abdominopelvic intravenous contrast CT illustrated an infiltrative tumoral lesion in the liver lobe with heterogeneous, nodular enhancement at an early phase. In addition, the surface of the liver was irregular, and there was central hypodensity. The findings were in favor of an atypical hemangioma or a hepatocellular carcinoma.

Abdominal magnetic resonance imaging demonstrated a large, lobulated mass lesion, 15 × 12 × 10 cm in size, in the right lower lobe of the liver with heterogeneous high-signal intensity in T2, as well as peripheral nodular enhancement after contrast injection, followed by centripetal progression of the enhancement, in favor of a cavernous hemangioma.

Therapeutic Intervention:

The patient underwent open-heart surgery in our center. After midline sternotomy, partial pericardiotomy, and thymectomy, the right atrium was explored and the giant mass was extracted. Additionally, his atrial septal defect was closed with a pericardial patch.

Follow UP and Outcome:

The patients discharge from hospital successfully on stable vital sign without dyspnea.

Table 1: The patient's laboratory data

Lab Data	
Na	139 mg/dL
K	4 mg/dL
Mg	2.6 mg/dL
FBS	102 mg/dL
BUN	11 mg/dL
Cr	1.2 mg/dL
AST	14 IU/L
ALT	12 IU/L
BR total	1.2 mg/dL
BR direct	0.4 mg/dL
LDH	289 IU/L
Hb	12.4 g/dL
WBC	5600 cells/mm ³

Serum iron	36 mg/dL
FER	20 ng/dL
TIBC	311.7 mg/dL

Na, Sodium; K, Potassium; Mg, Magnesium; FBS, Fasting blood sugar; BUN, Blood urea nitrogen; Cr, Creatinine; AST, Aspartate transaminase; ALT, Alanine aminotransferase; BR, Bilirubin; LDH, Lactate dehydrogenase; Hb, Hemoglobin; WBC, White blood cell; FER, Ferritin; TIBC, Total iron-binding capacity

The pathology examination reported a benign vascular lesion, compatible with a hemangioma with venous and capillary features.

Table 2: The patient's echocardiographic measurements

Echocardiographic Measurements	
LVEF	45%–50%
LVEDVI	59 mL/m ²
Ascending aorta	2.9 cm
RVID	2.8 cm
TAPSE	19 mm
RVSm	11 cm/s
Septal E'	9.5 cm/s

Lateral E'	18 cm/s
E velocity	69 cm/s
RA area	19 cm ²
RA mass size	4x2.71 cm
Mean PAP	22 mm Hg

LVEF, Left ventricular ejection fraction; LVEDVI, Left ventricular end-diastolic volume index; RVID, Right ventricular internal diameter; TAPSE, Tricuspid annular plane systolic excursion; RVSm, Right ventricular peak systolic myocardial velocity; RA, Right atrial; PAP, Pulmonary arterial pressure; Septal E', ??????; Lateral E', ?????

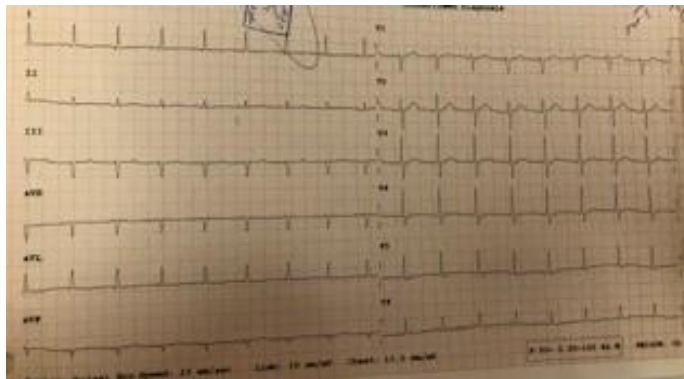


figure 1: the patients electrocardiogram

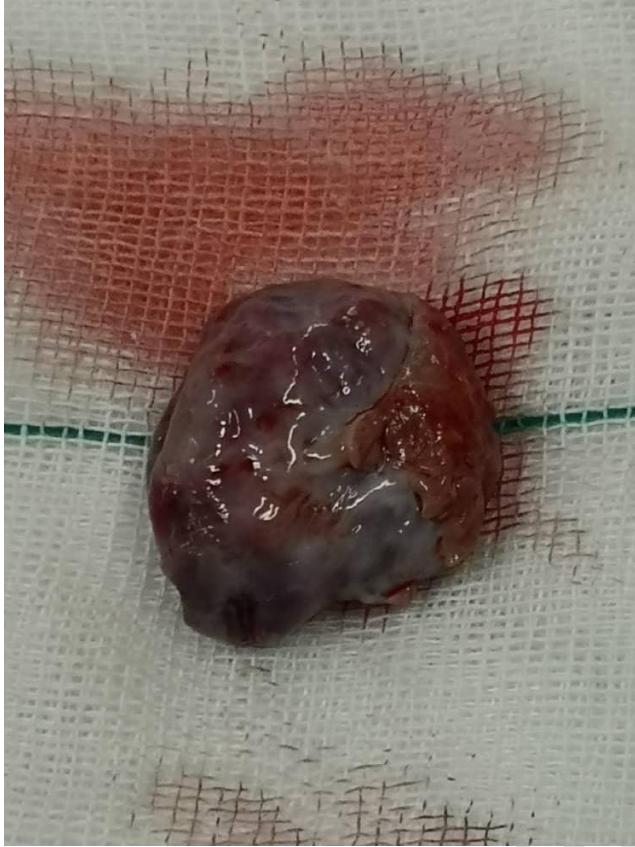
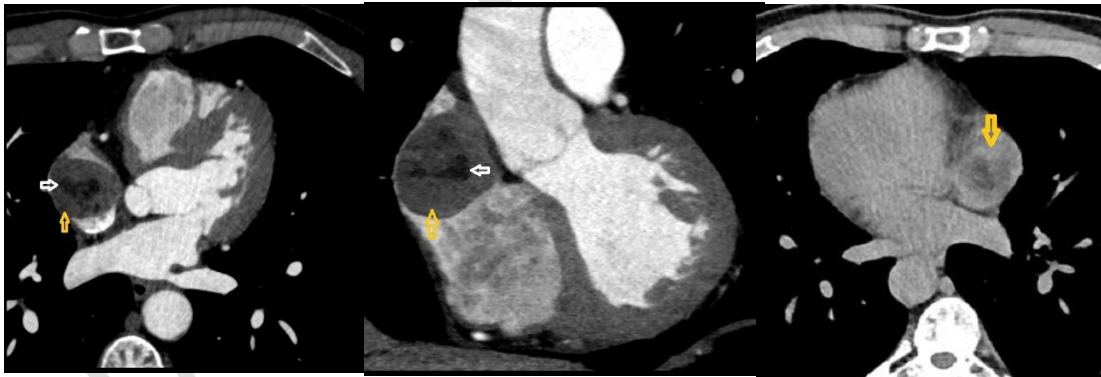
figure 2: mass view after resection



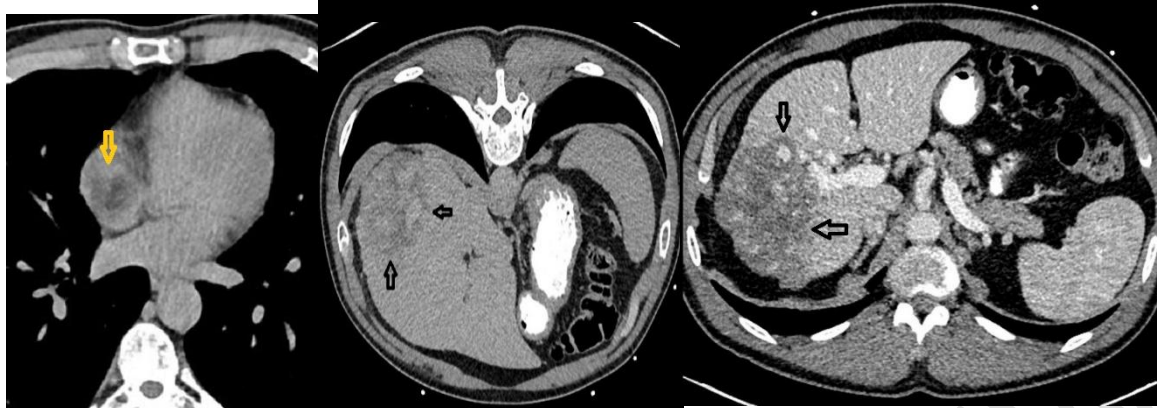

Figure 3 : Prospective ECG gated

Cardiac CT Angiography(a,b) reveals a round mass lesion in the right atrium with central lipid core (white arrow) and peripheral soft tissue.

Delay Non-ECG gated high pitch thorax CT(c) shows peripheral enhancement (white arrow)

Abdominal CT scan at the early phase (d) demonstrates peripheral enhancement of mass lesion in right liver lobe, and delay enhancement (e) displays iso dense with normal liver parenchyma.

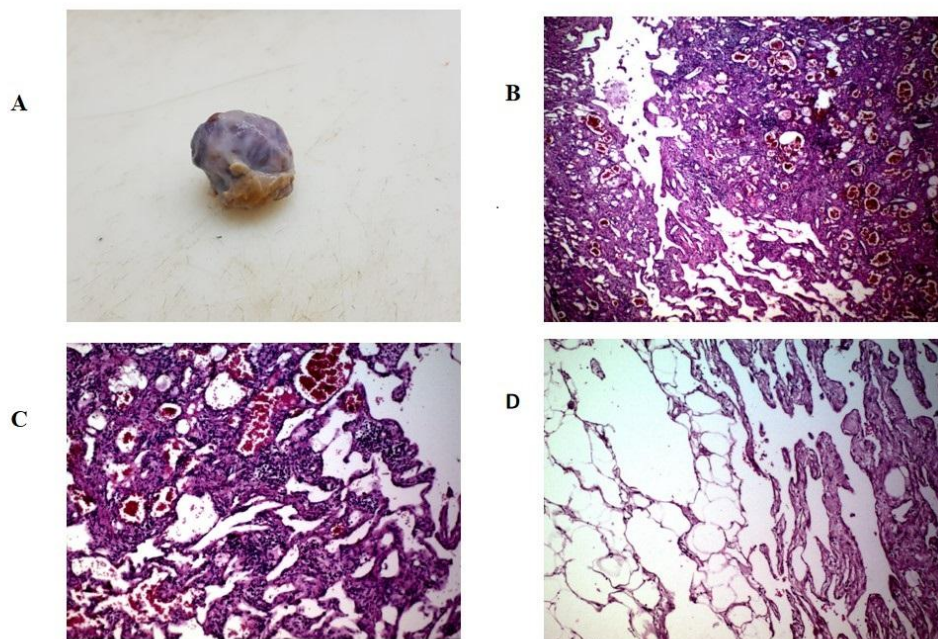


figure 4 : A) Gross examination shows an ovaloid shape well defined mass with soft consistency measure 2.5x2.5x1.5 cm. B and C)Microscopic examination shows dilated thin walled and capillary –type vascular channels lined by a single layer of flat endothelial cells without cellular atypia. No necrosis or mitosis is seen D) Mature adipose tissue between vessels are seen.

DISCUSSION

Primary cardiac tumors are a rare diagnosis. These tumors may have such different presentations as dyspnea, chest pain, heart failure, tamponade, pulmonary embolism, arrhythmia, and acute right-sided heart failure⁵ with constitutional symptoms, including sweating, fever, and weight loss.⁶ Symptom presentation is often a consequence of delayed diagnoses, with the average time interval from presentation to the correct diagnosis being 3 years.⁷ Most cardiac tumors are metastatic. The most common metastasis sites are the lung, liver, brain, and bone, although metastasis to the pancreas, spleen, skin, mandible, lymph nodes, adrenal glands, and kidneys has also been reported.^{8,9}

In the present case of a rare concomitant heart and liver hemangioma without any metastasis and constitutional symptoms, our initial suspicion prior to surgery was a malignant lesion. Primary hemangiomas of the heart were first described in 1893 by McAllister, who had reviewed 533 primary tumors and cysts of the heart and pericardium, of which 15 (2.8%) were hemangiomas.¹⁰ Cardiac hemangiomas are rare benign primary cardiac tumors, with fewer than 100 cases described in the current literature.¹¹ Hemangiomas are common benign congenital vascular lesions, and they generally arise from the gastrointestinal tract or cutaneous structures. Echocardiography is the diagnostic imaging modality of choice to suitably screen for cardiac tumors, including cardiac hemangiomas. Computed CT and magnetic resonance imaging are complementary methods in the diagnostic workup of cardiac tumors in that they can assess the scope of myocardial and local invasion. The recurrence rate of cardiac tumors after surgical resection is indefinite; nonetheless, recurrent masses are likely benign.

CONCLUSION:

Primary cardiac tumors are a rare diagnosis, most cardiac tumors are metastatic but in 2.8% may be a benign hemangioma concomitant with gastrointestinal mass. In cardiac hemangioma evaluation of gastrointestinal system should be considered like this case in concomitant right atrium and liver mass.

DECLARATION:

Ethics Approval and consent to participate: Ethic code was received from ethics ward of Rajaie cardiovascular heart center (IR.RHC.REC.1400.093) and Written informed consent was obtained from the patient for publication of this case report and any accompanying images. A copy of the written consent is available for review by the Editor-in-Chief of this journal. Supporting data is available and Authors who do not wish to share their data must state that data will not be shared due respect patients. Funding of this article approved by Rajaie cardiovascular heart center

REFERENCES

1. Arruda MV, Braile DM, Joaquim MR, Soares MJ, Alves RH: Resection of left ventricular myxoma after embolic stroke [in English and Portuguese].
Rev Bras Cir Cardiovasc 2008, 23:578-580.
2. Jang KH, Shin DH, Lee C, Jang JK, Cheong S, Yoo SY: Left atrial mass with stalk: thrombus or myxoma? J Cardiovasc Ultrasound 2010, 18:154-156.
3. Vale Mde P, Freire Sobrinho A, Sales MV, Teixeira MM, Cabral KC: Giant myxoma in the left atrium: case report [in English and Portuguese]. Rev Bras Cir Cardiovasc 2008, 23:276-278.
4. Hermans K, Jaarsma W, Plokker HW, Cramer MJ, Morshuis WJ: Four cardiac myxomas diagnosed three times in one patient. Eur J Echocardiogr 2003, 4:336
5. Bruce CJ. Cardiac tumors: diagnosis and management. Heart 2011;97:151–60.
6. Chalhoub E, Mattar BI, Shaheen W, et al. Cardiac angiosarcoma presenting with tamponade. Intern Med 2012;51:2905–7.
7. Jain A, Simon S, Elangovan I. (18)F-fluoro-deoxyglucose positron emission tomography-computed tomography in initial assessment and diagnosis of right atrial angiosarcoma with widespread visceral metastases: A rare case report and review of the literature. Indian J Nucl Med 2015;30:51–4.
8. Waness A, Batoon AA, Mirza I, et al. Elusive cardiac angiosarcoma in a young pregnant female: rare presentation with fatal outcome. Cardiol Res 2015;6:292–6.
9. Ramadhan A, Willén H, Thor A. Angiosarcoma of the mandible: metastasis from a primary tumor of the right atrium of the heart. Case Rep Clin Med 2013;02:53–7.
10. McAllister H. Tumors of the heart and pericardium. In: Silver MD, editor. Cardiovascular pathology. New York: Churchill Livingstone; 1983. p. 909e43.
11. Perk G, Yim J, Varkey M, Colvin SB, Tunick PA, Kronzon I. Cardiac cavernous hemangioma. J Am Soc Echocardiogr 2005; 18:979 [e3e4].