

## Case report

# Solitary Cervical osteochondroma with neurological symptoms: Case report

Keywords: Solitary, Osteochondroma, Osteophytes, neurological, numbness, extradural, cervical spine

## Abstract:

Osteochondromas are the most common benign tumors of the bone. They mostly arise from the metaphysis of the long bones in the first two decades of life. Involvement of the flat bones is uncommon and the involvement of the small bones of hands and vertebrae are extremely rare. We report a 42-year-old male patient who presented with neck pain, numbness and weakness of left arm. Radiological images revealed a solitary, well defined, bony lesion in the cervical canal between C1-C2 arches. Excisional biopsy was performed. Histopathological examination of the specimen confirmed the diagnosis of osteochondroma. We conclude that this rare tumor of the cervical spine can cause serious neurological symptoms and the total excision of the lesion assures a good outcome.

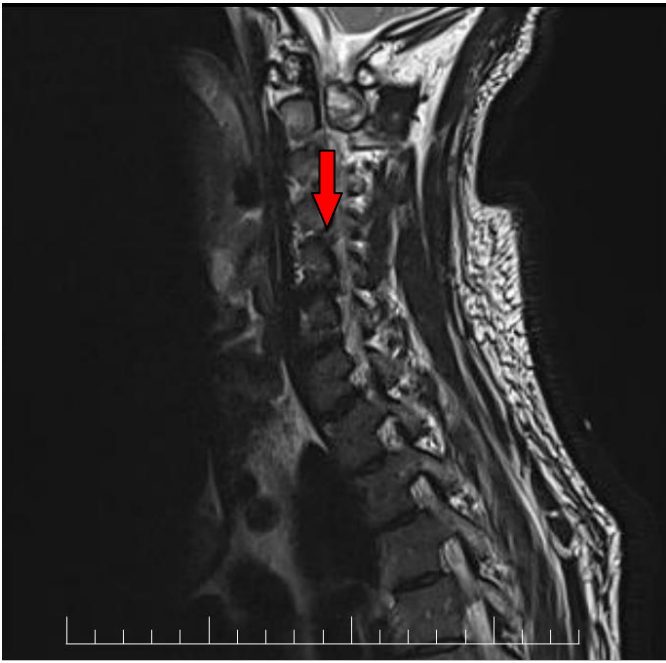## Introduction

Osteochondromas are common benign bone tumors that accounts for approximately 35% of benign bone tumors and 10% of all bone tumors [1]. They occur usually in the metaphysis of the long bones in the first two decades of life with slight male predominance [1]. Involvement of the femur > humerus > tibia are the commonest. Flat bones such as iliac bone and sternum is uncommon. However, involvement of small bones of the hands and feet, ribs and vertebra is extremely rare [2].

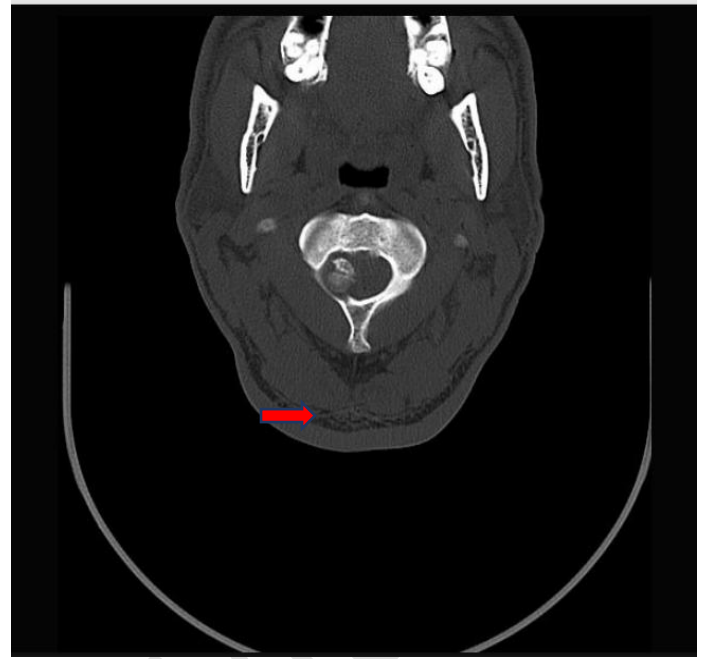Osteochondromas can occur as solitary sporadic tumors or as multiple tumors like in hereditary exostoses (MHE) [2]. Clinically, they are often asymptomatic. They may cause symptoms due to fracture, growth or impingement of other structures. We present a case of a cervical spine osteochondroma that is inside the cervical canal between the arches of C1-C2 and was causing pressure on the cervical nerves presenting as neck pain, numbness and weakness of the left upper arm.

On 10th November 2021, 46 year old male, smoker, a known case of vitamin D deficiency, presented to our main tertiary care hospital (Salmaniya Medical complex) accident and emergency department with history of neck pain radiating to both upper limbs with left upper limb numbness and pain for the last 6 months with recent exacerbation of pain. On physical examination, patient is afebrile complaining of persisting upper neck pain radiating to both upper limbs with increasing pain and numbness in the left upper limb. He has minimal upper limbs weakness. He was admitted to the hospital for a suspected herniated cervical spine disc. Patient's initial labs were all within normal limits, his electrolytes were normal as well. Patient was taken for a cervical spine MRI (figure1) and computed tomography studies (figure 2) and the tests concluded that the patient has a C1 - C2 well defined, solitary, extradural, bony lesion protruding in to the cervical canal with mild cord compression and spinal canal stenosis

## Case presentation



**Figure. 1.** Prioperative T2-weighted MRI demonstrating severe cord compression by an extradural hypointense lesion originating from posterior arch of c1 (arrow).



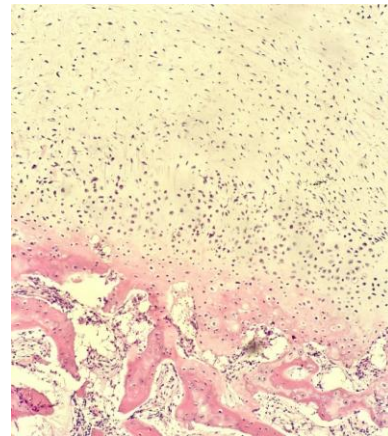
**Figure. 2.** Prioperative axial CT Scan depicting the relatively hyperdense lesion originating from c1 posterior arch with intraspinal growth (arrow).

After that, patient was admitted to the neurosurgery Ward, and a scheduled surgery was performed the next day. Intraoperative finding was an extradural cervical spine lesion measuring 1.4x1.4x1.2 cm at the level of C1-C2 protruding from the posterior arches of C1 cervical vertebra. So the patient underwent posterior spinal fusion with laminectomy and level C1-C2 Cervical spine extradural lesion resection under general anesthesia with no complications. The resected lesion was sent to pathology department for microscopic examination. The postoperative course was uneventful and the symptoms improved immediately after surgery, and the patient fully recovered without any residual deficit.

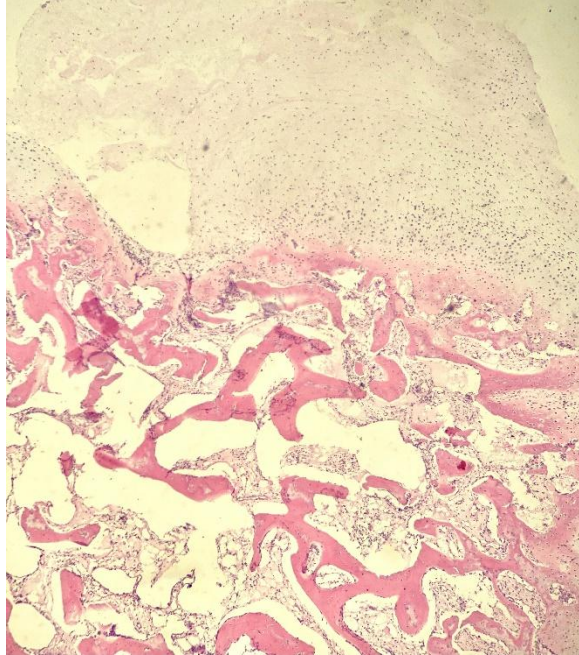
### Histological findings

The histological diagnosis was made on hematoxylineosin- stained slides. Sections of the resected lesion were evaluated through light microscopy (Olympus, CX41). Histologically, the lesion composed of

fragments of mature cartilage overlying viable bony trabeculae with fatty marrow. There was no evidence of any noted cytological atypia ((figure3. A and B).



**Figure. 3. A.** Hematoxylin-eosin-stained sections of the lesion. Mature cartilage overlying viable bony trabeculae with fatty marrow confirms the diagnosis of Osteochondroma (Magnification  $\times 20/0.08$  NA).



**Figure. 3. B.** Hematoxylin-eosin-stained sections of the lesion. Mature cartilage overlying viable bony trabeculae with fatty marrow confirms the diagnosis of Osteochondroma (Magnification  $\times 10/0.08$  NA).

## Discussion

Osteochondromas (also known as osteocartilaginous exostosis) according to The World Health Organization (WHO) classification of bone tumors are benign cartilage forming neoplasms that are relatively common. They account for 10-15% of all bone tumors and approximately 35% of all benign bone tumors [3]. Although usually thought of as a benign bone tumor, they may be thought of as a developmental anomaly [3]. They are frequently asymptomatic and have very low malignant potential if sporadic and solitary.

Osteochondromas develop during childhood (period of most rapid skeletal growth) usually in the metaphysis of the long bones [4], but once formed remain for the rest of the individual's life. They can present at any age and are most frequently found incidentally. They are usually sporadic, but can be part of few syndromes such as hereditary multiple exostoses (HME)

also known as diaphyseal aclasis [5] and Trevor disease: also known as dysplasia epiphysealis hemimelica [5].

They most commonly arise from the appendicular skeleton, especially around the knee. Osteochondromas of the lower limbs accounts for 50% of the cases with the most commonly involved bone is the femur (especially distal):30% , followed by proximal tibia:15-20% of the cases.[6]. Humerus bone also involved commonly by these tumors:10-20% [6]. Vertebrae of the spine is less commonly involved with osteochondromas. However, the posterior arches of the vertebrae, especially the cervical spine vertebrae are not rare site for these tumors.[6]

Symptomatic presentation is either due to mechanical effects of the lesion, fracture, or malignant transformation.[7] Clinically, cervical spine osteochondromas can cause mechanical symptoms due to its extradural location and nerve compression in the spinal canal. Fractures occur typically through the neck of pedunculated lesions.[7] Moreover, ongoing growth and or pain after skeletal maturity has been reached is suspicious for malignant degeneration[7].

Histopathologically, these tumors are considered a chondroid neoplasm and are primarily a part of the growth plate which separates and continues growing independently, without an associated epiphysis, usually away from the nearby joint [8]. The medullary cavity is continuous with the parent bone, and hyaline cartilage caps them [8]. Osteochondromas can be congenital or occur as a result of previous trauma, including previous irradiation [8]. Malignant transformation occurs in the cartilage cap, and is uncommon in sporadic solitary osteochondromas (~1%), whereas in the setting of hereditary multiple exostoses the rate is much higher (5-25%)[8].

These tumors can be confidently diagnosed by different radiological modalities such as Plain

radiograph, Ultrasound, Computed tomography (CT scan) and Magnetic resonance imaging (MRI)[9,10]. Plain radiograph can give us idea regarding sessile (broad base) or pedunculated (narrow stalk) lesions found on the surface of bones. Whereas MRI is the best imaging modality to assess cartilage thickness (and thus assessing for malignant transformation), the presence of edema in bone or adjacent soft tissues, and visualizing neurovascular structures in the vicinity [9,10].

Prognosis is usually excellent. As in most instances, no treatment is required unless the osteochondroma is causing symptoms (neurological symptoms of numbness and pain like in our case). In this circumstances, it should be totally resected to relief the symptoms and to prevent future recurrence [9,10]. If malignant transformation occurs (~1% in solitary osteochondromas and ~5-25% with hereditary multiple exostoses) then the resultant chondrosarcoma is usually of low grade (67-85% of cases), and surgery is usually curative (70-90%)[9,10]. Local recurrence is seen in both benign and malignant lesions, due to spillage of cartilage cells into the resection bed. Rates are estimated at 2% and up to 15% respectively[11].

There are many differential diagnosis of osteochondroma and that depends on its location. In cervical osteochondroma, the close differential diagnosis is osteoma. Herniated cervical intervertebral disc will give the same neurological manifestation. However, it could be easily diagnosed by different imaging modalities[10].

## Conclusions

Due to its rarity, solitary cervical spine osteochondroma is usually diagnosed late, after the progression of the patient's neurological symptoms due to the gradual cord compression. However, in majority of the cases, the tumor is successfully

treated by laminectomy with radical resection. The surgery usually has favorable outcomes. Complete surgical removal is necessary to prevent recurrence. Despite being rare, C1-C2 level osteochondromas should be always considered in the differential of any extradural cervical spine lesions, as it is the most common location for osteochondromas in the spine.

## References :

1. Murphey MD, Choi JJ, Kransdorf MJ, Flemming DJ, Gannon FH (2000) Imaging of osteochondroma: variants and complications with radiologic-pathologic correlation. *Radiographics* 20:1407-1434
2. Silber JS, Mathur S, Ecker M (2000) A solitary osteochondroma of the pediatric thoracic spine: a case report and review of the literature. *Am J Orthop (Belle Mead NJ)* 29:711-714
3. Patel A, Tharadara GD (2014) Rare case of osteochondroma of spine. *Indian journal of Applied research* 4:456-458
4. Faik A, Mahfoud Filali S, Lazark N, El Hassani S, Hajjaj-Hassouni N (2005) Spinal cord compression due to vertebral osteochondroma: report of two cases. *Joint Bone Spine* 72:177-179
5. Sharma MC, Arora R, Deol PS, Mahapatra AK, Mehta VS, Sarkar C (2002) Osteochondroma of the spine: an enigmatic tumor of the spinal cord. A series of 10 cases. *J Neurosurg Sci* 46:66-70
6. Moon KS, Lee JK, Kim YS, Kwak HJ, Joo SP, Kim IY et al (2006) Osteochondroma of the cervical spine extending multiple segments with cord compression. *Pediatr Neurosurg* 42:304-307
7. Wang V, Chou D (2009) Anterior C1-2 osteochondroma presenting with dysphagia and sleep apnea. *J Clin Neurosci* 16:581-582

8. Sultan M, Khursheed N, Makhdoomi R, Ramzan (2016) A compressive myelopathy due to osteochondroma of the atlas and review of the literature. *Pediatr Neurosurg* 51:99–102
9. Chatzidakis E, Lypiridis S, Kazdaglis G, Chatzikonstadinou K, Papatheodorou G (2007) A rare case of solitary osteochondroma of the dens of the C2 vertebra. *Acta Neurochir* 149:637–638
10. Bernard S, Murphey M, Flemming D, Kransdorf M. Improved Differentiation of Benign Osteochondromas from Secondary Chondrosarcomas with Standardized Measurement of Cartilage Cap at CT and MR Imaging. *Radiology*. 2010;255(3):857-65.

UNDER PEER REVIEW