

CASE REPORT: EARLY PREGNANCY INVASIVE PLACENTA –LATE PRESENTATION

ABSTRACT:

Introduction: Placenta percreta is the severe form of morbidly adherent placenta (MAP) where chorionic villi penetrate through the myometrium and to or through the serosa involving bladder or bowel in some cases and can be associated with severe complications.

Case presentation: In our present case we had a 30 year old, Gravida 4, Para 2 Living 2 Abortion 1 with previous 2 cesarean sections, present with bleeding on and off since 3 months, post spontaneous abortion at 13+ weeks followed by incomplete check curettage. On examination she was found to have a boggy mass per vagina and a serum Beta-Human Chorionic Gonadotropin value was slightly above normal. On imaging and evaluation she was found to have a mass occupying the lower uterine cavity invading the myometrium with significant vascularity, reported as invasive mole provisionally. She was taken up for laparotomy and hysterectomy after counselling in detail and correction of anemia. Intra-op a ballooned out lower uterine segment with a vascular mass was noted which was partially invading the bladder wall. Patient had an uneventful post op period. Her final histopathology report was placenta percreta with few viable chorionic tissue

Discussion: Morbidly adherent placenta in early pregnancy can be tricky to diagnose and manage. Patient antenatal history of previous 2 cesarean - sections and low lying placenta in index pregnancy and a failed curettage gave us important clues to her diagnoses along with the MRI findings and BHCG values. Hysterectomy seemed best option for her.

Conclusion: To conclude high index of suspicion and planning is required to manage placenta percreta cases successfully.

Comment [AaM1]: 30-year-old

Comment [AaM2]: caesarean

Comment [AaM3]: presented

Comment [AaM4]: Beta-Human Chorionic Gonadotropin (BHCG)

Comment [AaM5]: Intra-operatively,

Comment [AaM6]: postoperative

Comment [AaM7]: showed

Comment [AaM8]: caesarean

Comment [AaM9]: low-lying

Comment [AaM10]: Please, delete it.

Comment [AaM11]: Please, add 3-6 keywords.

INTRODUCTION:

Morbidly adherent placenta also referred to as *accrete syndromes* is used to describe a spectrum of abnormal placentation and firm adherence due to partial or total absence of decidua basalis and imperfect development of fibrinoid / Nitabuch layer or defect of biological functions of trophoblast leading to excessive invasion. Variants of MAP are classified based by depth of trophoblastic growth. Placenta accreta indicates that villi are attached to myometrium, in placenta increta villi actually invade the myometrium and in placenta percreta villi penetrate through or to the serosa¹ and sometimes to bowel or bladder.

The overall incidence of MAP is rising due to rising number of c- sections. Placenta percreta accounts to 5-7% of adherent placenta.² The 2 most significant risk factors for placenta accrete are previous c-section and placenta previa. An asymptomatic antenatal condition can result in life threatening complications during interventions to separate placenta. Both MRI and USG are modalities for prenatal diagnosis of MAP although limitations exist for both. In our case patient presented with history of spontaneous abortion and incomplete curettage with bleeding on and off for 3 months which made her diagnosis tricky considering the possibility of gestational trophoblastic disorders presenting in similar manner.

CASE PRESENTATION

Mrs. Amreen Begum, 30 years of age, Gravida 4 para 2 living 2 abortion 1 with 13+ weeks gestation was referred to us with suspicion of gestational trophoblastic neoplasia for further management. She gave us a history of spontaneous abortion at home 3 months back, followed by attempted check curettage at local hospital along with sterilisation done in the same sitting. However according to records, minimal tissue was obtained on curettage and misoprostol was inserted for retained products and discharged. She however continued to bleed on and off after that and on evaluation was found to have a large boggy mass per vagina when examined by local doctor 2 months later. Her ultrasound pelvis revealed a large lobulated lesion of 9.3 x 6.9 cm x 2.6 cm-260cc with multiple cystic areas and high internal vascularity in the lower uterine cavity with uterus measuring 12.9 x 4.23x 6.85cm. She was transfused 2 pint PRBC in view of low haemoglobin of 9 and referred here for further management. Further plain MRI done revealed an ill- defined lesion 8.6 x 8.1x 9.2 cm in lower endometrial canal with hemorrhagic areas within. The possible diagnosis was reported as retained products of conception. Serum BHCG was done weekly which revealed serially decreasing values of 61,22.81 and 17 respectively.

On further evaluation she gave us a obstetric history of prev 2 cesarean sections and a spontaneous abortion at 4 months prior to the present pregnancy. In the present pregnancy she gave a history of on and off bleeding since the time of conception with her Nuchal Translucency-Nasal Bone scan showing a single live intrauterine of 13+5 weeks gestation and low lying placenta. No other abnormality was otherwise

Comment [AaM12]: Delete

Comment [AaM13]: all layers of uterus and may extend to the surrounding viscera as bowel and urinary bladder^{1,2}. In the normal situations, the cytotrophoblast extending through the primary chorionic villi form a continuous shell in endometrium preventing further invasion and abnormal extension of villi into myometrium².

Please, add this reference of embryology to the mentioned one.

Hegazy A. Clinical embryology for medical students and postgraduate doctors. Lap Lambert Academic Publishing; 2014.

Comment [AaM14]: caesarean section (CS)

Comment [AaM15]: abnormal adherent

Comment [AaM16]: CS

Comment [AaM17]:

Comment [AaM18]: Please, clarify these abbreviations & then write the abbreviation following its clarification in-between brackets.

Comment [AaM19]: Delete the name; Instead write A female,

Comment [AaM20]: pints

Comment [AaM21]: Clarify the abbreviation

Comment [AaM22]: an

Comment [AaM23]: previous

Comment [AaM24]: CSs

Comment [AaM25]: Delete it.

mentioned. On speculum examination the cervix was found to be normal and on per vaginal examination a large boggy mass of 14 weeks size occupying all fornices was felt which was thought to be consistent with uterus and parametrium was found to be free.

On admission, Bhcg was repeated in our lab which was found to be 16. MRI with contrast revealed a large well defined uterine lesion of 8.5 x 7.8 x7.6 cm occupying mid and lower uterine cavity which was causing thinning of uterine wall and possibly adherent/infiltrating the wall with possible suspicion of trophoblastic tumour was reported. She was posted for laparotomy and hysterectomy with a suspicion of gestational trophoblastic tumor /adherent placenta.

Intra op we found the fundus of uterus normal and the lower segment ballooned out with tumour which was very vascular on appearance with bladder completely adherent to the lower segment .We infiltrated the uterus with dilute vasopressin to achieve hemostasis and hysterectomy was carried out. During dissection of bladder adhesions, we noted a small rent of 2 cm in the bladder (region of invasion to bladder) which was then repaired in 2 layers. The patient was transfused one pint PRBC intra op with estimated blood loss of approximately 700 ml. She recovered well in post op period and was discharged in 3 days in stable condition. Catheter was removed on day 14.

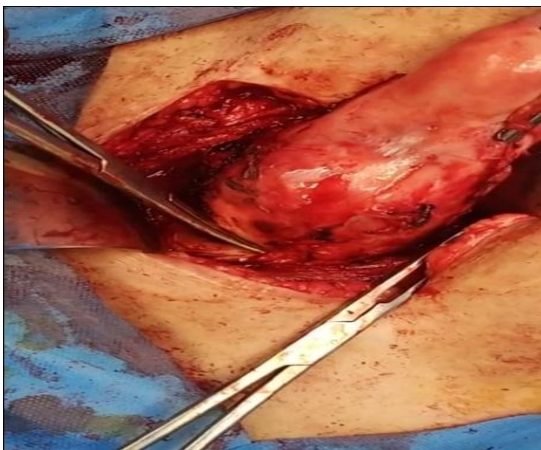

Figure 1-intra op finding showing ballooned out lower segment

Comment [AaM26]: Clarify it.

Comment [AaM27]: All figures appearing in the paper are not be referred within the text. [lease, refer to each figure within the text corresponding its meaning.

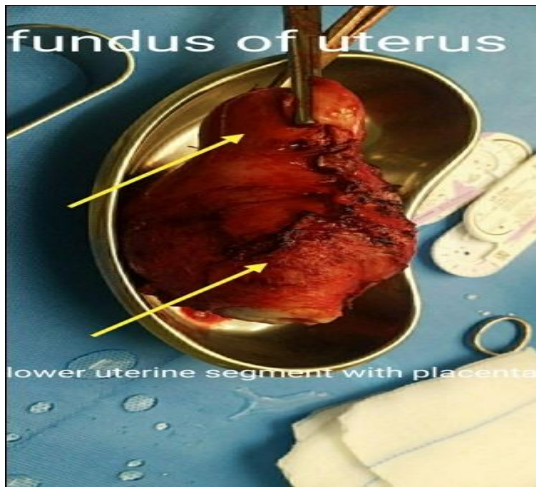


Figure 2-gross specimen

Her HPE report on cut section of LUS revealed a polypoidal growth of 8 x 7 cm which was a lesion with extensive necrosis and haemorrhage and degenerated chorionic villi with few viable chorionic villi. Grossly the tumor involves the serosa. No hyperplastic trophoblastic proliferation seen. Features were suggestive of adherent/invasive placenta-placenta percreta.

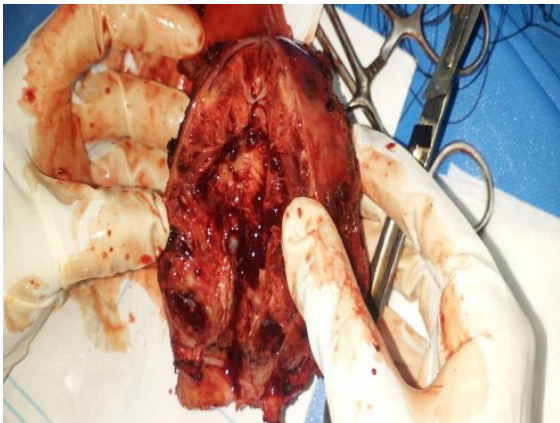


Figure 3-cut section of lower uterine segment showing invasion

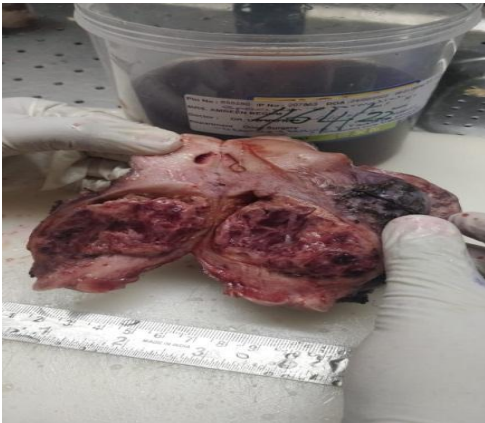

Figure 4-pathology specimen on cut section

DISCUSSION:

In cases of first and second trimester accrete syndromes, there is usually haemorrhage that is a consequence of coexisting placenta previa. Such bleeding will prompt evaluation and management, else it goes on undiagnosed till third trimester. In our case although low lying placenta was picked up on scan, MAP was not recognised. Both USG and MRI are modalities for prenatal diagnosis of MAP although limitations exist for both techniques. 3-dimensional power Doppler may complement in the antenatal diagnosis of MAP. They identify thinned decidual endometrium, and myometrium, and placental extension into the myometrium. Sonograms can detect loss of hypoechoicity of the myometrium between the bladder and the placental wall. Also, visualization of intra placental sonolucent spaces also referred to as venous lakes, adjacent to the involved uterine-wall is strongly suggestive of placenta accrete. The diagnostic sensitivity and specificity approaches 85 to 90 percent with experienced sonographers. MRI can be used if sonogram findings are uncertain. Signs such as uterine bulging into the bladder, heterogeneous signal intensity within the placenta, and the presence of intra placental bands may predict accreta. Cystoscopy can be used to detect bladder involvement where placenta percreta is strongly suspected. In our case due to late presentation possibility of invasive mole was also considered.

Most common predisposing factor of abnormal placentation is previous Caesarian section and placenta previa, as was in our case. Other factors are prior uterine scars such as uterine curettage, myomectomy, Asherman's syndrome, iatrogenic uterine perforation, manual removal of the placenta, advanced maternal age^{3,4}. In vitro fertilization may be considered as one of reason for increase incidences of placenta percreta in modern scenario^{5,6}. Clark and colleagues studied the relationship between previous cesarean section and placental abnormalities and noted that risk of placental disorders including placenta previa increases with the number of previous cesarean sections⁷.

Comment [AaM28]: Delete

Comment [AaM29]: Please, add a reference to this paragraph.
Please, add a reference to this paragraph.

Comment [AaM30]: CS

Comment [AaM31]: CS

In literature, the first trimester placenta accreta cases have mostly been reported to occur after dilatation and curettage procedures. However, Horneman et al.⁸ reported a case of uterine rupture associated with placenta accreta developing in the second trimester. The common factor in first and early second trimester placenta previa cases is the history of previous cesarean section and/or uterine curettage like in our case. A few of cases of spontaneous rupture of uterus due to placenta percreta have been reported in countries other than USA, like Japan, Turkey, Mexico, and Germany. All these patients underwent hysterectomy. This catastrophic complication from early percreta occurs due to thinning of the myometrium caused by invasion of the placental villi into the myometrium, at the site of placental implantation (particularly at previous scar site) leading to rupture of the uterus. In our case too, we predicted a similar outcome considering the thinned out myometrium on imaging and decided for direct hysterectomy in place of conservative management. Höpker et al. from Germany reported a case presentation at 10 weeks gestation in a patient who was suspected to have molar pregnancy based on USG, CT and MRI as part of the work-up, all of which showed trophoblastic infiltration through the myometrium into the serosa⁹. A D and C was undertaken for suspected molar, which resulted in severe hemorrhage, and the patient needed hysterectomy despite uterine artery ligation. Pathology revealed placenta percreta, without any evidence of hydatiform mole. This is very similar to our case, however she was directly posted for hysterectomy hence avoiding bleeding due to potential haemorrhage from a direct dilatation and curettage. Also, Pont et al. from France noted a case of acute abdomen and hemoperitoneum at 13 weeks gestation¹⁰. Patient underwent laparotomy which diagnosed the placenta percreta and a hysterectomy was performed. All these cases describe unrecognized first or second trimester placenta percreta that led to extensive blood loss, lengthy operations, and caused considerable maternal morbidity.

Comment [AaM32]: CS

Placenta percreta can be managed in two ways, first is surgical removal of the uterus and the surrounding tissues and another is conservative therapy including localized resection of the placental implantation site, oversewing, blunt dissection and packing techniques. The choice between hysterectomy and conservative therapy is dependent on the severity of the placenta percreta and associated complications¹¹. In our case, patient presented 3 months post her abortion with anemia which made her diagnosis even tricky. Although the possibility of molar pregnancy was considered due to late presentation post abortion, her prior history of prev 2 lscs, low lying placenta in present pregnancy on early scan, incomplete curettage record, clinical and lab findings of S. BHCG levels and MRI findings gave us important clues to a more likely possibility of adherent placenta. She was counselled in detail about her condition and hysterectomy seemed to be the best option for her considering continued bleeding for 3 months, possibility of uterine rupture in future and her completed family history. Our elaborate planning in terms of correction of anemia pre-operatively and intra operatively, adequate anesthesia and OT back up, experienced gynaec oncologist to perform the surgery along with detailed counselling of patient and attenders ensured a smooth intra operative and post operative period without any serious maternal morbidity.

CONCLUSION:

Placenta percreta can a silent killer if not detected on time and one should manage such cases in a tertiary care hospital preferably. Anticipation, preparation and action are the key factors involved in successful management of such high risk patients.

Comment [AaM33]: Delete

Comment [AaM34]: high-risk

ACKNOWLEDGMENTS: Authors would like to acknowledge our anesthesiologists Dr.Azam,Dr.Kavita and nursing staff team of Bhagawan Mahaveen Jain Hospital for their support during this surgery.

COMPETING INTERESTS DISCLAIMER:

Authors have declared that no competing interests exist.

REFERENCES:

Comment [AaM35]: delete

1. Obstetrical Hemorrhage. In: Cunningham F, Leveno KJ, Bloom SL, Dashe JS, Hoffman BL, Casey BM, Spong CY. eds. Williams Obstetrics, 25e. McGraw Hill; 2018. Accessed May 15, 2022. <https://accessmedicine.mhmedical.com/content.aspx?bookid=1918§ionid=185083809>
2. Hudon L, Belfort A, Broome R. Diagnosis and management of placenta percreta: a review. *Obstet Gynecol Surv.* 1998;53:509-17.
3. Lamyman, M.J., Mannor, H. and Brown, R. (2005) Abdominal Pain and Dysuria in Pregnancy: Urinary Tract Infection or Life Threatening Haemorrhage? *Emergency Medicine Journal,* 22, 918-927. <http://dx.doi.org/10.1136/emj.2004.017905>
4. Neyazi, S.M. (2013) Placenta Percreta and Uterine Rupture. *Saudi Medical Journal,* 34, 753-756
5. Dahiya, P., Nayar, K.D., Gulati, A.J.S. and Dahiya, K. (2012) Placenta Accreta Causing Uterine Rupture in Second Trimester of Pregnancy after in Vitro Fertilization: A Case Report. *Journal of Reproduction and Infertility,* 13, 61-63.

6. Medel, J.M., Mateo, S.C., Conde, C.R., Cabistany Esqué, A.C. and Ríos Mitchell, M.J. (2010) Spontaneous Uterine Rupture Caused by Placenta Percreta at 18 Weeks' Gestation after in Vitro Fertilization. *Journal of Obstetrics and Gynaecology Research*, 36, 170-173. <http://dx.doi.org/10.1111/j.1447-0756.2009.01082.x>
7. S. L. Clark, P. P. Koonings, and J. P. Phelan, "Placenta previa/accreta and prior cesarean section," *Obstetrics and Gynecology*, vol. 66, no. 1, pp. 89–92, 1985. View at: Google Scholar
8. Hornemann A, Bohlmann MK, Diedrich K, Kavallaris A, Kehl S, Kelling K, et al. Spontaneous uterine rupture at the 21st week of gestation caused by placenta percreta. *Arch Gynecol Obstet* 2011; 284(4):875-8. [CrossRef]
9. M. Höpker, G. Fleckenstein, W. Heyl, B. Sattler, and G. Emons, "Placenta percreta in week 10 of pregnancy with consecutive hysterectomy," *Human Reproduction*, vol. 17, no. 3, pp. 817–820, 2002. View at: Google Scholar
10. M. Pont, E. Kouadio, M. P. Fernandez et al., "Placenta percreta at first trimester of pregnancy. Diagnostic and decision-making difficulties: about a case and a review of the literature," *Journal de Gynecologie Obstetrique et Biologie de la Reproduction*, vol. 39, no. 6, pp. 498–502, 2010. View at: Publisher Site | Google Scholar
11. Kazandi, M. (2003) Placenta Percreta: Report of Two Cases and Review of the Literature. *Clinical Experimental Obstetrics Gynecology*, 30, 70-72

Comment [AaM36]: please, write the names and abbreviations of names as done in other references.

Comment [AaM37]: please, write the names and abbreviations of names as done in other references.

Comment [AaM38]: please, write the names and abbreviations of names as done in other references. & write all authors instead of et al.