

Case report

A Case of Lung Cancer with Covid-19: Symptom and Imaging Analysis -Dilemma of Managing Multiple Comorbidities

Comment [DMGH1]: Please omit

Comment [DMGH2]: Not required

Comment [DMGH3]: A dilemma

Abstract:

The most common symptoms of COVID-19 patients are coughs, colds, fevers, flu-like symptoms, and severe pneumonia. In addition, our patient presented with complications from his comorbidities, such as diabetes leading to diabetic foot and emphysematous osteomyelitis. The patient was diagnosed as COVID-Positive during his regular follow-up. Meanwhile, the patient developed respiratory symptoms with CT scan findings of presumptive lung cancer. It was a diagnostic dilemma to treat the current infection or treat the patient as having severe COVID-19 pneumonia. However, continuing antibiotics and planning for further workup on lung cancer were helpful in our case. Our follow-up parameters have monitored arterial blood gas, calcitonin level, and other inflammatory markers to exclude COVID-related causes. We present this case to establish the best possible treatment plan for asymptomatic COVID patients with other co-morbidities and respiratory symptoms.

Comment [DMGH4]: Co-morbidities

Comment [DMGH5]: infections

Introduction:

According to the WHO, Covid 19 is an infection caused by the SARS-CoV-2 virus which causes mild symptoms in the majority of the cases. However, lung cancer with covid usually presented with severe respiratory disease due to an immunocompromised state from disease pathogenicity or its therapy. During this pandemic period, it was evident that lung cancer patients are suffering from increased mortality due to less available respiratory treatment resources or delay in diagnosis due to a lack of regular primary care. Considering covid-19 infection in the context of lung cancer is creating a dilemma to provide appropriate cancer-specific treatment such as immunotherapy, chemotherapy, radiation, or targeted therapy. According to several systemic meta-analyses, smoking-related damage of alveolar structures and immunologic response of smokers' lungs are susceptible to severe covid-19 infection (RR=2.4, CI: 1.43-4.04) [1]. It is also obvious that symptoms of long-covid and lung cancer are usually overlapped with ongoing cough, dyspnea, fatigue, and pleuritic chest pain. We are presenting a case of a diabetic and hypertensive 65-years old male who presented with fever, dyspnea, and non-healing leg ulcer for 5 days was eventually tested positive for Covid and a pulmonary lesion on initial investigations.

Comment [DMGH6]: WHO (World Health Organization)

Comment [DMGH7]: Covid19 infections

Comment [DMGH8]: In the

Comment [DMGH9]: Needs references

Comment [DMGH10]: Long term

The chronic wound prevalence is more among diabetic and older than 65 years old patients [2,3]. Recently with Covid-19 pandemic chronic wound patient are more susceptible to get infected with SARS-Cov-2 with no obvious contact history due to essential hospital or urgent care visit. After extensive literature search, there are no evidence that Covid-19 causes chronic ulcer or treatment of Covid -19 improves outcome of patient with chronic ulcer. However, the outcome of a patient with chronic

Comment [DMGH11]: Due to ??????????

Comment [DMGH12]: omit

ulcer depends on a number of **comorbidities** such as Diabetes, Hypertension with Covid-19 [4].

Comment [DMGH13]: Co-morbidities

Case Presentation:

We are presenting a case of a 65-years-old male with a past medical history of Diabetes, Hypertension, Dyslipidemia, Methadone dependence who presented with increased severity of chronic cough for 2 weeks. However, there is no history of chest pain, shortness of breath, sore throat, or fever. He **also** didn't mention any history of loss of consciousness, weight loss, blood in sputum, or contact with tuberculosis or Covid patients in the last six months. He also mentioned having chronic non-productive cough early in the morning with no changes in the last 3 years. He is a former smoker with a history of smoking for 40 years with 20 packs/year.

Comment [DMGH14]: omit

He has **endorsed** an increased amount of foul-smelling discharge from his chronic non-healing ulcer for the last 7 days. He is allergic to fish-derived products with a history of moderate to severe allergic reactions 25-years ago. He lives alone in an apartment with no available social contact at this point. There is no history of recent travel, contact with covid patients, or covid symptoms for the last 6 months. Additionally, the patient received all vaccinations including booster doses of covid, pneumococcal, and flu vaccine in the last 2 years.

Comment [DMGH15]: ???????????

Our patient was diagnosed and treated for a diabetic foot ulcer and had undergone subsequent amputation of all toes of the left foot two months ago. He was also admitted and treated with intravenous antibiotics for two weeks for his diabetic foot and suspected osteomyelitis. However, discharge from his foot ulcer increased last week with leg edema and discomfort. According to the patient, discharge is blood-stained and foul-smelling with an amount of 10-15 ml per day. He has been suffering from difficulty in walking due to leg edema for the last six weeks.

Physical Examination on admission: On examination

Comment [DMGH16]:

Comment [DMGH17]: omit

On general examination, Patient was alert, conscious, atraumatic, normocephalic, in acute distress for his leg pain and chronic cough. His Blood pressure was recorded at 119/63, Pulse: 87/min, Respiratory rate 18/ min, Heart sound: S1+S2, no added sound, Lung- clear, mild crackles over the upper lobe of the left lung.

Foot Examination: Plantar aspect of the midfoot is ulcerated approximately 10x8 cm, with erythema and subcutaneous edema throughout the hindfoot and midfoot. There are also foul-smelling discharge with visible necrotic tissue. On palpation, the ulcer is tender, no bleeding on touch.

Lab Reports:

Comment [DMGH18]: ??????Laboratory

His routine blood work was showing WBC count normal with neutrophilia, hemoglobin is low but reticulocyte count is 2.21%; Serum creatinine and other metabolic panels were

in normal level except low albumin level. However, he was tested positive for covid 19 on Day 1, and on Day 3 of his admission, he developed non-anion gap respiratory alkalosis. All screening tests including HIV, Hepatitis B, Respiratory syncytial virus, influenza A and B were negative.

Table 1 . Lab test report

Lab test	Reference level	Jan 5, 2022 Day 1	Jan 7, 2022 Day 3	Jan 10, 2022 Day 5	Comments
<u>CBC</u>					
WBC	4.5-11.0 10x3/uL	8.8	9.9	10.1	Increased
RBC	3.8-5.3 10x6/uL	3.34	3.05	2.78	Decreased
HGB	11-15	8.5	7.8	7.8	Decreased
HCT	35-46%	27.2	24.7	24.3	Decreased
MCV	75.2	81.2	81.0	81.3	Normal
RDW	11.5-15.1	17.9	18.3	17.7	Increased
Platelet	130-400 10X3 u/L	298	314	273	Normal limit
<u>Differentials</u>					
Neutrophils	40-70%	6.80	7.50	7.70	Increased
Lymphocytes	22-48	0.80	0.90	0.80	Decreased
Retic Count%	0.5-2%			2.21	Increased
<u>Gen Chem</u>					
Glucose	80-115	123	98	119	Increased
BUN	9.8-20.1	7.5	10.8	10.6	Normal
Creatinine	0.57-1.11 mg/dl	0.87	0.81	0.79	Normal
Sodium	136-145 mmol/L	138	137	136	Normal
Potassium	3.5-5.1 mmol/L	4.4	4.1	3.9	Normal
Chloride	98-107 mmol/L	100	98	96	Normal
CO2	23-31 mmol/L	31	33	30	Increased

Comment [DMGH19]: ???????????

Comment [DMGH20]: ???????????????????

Comment [DMGH21]: Full name

Calcium	8.8-10 mg/dl	8.6	8.5	8.7	Decreased
Anion gap	12	7.00	6.00	10.00	Normal
Phosphorus	2.3-4.7 mg/dl	2.6	2.5	2.3	Normal
Albumin	2.9-4.5 g/dl	2.2	2.1	2.0	Decreased
Bilirubin	0.2-1.2 mg/dl	0.7	0.8	0.5	Normal
ALT	10-55 U/L	12	10	10	Normal
Alk phos	40-150 U/L	46.6	41.4	41.7	Normal
LD	140-280 U/L			455	Increased
Creatinine kinase	24-198 U/L			22.9	Decreased
<u>Arterial Blood gas</u>		Day 1	Day 7	Day 10	
pH	7.35-7.45	7.38	7.38	7.40	Normal
pCO2	35.0-45.0	52.0	51.9	38.9	Normal
pO2	80.0-100.0	52.3	130.0	108.0	Normal
HCO3 Arterial	22.0-28.0	29.5	29.7	23.3	Normal
O2 Sat	92-98.5%	86.1	98.9	98.6	Normal
Total CO2	19-25	31.4	31.3	24.5	Increased
Covid 19		Positive	Positive	Positive	

Comment [DMGH22]: Rapid antigen/RT-PCR

D-Dimer(ng/ml)	4856	<500
ESR(mm/hr)	50	0-22
CRP (mg/L)	5	<3
Procalcitonin(ng/ml)	0.06	0.00-0.08
Creatine kinase U/L	37	30-200

Imaging:

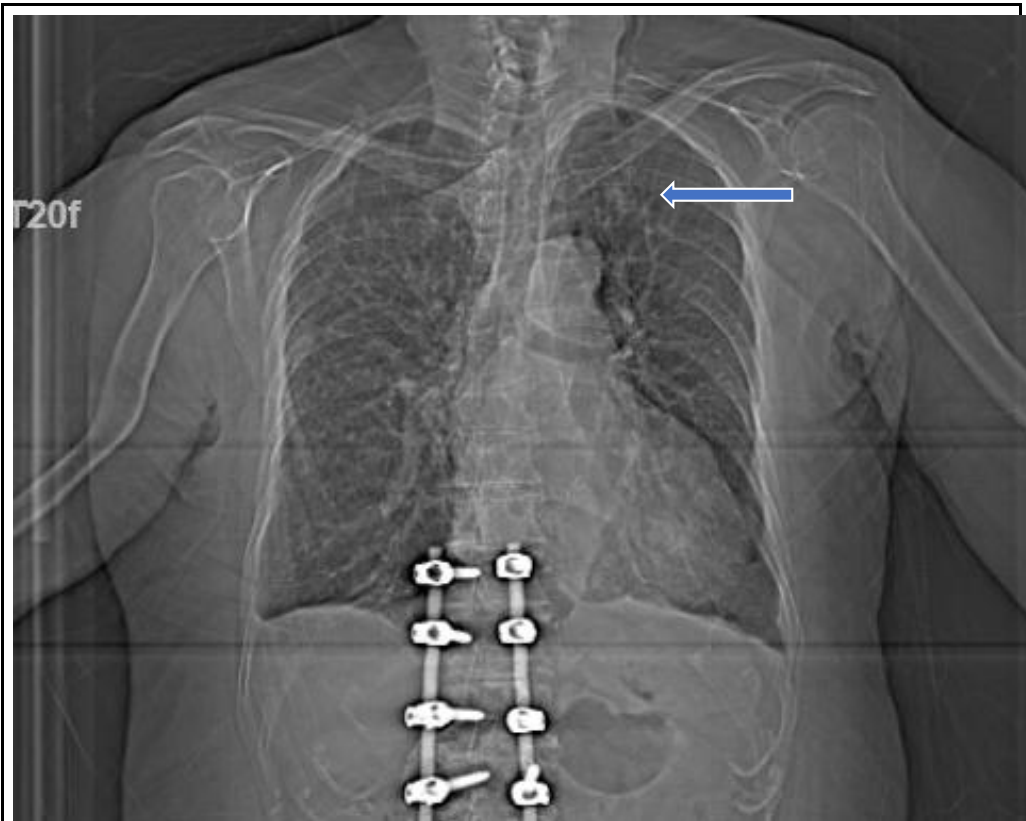


Figure 1: Chest X-ray: Day 1: There is 7 cm mass in the left upper lung field (Arrow)

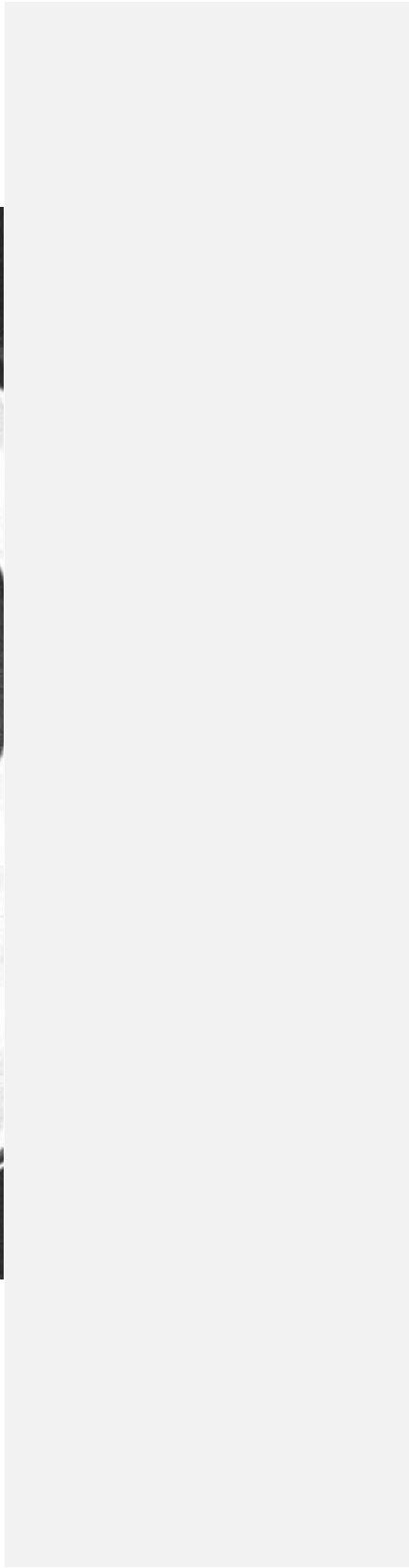
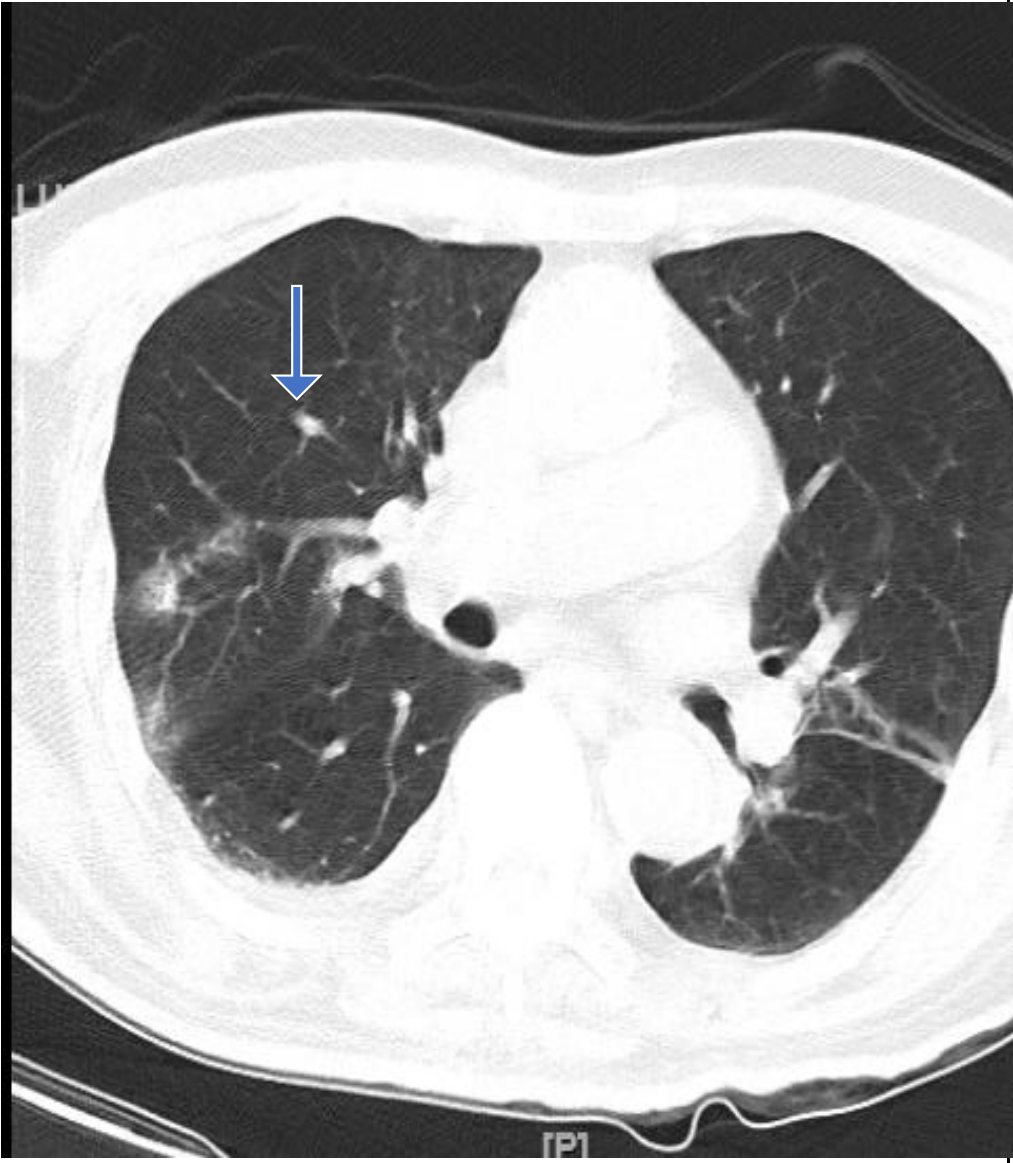


Figure 2:CT Scan: On Day 1:

*There is a Heterogeneous irregular soft tissue density mass, measuring at least 5.5x4.3x5.2 cm
(Arrow)*

CT scan of left lower extremity without intravenous contrast: There are erosive/destructive changes at the base of the 5th metatarsal as well as within the cuboid, cuneiforms, and anterior calcaneus, extensive scattered areas of gas throughout the hind foot and midfoot with cellulitis; suggestive of emphysematous osteomyelitis. Echocardiogram: Left ventricular systolic dysfunction with lateral wall hypokinesia Ejection fraction of 40-45%. Mild tricuspid regurgitation. Large pleural effusion.

On the hospital day of 13, CTPA was performed in the view of increasing shortness of breath that concluded no acute pulmonary embolism or aortic dissection but Interval development of large loculated left pleural effusion and no significant interval changes noted in the left upper lobe and Lingula along with Tiny right pleural effusion.

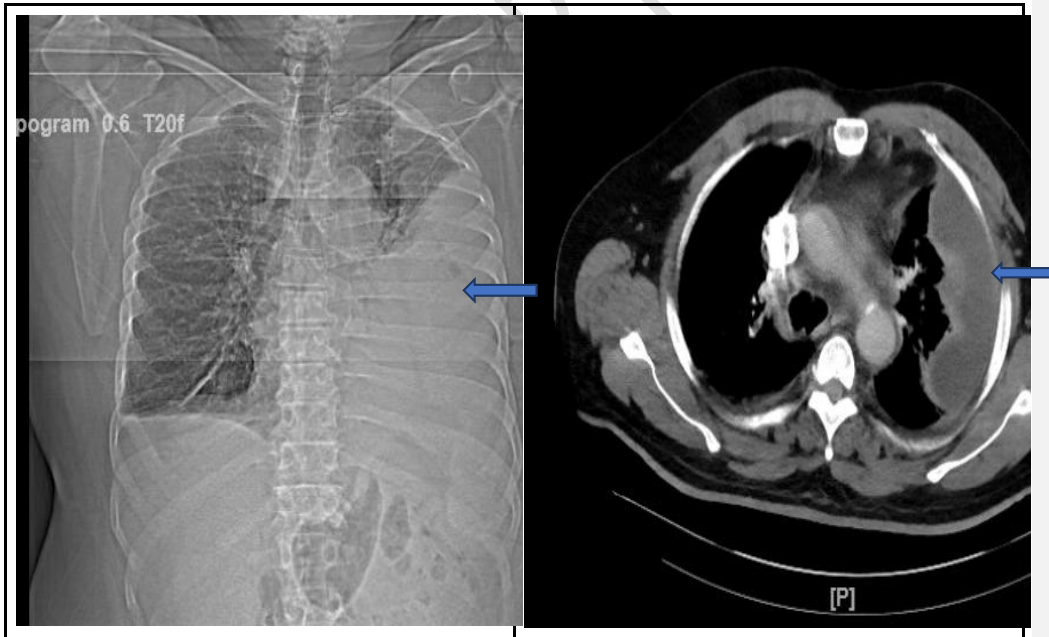


Figure 3: CT angiogram chest with contrast showing large loculated left pleural effusion (Blue Arrows)

Further Plan and Management:

The patient was admitted two months ago for osteomyelitis and was treated with intravenous antibiotics, however, his last chest x-ray 2 months ago had shown 1.5 cm of hilar mass. The patient had readmission after 2 weeks due to an increased amount of foul-smelling discharge from the left plantar surface. We have found his last LDH was 2.38, ESR 114, and WBC 25.2, and repeat LDH and complete blood count were ordered. We have decided his working diagnosis would be emphysematous osteomyelitis with lung carcinoma and covid with h/o substance abuse such as cocaine and opiates.

The patient was initiated with 2L of normal saline as per sepsis protocol. In addition, we have started with broad-spectrum antibiotics such as Vancomycin, Zosyn, and Flagyl. Infectious disease and Orthopedic surgery were involved in his care. The plan was to continue antibiotics, hydration, and debridement of the necrotic tissue as much as possible. The pulmonologist recommended doing an interventional radiologist-guided biopsy of the lung mass but the patient refused to do due to low back pain and difficulty in lying prone position. The patient was advised to follow a diabetic diet and Lantus prescribed 10 units with regular monitoring of blood glucose during fasting, 2 hours after breakfast, and before bedtime to control blood sugar. The coming plan is to use VeNodyne boots as venous thromboembolism prophylaxis after surgery. In addition, he is also diagnosed with anemia of chronic disease which needs close monitoring and transfusion if needed before surgery.

After 5 days of treatment, the patient deteriorated and was admitted to ICU for further management of his severe respiratory distress (SpO₂=93%, Respiratory rate: 26/ min) as well as sepsis. The patient was on antibiotic therapy and viral pneumonia excluded with monitoring of D-Dimer, CRP, ESR, Ferritin, Procalcitonin, LDH level, and regular CBC count. On day 11, the patient's symptoms improved and he was discharged to follow up in the outpatient facility.

Discussion:

Covid-19 patients usually present with respiratory symptoms, however our patient presented with sepsis from leg ulcer. According to evidence-based medicine we have provided treatment of sepsis and management of leg ulcers. We have found that atypical presentations of Covid -19 positive with no respiratory presentation or history of contact or past exposure could present with predominant co-morbidity. It is obvious to follow up his lung lesion, blood sugar and focus of infection of left foot.

Comment [DMGH23]: ?????pharmacological termination

In the literature, Covid 19 patient presented with higher mortality with lung cancer [5] due to delay in diagnosis and compromised lung condition. In our case, patient also presented with sepsis related respiratory distress, however treating the most relevant condition improves outcome. It was evident from all literature that the fatality rate of lung cancer with SARS-CoV-2- significantly rise steadily with age more than 65 years [6]. Several recommendations regarding lung cancer treatment with Covid-19 prioritize to follow evidence based treatment protocol for symptomatic management. These recommendations are helping to make informed decisions and also reducing mortality related to Covid-19 and comorbidity [7,8].

Several reported skin lesions and chronic ulcer related with Covid is due to vascular vasoconstriction due to Angiotensin Converting Enzyme-2 downregulation (ACE-2 receptor) which leads to accumulation of angiotensin-2. The viral activity can cause vasculitis, vessel thrombosis, and immune dysregulation. Most commonly found lower extremity lesions are livedo reticularis, pressure ulcer, painful pernio-like lesions [9,10,11]. However, diabetic foot ulcer is 7.5 times more common than other causes in a diabetic patient and the recommendation is to follow up every 2-weeks and more frequent debridement to reduce complications [12].

Comment [DMGH24]: Space

Conclusion:

Treating Covid with critical comorbidities is challenging. Our case report may contribute to the evolving experience of Covid infection in terms of its variant association. In this case, lung carcinoma was an association making the management plan complicated. Moreover, Septicemia contributed to prolonged recovery time and hospital stay. We can conclude that chronic condition like underlying undiagnosed lung cancer can be found incidentally but it might obviate extreme outcome of other infection specially like covid19. However, treating the most apparent complication first and monitoring other possibilities is the best approach to disease management.

Comment [DMGH25]: Covid 19

Comment [DMGH26]: There may be primary disease which should be look for and manage meticulously.

Reference:

1. Vardavas CI, Nikitara K. COVID-19 and smoking: a systematic review of the evidence. *Tob Induc Dis* 2020;18:20. [doi:10.18332/tid/119324](https://doi.org/10.18332/tid/119324)

2. Hicks CW, Selvarajah S, Mathioudakis N, et al. Burden of Infected Diabetic Foot Ulcers on Hospital Admissions and Costs. *Ann Vasc Surg.* 2016;33:149-158. doi:10.1016/j.avsg.2015.11.025

3. Nussbaum SR, Carter MJ, Fife CE, et al. An Economic Evaluation of the Impact, Cost, and Medicare Policy Implications of Chronic Nonhealing Wounds. *Value Health* 2018; 21:27. DOI: [10.1016/j.jval.2017.07.007](https://doi.org/10.1016/j.jval.2017.07.007)

4. Guan WJ, Liang WH, Zhao Y, et al. Comorbidity and its impact on 1590 patients with COVID-19 in China: a nationwide analysis. *Eur Respir J.* 2020;55(5):2000547. Published 2020 May 14. doi:10.1183/13993003.00547-2020

5. Horn L, Garassino M. COVID-19 in patients with cancer: managing a pandemic within a pandemic. *Nat Rev Clin Oncology* 2021;18:1–2. doi:10.1038/s41571-020-00441-5

6. LYW L, Cazier JB, Starkey T. COVID-19 prevalence and mortality in patients with cancer and the effect of primary tumor subtype and patient demographics: a prospective cohort study. *Lancet Oncol* 2020;2020. Doi: [10.1016/S1470-2045\(20\)30442-3](https://doi.org/10.1016/S1470-2045(20)30442-3)

7. Garassino MC, Whisenant JG, Huang L-C, et al. COVID-19 in patients with thoracic malignancies (TERAVOLT): first results of an international, registry-based, cohort study. *Lancet Oncol* 2020;21:914–22. doi:10.1016/S1470-2045(20)30314-4

8. Kuderer NM, Choueiri TK, Shah DP, et al. Clinical impact of COVID-19 on patients with cancer (CCC19): a cohort study. *Lancet* 2020;395:1907–18. doi:10.1016/S0140-6736(20)31187-9

9. Vaduganathan M, Vardeny O, Michel T, et al. Renin-Angiotensin-Aldosterone System Inhibitors in Patients with Covid-19. *N Engl J Med* 2020; 382:1653. DOI: [10.1056/NEJMr2005760](https://doi.org/10.1056/NEJMr2005760)

10. Young S, Fernandez AP. Skin manifestations of COVID-19 [published online ahead of print, 2020 May 14]. *Cleve Clin J Med.* 2020;10.3949/ccjm.87a.ccc031. doi:10.3949/ccjm.87a.ccc031

11. Tang K, Wang Y, Zhang H, Zheng Q, Fang R, Sun Q. Cutaneous manifestations of the Coronavirus Disease 2019 (COVID-19): A brief review. *Dermatol Ther.* 2020;33(4):e13528. doi:10.1111/dth.13528

12. Warriner RA 3rd, Wilcox JR, Carter MJ, Stewart DG. More frequent visits to wound care clinics result in faster times to close diabetic foot and venous leg ulcers. *Adv Skin Wound Care*. 2012;25(11):494-501. [doi:10.1097/01.ASW.0000422629.03053.06](https://doi.org/10.1097/01.ASW.0000422629.03053.06)

UNDER PEER REVIEW