

Study on Septal Correction: Review of literature and clinical findings

Abstract

Septal reconstruction has many needs and usages. Nowadays, people are very concerned about looking and would like to correct them. Septal reconstruction has been immensely used in the field of cosmetics. A successful septoplasty would lead us to know about the pathology of the septum by which we can avoid further complications. It would be further significant in nasal obstruction or difficulty in breathing. Deviation of the nasal septum can also be corrected by septal reconstruction by various techniques used for septoplasty. Complete septal reconstruction is the best method for extreme S-shaped and wave-like deviations or multiple fractures. The septoplasty is performed endonasal for caudal septal deviation. Traction sutures to rectify the caudal septum deviation is another type of surgery. Septoplasty usually opens the way for all other rhinoplasty procedures, as a straight, stable septum reflects the attractiveness and functionality of the nose. The patient's history and the surgeon's expertise play a favorable outcome. In conjunction with other nose procedures, such as cosmetic rhinoplasty and endoscopic sinus surgery, Septoplasty is frequently done to alleviate nasal airway obstruction or headaches induced by rhinology irritation produced by touch. Endoscopic septoplasty requires the same amount of time and delivers equal, if not better, results than previous procedures. Visualization is vastly improved by endoscopic technology. Isolated deviation, spurs, perforations, and contact sites are examples of distinct septal disorders that can be treated individually using this procedure. In this review article, the importance of traction sutures is mentioned. The article gives us an idea about Septoplasty and how it can be achieved, its complications, risk factors, and a few postoperative points.

Key Points - Septoplasty, Nasal Septal Deviation, Endoscopy, Septal Correction.

Introduction

The septum is made up of three parts:

- Columellar Septum⁽¹⁾
- Membranous Septum⁽¹⁾
- Septum Proper comprises a cartilaginous framework covered by the nose's mucous membrane. Its constituents are:
 1. The perpendicular plate made up of ethmoid bone⁽¹⁾
 2. Vomer⁽¹⁾
 3. A sizeable septal cartilage wedged between the above two bones anteriorly.⁽¹⁾

Septal correction is a beneficial and convenient method for any sort of septal defect. Correction of pathologies is easily achieved by this method. There are various methods by which this can be achieved, and septoplasty is commonly used. Septal repair is a very beneficial and convenient approach for any type of septal defect. Many innovative techniques like bone grafts, ethmoid bone grafts, caudal septal batten grafting, and endoscopic septoplasty are used for this procedure. The type and size of the malformation, the patient's target, and the surgeon's choice and experience of all methods of septoplasty. This can be accomplished in various ways, with septoplasty being one of the most popular.

Deviated Nasal Septum usually causes nasal obstruction.

Types of nasal septal deviation (NSD):

- S-shaped deformity⁽¹⁾
- Spur⁽¹⁾
- Anterior dislocation⁽¹⁾
- C-shaped deformity⁽¹⁾
- Thickening⁽¹⁾

Indications of Septoplasty

- Severe S-shaped deformity
- Severe wave-like deformity
- Multiple fractures
- C-shaped deformity
- Cosmetic surgery
- Thickening
- Spur
- Difficulty in breathing
- Anterior dislocation of the septum

Objective

The objective of writing this piece of literature is to study the methods of septal correction and septoplasty methods To study a better approach for the same.

Materials and Methodology

In this article, we have gained the literature on Nasal Septal Reconstruction from PubMed, Lancet, StatPearls [Internet], Elsevier, Google Scholar, Sage journals. While searching various databases. The keywords and phrases were used in different platforms and amalgamation: septal correction, nasal septal deviation, septoplasty, endoscopic septoplasty. A potential source of information was also the reference list of pertinent articles. There were no attempts to find unpublished data.

Discussion

There are different types of septal deviation, and there are different methods to correct them. NSD is caused by trauma; it is a congenital anomaly; it can be hereditary and pathologic for some. The patient usually complains of feeling a foreign body in the nasal cavity and

Comment [DWM01]: 1.It is better to mention the inclusion and/or exclusion criteria used in the study?
2.Please mention how many published articles/literature include in this study
3.How many has been excluded for what reason(s)
4.The best way is drawing a algorithm!

It can lead to difficulty in breathing. Collet's test is performed to confirm NSD in a patient. Nowadays, people are very conscious about the way they look. Hence it plays a vital role in the cosmetic industry.

Etiology for NSD:

- ❖ Trauma - It can be caused at birth. Trauma can take place by a sidewise punch on the nose.⁽¹⁾
- ❖ Developmental error - Nasal septum buckling can be caused by unequal growth between the palate and the skull base. The palate is frequently and strongly arched in mouth breathers, as it is in adenoid hypertrophy. There is deviated septum.⁽¹⁾
- ❖ Racial factor- It is more common in Caucasians.⁽¹⁾
- ❖ Hereditary factors - nasal septal deviation can be present in another family members.⁽¹⁾

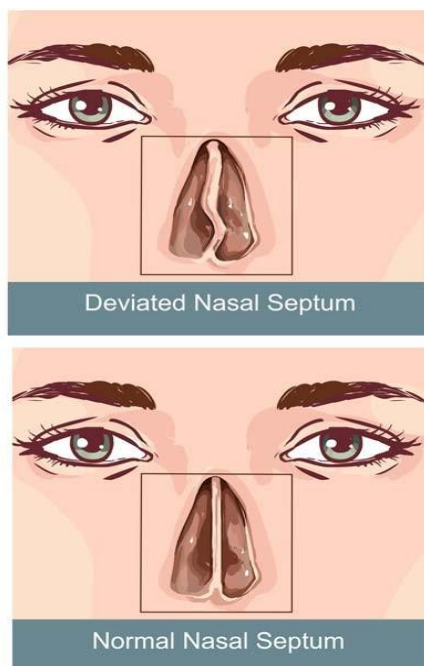


Fig no. 1 ⁽²⁾

Surgeries for Nasal Septal Deviation

Usually, septoplasty paves the way for every other surgery in rhinoplasty as a linear, stable septum tells about the attractiveness and functioning result. The excellent result is determined by the patient's history and the expertise of the surgeon.

According to **Heppt W, Hildenbrand^t**, For deviations like extreme S-shaped and wave-like deviation or multiple fractures, complete septal reconstruction is the best method to use. If there are cases, like uncomplicated C and S-shaped deformities, can be treated endonasal. The septal malformations where the types are complicated s-shaped or multiple fractures septoplasty are among the best methods. It can be even suitable for wave-like deviation. Acaudal septal batten graft procedure tells us about the low risk of complications⁽⁴⁾. Here the septoplasty is performed endonasal for caudal septal deviation. They carried out this procedure under general anesthesia. The endonasal technique was used to make a unilateral hemitransfixion incision 2 to 3 mm posteriorly to the caudal region of the concave side of the nasal cavity. This incision revealed the whole of the caudal margin of the septum from the anteriorseptal angle to the anterior nasal spine. Mucosal elevation has been conducted on the convex side till just posterior to the maximally convex portion. After conserving a section of the L-strut of the dorsal and caudal cartilaginous septum that was at least 1.5 cm long, the curved portion of the septal cartilage and bone was extracted. Subperichondrial dissection into the nasal floor was conducted after bilateral flap elevation to the point where a bone graft could be placed. The harvested septal bone caudal septal batten graft was fitted to the desired site, usually on the concave side (but both sides if graft tilt was an issue), and fastened with 5-0 polydioxanone sutures. 1 or 2 through-and-through transcartilage and transbony sutures were used to repair the gap between the posterior section of the caudal septal bony batten graft and the caudal septum (5-0 polydioxanone sutures). 6-0 chromic gut sutures (Ethicon Inc) were used to close the hemitransfixion incision, and 2 or 3 through-and-through transmucosal sutures (4-0 chromic gut sutures) were utilized to secure both

mucosae to the newly formed caudal septum.⁽⁴⁾ Caudal septal deviation surgery can be performed endonasal. This surgery is usually carried out under general anesthesia. Here a unilateral hemitransfixation incision is used. Septoplasty has been proved crucial in the treatment of crooked noses. **Lee JW, Baker SR**⁽⁵⁾ suggested nasal septal bone grafts can help rectify caudal septal deviation and stabilize severe cartilaginous malformations or deviations. Nasal septal bone transplants are used to correct septal deviation. Caudal septal deviation and severe cartilaginous abnormalities or deviations can both benefit from nasal septal bone transplants. To rectify septal deviation, nasal septal bone grafts are employed. The septal bone can be used to rectify the caudal bone graft⁽⁵⁾.

Aksakal C, Akti S.⁽⁶⁾ described the use of traction suture to rectify the caudal septum deviation. The patients' preoperative nasal obstruction symptom evaluation (NOSE) scores were compared to their six-month postoperative NOSE scores. Furthermore, the findings of the patients' preoperative nasal examinations were compared to those in the postoperative period. This method was found out to be safe to treat caudal septum deviation.

Vatamanesku IV, Ciurea M, Popa DG, Nica OL, Parasca SV⁽⁷⁾ suggested that the most common method for correcting complex septal and pyramid defects is extracorporeal septoplasty. Extracorporeal septoplasty has demonstrated its worth in crooked noses even in limited series. However, it requires ingenuity and a precise dissection approach⁽⁷⁾.

The lateral cartilage on the lower side can be corrected using Columellar strut graft⁽⁸⁾. The partial cutting and suture approach is simple and successfully correct caudal septal deviation⁽⁹⁾.

As opposed to the typical open approach, endoscopic septoplasty allows for a better view of nasal anatomy and is especially useful for problems with the posterior septum⁽¹⁰⁾.

Iimura J, Miyawaki T, Kikuchi S, Tsumiyama S, Mori E, Nakajima T, Kojima H, Otori N⁽¹¹⁾ told us that the main downside of the Killian incision is the failure to reach the caudal septum and correct the caudal septal deviation. In such circumstances, open and hemitransfixion

Septorhinoplasty is regarded as required. Due to this difficulty

'J-shaped'⁽¹¹⁾ incision has been giving results. The J septoplasty procedure for minor caudal septal deviation is simple to execute using a modified

Killian incision and appears to be effective in some patients.

Van Egmond MM, Rovers MM, Hannink G, Hendriks CT, vanHeerbeek N⁽¹²⁾

conducted an experiment where they found out that septoplasty is more effective than non-surgical treatment for nasal obstruction in people with a deviated septum.

Yazici A, Er HC⁽¹³⁾ suggested that different values may be seen in different sections of nasal tomography scans. However, it is still debatable whether the clinical usage of tomography scans might be employed as one of the indication criteria for septoplasty surgery.⁽¹⁴⁾ The evidence for the

The superiority of suturing procedures over standard septoplasty packing is now substantial, and suturing techniques as a first-line intervention are becoming recommended⁽¹⁴⁾.

Septoplasty performed with Endoscopic Method

Septoplasty is frequently used in conjunction with other nose surgeries, such as aesthetic rhinoplasty and endoscopic sinus surgery, to treat obstruction in nasal airway or headache due to rhinology reasons caused by irritation due to contact. **Raynor EM⁽¹⁵⁾** suggested a traditionally

performed using a "headlight" approach before these procedures. In cases

of solitary septal spurs or modest septal deviations, power-assisted

endoscopic septoplasty is a beneficial adjuvant. Traditional headlight

septoplasty is preferable for patients with a significant nasal blockage caused by the septum's caudal displacement from the nasal spine.

Getz AE, Hwang PH⁽¹⁶⁾, performed the other endoscopic surgery.

He said that endoscopic septoplasty pro,cedures, and apparatus are discussed, as well as the indications for endoscopic septoplasty and its perks over conventional headlight septoplasty. By this method, it is much more likely to stay away from recurrent symptoms and new

Complications. Endoscopic septoplasty takes the same time and produces similar results as older methods, if not better. Endoscopic technology substantially improves visualization. In this method, isolated deviation, spurs, perforations, and contact sites are examples of discrete septal diseases that can be handled in a targeted manner.

Gupta N⁽¹⁷⁾ were keen to tell us that in complicated abnormalities, endoscopic septoplasty has a restricted role. However, it is unquestionably a supplement to the standard method because the condition of the septum may be readily determined during surgery. As a result, the deformity can be better corrected. Septoplasty is frequently used in conjunction with ESS to gain access to the surgical site and improve postoperative nasal cavity cleaning. Endoscopic septoplasty is becoming more popular as a supplement to ESS. It provides a better view than the classic headlight procedure; when used with video monitors, endoscopic septoplasty is also a great teaching tool.

Endoscopic septoplasty is the advanced method of regular septoplasty surgery. It is less invasive and better to operate with. This method improves visualization. Sometimes it is preferred over the traditional headlight procedure. Endoscopic septoplasty is helpful in the removal of focal spurs; this is done when the incision is given just above the spur apex.⁽¹⁸⁾ **Prepageran N, Lingham OR⁽¹⁹⁾** stated that complications due to the endoscopic method are significantly less, increasing the visualization.

Endoscopy improves the assessment of posterior nasal septal abnormalities, identifies the degree of mucosal involvement of the inferior turbinates' posterior ends, and assesses the middle meatus simultaneously. It allows for unbiased evidence of the etiology of nasal blockage, which can then evaluate the outcome. The endoscope can readily pass through the septal flaps with only a small amount of flap retraction necessary for optimum visibility. With this, as the incision can be made way posterior than others which is just anterior to the deviation, mucosal elevation from the anterior side is reduced. Due to this, there are significantly fewer chances of edema. **Hong YK, Jeun SS, Park JS, Kim SW, Cho JH, Park YJ, Kim SI, Kim SW⁽²⁰⁾** suggested the solution to

Treating a deviated nasal septum is the separation of a deviated complex surrounding the sphenoidal process of the septal cartilage. The posterior septectomy (which includes the removal of this deviated complex) can be accomplished using endoscopic endonasal transsphenoidal approach (EETSA)⁽²⁰⁾ in combination with the two nostrils–four hands approach.

Thus, as it happens in cases of severe nasal septum abnormalities, EETSA can begin without prior septoplasty.

Complication

Intranasal drug users, especially people using cocaine, are highly contraindicated⁽²¹⁾. Patients with rhinosinusitis and vasculitis with no appropriate medical treatment are contraindicated⁽²¹⁾.

Vasoconstriction decongestant nasal spray should be avoided⁽²¹⁾. CSF leak is one of the complications followed by septoplasty surgery which was commonly seen in patients aged 2.5 to 20 years old; it was usually expected in the right side of the brain⁽²²⁾. Unilateral blindness⁽²³⁾. In Crouzon Syndrome, there is a Cerebrospinal Fluid Leak Following Septoplasty⁽²⁴⁾. It is one of the infrequent complications.

Post Operation

Dubin MR, Pletcher SD⁽²⁵⁾ suggested that the use of nasal covering after septoplasty has been proposed for a variety of reasons. Preventing postoperative problems like bleeding and the formation of synechiae or a septal hematoma is one of the most prominent reasons for using packing.

Another reason packing may be utilized to stabilize the remaining cartilage and prevent postoperative deviation. Although it may seem natural that packing could prevent or reduce the occurrence of these issues, the data to support this claim is at best inconclusive. Furthermore, certain forms of nasal packing have been shown to enhance postoperative pain and to be a contributing cause in catastrophic complications such as toxic

Shock. The usual use of postoperative packing following septoplasty should be questioned due to a lack of data to demonstrate a favorable benefit and the potential for adverse side effects. Risk factors are:

- Toxic shock syndrome⁽²⁵⁾
- Formation of synechiae⁽²⁵⁾
- A septal hematoma⁽²⁵⁾
- Pain⁽²⁵⁾

Nanda MS and Kaur M's⁽²⁶⁾ research concluded that in comparison to other current medicines such as NSAIDs, oral enzymes are extremely effective in managing post-operative inflammation and infection. When oral enzymes are given after surgery, patient satisfaction is substantially higher. When oral enzymes are used, the symptoms of post-operative discomfort, nasal blockage, and nasal discharge are significantly reduced. There is reduced nasal edema and faster healing of post-operative scars when oral enzymes are used. Compared to NSAIDs, they have far fewer adverse effects and are far safer.

Risk

Concerns associated with septoplasty include:

- Symptoms such as nasal blockage that persist⁽²⁷⁾
- Loss of blood⁽²⁷⁾
- A alteration in nose's form⁽²⁷⁾
- The septum has a hole in it⁽²⁷⁾
- Reduced olfactory perception⁽²⁷⁾
- Blood clots in the nasal cavity that must be drained⁽²⁷⁾
- Numbness in the upper gums, teeth, or nose for a short time⁽²⁷⁾
- Adhesions⁽²⁸⁾
- Anesthesia of the tooth and upper lip⁽²⁸⁾
- Complications of the eyes⁽²⁸⁾
- Infection⁽²⁹⁻³⁴⁾

Conclusion

There are various ways to do septoplasty. It is one of the main procedures for septal reconstruction and correction. The incisions given are hemitransfixion incision, Killian incision, and Cottle elevator incision. The way the nose can be altered for the best with the help of septoplasty. It

solves the problem of aesthetic look as well as any pathologic problem. Indications for septoplasty are difficulty in breathing, cosmetic purpose, pathology, obstruction in breathing, and septal deviation. Various techniques used for this procedure are bone grafts, ethmoid bone graft,

caudal septal batten grafting, and endoscopic septoplasty. These techniques are widely used and do a greater good. Regular septoplasty and

septoplasty performed endoscopically has its advantages and disadvantages. Regular septoplasty is majorly used in complicated deviations. It has been used more since it's been an old procedure. It has got many success rates. Endoscopic septoplasty is a more advanced method. It is less invasive. Therefore more looked upon. It is easier to perform and gives more visualization. It is less invasive and better to operate with. This method improves visualization. Sometimes it is preferred over the traditional headlight procedure. More encouragement is given to endoscopic septoplasty nowadays as there are significantly less chances of complication due to better visualization. There is also a good explanation based on if we artificially procure oral enzymes and give them to patients after surgery, it plays a more influential role than NSAIDs. Packing the nose after surgery would eventually decrease the number of

complications like bleeding and hematoma. Both of the methods are important in their way.

Ethical Approval:

As per international standard or university standard ethical approval has been collected and preserved by the authors.

References

1. PL Dhingra, Shruti Dhingra Assisted by Deeksha Dingra, Diseases of ear, nose, and throat and head and neck surgery, 7th edition
2. <https://entspecialistsingapore.com/deviated-nasal-septum/>
3. Hept W, Hildenbrand T. Septal surgery in septorhinoplasty. *Hon.* 2011 Aug 1;59(8):831-43.
4. Kim DY, Nam SH, Alharethy SE, Jang YJ. Surgical outcomes of bony batten grafting to correct caudal septal deviation in septoplasty. *JAMA facial plastic surgery.* 2017 Dec 1;19(6):470-5.
5. Lee JW, Baker SR. Correction of caudal septal deviation and deformity using nasal septal bone grafts. *JAMA facial plastic surgery.* 2013 Mar 1;15(2):96-100.
6. Aksakal C, Akti S. Traction Suture Technique for Correction of Caudal Septal Deviation. *Journal of Craniofacial Surgery.* 2021 Jun 1;32(4):e366-9.
7. Vatamanesku IV, Ciurea M, Popa DG, Nica OL, Parasca SV. Extracorporeal Septoplasty-A Well Proven Technique for Treatment of Crooked Noses. *Current Health Sciences Journal.* 2020 Jan 1;46(1):39-43.
8. Suh MK. Correction of the deviated tip and columella in crooked nose. *Archives of Plastic Surgery.* 2020 Nov;47(6):495.
9. heon T-U, Song YJ, Kang BC, Nam J-G, Lee T-H. Partial Cutting and Suture Technique for Caudal Septoplasty. *American Journal of Rhinology & Allergy.* 2019;33(6):640-643. doi:[10.1177/1945892419857694](https://doi.org/10.1177/1945892419857694)
10. Shah J, Roxbury CR, Sindwani R. Techniques in septoplasty: traditional versus endoscopic approaches. *Otolaryngologic clinics of North America.* 2018 Oct 1;51(5):909-17.
11. Jimura J, Miyawaki T, Kikuchi S, Tsumiyama S, Mori E, Nakajima T, Kojima H, Otori N. A new "J septoplasty" technique for correction of mild caudal septal deviation. *Auris Nasus Larynx.* 2020 Feb 1;47(1):79-83.
12. van Egmond MM, Rovers MM, Hannink G, Hendriks CT, van Heerbeek N. Septoplasty with or without concurrent turbinate surgery versus non-surgical management for nasal obstruction in adults with a deviated septum: a pragmatic, randomised controlled trial. *The Lancet.* 2019 Jul 27;394(10195):314-21.
13. Yazici A, Er HC. The correlation of computed tomography in the evaluation of septoplasty patients. *Nigerian journal of clinical practice.* 2019 Sep 1;22(9):1196.
14. Certal V, Silva H, Santos T, Correia A, Carvalho C. Trans-septal suturing technique in

septoplasty: a systematic review and meta-analysis. *Rhinology*. 2012 Sep 1;50(3):236-45.

15. Raynor EM. Powered endoscopic septoplasty for septal deviation and isolated spurs. *Archives of facial plastic surgery*. 2005 Nov 1.
16. Getz AE, Hwang PH. Endoscopic septoplasty. *Current opinion in otolaryngology & head and neck surgery*. 2008 Feb 1;16(1):26-31.
17. Gupta N. Endoscopic septoplasty. *Indian J Otolaryngol Head Neck Surg*. 2005 Jul;57(3):240-3. doi: 10.1007/BF03008021. PMID: 23120179; PMCID: PMC3451332.
18. Chandra RK. Endoscopic Septoplasty: "How I do it" With Illustration and Video. *American journal of rhinology & allergy*. 2017 Jul;31(4):276-7.
19. Prepageran N, Lingham OR. Endoscopic septoplasty: the open book method. *Indian Journal of Otolaryngology and Head & Neck Surgery*. 2010 Sep;62(3):310-2.
20. Hong YK, Jeun SS, Park JS, Kim SW, Cho JH, Park YJ, Kim SI, Kim SW. Is septoplasty necessary when using the endoscopic endonasal transsphenoidal approach for a deviated nasal septum?. *Journal of Neurological Surgery Part B: Skull Base*. 2018 Dec;79(06):569-73.
21. Watters C, Brar S, Yapa S. Septoplasty. [Updated 2020 Dec 23]. In: StatPearls [Internet]. Treasure Island (FL): StatPearls Publishing; 2021 Jan-. Available from: <https://www.ncbi.nlm.nih.gov/books/NBK567718/>
22. Venkatesan NN, Mattox DE, Del Gaudio JM. Cerebrospinal fluid leaks following septoplasty. *Ear, Nose & Throat Journal*. 2014 Dec;93(12):E43-6.
23. Kilavuz AE, Yildirim D, Serin GM, Kaytaz A. Unilateral Blindness After Septoplasty. *Journal of Craniofacial Surgery*. 2017 Oct 1;28(7):e634-6.
24. Demir B, Abuzaid G, Binnetoglu A. Cerebrospinal Fluid Leak After Septoplasty in Crouzon Syndrome. *Journal of Craniofacial Surgery*. 2021 Jan 1;32(1):329-30.
25. Dubin MR, Pletcher SD. Postoperative packing after septoplasty: is it necessary?. *Otolaryngologic Clinics of North America*. 2009 Apr 1;42(2):279-85.
26. Nanda MS, Kaur M. Role of Oral Enzymes in Post Operative Septoplasty Cases. *Indian Journal of Otolaryngology and Head & Neck Surgery*. 2019 Nov;71(3):1663-7.
27. Dąbrowska-Bień J, Skarżyński PH, Gwizdalska I, Łazęcka K, Skarżyński H. Complications in septoplasty based on a large group of 5639 patients. *European*

Archives of Oto-Rhino-Laryngology. 2018 Jul;275(7):1789-94.

28. Fating L. Case Report on Management of Pregnancy in a Patient with Small Muscular Ventricular Septal Defect. JOURNAL OF PHARMACEUTICAL RESEARCH INTERNATIONAL. 2021;33(38A):325–8.
29. Ghavat, Chinmay, Nitin Bhola, Anendd Jadhav, Nupoor Deshpande, and Chetan Gupta. “Malignant Transformation of Solitary Cylindroma Involving the Frontonasal Region- A Rarity.” JOURNAL OF CLINICAL AND DIAGNOSTIC RESEARCH 14, no. 4 (April 2020): ZD1–4. <https://doi.org/10.7860/JCDR/2020/43006.13620>.
30. Ghavat, Chinmay, Nitin Bhola, Anendd Jadhav, Nupoor Deshpande, and Chetan Gupta. “Malignant Transformation of Solitary Cylindroma Involving the Frontonasal Region- A Rarity.” JOURNAL OF CLINICAL AND DIAGNOSTIC RESEARCH 14, no. 4 (April 2020): ZD1–4. <https://doi.org/10.7860/JCDR/2020/43006.13620>.
31. Jain, Shraddha, Prajakta Bhalerao, and Chandraveer Singh. “A New Endoscopic and Anatomical Classification of Deviated Nasal Septum with Clinical Relevance.” MEDICAL SCIENCE 24, no. 104 (August 2020): 2544–54.
32. Singh, Chandra Veer, Shraddha Jain, Sagar Gourkar, and Sandeep Iratwar. “Salvage of Failed Endovascular Management of Internal Carotid Artery Injury during Endoscopic Endonasal Pituitary Surgery.” JOURNAL OF CLINICAL AND DIAGNOSTIC RESEARCH 14, no. 12 (December 2020): MD01–4. <https://doi.org/10.7860/JCDR/2020/43778.14310>.
33. Singh CV, Jain S, Parveen S, Deshmukh P. The outcome of fluticasone nasal spray on anosmia and triamcinolone oral paste in taste dysgeusia in COVID-19 patients. AMERICAN JOURNAL OF OTOLARYNGOLOGY. 2021 Aug;42(4).
34. Singh CV, Jain S, Parveen S. The outcome of fluticasone nasal spray on anosmia and triamcinolone oral paste in dysgeusia in COVID-19 patients. AMERICAN JOURNAL OF OTOLARYNGOLOGY. 2021 Jun;42(3).