

## Original Research Article

### **Histopathological studies of skeletal muscle and liver of *Labeo rohita* during immunomodulation and aeromoniasis**

#### **ABSTRACT**

The impact of oral feeding diet (supplement) Aqua Fix was studied on the histopathological changes in skeletal muscles and liver of *L.rohita* during immunomodulation and aeromoniasis. Three groups (D,E,F) of six months old fish were employed; groups D and E were treated with Aqua Fix for 4 days, on day 5 fish of group E and F were infected with *Aeromonas hydrophila* @  $10^{-6}$ CFU/fish(fish of group F were fed with normal diet for 4 days).Controls (group G) were untreated and uninfected. Histological examination of the skeletal muscle and liver tissues were carried out on selected days of experimentation (day 1 and day 4 of experiment). The stained sections were observed under microscope and histological changes were noted. Immunostimulated fish (group D) showed normal arrangement of muscle fibers and muscle bundles compared to other groups (E and F) of fish. Both the muscle fibers and muscle bundles were healthy as in controls (Group G). In infected group (untreated with Aqua Fix, group F), fragmentation of muscle fibers was noticed along with sarcoplasmic debris. Dermal lesions and moderate edema is noticed in necrotic muscle fibers. Liver in immunostimulated fish showed large, polygonal hepatocytes with distinct, round nuclei. Hepatic central vein and sinusoids were clearly visible. By day 1 of infection, liver exhibited necrosis of hepatocytes, pycnosis of hepatocyte nuclei, granulation and vacuolisation (group F). Dilation of hepatic vein and sinusoids were observed. Necrotic foci and haemorrhages were evident in the capillaries of liver and occurred more severely in group F compared to group E (treated with Aqua Fix and infected). The fish (group E) which received immunostimulant and infection showed moderate effect on liver suggesting that Aqua Fix supplementation ameliorate the ill effects of *A. hydrophila*.

Key words: Skeletal muscle, Liver, Immunostimulant , *Aeromonas hydrophila* , *Labeo rohita*

## INTRODUCTION

*Aeromonas hydrophila* has been reported to cause dropsy, hemorrhagic septicemia, ulcers, skin lesions, bleeding of internal organs and tail and fin rot (Rahman et al; 2001). *L. rohita* infected with *A. hydrophila* showed much variation in the haematology, enzyme activities and tissue sections revealed dermal edema, muscular degeneration and necrosis of liver, glomeruli and renal tubules of kidney (Manoj et al;2010). Marked histopathological changes were found in liver and kidney of *Heteropneustes fossilis* infected with *A. hydrophila* (Islam et al;2011). Clinical signs and internal lesions were observed in estuarine cat fish and *H. fossilis* infected with *A. hydrophila* (Alagappan et al;2009;Islam et al;2013). Cutaneous lesions, hyperemia of abdominal organs and pathological lesions were found in spleen, intestine, stomach, gills and anterior kidney of cat fish infected with *A. hydrophila* (Rasmussen-Iver et al;2016; Abdelhamed et al;2017). *A. hydrophila* infection has been found in a wide variety of hosts (Huizinga et al., 1979; Soltani et al., 1998); the pathogenicity and abnormal histological changes caused by this opportunistic pathogen has been studied in *C. carpio* (Vivas et al., 2004) and channel catfish *Ictalurus punctatus* (Galindo et al., 2004). *A. hydrophila* has been reported to cause red fin disease in cultured eel, *Anguilla japonica* (Hoshima, 1962), red sore disease in large mouth bass, *Micropterus salmonides* (Huizinga et al., 1979) and hemorrhagic septicemia in *C. carpio* (Miyazaki et al., 1985), catfish larvae, *Silurus asotus* (Kuge et al., 1992) and in cyprinid fish (Zhang et al., 2014). Costa and Wijeyaratne (1989) reported that *A. hydrophila* is responsible for causing lesions in several fish species. Aeromoniasis causes several histopathological changes in fish which provide a valuable platform to understand the causes of their mortality. *Clarius batrachus* and *Salmo gairdneri* infected with *A. hydrophila* showed marked histopathological changes in many internal organs (Angka, 1990; Candan, 1990). Miyazaki and Jo (1985) and Miyazaki et al., (2001) reported that the damage of liver (chief metabolic organ), cells is damaged more when compared to cells of other organs in number of fish species. In large mouth bass, *M. salmonoides*, aeromoniasis lead to necrosis in liver, kidney and heart.

Harikrishnan and Balasundaram (2005) reported therapeutic (antibacterial) activity of some herbal extracts in preventing the *in vitro* growth of *A. hydrophila* in fish. Harikrishan et al., (2009) reported that an intramuscular injection of *A. hydrophila* caused sloughing of scales and ulcerative dermatitis associated with edema and dermal necrosis exposing the underlying muscles in Goldfish *Carassius auratus*.

Hasan *et al.*, (2008) and Islam *et al.*, (2008) reported the ill effects of aeromoniasis in liver and kidney of farmed fish. Hossain *et al.*, (2011) reported much pathological reactions in liver and kidney of *Anabas testiduens* during *A. hydrophila* infection.

Ventura and Grizzle (1988) described the histological changes in liver of channel catfish, *Ictalurus punctatus* naturally and experimentally infected with *A. hydrophila*. Destruction of hepatocytes and affinity of these bacteria to the liver were found. Various authors have reported histopathological changes in different tissues of *A. hydrophila* infected catfish, *C. batrachus* (Angka, 1990), *Salmo gairdneri* (Candan, 1990) and *C. mrigala* (Datta Ray and Homechaudhuri, 2014). Pal *et al.*, (2015) reported that *L. rohita* after *A. hydrophila* infection exhibited hepatic damage characterized by granulomatous inflammation, aggregation of melanomacrophage centres (MMC) and rupturing and cytolysis of hepatocytes leading to distortion of hepatic chords. Channel catfish and rainbow trout infected with *A. hydrophila* showed almost similar histopathological changes. The liver lost its structural integrity and became the primary target organ of an acute septicemia due to the action of bacterial endotoxins. The severity of lesion in the experimental fishes attributed to toxins released by *A. hydrophila*.

The presence of diseases and their causative pathogens can be detected in fish in various ways including: analysis of biochemical parameters (Gabriel *et al.* 2015, Ukwe 2021), histopathological and haematological assessment (Ukwe *et al.* 2021, Ukwe and Deekae 2022). *Ipomoea batatas* (sweet potato) leaf possess significant nutrients and phytochemicals that can enhance productivity in aquaculture (Ukwe and Deekae 2024).

## **MATERIALS AND METHODS**

*L. rohita*, an Indian major carp of approximately 6 months (12-15 g) old were collected from local fish farm, Singh farms, Kuchipudi (V), Amrutaluru (M), Guntur (D), Andhra Pradesh, India. In the laboratory fish were kept in the plastic tubs and acclimatized for 7 days. Water quality parameters were within optimum range and the water quality was regularly monitored. Fish were fed with commercially available pellet food. Two-third of the water was renewed every day using de-chlorinated ground water to maintain good water quality. Three experimental groups of six month old *L. rohita* (12-15 g) were selected for the experimentation. Groups, D (treated with Aqua Fix), E (treated with Aqua Fix and infected with *A. hydrophila*), F (untreated with Aqua Fix but infected with *A. hydrophila*) and one

control group, G (untreated and uninfected) of fish (35 in each group) were maintained in optimum conditions. Fish of group D and E fed with a diet supplemented with Aqua Fix (@50mg/100 g of feed) for 4 days; on day 5 fish of group E and F were infected intraperitoneally with *A. hydrophila* @  $10^{-6}$  CFU/fish. Fish of groups F and G were fed with normal diet (without Aqua Fix) during the entire experimental period.

### **Bacterial culture**

The bacterial strain used in this study, *Aeromonas hydrophila* was collected from State Institute of Fisheries Technology (SIFT), Kakinada, (A.P.), India. This parent culture was subsequently revived by nutrient broth and transferred the culture to a nutrient agar medium. Culture and preparation of isolated bacterial colonies were made under aseptic conditions following the method of Pelczar (1993).

### **Histopathology**

Histological examination of the skeletal muscle and liver tissues were carried out on selected days of experimentation (day 1 and day 4 of experiment). Isolated muscle and liver tissues of control and experimental fish were gently rinsed with normal physiological saline (0.9% NaCl) to remove blood and debris adhering to the tissues and were fixed in 10% formalin. After dehydrating to a graded series of alcohols, the tissues were cleared in absolute methyl alcohol and xylene, and embedded in paraffin wax. Sections were cut at 5  $\mu$  thickness and stained with haematoxylin and eosin. After dehydration and clearing, sections were mounted with DPX. The stained sections were observed under microscope and histological changes were noted.

### **RESULTS AND DISCUSSION**

The tissue sections of muscles and liver of 6 months old *L. rohita* displayed marked histological / pathological changes during bacterial infection (groups E– treated with Aqua Fix + infected; F– infected). The fish which were fed with Aqua Fix (groups D) and control (group G) showed normal architecture in the muscles and liver throughout the experiments.

#### **Skeletal Muscles:**

##### **Microscopic examination:**

##### **On day 1 of experiment:**

##### **Group G (control, untreated with Aqua Fix and infection) (Fig. 1, G1):**

Histological structure of muscle showed normal arrangement of muscle fibers (myofibrils) and muscle bundles on day 1 of experiment.

**Groups D (treated with Aqua Fix), E (treated with Aqua Fix and infected with *A. hydrophila*) and F (infected with *A. hydrophila*) (Fig. 1; D1, E1, F1)**

Immunostimulated fish (group D) showed normal arrangement of muscle fibers and muscle bundles compared to other groups (E and F) of fish. Both the muscle fibers and muscle bundles were healthy as in controls (Group G) (Fig.1 G1). In the immunostimulated and infected fish (group E), there was slight derangement of muscle fibers. Also, muscle fibers slightly lost their elongation and appeared slightly curved. Sarcoplasmic debris appeared at certain places. Hypertrophy is seen in muscle bundles (Fig.1, E1). In infected group (untreated with Aqua Fix, group F), fragmentation of muscle fibers was noticed along with sarcoplasmic debris. Dermal lesions and moderate edema is noticed in necrotic muscle fibers.

**On day 4 of experiment:**

**Group G (control, untreated with Aqua Fix and infection) (Fig. 1, G4):**

Histological structure of muscle showed normal arrangement of muscle fibers (myofibrils) and muscle bundles on day 4 of experiment.

**Groups D (treated with Aqua Fix), E (treated with Aqua Fix and infected with *A. hydrophila*) and F (infected with *A. hydrophila*) (Fig. 1; D4, E4, F4)**

Histological structure of muscles in immunostimulated fish (group D) was characterised by the presence of normal arrangement of healthy muscle fibers and muscle bundles (Fig.1, D4). In Aqua Fix treated and infected fish (Group E), the muscle bundles and muscle fibers were markedly fragmented; the fragments of muscle fibers accumulated at certain places. Lacunae were clearly visible in musculature due to muscular degeneration (Fig. 1, E4). Marked oedema, vacuolation, necrosis and dermal lesions were observed in the muscle tissue of infected fish (group F; Fig.1, F4). Derangement and fragmentation of muscle fibers, cloudy appearance of muscle fibers and scattered sarcoplasmic debris were also noticed.

**Liver:**

**Microscopic examination:**

Multiple transverse sections of normal liver of fish displayed a continuous mass of hepatocytes arranged irregularly. Hepatocytes are large, polygonal in shape with almost centrally placed nuclei. Blood sinusoids were clearly evident.

**On day 1 of experiment:**

**Group G (control, untreated and uninfected) (Fig.2, G1)**

Histology of liver in control fish on day 1 of experiment was characterized by the presence of large, polygonal hepatocytes. Nuclei of hepatocytes are distinctly round and almost centrally placed. Hepatocytes exhibited prominent central vein, sinusoids were clearly observed.

**Groups D (treated with Aqua Fix), E (treated with Aqua Fix and infected with *A. hydrophila*) and F (infected with *A. hydrophila*) (Fig.2, D1, E1 F1):**

Histological analysis of the liver in immunostimulated fish showed large, polygonal hepatocytes with distinct, round nuclei. Hepatic central vein and sinusoids were clearly visible (Fig. 2, D1). In case of immunostimulated and infected fish (group E), liver tissue exhibited haemorrhagic spots, vacuolisation and granulation. Slight disruption appeared in hepatocytes (Fig.2, E1). By day 1 of infection, liver exhibited necrosis of hepatocytes, pycnosis of hepatocyte nuclei, granulation and vacuolisation (group F; Fig.2, F1). Dilation of hepatic vein and sinusoids were observed. Necrotic foci and haemorrhages were evident in the capillaries of liver and occurred more severely compared to group E (treated with Aqua Fix and infected).

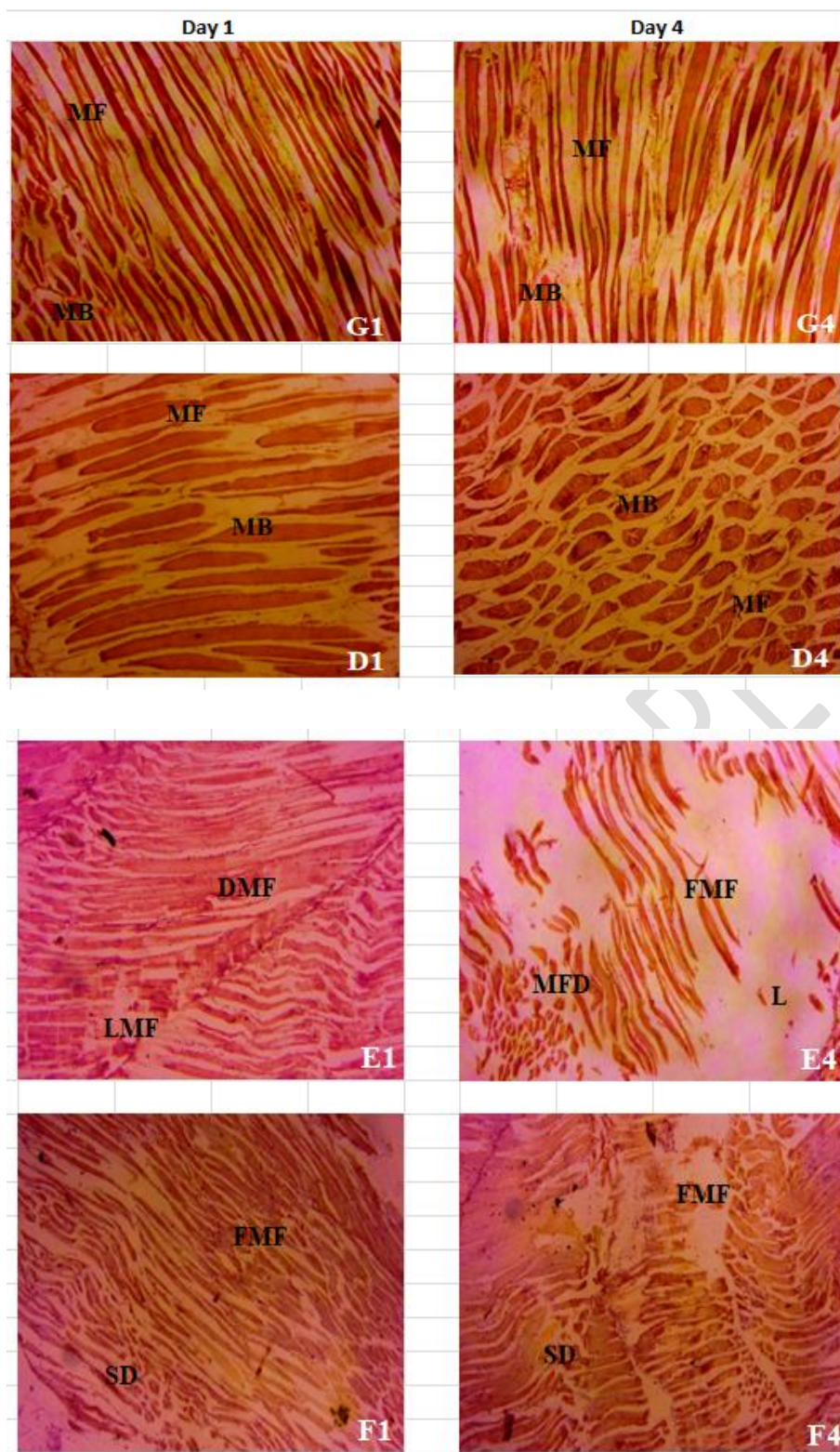
**On day 4 of experiment:**

**Group G (control, untreated and uninfected) (Fig.2, G4)**

Histology of liver in control fish on day 4 of experiment was characterized by the presence of large, polygonal hepatocytes. Nuclei of hepatocytes are distinctly round and almost centrally placed. Hepatocytes exhibited prominent central vein, sinusoids were clearly observed.

**Groups D (treated with Aqua Fix), E (treated with Aqua Fix and infected with *A. hydrophila*) and F (infected with *A. hydrophila*) (Fig.2, D4, E4, F4)**

Histology of the liver in immunostimulated fish (group D) revealed a continuous mass of hepatocytes. These cells are large, polygonal with distinct nucleie (Fig.2, D4). The liver tissue of immunostimulated and infected fish (group E) showed mild vacolisation, granulation and haemorrhages. Mild dilation of veins and sinusoids were evident (Fig. 2, E4). Necrotic hepatocytes, pycnosis, vacuolization, cell debris, haemorrhages and necrotic foci were found in infected fish (group F). Veins and sinusoids were markedly dilated (Fig.2, F4).



**Fig.1.** Showing the section of skeletal muscles of *L. rohita* (6 months old) from group G (control, untreated with Aqua Fix and uninfected), group D (Aqua Fix treated @ 50mg/100g of feed), group E (treated with Aqua Fix @ 50mg/100g of feed+ infected with *A. hydrophila* @  $10^{-6}$  CFU/fish) and group F (infected with *A. hydrophila* @  $10^{-6}$  CFU/fish) on day 1 and 4 of experimental period. Abbreviations: MF – Muscle fiber; MB – Muscle bundle; DMF – Derangement of muscle fibers; LMF – Loss of muscle fibers; FMD – Fragmentation of muscle fibers; SD – Sarcoplasmic debris; MFD – Muscle fiber degeneration; L - Lacuna

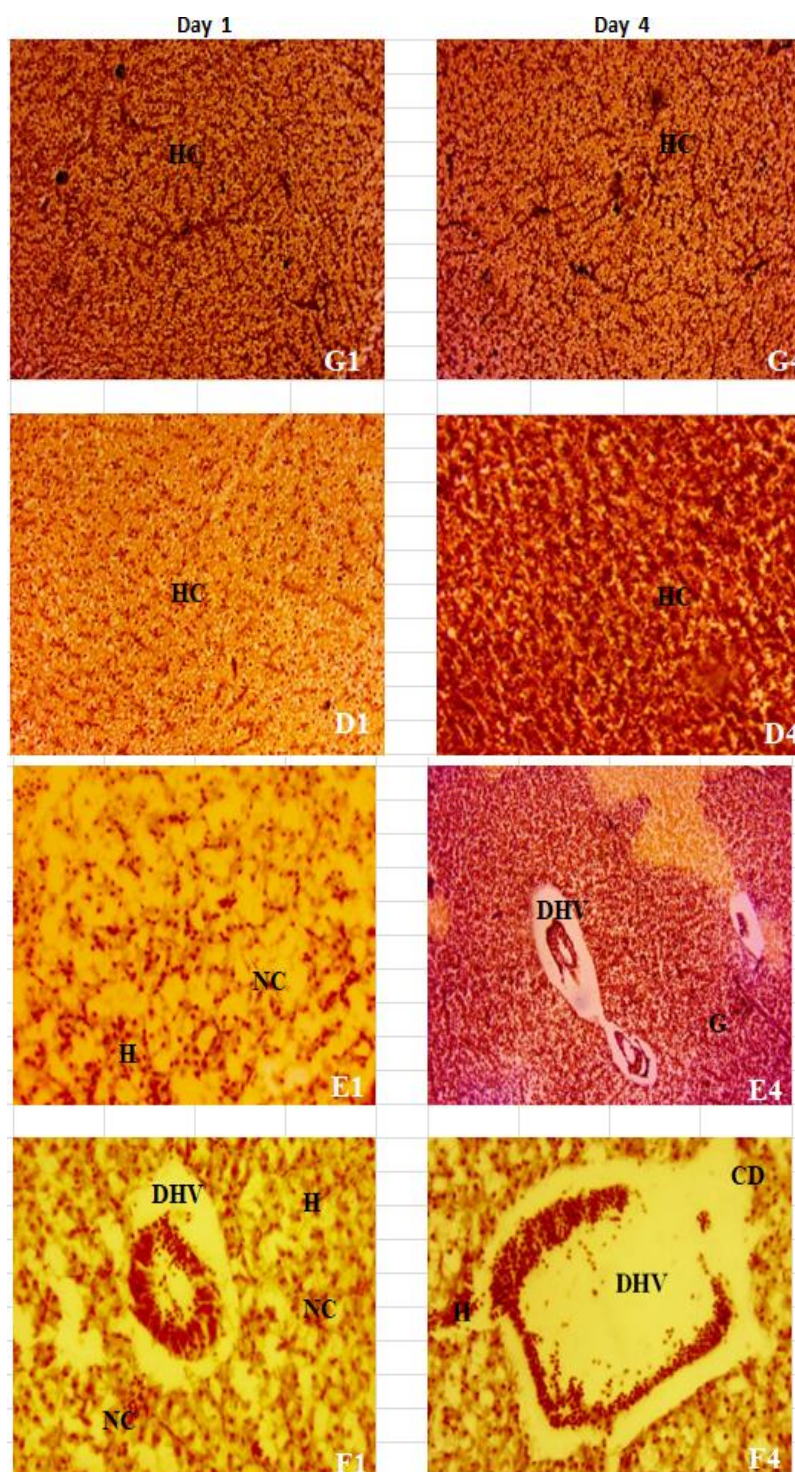


Fig.2. Showing the section of liver of *L. rohita* (6 months old) from group G (control, untreated with Aqua Fix and uninfected), group D (Aqua Fix treated @ 50mg/100g of feed), group E (treated with Aqua Fix @ 50mg/100g of feed+ infected with *A. hydrophila* @  $10^{-6}$  CFU/fish) and group F (infected with *A. hydrophila* @  $10^{-6}$  CFU/fish) on day 1 and 4 of experimental period. **Abbreviations:** HC – Hepatocytes; H – Haemorrhages; NC – Necrotic foci; DHV – Dilatation of hepatic vein; G – Granulation; CD – Cell debris.

## CONCLUSION

The present findings on histopathological changes in skeletal muscles confirm that of Harikrishnan *et al.*, (2009) who found fragmentation of muscle fibers with necrosis and sarcoplasmic debris in goldfish, *C. auratus* infected with *A. hydrophila* and Manoj *et al.*, (2010) who also found local haemorrhages, dermal odema and muscular degeneration in *L. rohita* infected with *A. hydrophila* by immersion challenge. The fish (group E) which received immunostimulant and infection showed moderate effect on liver suggesting that Aqua Fix supplementation ameliorate the ill effects of *A. hydrophila*. Various authors (Selvaraj *et al.*, 2005; Rairakhwada *et al.*, 2006; Gupta *et al.*, 2008) documented the positive influence of immunostimulants in freshwater fish which in turn retains the normal histology to certain extent compared to other groups.

Herbs and herbal products have proven to be good solutions and replacement for synthetic drugs in the practice of aquaculture as they are eco-friendly, not immunespecific and does not deposit on the fish flesh (Ukwe *et al.*;2019). Aqua fix seems to possess the potentials of maintaining normal biochemical activities and safe guard fish liver against *A. hydrophila*. However more studies are required in different species to prove the efficacy of herbal immunostimulants to maintain sustainable growth in Aquaculture.

## References

1. Abdelhamed *et al.*; 2017, Characterization of Histopathological and Ultrastructural Changes in Channel Catfish Experimentally Infected with Virulent *Aeromonas hydrophila*, *Front microbiol* 15;8:1519. doi: [10.3389/fmicb.2017.01519](https://doi.org/10.3389/fmicb.2017.01519)
2. Alagappan K. M., Deivasigamani B., Kumaran S., Sakthivel M. (2009). Histopathological alterations in estuarine catfish (*Arius maculatus*; Thunberg, 1792) due to *Aeromonas hydrophila* infection. *World J. Fish Mar. Sci.* 1 185–189.
3. Hassan, M.A., Rashid, M.M., Islam, M.A., Mostafa, K. and Islam, M.T. 2008. Histopathological studies of EUS affected shing *Heteropneustes fossilis* from a fish farm of Mymensingh. **Bangladesh J. Fish. Res.**, **12(1)**: 12-36.
4. Hossain, F.M., Rashid, M.M. and Sayed, M.A. 2011. Experimental infection of indigenous climbing perch. *Anabas testudineus* with *Aeromonas hydrophila* bacteria. **Progress. Agric.** **22(1&2)**: 105-114.

5. 12. Huisinga, H.W., Esch, G.W. and Hazen, T.C. 1979. Histopathology of red-sore disease (*Aeromonas hydrophila*) in naturally and experimentally infected large mouth bass, *Micropterus salmoides* (Lacepeda). **J. Fish Dis.** **2**: 263-277.
6. 13. Islam, M.T., Rashid, M.M. and Mostafa, K. 2008. Histopathological studies of experimentally infected shing, *Heteropneustes fossilis* with *Aeromonas hydrophila* bacteria. **Progress. Agric.** **19(1)**: 89-96.
7. 14. Kuge, T., Takahashi, K., Barcs, I. and Hayashi, F. 1992. *Aeromonas hydrophila*, a causative agent of mass mortality in cultured Japanese catfish larvae (*Silurus asotus*). **Fish Pathol.** **27**: 57-62
8. 15. Islam M., Mostafa K., Rashid M. (2013). Histopathological studies of experimentally infected shing, *Heteropneustes fossilis* with *Aeromonas hydrophila* bacteria. *Prog. Agric.* 19 89-96. 10.3329/pa.v19i1.17359
9. 15. Miyazaki, T. and Jo, Y. 1985. A histopathological study of motile aeromonad disease in ayu. **Fish Pathol.** **20**: 55-59.
10. 21. Rasmussen-Ivey C. R., Hossain M. J., Odom S. E., Terhune J. S., Hemstreet W. G., Shoemaker C. A., et al. (2016). Classification of a hypervirulent *Aeromonas hydrophila* pathotype responsible for epidemic outbreaks in warm-water fishes. *Front. Microbiol.* 7:1615 10.3389/fmicb.2016.01615
11. 3. Costa, H.H. and Wijeyaratne, M.J.S. 1989. Epidemiology of epizootic ulcerative syndrome occurring for the first time among fish in Sri Lanka. **J. Appl. Ichthyol.** **1**: 48-52.
12. 4. Datta Ray, S. and Homechaudhuri, S. 2014. Morphological and functional characterization of hepatic cells in Indian Major Carp (*Cirrhinus mrigala*) against *A. hydrophila* infection. **J. Environ. Biol.** **35**: 253-258
13. 5. Gabriel, N.N., Quiang, J., Ma, X.Y, He, J., Xu, P. and Liu, K. (2015) Dietary Aloe vera improve plasma liquid profile, antioxidant, and hepatoprotective enzyme activities in tilapia (*Oreochromis niloticus*) after *Streptococcus iniae* challenge. *Fish physiology and Biochemistry.* ;4:1321 – 1332.
14. 6. Galindo, C.L., Fadl, A.A., Sha, J., Gutierrez, Jr. C., Popov, V.L., Boldogh, I., Agarwal, B.B. and Chopra, A.K. 2004. *Aeromonas hydrophila* cytotoxic enterotoxin activates mitogen-activated protein kinases and induces apoptosis in murine macrophages and human intestinal epithelial cells. **J. Biol. Chem.** **279**: 37597-37612.
15. 7. Gupta, S.K., Pal, A.K. Sahu, N.P., Dalvi, R., Kumar, V. and Mukherjee, S.C. 2008. Microbial levan in the diet of *Labeo rohita* Hamilton juveniles effect on non-specific

- immunity and histopathological changes after challenge with *Aeromonas hydrophila*. **J. Fish Dis.** **31**: 649-657.
16. 8. Harikrishnan, R. and Balasundaram, C. 2005. Modern trends in *Aeromonas hydrophila* disease management with fish. **Rev. Fish Sci.** **13**: 281-320.
  17. 9. Harikrishnan, R., Balasundaram, C., Young-Gunman, Man-Chul Kini, Ju-Sang Kim and Moon-Soo Heo. 2009. Use of herbal concoction in the therapy of goldfish (*Carassius auratus*) infected with *Aeromonas hydrophila*. **Bull. Vet. Inst. Pulawy.** **53**: 27-36.
  18. Angka, S.L. 1990. The pathology of the walking catfish, *Clarias batrachus* (L.) infected intraperitoneally with *A. hydrophila*. **Asian Fish. Sci.** **3**: 341-351.
  19. Candan, A.A. 1990. A study on the histopathology of *A. hydrophila* infections of rainbow trout (*Salmo gairdneri* R.) kept under experimental conditions and the effect of choramphenicol. **J. Aquat. Prod.** **4**: 5-20
  20. Manoj, C.K., Mohankumaran, Nair, C., Patel, M.B. and Salin, K.R. 2010. Haematobiochemical and histopathological changes in *Labeo rohita* infected with *Aeromonas hydrophila* by immersion challenge. **Fishery Technol.** **47(2)**: 151-160.
  21. Miyazaki, T., Kageyama, T., Miura, M. and Yoshida, T. 2001. Histopathology of viremia-associated ana-aki-byo in combination with *Aeromonas hydrophila* in color carp *Cyprinus carpio* in Japan. **Dis. Aquat. Org.** **44**: 100-120.
  22. Pal, S., Ray, S.D. and Homechaudhuri, S. 2015. Evaluation of *in vivo* non-specific immunity and oxidative stress in *Labeo rohita* (Hamilton, 1822) infected with *Aeromonas hydrophila* as biomarker for early diagnosis. **Int. J. Fish. Aqua. Stu.** **3(1)**: 116-124.
  23. Pelczar, M.J. Jr., Chan, E.C.S. and Noel, R.K. 1993. Characterization of microorganisms. Microbiology concepts and applications. 5<sup>th</sup> ed. Tata McGraw Hill Publishing Co. Ltd., pp. 81-83 (Robert Koch, 1883).
  24. Rahman, M.H., Suzuki, S. and Kawai, K. 2001. The effect of temperature on *Aeromonas hydrophila* infection in gold fish, *Carassius auratus*, **J. Appl. Ichthyol.** **17**: 282-285.
  25. Rairakhwada, D., Pal, A.K., Bhatena, Z.P., Sahu, N.P., Jha, A. and Mukherjee, S.C. 2006. Dietary microbial levan enhances cellular non-specific immunity and survival of common carp (*Cyprinus carpio*) juveniles. **Fish & Shellfish Immunol.** **22**: 477-486.

26. Selvaraj, V., Sampat, K. and Sekhar, V. 2005. Administration of yeast glucan enhances survival and some non-specific and specific immune parameters in carp (*Cyprinus carpio*) infected with *Aeromonas hydrophila*. **Fish & Shellfish. Immunol.** **19**: 293-306.
27. Soltani, N., Mirzargar, S.S. and Abrahizadeh, H.A. 1998. Occurrence of a motile *Aeromonas septicaemia* in the imported ornamental fish, oscar *Astronotus ocellatus*: Isolation characterization and pathogenicity. **J. Faculty Vet. Med. Univ. Tehran** **53**: 63-65.
28. Ukwe, I. O. K. & Deekae, S. N. (2024). Phytochemical and Proximate Analysis of sweet potato (*Ipomea batatas*) leave aqueous extract and it's prophylactic effects on *Pseudomonas aeruginosa*. Infected *Clarias gariepinus*. *Asian Journal of Aquatic Research*, 26 (6): 76 – 87
29. Ukwe, I. O. K., & Gabriel, U. U. (2019). Herb and Herbal Supplements: Key to a Productive, Healthy, and Eco-Friendly Aquaculture Practice. *Delta Agriculturist*, 23, 123-130
30. Ukwe, I.O.K. & Deekae, S.N. (2022). Phytochemical Assessment of *Persea americana* powdered leaves and its potency in protecting *Clarias gariepinus* against *Klebsiella pneumonia*. *Asian Journal of Fisheries and Aquatic Research*, 16(6): 1-9.
31. Vivas, J., Carracedo, B., Riano, J., Razquin, B.E, Lopez-Fierro, P., Acosta, F., Naharro, G. and Villena, A.J. 2004. Behavior of an *Aeromonas hydrophila aroA* live vaccine in water microcosms. **Appl. Environ. Microbiol.** **70**: 2702-2708.
32. Ukwe, I. O. K., & Abu, O. M. G. (2021). Effect of dietary *Persea americana* on the organosomatic indices, diseases resistance, and liver histopathology of *Clarias gariepinus* exposed to *Klebsiella pneumoniae*. *Asian Journal of Fisheries and Aquatic Research*, 15(6), 148-156.