

Incidental Extraluminal Leiomyosarcoma of the Urinary Bladder: A Rare Diagnostic and Therapeutic Challenge

Abstract

Introduction - Non-urothelial malignancies in the bladder are rare. Leiomyosarcoma has been recognized as the most common mesenchymal tumor, accounting for less than 0.1% of primary bladder tumors. The diagnosis of leiomyosarcoma mostly relies on histopathological analysis and specific immunohistochemical markers, as clinical and imaging findings are typically inadequate.

Case report - We here describe the case of a 56-year-old female who presented with diffuse pain in the lower abdomen during micturition for one week. Whole body 18F-fluorodeoxyglucose (FDG) positron emission tomography-computed tomography (PET-CT) imaging findings identified a faintly FDG-avid lesion in the anterior pelvic region raising the suspicion of a mesenteric mass. She underwent exploratory laparotomy, which revealed a 4x3 cm mass originating from the fundus of the bladder (extraluminal) with adhesions to the sigmoid colon. Histopathological examination of the resected mass confirmed it as a high-grade sarcoma of the urinary bladder with necrotic areas and high mitotic activity. The surrounding cuff of bladder tissue revealed no evidence of malignancy. The immunohistochemistry report results were positive for smooth muscle actin, desmin, and caldesmon supporting the diagnosis of leiomyosarcoma urinary bladder.

Conclusion- This case underscores the rarity and diagnostic challenges associated with extraluminal leiomyosarcoma of the bladder. There is a need to consider leiomyosarcoma as differential diagnosis of atypical bladder masses highlighting the importance of a tailored, multidisciplinary approach, addressing the potential for recurrence, and improving patient outcomes. Continued reporting of cases and collaborative research efforts are essential to advance our understanding of this rare malignancy.

Keywords: Extraluminal, leiomyosarcoma, pelvic mass, urinary bladder tumors, high grade sarcoma

Introduction

Leiomyosarcomas of bladder are regarded as rare but aggressive tumors associated with significant morbidity. The primary causative agents attributed to these tumors include genetic syndromes such as Li-Fraumeni syndrome, NF-1 gene mutation, Retinoblastoma gene mutation, prior irradiation to the pelvis, long-term use of cyclophosphamide therapy, and persistent bladder inflammation.^[1] It is often difficult to diagnose bladder leiomyosarcomas based on clinical and radiological imaging findings.^[2] Histopathological diagnosis and specific immunohistochemical markers facilitate its diagnosis. More than 60% of the patients with leiomyosarcoma of the urinary bladder develop metastasis or recurrent disease in the due course of the disease.^[3]

Leiomyosarcomas often present with nonspecific symptoms, resulting in delayed diagnosis until the tumor reaches advanced stages.^[4] The primary goal of treatment is complete excision with wide negative surgical margins (R0 resection), thereby resulting in prolonged survival rates. A thorough literature search revealed a lack of entity of leiomyosarcoma arising from the urinary bladder wall with an extraluminal origin. This case report requires special mention due to its uncommon presentation in a female patient, absence of established risk factors, and incidental finding of extraluminal leiomyosarcoma of the urinary bladder intraoperatively. Since this is the first case report documenting an extraluminal leiomyosarcoma of bladder, our effort is to add on to the existing data to improve the diagnostic and therapeutic strategies in such rare bladder malignancies.

Case presentation

A 56-year-old female presented with diffuse pain in lower abdomen while micturition since one-week. The pain was spasmodic, and intermittent in nature with no aggravating or relieving factors. The patient had no history of hematuria, burning micturition, early satiety, abdominal distention or other complaints. There was no personal history of smoking or second-hand smoking. She had no comorbidities and good performance status. She had undergone a total abdominal hysterectomy for bleeding per vaginum 2 years back. The details of the diagnostic and histopathological report were not available to rule out the possibility of leiomyosarcoma arising from the uterus. There was no significant past history or family history. An ultrasound abdomen revealed the presence of a mass in the anterior pelvic cavity. Subsequently, she was referred to a higher center for further evaluation.

Physical examination revealed mild pallor and a soft abdomen with no palpable mass. Her blood parameters including tumor marker (CA-125) were in the normal range. She underwent MRI abdomen and pelvis which revealed an ill-defined heterogeneous soft tissue lesion in the mesentery in the anterior pelvic region. The small and large bowels were seen separately from the mass, indicating that they were not the primary site of origin. Since the findings could not localize the primary lesion, she was subjected to PET-CT scan. A faintly FDG-avid (SUV=2.94gm/ml) heterogeneously enhancing soft tissue lesion was seen in the anterior pelvic cavity involving the mesentery in this region abutting the base of the urinary bladder inferiorly and bowel loops superiorly with central necrotic areas in it, measuring 4.1x5.0x4.1 cm in size. No lymph nodal or distant metastasis were observed (Figure 1).

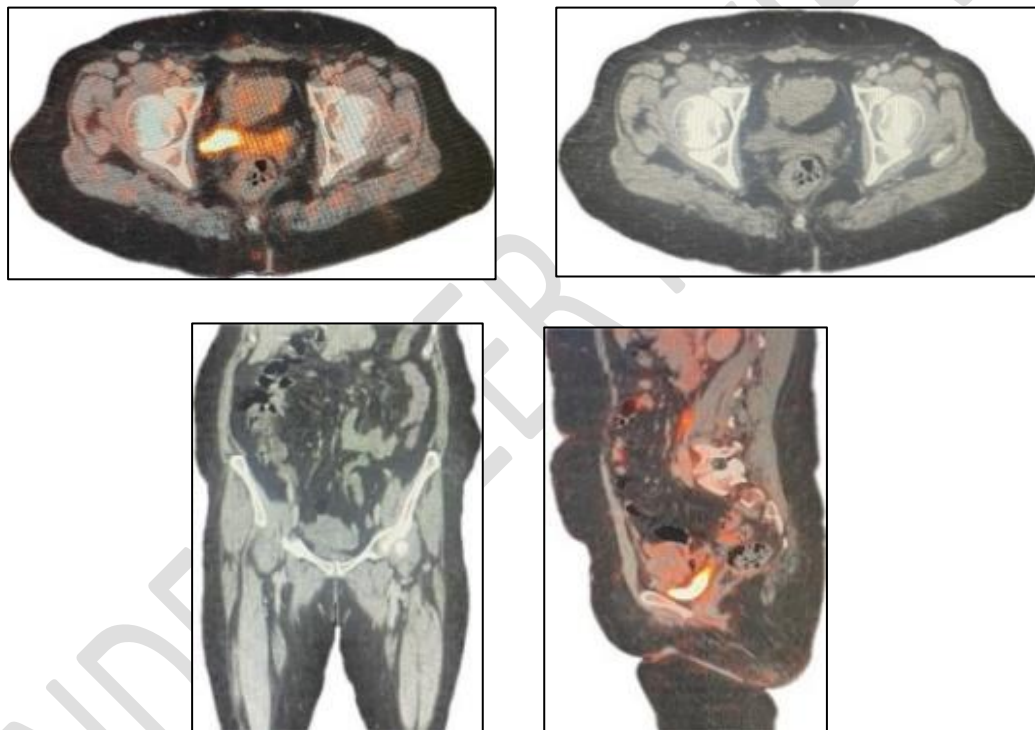


Figure 1: PET-CT scan images prior to exploratory laparotomy

The case was discussed in the multidisciplinary tumor board. Given the ambiguity of its clinical presentation and obscure diagnosis on imaging, we planned to proceed with elective exploratory laparotomy with complete resection of the mass. Intraoperative findings confirmed with the surgeon revealed a 4x3cm urinary bladder mass arising from the fundus of the bladder. There were dense adhesions of this mass with the sigmoid colon. The tumor was dissected through adhesions from adjacent structures. No intraluminal component was seen. Her post-operative period was uneventful without acute complications and she was discharged on the 8th post-operative day (Figure 2).

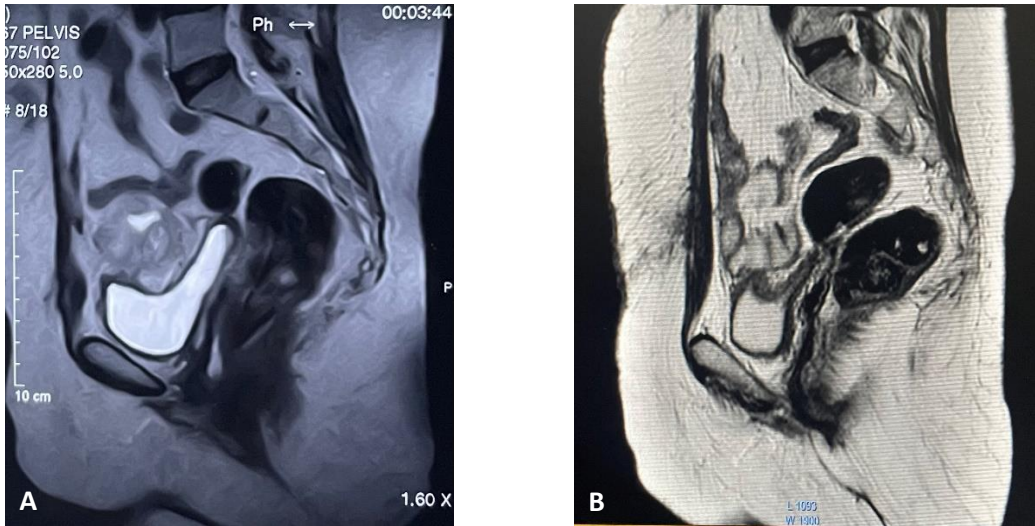


Figure 2: (A&B) Preoperative and post-operatively done T2 weighted MRI scans.

The histopathological examination of the excised mass revealed nodular growth measuring 5.6x4cm with a bladder cuff about 1x2cm. The cut section showed greyish-white growth measuring 5.5x3cm with firm and necrotic areas (Figure 3).

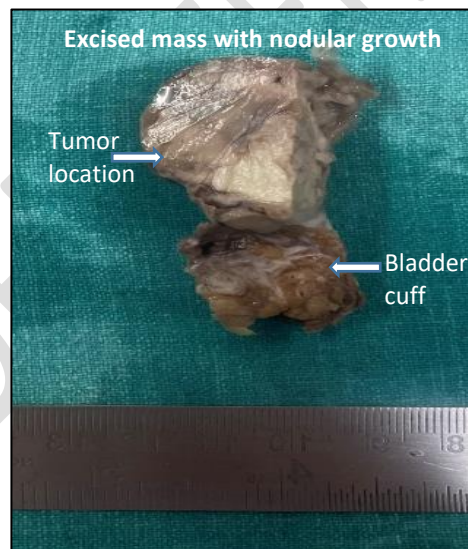

Figure 3: Gross surgical specimen

A high-grade sarcoma with malignant round to spindle-shaped cells showing a high-grade atypia with increased mitotic activity in sheets and fascicles was reported. Around 20-30% of tumor tissue showed necrosis without evident lymphovascular and perineural invasion. The surrounding cuff of bladder tissue showed no evidence of malignancy.

Immunohistochemical evaluation confirmed that tumor cells stained positive for smooth muscle actin, desmin, and caldesmon and negative for CD34 and S100 (Figure 4).

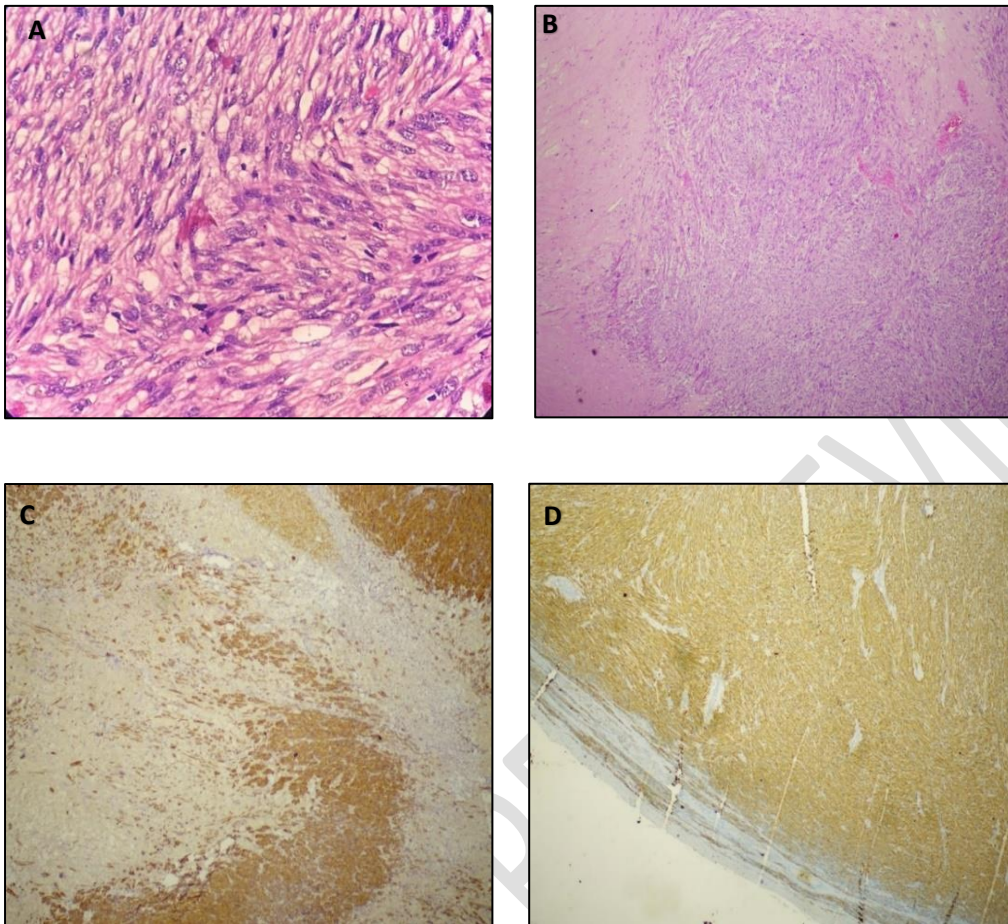


Figure 4: A) & B) Hematoxylin and Eosin C) Smooth muscle actin D) Immunostaining with anti-H caldesmon.

This confirmed the diagnosis of a leiomyosarcoma originating from the bladder wall. Taking into consideration, high-grade tumor characteristics (atypia, mitosis and Ki-67 positivity in 60-70% of cells) suggestive of aggressiveness of the disease, the patient was subsequently treated with adjuvant radiotherapy. The radiation therapy was administered using the Image-guided radiation therapy (IGRT) technique, utilizing 6 MV photons, delivered at a total dose of 50.4 Gy over 28 fractions. The irradiation was delivered to the tumor bed only and no regional lymph nodes were treated. In light of incidental findings of extraluminal leiomyosarcoma and no lymph nodal assessment at the time of surgery, the treating oncologists planned to pursue systemic therapy to prevent potential recurrence in the future.

Discussion

Rowland and Eble first reported a case of leiomyosarcoma, arising from urinary bladder smooth muscle following cyclophosphamide therapy.^[5] Over the years, it has been recognized as an extremely rare non-urothelial malignancy, with few case reports and meta-analyses. It accounts for around 0.1% of bladder neoplasms.^[2] These tumors typically present challenges in the diagnosis and management due to their rarity and potential for rapid progression.^[6] Age appears to be a factor, with leiomyosarcomas occurring more frequently in older adults with a slight male predominance.^[1,2,7] Zieschang et al. have published the largest systematic review analyzing the clinical data of 210 cases of urinary bladder leiomyosarcoma. Painless, gross hematuria was reported as the most frequent symptom (80%), followed by less common symptoms of dysuria, nocturia, obstructive symptoms, pelvic pain, abdominal pain, recurrent urinary tract infection, increased frequency of micturition, or burning micturition.^[1] However, our patient was a middle-aged female with minimal complaints. Potential contributors to its development include genetic predispositions involving mutations in the retinoblastoma gene and NF-1 gene or syndromes namely Li-Fraumeni. Prior history of bladder cancers, pelvic irradiation, and use of cyclophosphamide have also been implicated in its etiology.^[1] Our patient had no history of these predisposing factors to explain the origin of this disease. The literature search revealed that leiomyosarcoma of the urinary bladder is diagnosed more frequently when localized.^[8] Contrary to this, our patient had an extraluminal mass arising from the urinary bladder not causing any urinary symptoms. These tumors are believed to be aggressive with high mortality rates owing to delayed diagnosis or metastatic disease.^[9]

A conventional CT scan usually reveals bladder tumors as intraluminal hyper-enhanced lesions or hyper-enhanced bladder wall thickening evident on urothelial phase images or filling defects in the excretory phase images.^[10,11] It is challenging to differentiate leiomyoma from leiomyosarcoma even on MRI. Favorable features for leiomyosarcoma include large mass with necrosis manifesting as heterogeneous signal intensity on T2-weighted images, poorly circumscribed margins, and involvement of adjacent structures.^[12] In our case, the clinical and radiological findings were uncertain in predicting the accurate diagnosis.

Due to mystification in the diagnosis, the patient was subjected to exploratory laparotomy for the resection of the suspected mass. The surgeons intraoperatively noted that the growth originated as an exophytic component from the urinary bladder. **Similar to this, we found a case report by Fiorentino et al wherein the exophytic part of the tumor was removed**

with the bladder wall.^[13] In our case, the resected mass was diagnosed as leiomyosarcoma of the urinary bladder with an extraluminal component. Histopathologically, this mass was diagnosed as leiomyosarcoma of the urinary bladder based on identification of spindle-shaped cells, high mitotic activity, and evidence of necrosis. Immunohistochemical staining for smooth muscle markers such as desmin and smooth muscle actin further supported the diagnosis. Moreover, imaging in our patient did not demonstrate lymph nodal involvement. Coiner et al found that tumor size (>5cm) was an independent prognostic factor in bladder leiomyosarcoma.^[14] Xu et al. reported the case of a 31-year-old woman with a 2-month history of urinary complaints. MRI imaging revealed a mass of 4 cm in the left wall of the bladder, with a clear margin in the mesentery and abdominal wall with no enlarged lymph nodes. The biopsy showed leiomyosarcoma pathologically. The patient underwent partial cystectomy with negative surgical margins and no further adjuvant chemoradiation therapy. This patient was disease-free after 7 years of follow-up. This case report emphasized that though bladder leiomyosarcomas are aggressive, managing them with partial surgery to preserve the organ functionality can also be considered a valid option^[15]. Based on radiological and pathological findings we have ruled out the differential diagnosis of gastrointestinal stromal tumor of small intestine and sclerosing mesenteritis.

Management of extraluminal leiomyosarcoma of the urinary bladder requires a multidisciplinary approach. Surgical resection to achieve negative margins is the primary treatment modality. The extent of surgery may vary depending on the tumor size, location, and involvement of adjacent structures. Adjuvant modalities such as chemotherapy and radiation therapy may be considered.^[1] Leiomyosarcoma of the bladder is associated with a guarded prognosis, influenced by factors including tumor grade, stage at diagnosis, and completeness of surgical resection.^[1,2] Long-term survival rates are generally poor, necessitating vigilant post-operative surveillance for recurrence and metastasis.^[16] Extraluminal leiomyosarcoma of the urinary bladder poses significant diagnostic and therapeutic challenges due to its rarity and unknown behavior.

Conclusion

Extraluminal leiomyosarcoma originating from the bladder wall should be considered as the differential diagnosis of atypical bladder mass, especially when asymptomatic. Timely diagnosis, careful assessment, and interdisciplinary treatment approach are the prerequisites

for managing this rare disease. Surgery remains the mainstay of treatment to be complemented by adjuvant radiotherapy and chemotherapy depending upon the aggressiveness of the disease. Given the rare occurrence of this entity, this case report augments the existing knowledge while managing similar cases in the clinic.

Disclaimer (Artificial intelligence)

Author(s) hereby declare that NO generative AI technologies such as Large Language Models (ChatGPT, COPILOT, etc.) and text-to-image generators have been used during the writing or editing of this manuscript.

References

1. Zieschang H, Koch R, Wirth MP, Froehner M. Leiomyosarcoma of the Urinary Bladder in Adult Patients: A Systematic Review of the Literature and Meta-Analysis. *Urol Int*. 2019; 102: 96-101.
2. Saidani B, Saadi A, Bedoui MA, Zaghbib S, Chakroun M, Slama RB. Leiomyosarcoma of the bladder: A review and a report of four further cases. *Int J Surg Case Rep*. 2023; 110: 108735.
3. Patnayak R, Jena A, Rambabu S, Reddy MK. Leiomyosarcoma of urinary bladder – potential mimicker of carcinoma: case report and review of literature. *Indian J Cancer* 2015; 52: 573-4.
4. Fakhri N, Bhalla R. Leiomyosarcoma of Urinary Bladder: A Review of Two Cases. *Am J Clin Path* 2020; 154: S52.
5. Rowland RG, Eble JN. Bladder leiomyosarcoma and pelvic fibroblastic tumor following cyclophosphamide therapy. *J Urol* 1983; 130: 344-6.
6. Vias P, Goyal S, Periasamy K, Madan R, Devana SK, Bal A, et al. Leiomyosarcoma of urinary bladder with unusual recurrence in intestinal mucosa and peritoneum: a case report. *J Egypt Natl Canc Inst* 2021; 33: 38.
7. Youseff K, Dembele ON, Idriss Z, Elsayegh H, Iken A, Benslimane L, et al. Bladder leiomyosarcomas: about 3 cases. *Pan Afr Med J* 2018; 9: 30.
8. Ohan H, Minassian G, Minassian H, Farooq T, Zdilla MJ. Retinoblastoma in infancy with subsequent bladder leiomyosarcoma in adulthood: Genomic considerations. *Urol* 2020; 140: 38-40.

9. Rodríguez D, Preston MA, Barrisford GW, Olumi AF, Feldman AS. Clinical features of leiomyosarcoma of the urinary bladder: analysis of 183 cases. *Urol Oncol.* 2014 ; 32 : 958-65.
10. Han BH, Park SB, Chang IH, Chi BH, Park HJ, Lee ES. Urothelial-phase thin-section MDCT of the bladder in patients with hematuria: added value of multiplanar reformatted images. *Abdominal Radiol* 2021; 46: 2025–2031.
11. Abouelkheir RT, Abdelhamid A, Abou El-Ghar M, El-Diasty T. Imaging of bladder cancer: standard applications and future trends. *Medicina* 2021; 57: 220.
12. Wong-You-Cheong JJ, Woodward PJ, Manning MA, Sesterhenn IA. Neoplasms of the urinary bladder: radiologic-pathologic correlation. *Radiographics* 2006; 26: 553–580.
13. Fiorentino V, Pierconti F, Lenci N, Calicchia M, Palermo G, Bassi P, Larocca LM, Martini M. Urinary bladder leiomyosarcoma with osteoclast-like multinucleated giant cells: a case report. *BMC Cancer.* 2019 2; 19(1):763.
14. Coiner BL, Cates J, Kamanda S, Giannico GA, Gordetsky JB. Leiomyosarcoma of the urinary bladder: A SEER database study and comparison to leiomyosarcomas of the uterus and extremities/trunk. *Ann Diagn Pathol.* 2021; 53:151743
15. Xu YF, Wang GC, Zheng JH, Peng B. Partial cystectomy: is it a reliable option for the treatment of bladder leiomyosarcoma? *Can Urol Assoc J* 2011; 5: E11-E13.
16. Hamadalla NY, Rifat UN, Safi KC, Mohammed M, Abu-Farsakh H. Leiomyosarcoma of the urinary bladder: A review and a report of two further cases. *Arab J Urol* 2013; 11 : 159-64.