

## Case report

### FROM TUBERCULOSIS TO RETROPERITONEAL FIBROSIS ASSOCIATED WITH TAKAYASU'S DISEASE: A COINCIDENTAL ASSOCIATION OR A PATHOGENETIC RELATIONSHIP?

#### ABSTRACT:

Retroperitoneal fibrosis (RPF), also known as Ormond's disease, is a rare and progressive condition characterized by the formation of abnormal fibroinflammatory tissue in the retroperitoneum. It can be idiopathic or secondary to infiltrative, infectious, or malignant diseases. Retroperitoneal fibrosis associated with tuberculosis is a particularly rare form, with a complex diagnosis and poorly understood pathophysiological mechanisms. At the same time, Takayasu's disease, a vasculitis primarily affecting the aorta and its major branches, can be triggered by infections, particularly *Mycobacterium tuberculosis*, through a hypersensitivity reaction. We report the case of a 26-year-old patient presenting with retroperitoneal fibrosis associated with Takayasu's disease in the context of multifocal tuberculosis, illustrating a rare combination of these conditions.

**Keywords:** tuberculosis, retroperitoneal fibrosis, Takayasu's disease.

#### INTRODUCTION:

Retroperitoneal fibrosis (RPF) is a rare disease characterized by inflammation and fibrosis of the retroperitoneal tissue, often associated with the encasement of the ureters and adjacent structures [1,2]. Its incidence is estimated at 0.1 per 100,000 people. The frequency of its association, whether synchronous or metachronous, with autoimmune diseases remains unknown and is likely underestimated [3]. According to the available literature, the association between RPF and Takayasu's disease (TD) is extremely rare [4,5]. Infection with *Mycobacterium tuberculosis* may constitute a common link between these two conditions. Herein, we present a new observation illustrating this association.

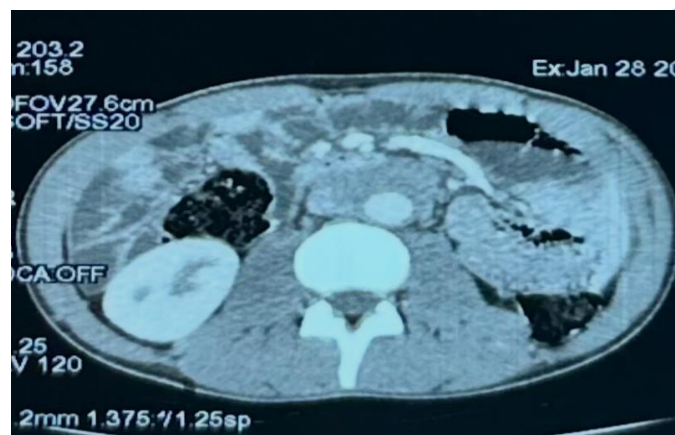#### Case presentation

##### OBSERVATION:

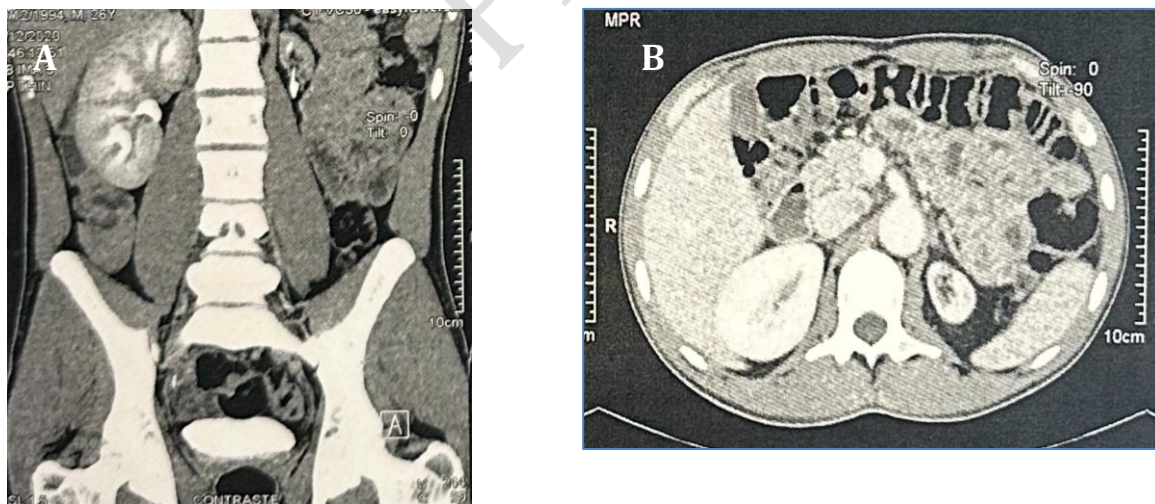
The patient was a 26-year-old man with no significant medical or surgical history, who had been experiencing chronic inflammatory lower back pain radiating to the pelvis for 8 months prior to hospitalization, accompanied by weight loss of 8 kg over 4 months, anorexia, and night sweats, without fever. Clinical examination revealed asymmetric blood pressure of 200/120 mmHg in the right arm and 180/100 mmHg in the left arm, a vascular murmur audible over the abdominal aorta, symmetrical peripheral pulses, and cervical and inguinal lymphadenopathies measuring approximately 1 cm. Laboratory tests showed an inflammatory syndrome with a C-reactive protein (CRP) level of 64 mg/L, alpha-2-globulinemia of 14.7 g/L, polyclonal hypergammaglobulinemia (15 g/L), and thrombocytosis ( $470,000/\text{mm}^3$ ), without leukocytosis. The results of lipid,

phosphocalcic, and immunological tests (ANCA and ANA) were normal. The tuberculin skin test (TST) was strongly positive at 20 mm, as was the interferon-gamma release assay (Quantiferon), while the search for Mycobacterium tuberculosis in sputum was negative. Renal and liver functions were normal, without tumor lysis syndrome, and HIV serology was negative.

A thoraco-abdomino-pelvic CT scan with angiographic sequence showed a tissue sheath encasing the aorta and inferior vena cava (IVC), hypodense and enhancing homogeneously after contrast injection, measuring 5 cm in transverse diameter and 6.6 cm in height, extending 1.5 cm below the origin of the renal arteries to the aortic bifurcation, suggestive of retroperitoneal fibrosis (figure 1). The scan also showed pre-aortic and mesenteric lymphadenopathies, the largest measuring 11 mm, a very thin but patent left renal artery with a nephritic kidney (Figure 2), superior polar splenic lesion, and pulmonary micronodules.



**Figure 1 :** A abdominal CT scan shows a tissue sheath enveloping the aorta.



**Figure 2 :** A/B : CT scan shows a nephritic kidney

Doppler ultrasound of the supra-aortic trunks revealed wall thickening of the carotid arteries, more pronounced on the right (1.24 cm), and right renal artery thickening. Positron emission tomography-computed tomography (PET-CT) showed heterogeneous and discontinuous hypermetabolism of the right common carotid, aortic arch, ascending and descending aorta, and retroperitoneal hypermetabolic tissue encasing the

descending aorta and IVC, consistent with active retroperitoneal fibrosis, accompanied by splenic hypermetabolic foci and hypermetabolic lymphadenopathy in Baret's and cervical regions.

A biopsy of the cervical lymph node showed epithelioid giant cell granulomas with caseous necrosis. A diagnosis of retroperitoneal fibrosis associated with Takayasu's disease in the context of multifocal tuberculosis was confirmed.

The clinical and biological evolution was favorable after the initiation of a 2-month quadruple anti-tuberculosis therapy (rifampicin, isoniazid, ethambutol, pyrazinamide), followed by a 4-month double therapy (rifampicin and isoniazid), corticosteroid treatment (prednisone 1 mg/kg/day for one month with gradual tapering), and antihypertensive treatment. A significant improvement was observed with the resolution of back pain, 10 kg weight gain, normalization of blood pressure, and a negative CRP level.

## **DISCUSSION:**

Retroperitoneal fibrosis (RPF) is a rare disease characterized by the formation of aberrant fibroinflammatory tissue, mainly localized around the subrenal portion of the abdominal aorta and iliac arteries. It is idiopathic in approximately two-thirds of cases, while the remaining third is attributed to secondary causes. However, the distinction between idiopathic and secondary forms remains unclear, as the causal link between the disease and secondary causes is uncertain.

RPF as a complication of tuberculosis has rarely been reported in the literature [6,7]. Although the pathophysiology of RPF is not fully understood, current data suggest an immunodysregulated origin. The pathogenic mechanisms linking tuberculosis to RPF are also poorly understood. Some authors postulate that tuberculosis may trigger autoimmune mechanisms leading to RPF, based on the following observations [8,9]:

- Mycobacteria share antigens with human tissues, which could explain the high frequency of autoantibodies observed in patients with mycobacterial infections [10].
- Monoclonal antibodies against *Mycobacterium tuberculosis*, generated in laboratory mice, can recognize autoantigens such as thyroglobulin, myosin, and collagen [11].
- Tuberculosis, as well as immunotherapy with *Bacillus Calmette-Guérin* (BCG), has been implicated in triggering inflammatory and autoimmune diseases (e.g., inflammatory arthritis and Henoch-Schönlein purpura), some of which regress after anti-tuberculosis treatment [12].

Takayasu's disease (TD) is a large-vessel vasculitis that primarily affects the aorta and its major branches, such as the subclavian, carotid, vertebral, renal, digestive, and iliac arteries. It can also affect the coronary and pulmonary arteries, leading to complications such as aneurysms and/or arterial stenosis. Although the pathogenesis of TD is not fully understood, several hypotheses, including an infectious origin, have been explored.

Tuberculosis is often cited as a potential factor due to its frequent association with TD [13]. Elevated levels of antibodies against mycobacterial antigens, including heat shock protein (HSP) 65, have been found more frequently in patients with TD than in controls [14]. Aortic tuberculosis can also be considered as a differential diagnosis.

However, this condition typically presents with aneurysms, dissections, or ruptures and is often associated with a contiguous tuberculosis focus (e.g., spinal or paraspinal abscesses) [15].

This case also highlights the importance of thoroughly investigating the potential causes of RPF and inflammatory aortitis, even when they appear idiopathic. RPF and TD are typically treated with corticosteroids and/or immunosuppressive agents [16]. In our patient, such an approach could have favored uncontrolled spread of tuberculosis.

#### **CONCLUSION:**

The association between retroperitoneal fibrosis and Takayasu's disease remains extremely rare. However, the pathogenic analogies between these two conditions suggest that they may share common underlying mechanisms, including the involvement of *Mycobacterium tuberculosis* as a triggering factor. Therefore, it is crucial to systematically investigate tuberculosis infections in cases of RPF and TD to avoid prematurely concluding an autoimmune origin. Proper management of these patients, requiring appropriate anti-tuberculosis therapy, can not only improve clinical outcomes but also prevent severe complications related to persistent inflammation.

#### **CONSENT :**

As per international standards or university standards, patient(s) written consent has been collected and preserved by the author(s).

#### **ETHICAL APPROVAL :**

Ethical approval was exempted by the Ethical Committee at Ibn Roch university hospital for reporting this case.

#### **COMPETING INTERESTS :**

Authors have declared that no competing interests exist

#### **REFERENCE :**

1. Kaaroud EH, Béji S, Ben Moussa F, Ben Hamida F, Turki S, Hedri H, et al. Retroperitoneal fibrosis. *Presse Med* 2005;34:213–7.
2. Estrade V, Traxer O, Sibony M, Haab F. Retroperitoneal fibrosis. *Ann Urol (Paris)* 2004;38:3–13.
3. Meier P, Gilaber C, Burnier M, Blanc E. Retroperitoneal fibrosis, a misunderstood inflammatory disease. Clinical observations and review of the literature. *Nephrologie* 2003;4:173–80.
4. Benucci M, Manfredi M, Michelagnoli S, Bertelli A, Cantini F. A case report of Takayasu arteritis with history of retroperitoneal fibrosis and coeliac disease: an unusual association. *Clin Exp Rheumatol* 2006;24:S104–5.
5. Houman H, Haouet S, Lamloum M, Ghorbel IB, Miled M. Retroperitoneal fibrosis associated with Takayasu arteritis. *Ann Med Interne (Paris)* 1998;149:107–8.
6. Bentley PG, Higgs DR. Peritoneal tuberculosis with ureteric obstruction, mimicking retroperitoneal fibrosis. *Br J Urol* 1976; 48:170.
7. Seth A, Ansari MS, Trikha V, Mittal R. Retroperitoneal fibrosis: a rare complication of Pott's disease. *J Urol* 2001; 166:622–3.

8. Greco P, Vaglio A, Corradi D, et al. Tuberculosis as a trigger of retroperitoneal fibrosis. *Clin Infect Dis* 2005; 41:e72-5.
9. Shoenfeld Y, Isenberg DA. Mycobacteria and autoimmunity. *Immunol Today* 1988; 9:178-82.
10. Thorns CJ, Morris JA. Common epitopes between mycobacteria and certain host tissue antigens. *Clin Exp Immunol* 1985; 61:323-8.
11. Shoenfeld Y, Vilner Y, Coates AR, et al. Monoclonal antituberculosis anti bodies react with DNA and monoclonal anti-DNA auto antibodies react with *Mycobacterium tuberculosis*. *Clin Exp Immunol* 1986; 66:255-61.
12. Islek I, Muslu A, Totan M, Gok F, Sanic A. Henoch Schoenlein purpura and pulmonary tuberculosis. *Pediatr Int* 2002; 44:545-6.
13. Lupi-Herrera E, Sanchez-Torres G, Marcushamer J, Mispireta J, Horwitz S, Vela JE. Takayasu's arteritis. Clinical study of 107 cases. *Am Heart J*. 1977;93:94-103.
14. Aggarwal A, Chag M, Sinha N, Naik S. Takayasu's arteritis: role of *Mycobacterium tuberculosis* and its 65 kDa heat shock protein. *Int J Cardiol*. 1996;55:49-55.
15. Long R, Guzman R, Greenberg H, Safneck J, Hershfield E. Tuberculous mycotic aneurysm of the aorta: review of published medical and surgical experience. *Chest* 1999; 115:522–31.
16. Gilkeson GS, Allen NB. Retroperitoneal fibrosis: a true connective tissue disease. *Rheum Dis Clin North Am* 1996; 22:23–38.