

Citrus limon Juice Promotes Healing of Cadmium-Induced Ulcerative Colitis by Enhancing Colonic Antioxidant Defense, Immune Response, and Microbial Balance in Male Wistar Rats

ABSTRACT

Ulcerative colitis (UC) an inflammatory disease, causing damage to the colon lining is intensified by long term exposure to cadmium chloride (CdCl_2) resulting in altered barrier and microbial population. *Citrus limon* has various antioxidant, anti-inflammatory, and gut microbial modulating properties. Hence, the study aims to determine *Citrus limon* juice (CLJ) effect on colitis healing of cadmium exposed rats. Sixty-four male Wistar rats weighing $200\text{g} \pm 20\text{g}$ were randomly divided into control group, CdCl_2 group, UC group, CLJ group, CdCl_2 + UC group, CdCl_2 + CLJ group, UC + CLJ group and CdCl_2 + UC + CLJ group. 5mg/kg of CdCl_2 and 7.5ml/kg of CLJ was administered orally for 25 days. Colitis was induced on day 16, 17 and 18. Compared to control group, colitis group elicited significant increase in colon weight, colonosomatic index, glutathione (GSH), 8-hydroxy-2-guanosine (8-OHdG), malonidialdehyde (MDA), myeloperoxidase (MPO), lymphocytes, *Escherichia. coli*, *Staphylococcus aureus*, fecal *Pseudomonas spp*, but decrease in body weight, red blood cell, hemoglobin, hematocrit, colonic *Klebsiella spp*, and moderate inflammatory cells infiltration. Also, CdCl_2 + UC elicited a significant increase in colon weight, colonosomatic index, superoxide-dismutase (SOD), 8-OHdG, MDA, lymphocytes, basophils, colonic *E. coli*, *Staphylococcus aureus*, fecal *Pseudomonas spp*, severe inflammatory cells infiltration and epithelial damage compared to control and UC groups. Treatment of CdCl_2 + UC with CLJ prevented epithelial damage, cells infiltration, decreased SOD, GSH, MPO, tumor necrosis factor (TNF- α), lymphocyte, neutrophil, monocyte, fecal *Pseudomonas spp*, increased colonic *Klebsiella spp*. *Citrus limon* juice ameliorated intensification and delayed healing of cadmium chloride on ulcerative colitis by regulating colonic antioxidant-immune defense system and microbial population. **These findings suggest that CLJ may serve as a potential therapeutic agent for mitigating heavy metal-induced colitis.**

Keywords: *Citrus limon* juice; Ulcerative colitis; Superoxide dismutase; Glutathione; Myeloperoxidase; Hematology; Microbial population; Inflammatory cells

Funding: Nil

INTRODUCTION

Ulcerative colitis is a chronic inflammatory disease affecting the colon, characterized by relapsing and remitting mucosal inflammation, starting in the rectum and extending to proximal segments of the colon (1-3). The colon which plays its primary role in the absorption of water, electrolytes, vitamins, formation and movement of feces toward the rectum for elimination is divided into four major segments; the cecum and ascending colon, transverse colon, descending colon, and sigmoid colon (4-5).

Intestinal epithelium, the first line of protection against luminal bacteria and foreign toxicants providing mechanical barrier is composed of five distinct cells types mainly; the enterocytes, goblet cells, enteroendocrine cells, Paneth cells and microfold cells (6). It is also a habitation to immune cells, such as dendritic cells, T cells, B cells, and macrophages, all working in close relation to maintain intestinal homeostasis (6-7). These factors and their interactions with the gut microbiota is important for maintaining intestinal homeostasis and inflammation inhibition (8).

However chronic and progressive immune disorders related to alterations in the composition of the microbiota (dysbiosis), immune response, genetic and environmental factors are all triggers for the beginning of ulcerative colitis and its risk factors include; family history, genetics, drugs, oral contraceptives, and environmental pollutants such as cigarette smoking (3, 10, 11).

Exposure to cadmium, one of the natural occurring environment pollutants derived from agricultural and industrial sources occurs via; intake of contaminated food, water, cigarette smoking and inhalation (12, 13). Its sources of contamination are related to its use in industries as a corrosive reagent, stabilizer in PVC products, color pigments, and Ni-Cd batteries (13). Its absorption takes place mainly through the respiratory tract and to an extent via the gastrointestinal tract (13).

The gastrointestinal tract and the lungs are target organs for dietary intake and inhaled cadmium (14). Due to its subsequent ingestion and mucociliary clearance, a substantial inhaled proportion (60%) ends up in the digestive tract (15). As an exogenous pollutant, it can invade the gastrointestinal tract and influence the occurrence and development of gastrointestinal diseases (16). Its exposure causes a major alteration in bacterial populations and their relative abundance in the gut followed by an increased lipopolysaccharide (LPS) production, resulting in changes in the metabolic activity of the intestinal microbiome (17, 18). It induces oxidative stress and also interferes with the activity of antioxidant enzymes, such as catalase, manganese superoxide dismutase, and copper-zinc superoxide dismutase (13).

In the intestine, it stimulates inflammatory response and cell damage resulting in increased gut permeability, bacterial translocation and increase mice susceptibility to infections (19, 20, 21). It has been reported to intensify and delay the healing of ulcerative colitis in rats (11, 22).

However, Lemon (*Citrus limon*) fruit belonging to the rutaceae family is a very good potential treatment for ulcerative colitis due to its antioxidant, anti-inflammatory properties, as well as its modulating effect on the gut microbiota (23). Its chemical composition includes eriodictyol, limocitrin, rutin, isorhamnetin and the major component hesperidin (24). Hesperidin is an inhibitor of histamine, a neurotransmitter implicated in allergic and inflammatory reactions (76). It is metabolized by the intestinal microbiota to their aglycones hesperetin and naringenin respectively. (72). They are beneficial for the health through immune modulation, anti-inflammatory properties, and improved carbohydrate and lipid metabolism (72).

METHODOLOGY

Animal care and management

Sixty-four male Wistar rats weighing $200\text{g} \pm 20\text{g}$ were used for this study. They were obtained and kept at the animal house of the Department of Physiology, Ladake Akintola University of Technology (LAUTECH), Ogbomosho Oyo State. They were acclimatized for fourteen (14) days in a well-ventilated room maintained at a constant room temperature, under a 12-h light/dark cycle and given a balanced ration of feed and water of good quality source.

Ethical certification

Ethical approval was obtained from the faculty of basic medical science ethical research committee. Ethical approval number: ERCFBMSLAUTECH:043/06/2024.

Lemon (*Citrus limon*) juice preparation

Fresh *Citrus limon* fruits were bought from Waso market Ogbomoso, Oyo State, Nigeria, rinsed with distilled and its juice squeezed out using a manual grating machine. The lemon (*Citrus limon*) fruit juice was freshly prepared for each day of the administration.

Ulcerative colitis induction

Ulcerative colitis was induced according to the modified method of Ige *et al.* (25). Rats was fasted for 24 hour and allowed free access to water. After which, rectal flushing was done using 1ml of distilled water followed by a single intra-rectal administration of 2% acetic acid (2mL/100g BW) to all colitis groups on the 16, 17 and 18 day of treatment. The rats were kept in Trendelenburg position for 50 seconds to prevent reflux.

Study design

The rats were randomly divided into eight groups of eight rats per group. Group one (control), group two (cadmium), group three (colitis), group four (*Citrus limon* juice), group five (cadmium + colitis), group six (cadmium + *Citrus limon* juice), group seven (colitis + *Citrus limon* juice) and group eight (cadmium + colitis + *Citrus limon* juice). Group 2,5,6 and 8 were administered 5mg/kg BW of CdCl orally for 25 days. Group 4,6,7, 8 were administered 7.5ml/kg BW of CLJ orally for 25 days. 2% Acetic acid was used to induced UC in Group 3,5,7 and 8 on the 16th, 17th and 18th day of treatment. The whole treatment lasted for 25 days.

Animal sacrifice and organ collection

The rats were sacrificed on the twenty sixth (26th) day of administration, by cervical dislocation method. Blood averaging (1.5-2.0ml) was collected from the rats through cardiac puncture for hematological analysis. The distal colon of the rats measuring six (6) cm beginning from the proximal end of the rectum was excised and the fecal content collected for fecal microbial count analysis. The excised distal colon was rinsed in saline and divided into three portions (proximal, mid and distal). The distal portion of the colon was preserved in 0.25M sucrose solution maintained 4°C for biochemical assays. The mid portion of the colon was preserved in 10% formalin for histological analysis, while the proximal region was reserved for intestinal microbiota count analysis.

Assessment of disease activity index of ulcerative colitis

The disease activity index (DAI) of ulcerative colitis was assessed as the basis for clinical assessment of intestinal inflammation and quantified according to the method of Alsharif *et al.*, (26). Changes in body weight, colonic weight, colonosomatic index, were assessed.

Assessment of antioxidant enzymes and oxidative markers in the colon

Colons were homogenized using a Potter-Elvehjem homogenizer (Ultra-Turrax T25, Janke and Kunkel IKA-Labortechnik, Staufen, Germany) on ice-cold Tris-HCl buffer (0.01 M, pH 7.4) to give a 10% homogenate which was used for assays of Superoxide dismutase (SOD), Catalase, Reduced glutathione(GSH), 8-hydroxy-2-deoxyguanosine(8-OHdG), Malondialdehyde (MDA), Myeloperoxidase (MPO) level, Tumor Necrosis Factor (TNF- α) and nuclear factor kappa B cells (NF-kB) .

Activity of SOD and catalase in the colon was determined as described by Misra and Fridovich (1972) and Sinha (1972) respectively (27, 28). The method of Ansari *et al.* (2021) and Otu-Boakye *et al.* (2023) was followed for GSH and MDA respectively, (29, 30). Myeloperoxidase, 8-OHdG levels, TNF- α assays were done using enzyme linked immunosorbent assay (ELISA) kits, as instructed by the manufacturer (eBIOSCIENCE, Bender MedSystems GmbH, Wien, Austria).

Analysis of intestinal and fecal microbiota using serial dilution method

The large intestines (distal colons) were removed and individual sections cut longitudinally. After removal of the intestinal fluids, the tissue samples were washed with sterilized buffered peptone water (LaB M) mixed with 20% glycerol (Merck Millipore) and then vortex mixed to break down bacterial clumps and to remove loosely attached bacteria. Samples were stored in 20% glycerol in sterilized buffered peptone water (LaB M) at -20°C until microbiological analysis was performed (31, 32).

Intestinal tissues and feces were separately homogenized with sterilized buffered peptone water (LaB M) and were subjected to serial dilutions using $\frac{1}{4}$ strength Ringer's solution (LaB M) the procedure of Yanni *et al.* (2020) was then followed for further examination, (33).

Histological assessment of ulcerative colitis

The intensity of colonic tissues damage was assessed by staining with hematoxylin and eosin (H & E) stains and characterized according to Appleyard and Wallace (1995). A histopathologist, who was unaware of the treatments, observed and characterized the histological tissues. Pictures were obtained using a digital camera (Olympus DP21) attached with a microscope (30, 34).

Statistical analysis

Data were presented as Mean \pm standard error of the mean (Mean \pm SEM) and analyzed using graph pad prism 5, One-way analysis of variance (ANOVA). Tukey's post-hoc test was used for multiple comparisons. $P < 0.05$ was considered statistically significant.

RESULTS

Effect of *Citrus limon* juice on body weight changes, colon weight, and colonosomatic index in acetic acid-induced ulcerative colitis of cadmium exposed male Wistar rats.

Rats induced with colitis showed a significant increased colon weight and colonosomatic index accompanied by a significant weight reduction. The exposure of these colitis rats to cadmium resulted in a further significant increase in colon weight and colonosomatic index when compared to cadmium group and control group. However, treatment of cadmium exposed colitis rats with *Citrus limon* juice resulted in a reduction in body weight.

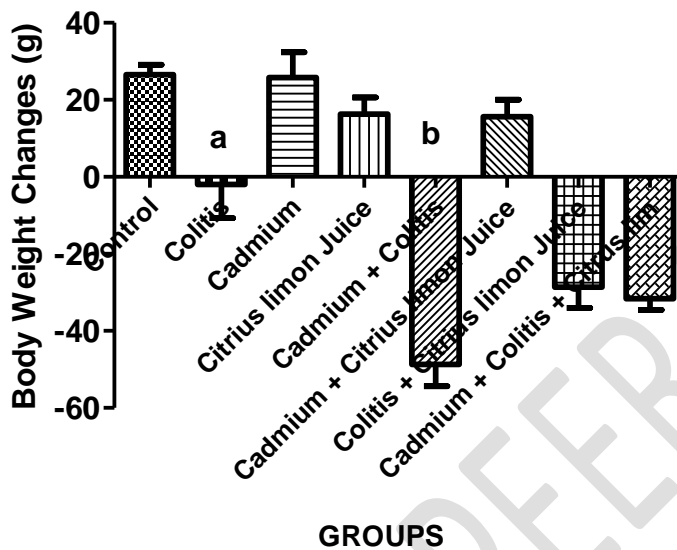


Figure 1a: Effect of *Citrus limon* juice on body weight in acetic acid-induced ulcerative colitis of cadmium exposed male Wistar rats.

- a** -Represents significant difference ($P < 0.05$) when compared with control group.
- b** - Represents significant difference ($P < 0.05$) when compared with colitis group.

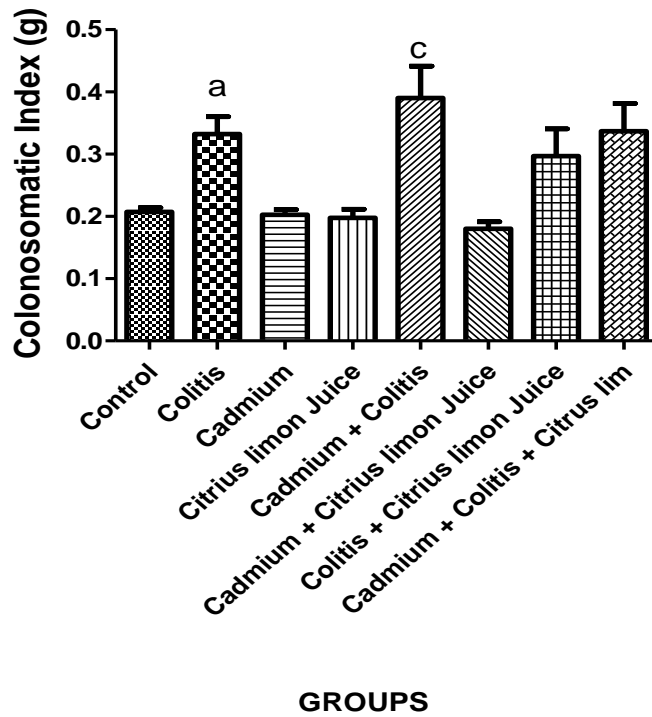


Figure 1b: Effect of *Citrus limon* juice on colonosomatic index in acetic acid-induced ulcerative colitis of cadmium exposed male Wistar rats.

a -Represents significant difference ($P < 0.05$) when compared with control group.

c - Represents significant difference ($P < 0.05$) when compared with cadmium group.

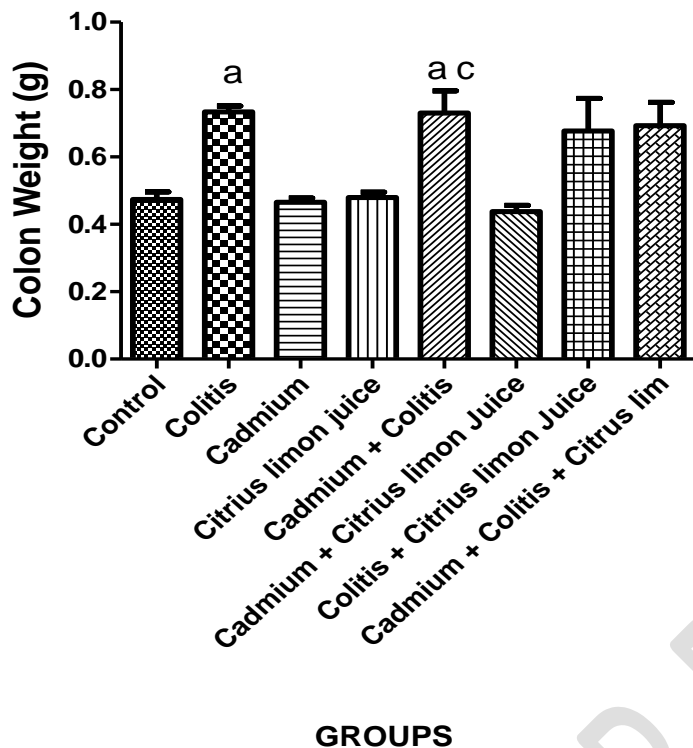


Figure 1c: Effect of *Citrus limon* juice on colon weight in acetic acid-induced ulcerative colitis of cadmium exposed male Wistar rats.

a -Represents significant difference ($P < 0.05$) when compared with control group.

c - Represents significant difference ($P < 0.05$) when compared with cadmium group

Effect of *Citrus limon* juice on antioxidant enzymes in acetic acid-induced ulcerative colitis of cadmium exposed male Wistar rats.

Rats induced with colitis showed increase in GSH level when compared to control group, while cadmium exposed colitis rats showed a significant increase in SOD when compared to colitis group and control group. Treatment of cadmium exposed colitis rats with *Citrus limon* juice showed a significant reduction in SOD and GSH when compared to cadmium exposed colitis group and when compared to control group. No significant difference was seen in catalase level across all groups.

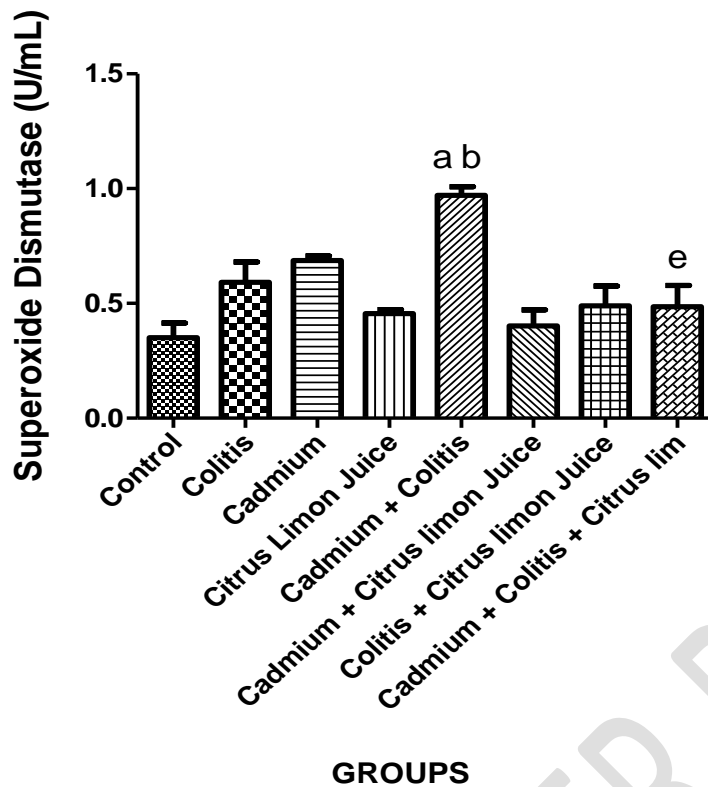


Figure 2a: Effect of *Citrus limon* juice on superoxide dismutase level in acetic acid-induced ulcerative colitis of cadmium exposed male Wistar rats.

a - Represents significant difference ($P < 0.05$) when compared with control group.

b - Represents significant difference ($P < 0.05$) when compared with colitis group.

e - Represents significant difference ($P < 0.05$) when compared with cadmium + colitis group.

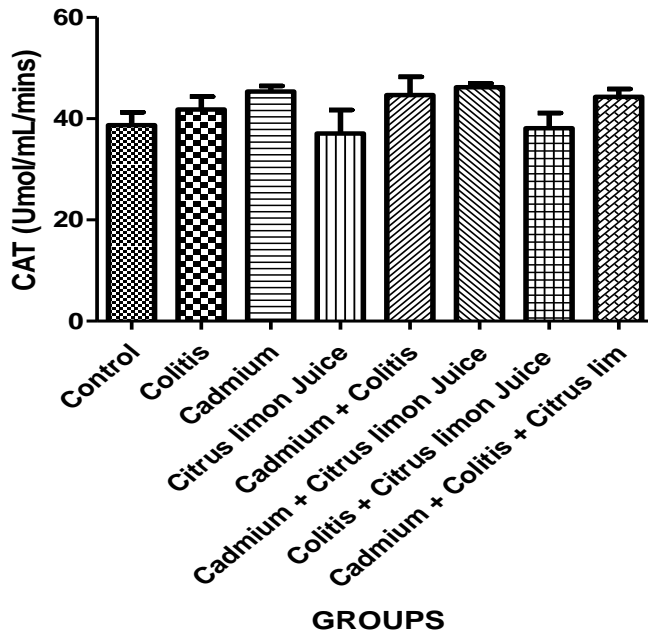


Figure 2b: Effect of *Citrus limon* juice on superoxide dismutase level in acetic acid-induced ulcerative colitis of cadmium exposed male Wistar rats.

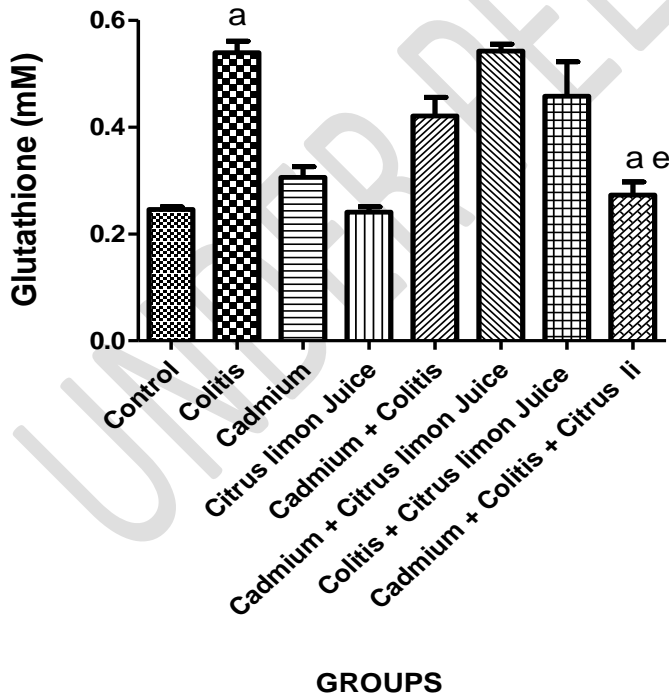


Figure 2c: Effect of *Citrus limon* juice on reduced glutathione level in acetic acid-induced ulcerative colitis of cadmium exposed male Wistar rats.

- a -Represents significant difference (P<0.05) when compared with control group.
- e - Represents significant difference (P<0.05) when compared with cadmium + colitis group.

Effect of *Citrus limon* juice on oxidative stress markers in acetic acid-induced ulcerative colitis of cadmium exposed male wistar rats.

Colitis group showed a significant increase in 8-OHdG, MDA and MPO when compared to control group. Cadmium exposed colitis rats showed a significant increase in 8-OHdG when compared to cadmium. MDA was increased in all cadmium exposed rats when compared to control group. Treatment of colitis group with *Citrus limon* juice showed a significant reduction in MPO when compared to colitis group.

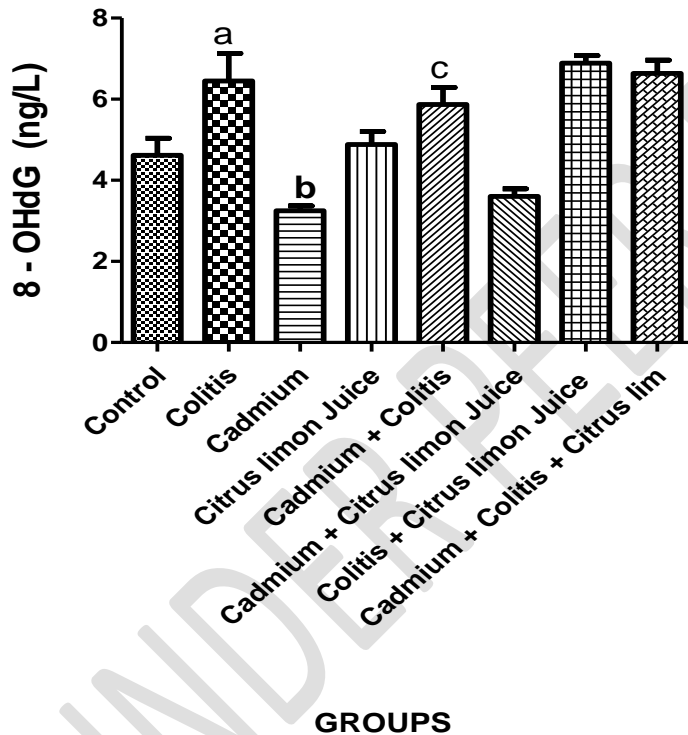


Figure 3a: Effect of *Citrus limon* juice on 8-hydroxy-2-deoxyguanosine level in acetic acid-induced ulcerative colitis of cadmium exposed male Wistar rats.

- a -Represents significant difference (P<0.05) when compared with control group.
- b - Represents significant difference (P<0.05) when compared with colitis group.
- c - Represents significant difference (P<0.05) when compared with cadmium group

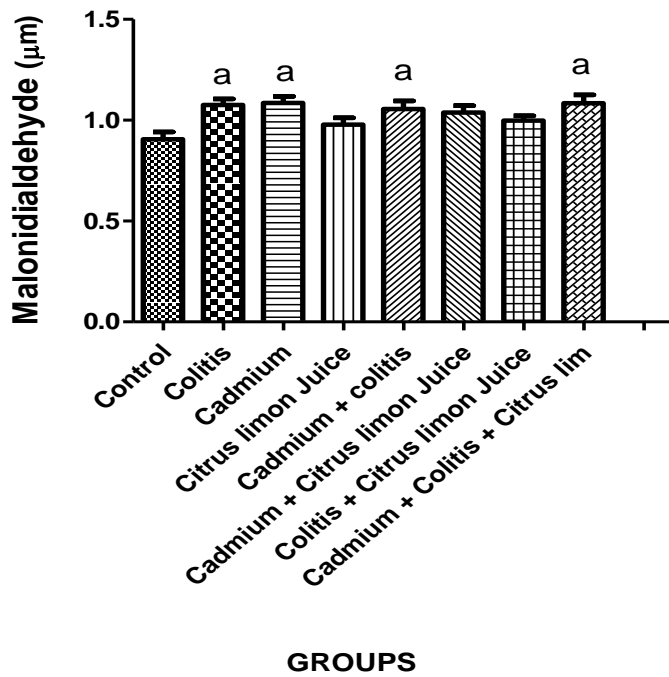


Figure 3b: Effect of *Citrus limon* juice on malondialdehyde level in acetic acid-induced ulcerative colitis of cadmium exposed male Wistar rats.

a -Represents significant difference ($P < 0.05$) when compared with control group.

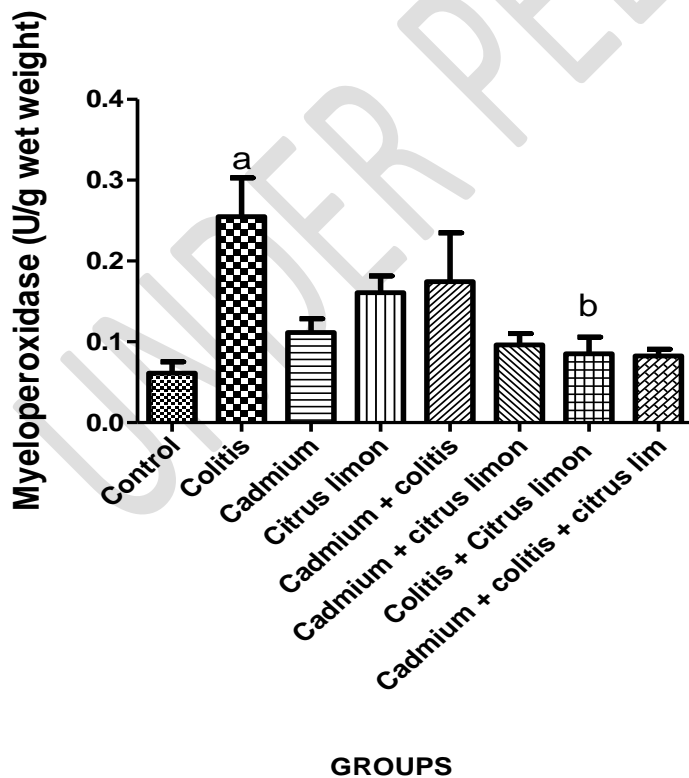


Figure 3c: Effect of *Citrus limon* juice on myeloperoxidase level in acetic acid-induced ulcerative colitis of cadmium exposed male Wistar rats.

- a -Represents significant difference ($P < 0.05$) when compared with control group.
- b - Represents significant difference ($P < 0.05$) when compared with colitis group.

Effect of *Citrus limon* juice on pro-inflammatory markers in acetic acid-induced ulcerative colitis of cadmium exposed male Wistar rats.

Colitis group showed no significant difference in TNF- α when compared to control group, however a significant increase was observed in cadmium group when compared to control group. No significant difference was observed in TNF- α level in Cadmium exposed colitis rats when compared to colitis group. However, cadmium + *Citrus limon* juice group showed a significant reduction in TNF- α when compared to cadmium group.

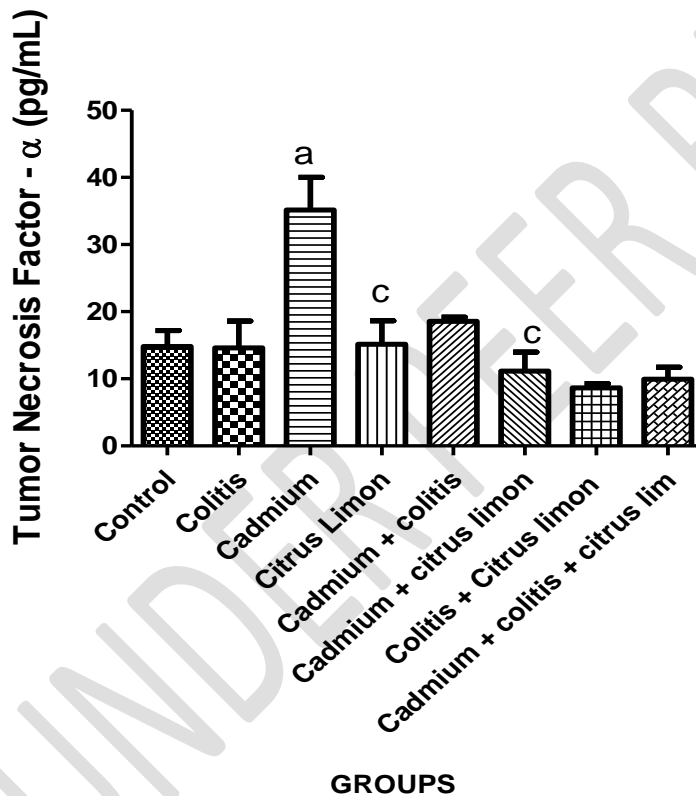


Figure 4a: Effect of *Citrus limon* juice on tumor necrosis factor - alpha

- a -Represents significant difference ($P < 0.05$) from control group.
- c - Represents significant difference ($P < 0.05$) from cadmium group

Effect of *Citrus limon* juice on Red blood cell (RBC) indices in acetic acid-induced ulcerative colitis cadmium exposed male Wistar rats.

Colitis group showed a significant decrease in decrease red blood cell count, hemoglobin concentration and hematocrit level when compared to the control group while cadmium exposed colitis group showed a non-significant decrease when compared to colitis group. However, colitis + *Citrus limon* juice group and cadmium + colitis + *Citrus limon* showed no significant difference when compared to colitis and cadmium + colitis group.

Table 1.0: Effect of *Citrus limon* juice on Red blood cell (RBC) indices

| Red Blood Cell (RBC) Indices | Control | Colitis | Cadmium | <i>Citrus limon</i> juice | Cadmium + Colitis | Cadmium + <i>Citrus limon</i> Juice | Colitis + <i>Citrus limon</i> Juice | Cadmium + Colitis + <i>Citrus limon</i> Juice |
|-------------------------------------|----------------|--------------------------|----------------|----------------------------------|--------------------------|--|--|--|
| RBC | 7.45 ± 0.10 | 5.95 ± 0.16 ^a | 7.09 ± 0.26 | 7.18 ± 0.01 | 6.5 ± 0.90 | 7.06 ± 0.24 | 6.6 ± 0.35 | 6.22 ± 0.25 |
| RDW-CV | 15.6 ± 0.69 | 15.8 ± 0.20 | 14.7 ± 0.86 | 16.2 ± 0.93 | 15.5 ± 0.72 | 14.75 ± 0.42 | 17.4 ± 0.61 | 17.2 ± 0.40 |
| RDW-SD | 41.1 ± 1.75 | 41.5 ± 1.27 | 40.3 ± 1.93 | 43.7 ± 0.32 | 39.9 ± 4.51 | 42.1 ± 2.45 | 47.2 ± 2.88 | 48.1 ± 3.28 ^e |
| HCT | 47.4 ± 0.96 | 37.6 ± 1.36 ^a | 49.5 ± 0.51 | 47.5 ± 3.11 | 41.8 ± 5.85 | 50.5 ± 2.48 | 44.6 ± 3.53 | 42 ± 1.19 |
| HGB | 14.6 ± 0.38 | 12.5 ± 0.52 ^a | 15.5 ± 0.78 | 13.8 ± 0.52 | 13.4 ± 1.25 | 15.2 ± 0.41 | 13.9 ± 0.98 | 13.4 ± 0.30 |

a -Represents significant difference (P<0.05) from control group.

e - Represents significant difference (P<0.05) from cadmium + colitis group

Effect of *Citrus limon* juice on white blood cell (WBC) indices in acetic acid induced ulcerative colitis of cadmium exposed male Wistar rats.

Colitis group showed a significant increase in lymphocyte when compared to cadmium group, while rats exposed to cadmium showed a significant increase in neutrophils when compared to control group. Cadmium exposed colitis rats showed a significant increase in lymphocytes and basophil level when compared to cadmium group. However, treatment of colitis rats with *Citrus limon* juice showed a significant increase in neutrophil, white blood cell count, and monocyte.

Table 2.0: Effect of *Citrus limon* juice on white blood cell (WBC) indices

| White Blood Cell (WBC) Indices | Control | Colitis | Cadmium | <i>Citrus limon</i> | Cadmium + Colitis | Cadmium + <i>Citrus limon</i> Juice | Colitis + <i>Citrus limon</i> Juice | Cadmium + Colitis + <i>Citrus limon</i> Juice |
|--------------------------------|-------------|--------------------------|--------------------------|-------------------------|-----------------------------|-------------------------------------|-------------------------------------|---|
| WBC Count | 8.73 ± 1.08 | 5.63 ± 0.54 | 8.98 ± 1.78 | 10.7 ± 1.33 | 8.28 ± 0.78 | 12.5 ± 2.82 | 11 ± 1.34 ^b | 12.2 ± 2.72 |
| Lymphocytes | 69.3 ± 2.87 | 75.9 ± 6.24 ^c | 56.3 ± 7.66 | 69.3 ± 11.3 | 79.1 ± 3.74 ^c | 78.9 ± 2.63 | 69.3 ± 3.09 | 70.1 ± 5.85 |
| Monocyte | 1.65 ± 0.35 | 1.97 ± 0.35 | 1.3 ± 0.2 | 0.53 ± 0.2 ^b | 2.5 ± 0.42 | 0.77 ± 0.53 | 0.55 ± 0.25 ^b | 3.9 ± 0.56 |
| Neutrophil | 17.8 ± 6.64 | 28 ± 4.45 | 33.8 ± 4.26 ^a | 17.8 ± 7.25 | 24.4 ± 9.48 | 19.4 ± 3.78 | 7.66 ± 1.90 ^b | 15.6 ± 1.99 |
| Basophil | 0.53 ± 0.15 | 1.1 ± 0.1 | 0.9 ± 0.34 | 0.6 ± 0.17 | 1.86 ± 0.46 ^{a, c} | 0.73 ± 0.30 | 0.56 ± 0.20 | 1.52 ± 0.43 |
| Eosinophil | 1.15 ± 0.96 | 0.43 ± 0.15 | 0.37 ± 0.17 | 1.13 ± 0.40 | 0.56 ± 0.15 | 2.25 ± 0.07 ^c | 0.7 ± 0.17 | 1.1 ± 0.26 |

- a -Represents significant difference (P<0.05) from control group.
- b - Represents significant difference (P<0.05) from colitis group.
- c - Represents significant difference (P<0.05) from cadmium group

Effect of *Citrus limon* juice on colon and fecal microbial count in acetic acid-induced ulcerative colitis of cadmium exposed male Wistar rats.

Cadmium exposed colitis rats showed an increase in colonic *E. coli*, *Staphylococcus aureus* and a decrease in *Klebsiella spp*. However, their treatment of colitis with *Citrus limon* juice showed a significant increase in *Klebsiella spp* and a decrease in *Staphylococcus aureus* population. Cadmium exposed colitis rats showed an increase in fecal *Pseudomonas sp*. However, their treatment with *Citrus limon* juice showed a reduction in fecal *Pseudomonas spp*.

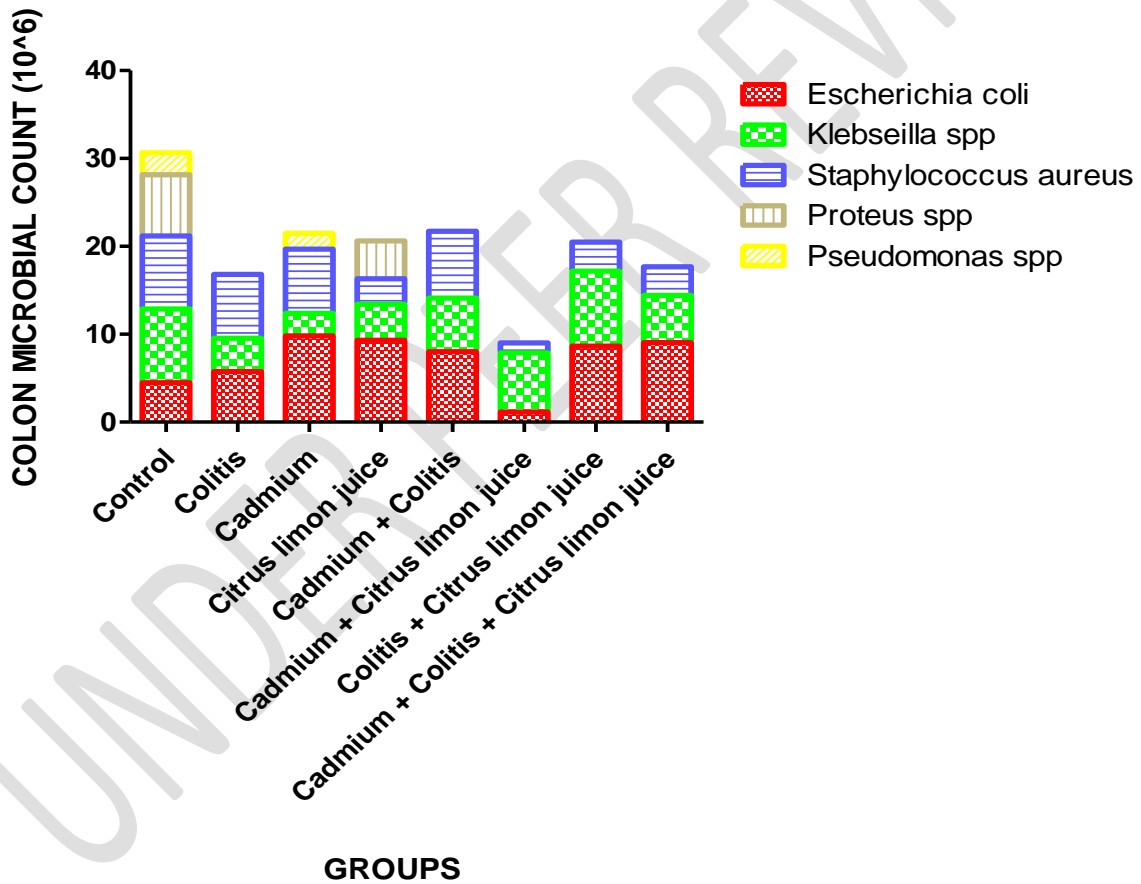


Figure 5a: Effect of *Citrus limon* juice on colon microbial count in acetic acid-induced ulcerative colitis of cadmium exposed male Wistar rats.

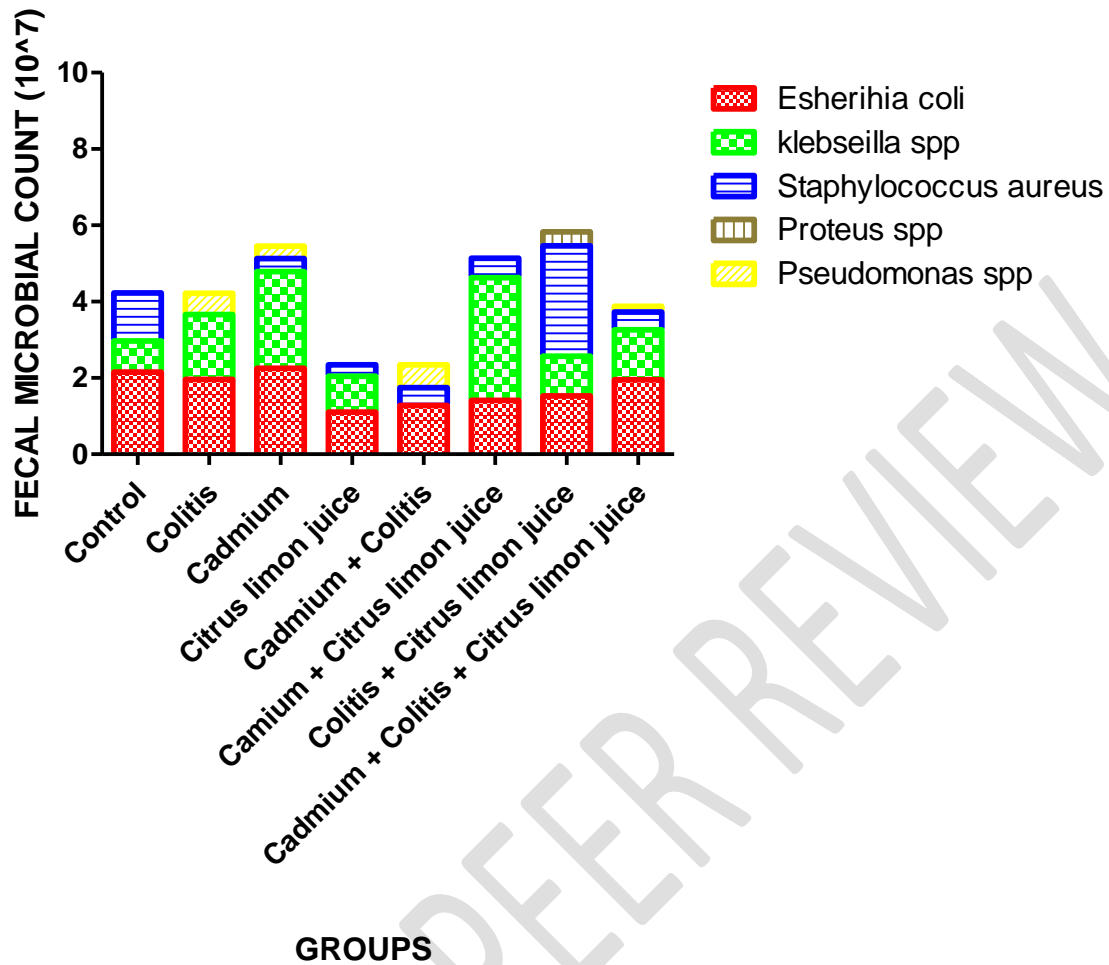
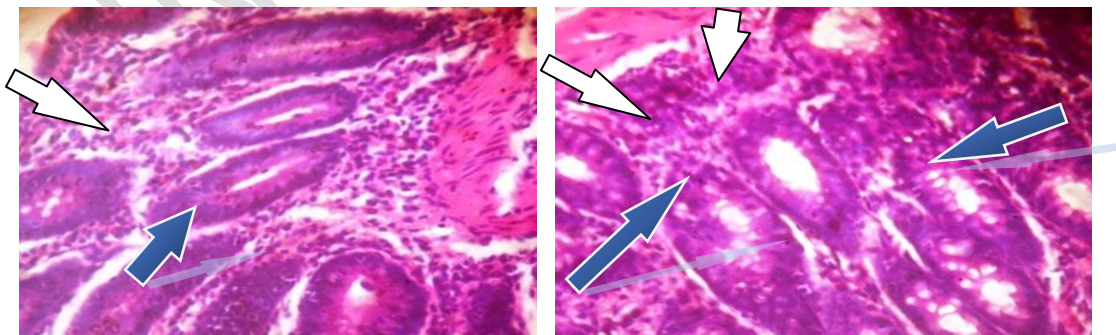


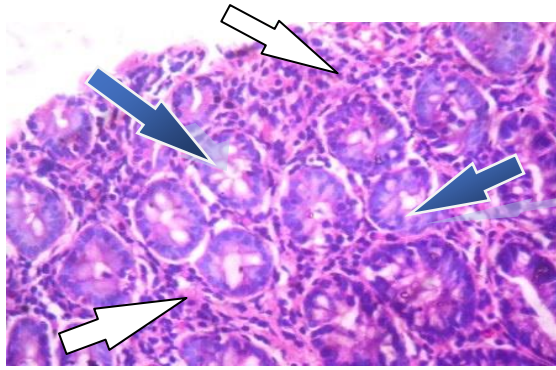
Figure 5b: Effect of *Citrus limon* juice on fecal microbial count in acetic acid-induced ulcerative colitis of cadmium exposed male Wistar rats.

Effect of *Citrus limon* juice on colon histology in acetic acid-induced ulcerative colitis of cadmium exposed male Wistar rats.

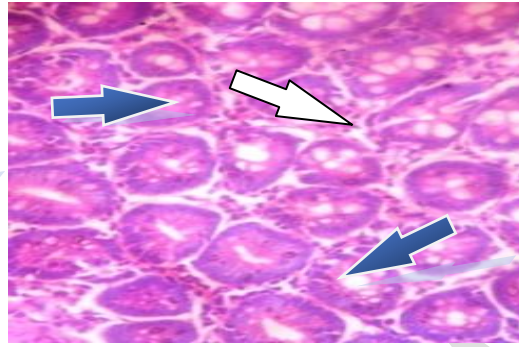


Control

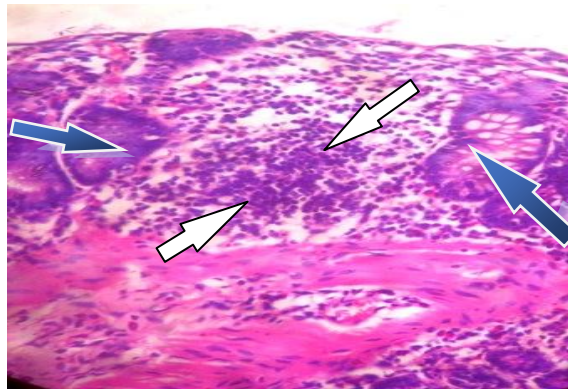
Colitis



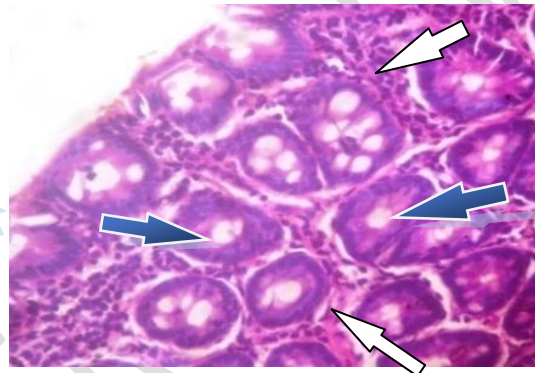
Cadmium



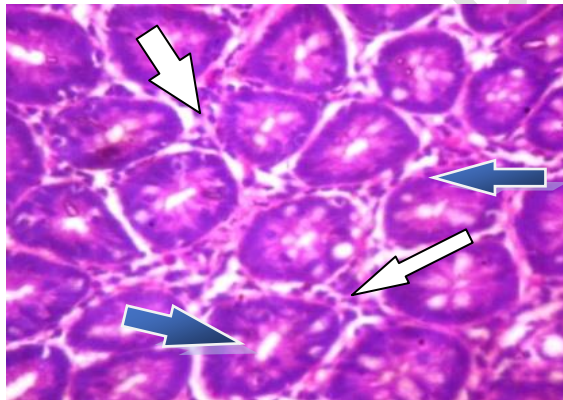
***Citrus limon* juice**



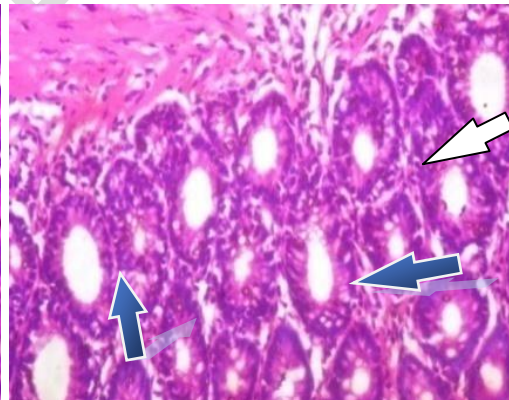
Cadmium + Colitis



Colitis + *Citrus limon* juice



Cadmium + *Citrus limon* juice




Cadmium + Colitis + *Citrus limon* juice

Figure 6: Photomicrograph showing the effect of *Citrus limon* juice on acetic acid-induced ulcerative colitis in cadmium exposed male Wistar rats.



Colon epithelial layer



Inflammatory cells infiltration of the lamina propria

DISCUSSION

Cadmium has been implicated in the delayed healing of ulcerative colitis through the excessive production of reactive oxygen species, depletion of antioxidants, and the loss of mucosa integrity (11, 22). This present study investigated the effect of *Citrus limon* juice on acetic acid-induced ulcerative colitis in cadmium chloride exposed male Wistar rats.

The findings of this study showed that colitis rats exposed to cadmium showed a significant decrease in body weight, increase in colon weight and colonosomatic index, while treatment with *Citrus limon* juice resulted in further weight loss. In agreement with previous studies, this observation is believed to be the result of mal-absorption, reduced food intake, loss of fluid through diarrhea and rectal bleeding followed by an increased lipid and protein degeneration by cadmium (22, 29).

Citrus limon juice has been reported to have lipid-lowering activity (35). Consumption of its fruits or juices appears to correlate with ameliorated blood lipid profiles, survival in the elderly, lower risk of cancers, decreased blood pressure, diminished risk of heart maladies' occurrence, and treatment of obesity (36).

The findings of this study showed that treatment of colitis rats and cadmium exposed colitis rats with *Citrus limon* juice showed a reduction in weight. The reduction according to previous studies, has been attributed to the role of *Citrus limon* in regulating lipid metabolism while inhibiting lipid accumulation around the abdominal organs (35, 37).

Further findings in this study revealed that colitis rats showed a significant increase in glutathione level compared to control rats, and cadmium exposed colitis rats showed a significant increase in superoxide dismutase when compared to control and colitis rats. These antioxidant defense enzymes are the major antioxidants present to combat free radicals produced through oxidative stress, following a problem related to a disease, (38). The increase level of superoxide dismutase observed in cadmium exposed rats, according to previous study is associated with a rapid antioxidant defense response to the presence of excessive free radicals generated through the action of cadmium, while higher level of reduced glutathione observed in colitis rats has been suggested to provide additional support to the antioxidant defense system response to free radicals (39, 40).

Citrus limon due to its high flavonoid's compounds such as hesperidin and hesperetin have been reported to have high antioxidant activity that is not only limited to scavenging of free radicals but also plays a major role in augmenting and enhancing the antioxidant cellular defenses (41).

The findings of this study also demonstrated that treatment of cadmium exposed colitis rats with *Citrus limon* juice resulted in a significant reduction in glutathione level when compared to colitis rats, so also cadmium exposed colitis rats showed a significant increase in superoxide dismutase rats when compared to control and colitis however treatment with citrus juice caused reduction in SOD when compared with cadmium exposed colitis rats, therefore indicating the restoration of the antioxidant defense system to a near normal level. This result is in agreement

with previous studies report on the modulating and regulatory potential of *Citrus limon* juice on the antioxidant defense system response to oxidative stress (42).

Cadmium exerts its toxic effect as a xenobiotics by inhibiting the activity of complex II, and complex III of the electron transfer chain, the principal site of reactive oxygen species (ROS) production as a result of oxidative stress, resulting in ROS accumulation and the activation of sequence of events such as apoptosis (13, 43). Oxidative stress biomarkers, are very relevant in the evaluation of disease state and progression (44).

The findings of this study revealed that colitis rats had a significant increase in MDA, OHdG and MPO when compared to control rats, while cadmium rats showed a significant reduction in OHdG when compared colitis rats. However, cadmium exposed colitis rats showed a significant increase in MDA when compared to control group and a significant increase in OHdG when compared to cadmium group rats. This is in agreement with previous studies that reported a significant increase in MDA, OHdG and MPO as a result of oxidative stress induction via cytotoxic oxygen metabolites stimulation and lipid peroxidation while the increase in MDA in cadmium exposed colitis rats may be suggested to be influenced by damage caused by cadmium mechanism of inflammation (45 - 47).

Citrus limon juice has been reported to reduce lipid peroxidation and also protect DNA from damage through one of its component vitamin C (48, 49). Malondialdehyde is characterized by cross linking cellular macromolecules including proteins and DNA, and induces cellular damage (50).

Findings of this study demonstrated that treatment of colitis rats with *Citrus limon* juice resulted in a significant reduction in MPO. This is in agreement with a previous study report on *Citrus limon* reducing the level of lipid peroxidation (51). However, treatment of cadmium exposed colitis rats with *Citrus limon* juice showed no significant difference in, OHdG and MDA when compared to control rats.

Cadmium has been reported to upregulate inflammatory cytokines in the colon (11, 52). It increases the level of inflammation in colitis rats through increased neutrophil/lymphocyte ratio thereby delaying the healing of colitis (22). It releases into the intestinal mucosa has been associated with intestinal epithelial barrier disruption (53).

Findings of this study showed that rats induced with colitis showed no significant difference in TNF- α when compared to control rats, and this is been attributed to the natural onset of healing beginning few days after colitis induction (11). However, a significant increase in TNF- α level was observed in cadmium exposed rats.

Citrus limon exhibit anti-inflammatory effects due to its high concentration of D-limonene, which play a major role in reducing cell migration, cytokine production (54). Findings of this study revealed that, treatment of cadmium exposed rats with *Citrus limon* juice showed a significant reduction in TNF- α level when compared to cadmium rats. This is in agreement with a previous report on the regulatory activity of *Citrus limon* on TNF- α in human colon by some of its components; nomilin and D- limonene (54, 55).

Cadmium has similar chemical composition to essential metals, such as iron, zinc, and calcium and can be taken up cells through ionic and molecular mimicry (56). It binds to the same protein in the blood and tissues such as albumin and metallothionein, and compete for uptake in the cells (57) Blood plays a major role in the transport of oxygen and nutrients (4). Its binding to metallothionein has been reported to cause oxidative stress, bone metabolism disturbance through the displacement of calcium, reduce blood flow and nutrients uptake inhibition (57).

Findings from this study revealed that rats induced with colitis showed a significant reduction in red blood cell, hemoglobin and hematocrit when compared to control rats. Also, the exposure of colitis rats to cadmium didn't cause any significant changes in red blood cell, hemoglobin and hematocrit concentration when compared to colitis or control group. Therefore, it is believed that the reduction in red blood cell, hemoglobin and hematocrit are the consequences of blood loss from the gastrointestinal tract (58).

Citrus limon has been suggested as a prevention of cardiovascular diseases, and may play a major role on hematological parameters due to its components such as vitamin c, flavonoids, iron and pyridoxine (59). It was reported to cause a significant increase in red blood cell and hemoglobin concentration (59). However, findings of this study showed that treatment of colitis rats, cadmium exposed rats and cadmium exposed colitis rats with *Citrus limon* juice didn't result in the restoration of the red blood cell count, hematocrit and hemoglobin concentration.

One of the ways the immune system provides defense against foreign particles and pathogenic organisms is through inflammation (60). Uncontrolled or excessive inflammation would cause damage to the host tissues damage and a resulting pathology (60). Cadmium has been reported to increase inflammation in rats during colitis through increased neutrophil or lymphocyte ratio (22).

The findings of this study showed a significant increase in lymphocytes in colitis group when compared to cadmium group and a significant increase in neutrophil in cadmium group when compared to control group. However, exposure of colitis rats to cadmium resulted in a significant increase in lymphocyte and basophil when compared to cadmium group and a significant increase in basophil when compared to control group. This, according to a previous study suggest a functional immune defense system rapid response to cadmium toxicity and severity of inflammation (61).

Citrus fruits exert their role in maintaining the integrity of the immunological barriers, and enhancing the functions of the immune cells such as natural killer cells, T-lymphocytes and B-cells through their components such as vitamin C and folate (60).

The findings of this study also demonstrated that treatment of colitis rats with *Citrus limon* juice caused a significant decrease in neutrophil and monocyte level while an increase was observed in white blood cell count. The reduction in neutrophil and monocyte can be attributed to the flavonoid component of *Citrus limon*, inhibiting monocyte inflammation and neutrophil generation of superoxide radicals (62, 63).

Thousands of bacteria species dwelling in the colon, in a state of “healthy” homeostasis, help with digestion, metabolism, and immune modulation (64, 65). Disruption of this state, called dysbiosis, is believed to be associated with various consequences such as ulcerative colitis (66). Exposure to cadmium induces a significant alteration in bacterial populations and their relative abundance in gut, accompanied by increased lipopolysaccharide (LPS) production, reflecting changed metabolic activity of the intestinal microbiome (17,18).

Findings of this study revealed an increase population of colonic *E. coli* and colonic *Staphylococcus aureus* and fecal *Pseudomonas spp* in cadmium exposed colitis rats when compared to control and colitis group. This is in agreement with report from previous studies on increase population of *E. coli* and *Pseudomonas spp* due to indirect (immuno-compromised host) cadmium stimulation of these microbes to produce virulence factors that triggers gene expression, inflammatory response and intestinal barrier damage (67). *Pseudomonas spp* increased population has also been attributed to its versatile and high tolerance for cadmium (68).

Extracts from *Citrus limon* fruits have been reported to have inhibitory and antibacterial activity against *Staphylococcus mutans*, *Staphylococcus capitis*, *Pseudomonas fluorescens* and *Escherichia coli* (69, 70).

Treatment of cadmium exposed colitis rats with *Citrus limon* juice resulted in an increase colonic *Klebsiella spp* and a decrease colonic *Staphylococcus aureus* and fecal *Pseudomonas spp*. This agrees with previous studies on *Citrus limon* effect in maintaining a healthy balance microbial population, by increasing colonic *Klebsiella spp* population which play a major role in preventing inflammation through *E. coli* clearance, while at the same time preventing colonic *Staphylococcus aureus* colonization through one of its component citric acid (71, 72, 73).

Histological examination revealed that induction of colitis caused moderate infiltration of inflammatory cells and preservation of epithelial layer while their exposure to cadmium resulted in a severe destruction of epithelial layer and infiltration of inflammatory cells. However, their treatment with *citrus limon* juice showed a moderate preservation of epithelial layer and infiltration of inflammatory cells. According to previous studies, the moderate and severe epithelial layer destruction and inflammatory cells infiltration is suggested to be associated with T-cell abnormalities and increased macrophage inflammatory protein-2 expression by cadmium (52, 74). The preservation of the epithelial layer and the prevention of inflammatory cells infiltration by can be attributed to the ability of *Citrus limon* to enrich the mucus layer (75).

CONCLUSION

Citrus limon juice neutralized the intensification and delayed healing effect of cadmium chloride on ulcerative colitis by modulating and regulating the antioxidant-immune defense system response, while maintaining a healthy microbial population.

DISCLAIMER (ARTIFICIAL INTELLIGENCE)

Author(s) hereby declare that NO generative AI technologies such as Large Language Models (ChatGPT, COPILOT, etc.) and text-to-image generators have been used during the writing or editing of this manuscript.

REFERENCE

1. Torres J, Billioud, V, Sachar DB, Peyrin-Biroulet L, and Colombel JF. Ulcerative colitis as a progressive disease: the forgotten evidence. *Inflammatory bowel diseases*. 2012; 18(7):1356-1363.
2. Høivik ML, Moum B, Solberg IC, Henriksen M, Cvancarova M, Bernklev T, et al. Work disability in inflammatory bowel disease patients 10 years after disease onset: results from the IBSEN Study. *Gut*. 2013;62(3):368-375.
3. Rowan C, Ungaro R, Mehandru S, and Colombel JF. An overview of ozanimod as a therapeutic option for adults with moderate-to-severe active ulcerative colitis. *Expert Opinion on Pharmacotherapy*. 2022;23(8), 893-904.
4. Azzouz LL, Sharma S. Physiology, large intestine. 2018
5. Ogobuiro I, Gonzales J, Shumway KR, Tuma F. Physiology, gastrointestinal. InStatPearls [Internet] 2023. StatPearls Publishing.
6. Beisner J, Stange EF, Wehkamp J. Innate antimicrobial immunity in inflammatory bowel diseases. *Expert Review of Clinical Immunology*. 2010;1;6(5):809-18.
7. Eri R, Chieppa M. Messages from the inside. The dynamic environment that favors intestinal homeostasis. *Frontiers in immunology*. 2013; 4:323.
8. Yoo JY, Groer M, Dutra SV, Sarkar A, McSkimming DI. Gut microbiota and immune system interactions. *Microorganisms*. 2020;8(10):1587.
9. Tomasello G, Tralongo P, Damiani P, Sinagra E, Di Trapani B, Zeenny MN, et al. Dismicrobism in inflammatory bowel disease and colorectal cancer: changes in response of colocytes. *World journal of gastroenterology: WJG*. 2014;20(48):18121.

10. Ananthakrishnan AN. Epidemiology and risk factors for IBD. *Nature reviews Gastroenterology & hepatology*. 2015;12(4):205-17.
11. Jiang Z, Mu W, Yang Y, Sun M, Liu Y, Gao Z, Li J, Gu P, Wang H, Lu Y, Ba Q. Cadmium exacerbates dextran sulfate sodium-induced chronic colitis and impairs intestinal barrier. *Science of The Total Environment*. 2020; 744:140844.
12. Ige SF, Adeniyi MJ, Ademilua OB, Fatola AO, Adeyemi IA, Okunlola AI, Akinyoade RA. Allium cepa remediates oxidative stress-mediated hepatic DNA damage in cadmium-exposed rats through enhanced p53 expression and inhibition of bcl2. *Int J Biomed Sci*. 2020;16(2):11-7.
13. Genchi G, Sinicropi MS, Lauria G, Carocci A, Catalano A. The effects of cadmium toxicity. *International journal of environmental research and public health*. 2020;17(11):3782.
14. Tinkov AA, Filippini T, Ajsuvakova OP, Skalnaya MG, Aaseth J, Bjørklund G, et al. Cadmium and atherosclerosis: A review of toxicological mechanisms and a meta-analysis of epidemiologic studies. *Environmental research*. 2018; 162:240-60.
15. Satarug S. Dietary cadmium intake and its effects on kidneys. *Toxics*. 2018;6(1):15.
16. Yuan W, Yang N, Li X. Advances in understanding how heavy metal pollution triggers gastric cancer. *BioMed research international*. 2016;2016(1):7825432.
17. Kim HJ, Hann HJ, Hong SN, Kim KH, Ahn IM, Song JY, et al. Incidence and natural course of inflammatory bowel disease in Korea, 2006–2012: a nationwide population-based study. *Inflammatory bowel diseases*. 2015;21(3):623-30.
18. Tinkov AA, Gritsenko VA, Skalnaya MG, Cherkasov SV, Aaseth J, Skalny AV. Gut as a target for cadmium toxicity. *Environmental Pollution*. 2018; 235:429-34.
19. Joly Condet C, Khorsi-Cauet H, Morlière P, Zabijak L, Reygnier J, Bach V, et al. Increased gut permeability and bacterial translocation after chronic chlorpyrifos exposure in rats. *PLoS One*. 2014;9(7): e102217.

20. Earley ZM, Akhtar S, Green SJ, Naqib A, Khan O, Cannon AR, et al. Burn injury alters the intestinal microbiome and increases gut permeability and bacterial translocation. *PloS one*. 2015;10(7): e0129996.
21. Liu JH, Yue T, Luo ZW, Cao J, Yan ZQ, Jin L, et al. *Akkermansia muciniphila* promotes type H vessel formation and bone fracture healing by reducing gut permeability and inflammation. *Disease models & mechanisms*. 2020;13(11): dmm043620.
22. Adegoke AG, Salami AT, Olaleye SB. Cadmium exacerbates acetic acid induced experimental colitis in rats. *Eur Exp Biol*. 2017;7(5):27.
23. Musumeci L, Maugeri A, Cirimi S, Lombardo GE, Russo C, Gangemi S, et al. Citrus fruits and their flavonoids in inflammatory bowel disease: An overview. *Natural Product Research*. 2020;34(1):122-36.
24. Abd-elrahman NM, Farid A, Fararh KM. Hesperidine promotes recovery of ulcerative colitis and inhibit inflammatory responses in acetic acid-treated rat. *Benha Veterinary Medical Journal*. 2019;36(1):133-46.
25. Ige SF, Adeniyi MJ, Olayinka AT, Kehinde IC. Role of dietary maize formulations in the healing of experimental acetic acid induced ulcerative colitis in male rats. *Journal of Physiology Investigation*. 2020;63(4):156-62.
26. Alsharif IA, Fayed HM, Abdel-Rahman RF, Abd-Elsalam RM, Ogaly HA. Miconazole mitigates acetic acid-induced experimental colitis in rats: insight into inflammation, oxidative stress and Keap1/Nrf-2 signaling crosstalk. *Biology*. 2022;11(2):303.
27. Misra HP, Fridovich I. The role of superoxide anion in the autoxidation of epinephrine and a simple assay for superoxide dismutase. *Journal of Biological chemistry*. 1972;247(10):3170-5.
28. Sinha AK. Colorimetric assay of catalase. *Analytical biochemistry*. 1972;47(2):389-94.
29. Ansari MN, Rehman NU, Karim A, Soliman GA, Ganaie MA, Raish M, et al. Role of oxidative stress and inflammatory cytokines (TNF- α and IL-6) in acetic acid-induced ulcerative colitis in rats: ameliorated by *otostegia fruticosa*. *Life*. 2021;11(3):195.

30. Otu-Boakye SA, Yeboah KO, Boakye-Gyasi E, Oppong-Kyekyeku J, Okyere PD, Osafo N. Acetic acid-induced colitis modulating potential of total crude alkaloidal extract of *Picralima nitida* seeds in rats. *Immunity, Inflammation and Disease*. 2023;11(5): e855.
31. Nagy A, Xu Y, Bauchan GR, Shelton DR, Nou X. Aggregative adherence fimbriae I (AAF/I) mediate colonization of fresh produce and abiotic surface by Shiga toxigenic enteroaggregative *Escherichia coli* O104: H4. *International journal of food microbiology*. 2016; 229:44-51.
32. Li H, Chen X, Liu J, Chen M, Huang M, Huang G, et al. Ethanol extract of *Centella asiatica* alleviated dextran sulfate sodium-induced colitis: Restoration on mucosa barrier and gut microbiota homeostasis. *Journal of Ethnopharmacology*. 2021; 267:113445.
33. Yanni AE, Mitropoulou G, Prapa I, Agrogiannis G, Kostomitsopoulos N, Bezirtzoglou E, et al. Functional modulation of gut microbiota in diabetic rats following dietary intervention with pistachio nuts (*Pistacia vera* L.). *Metabolism open*. 2020; 7:100040.
34. Appleyard CB, Wallace JL. Reactivation of hapten-induced colitis and its prevention by anti-inflammatory drugs. *American Journal of Physiology-Gastrointestinal and Liver Physiology*. 1995;269(1): G119-25.
35. Lee H, Woo M, Kim M, Noh JS, Song YO. Antioxidative and cholesterol-lowering effects of lemon essential oil in hypercholesterolemia-induced rabbits. *Preventive nutrition and food science*. 2018;23(1):8.
36. Ramful-Baboolall, D., Neergheen-Bhujun, V., and Bahorun, T. (2014). Prophylactic propensity of citrus phytochemicals: Action and mechanisms. *Mol. Phylogeny Antioxid. Prop. Med. Uses*, 95, 95-98.
37. Wu P, Tang X, Jian R, Li J, Lin M, Dai H, Wang K, Sheng Z, Chen B, Xu X, Li C. Chemical composition, antimicrobial and insecticidal activities of essential oils of discarded perfume lemon and leaves (*Citrus Limon* (L.) Burm. F.) as possible sources of functional botanical agents. *Frontiers in Chemistry*. 2021; 9:679116.
38. Tavazzi B, Amorini AM, Fazzina G, Di Pierro D, Tuttobene M, Giardina B, et al. Oxidative stress induces impairment of human erythrocyte energy metabolism through

the oxygen radical-mediated direct activation of AMP-deaminase. *Journal of Biological Chemistry*. 2001;276(51):48083-92.

39. Rana SV, Sharma S, Prasad KK, Sinha SK, Singh K. Role of oxidative stress & antioxidant defence in ulcerative colitis patients from north India. *Indian Journal of Medical Research*. 2014;139(4):568-71.
40. Rao SS, Patel UD, Makwana CN, Ladumor VC, Patel HB, Modi CM. Effect of quercetin and curcumin in rats sub-acutely exposed to cadmium chloride: haemato-biochemical changes, oxidative stress parameters and histopathological changes in intestine, liver and kidney of rats. *J. Phytomedicine*. 2021;10(5):399-408.
41. Parhiz H, Roohbakhsh A, Soltani F, Rezaee R, Iranshahi M. Antioxidant and anti-inflammatory properties of the citrus flavonoids' hesperidin and hesperetin: an updated review of their molecular mechanisms and experimental models. *Phytotherapy research*. 2015;(3):323-31.
42. Jaiswal SK, Gupta VK, Siddiqi NJ, Pandey RS, Sharma B. Hepatoprotective effect of Citrus limon fruit extract against carbofuran induced toxicity in Wistar rats. *Chinese Journal of Biology*. 2015;2015(1):686071.
43. Chatterjee A, Dasgupta S, Sidransky D. Mitochondrial subversion in cancer. *Cancer prevention research*. 2011;4(5):638-54.
44. Marrocco I, Altieri F, Peluso I. Measurement and clinical significance of biomarkers of oxidative stress in humans. *Oxidative medicine and cellular longevity*. 2017;2017(1):6501046.
45. Farjad E, Momeni HR. Silymarin ameliorates oxidative stress and enhances antioxidant defense system capacity in cadmium-treated mice. *Cell Journal (Yakhteh)*. 2018;20(3):422.
46. Naini MA, Zargari-Samadnejad A, Mehrvarz S, Tanideh R, Ghorbani M, Dehghanian A, Hasanzarrini M, Banaee F, Koohi-Hosseiniabadi O, Tanideh N, Iraj A. Anti-inflammatory, antioxidant, and healing-promoting effects of Aloe vera extract in the experimental colitis in rats. *Evidence-Based Complementary and Alternative Medicine*. 2021;2021(1):9945244.

47. Ahmed T, Masood HA, Noman M, Al-Huqail AA, Alghanem SM, Khan MM, et al. Biogenic silicon nanoparticles mitigate cadmium (Cd) toxicity in rapeseed (*Brassica napus* L.) by modulating the cellular oxidative stress metabolism and reducing Cd translocation. *Journal of Hazardous Materials*. 2023; 459:132070.
48. Zhao C, Zhang Z, Nie D, Li Y. Protective effect of lemon essential oil and its major active component, D-limonene, on intestinal injury and inflammation of *E. coli*-challenged mice. *Frontiers in Nutrition*. 2022; 9:843096.
49. Klimek-Szczykutowicz M, Szopa A, and Ekiert H. *Citrus limon* (Lemon) phenomenon—a review of the chemistry, pharmacological properties, applications in the modern pharmaceutical, food, and cosmetics industries, and biotechnological studies. *Plants*. 2020;9(1), 119.
50. Zhang L, Cheng X, Gao Y, Bao J, Guan H, Lu R, et al. Induction of ROS-independent DNA damage by curcumin leads to G2/M cell cycle arrest and apoptosis in human papillary thyroid carcinoma BCPAP cells. *Food & function*. 2016;7(1):315-25.
51. Zhou X, Miao J, Zhang B, Duan M, Li J, Yue J, et al. Cuticular wax metabolism of lemon (*Citrus limon* Burm. f. Eureka) fruit in response to ethylene and gibberellic acid treatment. *Postharvest Biology and Technology*. 2022; 194:112062.
52. Kaur A, Goggolidou P. Ulcerative colitis: understanding its cellular pathology could provide insights into novel therapies. *Journal of inflammation*. 2020; 17:1-8.
53. Barbara G, Barbaro MR, Fuschi D, Palombo M, Falangone F, Cremon C, et al. Inflammatory and microbiota-related regulation of the intestinal epithelial barrier. *Frontiers in nutrition*. 2021; 8:718356.
54. Amorim JL, Simas DL, Pinheiro MM, Moreno DS, Alviano CS, da Silva AJ, et al. Anti-inflammatory properties and chemical characterization of the essential oils of four citrus species. *PloS one*. 2016;11(4): e0153643.
55. Zhou Z, Yan Y, Li H, Feng Y, Huang C, Fan S. Nomilin and its analogues in citrus fruits: a review of its health promotion effects and potential application in medicine. *Molecules*. 2022;28(1):269.

56. Nair AR, DeGheselle O, Smeets K, Van Kerkhove E, Cuypers A. Cadmium-induced pathologies: where is the oxidative balance lost (or not)? *International journal of molecular sciences*. 2013;14(3):6116-43.
57. Schaefer HR, Dennis S, Fitzpatrick S. Cadmium: Mitigation strategies to reduce dietary exposure. *Journal of food science*. 2020;85(2):260-7.
58. Antunes CV, Hallack Neto AE, Nascimento CR, Chebli LA, Moutinho IL, Pinheiro BD, et al. Anemia in inflammatory bowel disease outpatients: prevalence, risk factors, and etiology. *BioMed research international*. 2015;2015(1):728925.
59. Riaz A, Khan RA, Mirza T, Mustansir T, Ahmed M. In vitro/in vivo effect of *Citrus limon* (L. Burm. f.) juice on blood parameters, coagulation and anticoagulation factors in rabbits. *Pakistan journal of pharmaceutical sciences*. 2014;27(4) 907-915.
60. Miles EA, Calder PC. Effects of citrus fruit juices and their bioactive components on inflammation and immunity: a narrative review. *Frontiers in immunology*. 2021; 12:712608.
61. Chapuy L, Bsat M, Mehta H, Rubio M, Wakahara K, Van VQ, et al. Basophils increase in Crohn disease and ulcerative colitis and favor mesenteric lymph node memory TH17/TH1 response. *Journal of Allergy and Clinical Immunology*. 2014;134(4):978-81.
62. Zielińska-Przyjemska M, Ignatowicz E. Citrus fruit flavonoids influence on neutrophil apoptosis and oxidative metabolism. *Phytotherapy Research: An International Journal Devoted to Pharmacological and Toxicological Evaluation of Natural Product Derivatives*. 2008;22(12):1557-62.
63. Ávila G, De Leonardis D, Grilli G, Lecchi C, Ceciliani F. Anti-inflammatory activity of citrus pectin on chicken monocytes' immune response. *Veterinary Immunology and Immunopathology*. 2021; 237:110269.
64. Wexler AG, Goodman AL. An insider's perspective: Bacteroides as a window into the microbiome. *Nature microbiology*. 2017;2(5):1-1.

65. Amon P, Sanderson I. What is the microbiome? *Archives of disease in childhood-Education and Practice*. 2017;102(5):257-260.
66. Bidell MR, Hobbs AL, Lodise TP. Gut microbiome health and dysbiosis: A clinical primer. *Pharmacotherapy: The Journal of Human Pharmacology and Drug Therapy*. 2022;42(11):849-57.
67. Luciardi MC, Blázquez MA, Alberto MR, Cartagena E, Arena ME. Lemon oils attenuate the pathogenicity of *Pseudomonas aeruginosa* by quorum sensing inhibition. *Molecules*. 2021;26(10):2863.
68. Hoff RT, Patel A, Shapiro A. *Pseudomonas aeruginosa*: An Uncommon Cause of Antibiotic-Associated Diarrhea in an Immunocompetent Ambulatory Adult. *Case reports in gastrointestinal medicine*. 2020;2020(1):6261748.
69. d'Alessio PA, Ostan R, Bisson JF, Schulzke JD, Ursini MV, Béné MC. Oral administration of d-limonene controls inflammation in rat colitis and displays anti-inflammatory properties as diet supplementation in humans. *Life sciences*. 2013;92(24-26):1151-6.
70. Otang WM, Afolayan AJ. Antimicrobial and antioxidant efficacy of *Citrus limon* L. peel extracts used for skin diseases by Xhosa tribe of Amathole District, Eastern Cape, South Africa. *South African Journal of Botany*. 2016; 102:46-9.
71. Piewngam P, Otto M. Staphylococcus aureus colonisation and strategies for decolonisation. *The Lancet Microbe*. 2024; 5(6): e606 – e618
72. Sost MM, Ahles S, Verhoeven J, Verbruggen S, Stevens Y, Venema K. A citrus fruit extract high in polyphenols beneficially modulates the gut microbiota of healthy human volunteers in a validated in vitro model of the colon. *Nutrients*. 2021;13(11):3915.
73. Cabral V, Oliveira RA, Correia MB, Pedro MF, Ubeda C, Xavier KB. Gut protective *Klebsiella* species promotes microbiota recovery and pathobiont clearance while preventing inflammation. *bioRxiv*. 2023:2023-11.
74. Hameed I, Masoodi SR, Mir SA, Nabi M, Ghazanfar K, Ganai BA. Type 2 diabetes mellitus: from a metabolic disorder to an inflammatory condition. *World journal of diabetes*. 2015;6(4):598.

75. Samanta S, Banerjee J, Ahmed R, Dash SK. Potential Benefits of Bioactive Functional Components of Citrus Fruits for Health Promotion and Disease Prevention. *InRecent Advances in Citrus Fruits*. Cham: Springer International Publishing. 2023:451-499.
76. González-Molina E, Domínguez-Perles R, Moreno DA, García-Viguera C. Natural bioactive compounds of *Citrus limon* for food and health. *Journal of pharmaceutical and biomedical analysis*. 2010;51(2):327-

UNDER PEER REVIEW