

## **Oral manifestation of von Recklinghausen's disease: A Case Reports of two cases**

### **Abstract:**

Background: Von Recklinghausen's disease also termed as "Neurofibromatosis type 1 (NF1)" is an autosomal dominant inherited disorder, characterized by various abnormalities such as neurofibroma, mainly in the skin and nerves. The classic manifestations include neurofibroma, café-au-lait macules, Iris Lisch nodules, optic glioma, axillary or inguinal freckling, and osseous dysplasia, neurological or cognitive impairment, scoliosis and oral and maxillofacial abnormalities. Various oral manifestations include soft tissues neurofibroma, dental abnormalities and osseous abnormalities. Case presentation: We are reporting two cases of von Recklinghausen's disease with predominant osseous abnormalities in one case while soft tissue neurofibroma on another case. Conclusion: Oral manifestations are not uncommon with NF1, including soft tissue, dental and osseous abnormalities. Oral specialist must be aware regarding the osseous and dental manifestation so that special attention and care must be provided to avoid further loss of dentition

**Keywords:** Recklinghausen's disease, autosomal, neurofibroma, optic glioma

### **Introduction**

Neurofibroma is a benign tumour of nerve tissue, derived from cells that constitute the nerve sheath. Neurofibroma can be seen either as solitary lesion or as a part of generalized syndrome of "Neurofibromatosis".<sup>1</sup> Neurofibromatosis mostly affects nervous system and skin thus also consider as a type of "Neurocutaneous disorder".<sup>2</sup> The Neurofibromatosis mainly includes three subtypes i.e. Neurofibromatosis type 1(NF1) or Von Recklinghausen's disease, Neurofibromatosis type 2 (NF2) and Schwannomatosis (SWN). Neurofibromatosis type 1 accounts for maximum number (90%) of all cases of neurofibromatosis. Difference between major subtypes (type 1 and type 2) is summarized in table 1.<sup>3,4,5</sup>

Von Recklinghausen's disease or Neurofibromatosis type 1 (NF1) is an autosomal dominant disease, caused by the mutation of long arm of chromosome 17 (17q11.2) affecting tumor suppressor gene NF1.<sup>1,2</sup>The common clinical features of NF1 are Cafe-au-lait macules, Neurofibromas, Axillary/inguinal freckling, Optic glioma, Lisch nodules,

osseous dysplasia (Sphenoid dysplasia, thinning of long bone cortex with or without pseudoarthrosis, decreased bone mineral density and scoliosis), neurologic or cognitive impairment, Seizures, Hypertension, Malignant Peripheral Nerve Sheath Tumor , Other soft tissue sarcomas (Rhabdomyosarcoma, Gastrointestinal stromal tumor, glomus tumor), Other glial and hamartomatous lesions of the CNS and Pheochromocytoma.<sup>6</sup> Table 2 describes the clinical criteria suggested by “The National Institutes of Health Consensus Development Conference 1988”.<sup>7</sup>

Previous studies reported oral manifestation, either clinical or radiological in 72%<sup>8</sup> and 92%<sup>9</sup>. The oral findings in NF 1 are not uncommon thus the oral physician must be aware and have sufficient knowledge regarding the early diagnosis of both clinical and radiological manifestations of this entity. We are reporting two cases of von Recklinghausen’s disease with predominant osseous abnormalities in one case while soft tissue neurofibroma on another case.

### **Case 1 Presentation:**

A 13 year old girl reported with missing right upper and lower back tooth region. She was previously diagnosed with neurofibromatosis type 1. **The diagnostic features were congenital facial plexiform neurofibroma (previously confirmed with biopsy), scoliosis (Figure 1b), Lisch nodules (Figure 1c), café-au-lait macules (Figure 1d), axillary and inguinal freckling (Crowe’s sign) and positive family history of her father with the same problem.** Extraoral examination revealed diffuse swelling on the right side of face, predominantly affecting lower 3<sup>rd</sup> involving upper and lower eyelid, upper lip and chin with a “bag-of-worms” consistency (Figure 1a). Intraorally, large flaccid nodular swelling was detected in relation to right posterior buccal mucosa extending to vestibular region in relation to missing 46,47 region, measuring about 3.5 x2cm in size (Figure 2a). Right buccal mucosa also presents with generalized flaccid rubbery swelling. Enlarged fungiform papillae with blackish pigmentations were identified mainly on tip of tongue and few on the lateral border of the on right side (Figure 2b). On hard tissue examination retained 55, missing 15, 16, 17, 46, 47, altered shape 45 and slight midline shifting toward right side was identified.

Based on clinical characteristics, Provisional diagnosis of neurofibroma was given for intraoral lesion. A panoramic radiograph revealed osseous changes in right mandible such as irregular, depressed inferior border of body of mandible, enlarged mandibular foramen, angulated condylar process, elongation and narrowing of the condylar and coronoid processes, deepening of the mandibular notch and dental changes like thinned enamel in relation to upper and lower anterior, retained 55, impacted teeth (15, 16, 17, 46, and 47), tooth bud 18, 28, 38 and 48 (Figure 2c). Periapical radiolucency with radiopaque lining was associated with 33, 34, suspecting periapical cemental dysplasia as teeth were vital in vitality testing without any clinical sign of odontogenic issues (Figure 2c).

### **Case 2 Presentation:**

A 45 year old male reported with growth on right side of tongue. Similar to case 1, patient was previously diagnosed with neurofibromatosis type 1. The diagnostic features were multiple neurofibroma on entire body, café-au-lait macules, axillary and inguinal freckling (Crowe's sign), Lisch nodules, positive family history. On examination, multiple café-au-lait spots were observed, with largest patch involved complete lower back (Figure 3a). Multiple numerous soft cutaneous nodules were appreciated on entire body, of variable sizes. Cutaneous nodules were most numerous on trunk and limbs, ranging from few millimeters to several centimeters in diameter (cutaneous neurofibromas) (Figure 3a). Some of the cutaneous nodules were pedunculated. Intraoral examination reveals a nodular growth on right lateral border of tongue measuring about 2x 2.5cm along with a lobulated lesion anterior to the nodular growth, measuring 3.5x 2.5cm in greatest dimension (Figure 3b). The mucosa over both lesions was smooth with pinkish-red coloration. On palpation, the both lesions were soft and nontender. Enlarged fungiform papillae were also found. Based on clinical characteristics, Provisional diagnosis of neurofibroma was given for intraoral lesion. Incisional biopsy confirms the diagnosis of neurofibroma. Panoramic radiograph does not reveal any significant osseous changes.

### **Discussion**

A study was performed to evaluate clinical and radiological manifestations in 24 patients with neurofibromatosis. The prevalence of oral and radiographic findings was found to be

72%.<sup>8</sup> Another study was performed to evaluate clinical and radiological manifestations of the disease in the head and neck region including 38 patients with neurofibromatosis. The study showed at least one intraoral or radiographic sign in 92 % of the sample.<sup>9</sup>

Previous studies concluded the enlarged fungiform papillae as the most common clinical intraoral finding while enlarged mandibular foramen and canal as the most common radiological manifestation.<sup>8, 9</sup> Similar to these studies, our both cases were presented with enlarged fungiform papilla and enlarged mandibular canal in first case..

A study investigated the prevalence of oral manifestations such as dental caries, dental abnormalities, periodontal health, neurofibromas, malocclusions, and enamel defects in a group of children affected by neurofibromatosis type 1. The study group (NF1 Group) showed significantly high prevalence of neurofibromas, enamel defects, shape anomalies, and poor oral hygiene. The study also concluded that the children with NF1 require special care and attention in relation to dental problems.<sup>10</sup> Similar to this study, both case presented with neurofibroma while first case was with tooth anomalies such as thinned enamel mainly on upper and lower anterior, retained 55 and impacted teeth (15, 16, 17, 46, and 47).

Neurofibroma is a benign tumour of nerve tissue, derived from cells that constitute the nerve sheath and considered as an important characteristic of neurofibromatosis.<sup>1</sup> It may present as single nodules, multiple or plexiform neurofibroma with common sites includes the tongue (most common), buccal mucosa, labial mucosa, alveolar crest, palate, floor of the mouth, paranasal sinuses, nasopharynx, larynx, and salivary glands.<sup>1</sup> Gingiva usually represents an uncommon site.<sup>11,12</sup> Proximity to intraoral neurofibroma may involve compression of cranial nerves such as trigeminal, facial glossopharyngeal and hypoglossal cranial nerve causing difficulties in phonation, chewing, swallowing, and facial expression.<sup>12</sup> Our first case had neurofibroma of buccal mucosa while second case had neurofibroma of tongue. Although asymmetry was present along with slight dental midline shifting towards right side, but both of our cases did not have any sign of compression affecting sensory or motor function of any nerves.

Maxillofacial Osseous abnormalities (radiographic findings) have been detected as high as 72% in one of the previous study. Enlarged mandibular canal (34%) and enlarged mandibular foramen (29%) were predominant radiographic findings.<sup>9</sup> Other features which

may present are hypoplasia of condyle and coronoid process, enlarged mandibular foramen, flat or missing Gonial angle, increased coronoid notch, orbital and sphenoidal wings dysplasia, Dysplasia of maxillary sinus etc. <sup>8, 9,13</sup>The relationship between maxillofacial osseous malformations and neurofibromas may be due to the presence of sizably voluminous plexiform neurofibroma causing unilateral jaw malformations. It has been suggested that the osseous changes are caused by various factors such as a) Tumor invasion of the skeletal muscles, b) Pressure caused by the growing tumor, c) Tumor cells stimulating osteoclasts, d) Embryological effects of the trigeminal nerve acting on mandibular development, e) As manifestations of mesodermal dysplasia not directly related to neurofibromatous tissue.<sup>13,14</sup> Similar to previous studies, our first caserevealed irregular and depressed inferior border of right body of mandible, enlarged mandibular foramen, angulated condylar process, elongation and narrowing of the condylar and coronoid processes, deepening of the mandibular notch.

Neurofibromatosis type 1 (NF1) represents a major risk factor for development of malignancy, particularly malignant peripheral nerve sheath tumors, optic gliomas, other gliomas, lymphoma, leukemias, brain cancer, and breast cancer.<sup>15</sup>Regarding oral malignancy, Neville BW reported two cases of oral neurofibrosarcoma associated with NF1.<sup>16</sup> Although Oral malignancy is very rare but early diagnosis is mandatory in these cases to rule out any possibility of malignant transformation. The fast growing neurofibromas with pain must be suspected for malignant transformation and thus a biopsy must be performed.

Usually, Magnetic resonance imaging (MRI) is required to diagnose optic gliomas and other cutaneous tumors. NF1 suspects with vascular abnormalities may require MRI angiography or CT angiography. Osseous abnormalities can be imaged with conventional plane radiography or advanced radiography like CT. Positron emission tomography must be advised to check the malignant transformation of tumors in NF1 patients.<sup>17</sup> Advanced MRI imaging sequences such as Diffusion-weighted imaging (DWI) with quantitative apparent diffusion coefficient (ADC) mapping, and metabolic imaging techniques (MR spectroscopy and positron emission testing) have been discussed in few literatures.<sup>18</sup>

## **Conclusion**

Oral manifestations are not uncommon with NF1, including soft tissue, dental and osseous abnormalities. These changes can be easily detected during childhood and adolescence. Oral specialist must be aware regarding the osseous and dental manifestation so that special attention and care must be provided to avoid further loss of dentition. Patient must be motivated to maintain good oral hygiene. Regarding soft tissue, patient must be regularly inspected completely to avoid any chances for malignant transformation. Not only oral examination, patient must be examined completely as malignancy associated with NF1 can be diagnosed at early stages.

### **Consent**

As per international standards or university standards, patient(s) and parental (Minor patients) written consent has been collected and preserved by the author(s).

### **Disclaimer (Artificial intelligence)**

Option 1:

Author(s) hereby declare that NO generative AI technologies such as Large Language Models (ChatGPT, COPILOT, etc.) and text-to-image generators have been used during the writing or editing of this manuscript.

### References

1. Shivhare P, Parihar A. Benign and Malignant Non-odontogenic tumours. In: Shivhare P, Parihar A, editors. Textbook of Oral Medicine and Radiology. 2nd ed. Hyderabad: Paras Publisher; 2021. p. 781-802.
2. Kioutchoukova I, Foster D, Thakkar R, Ciesla C, Cabassa JS, et al. Neurocutaneous Diseases: Diagnosis, Management, and Treatment. J Clin Med. 2024;13(6):1648.
3. Ardizzone A, Capra AP, Campolo M, Filippone A, Esposito E, Briuglia S. Neurofibromatosis: New Clinical Challenges in the Era of COVID-19. Biomedicines. 2022;10(5):940.

4. Thota E, Veeravalli JJ, Manchala SK, Lakkepuram BP, Kodapaneni J, Chen YW, Wang LT, Ma KS. Age-dependent oral manifestations of neurofibromatosis type 1: a case-control study. *Orphanet J Rare Dis.* 2022;17(1):93
5. Welch MC, Huppmann AR. Educational Case: Peripheral Nerve Sheath Tumors. *AcadPathol.* 2019;6:2374289519857201.
6. Thota E, Veeravalli JJ, ManchalaSK, LakkepuramBP, KodapaneniJ, Chen YW et al. Age-dependent oral manifestations of neurofibromatosis type 1: a case–control study. *Orphanet J Rare Dis.* 2022;17 (93):1-10
7. Gutmann DH, Aylsworth A, Carey JC, Korf B, Marks J, Pyeritz RE et al. The diagnostic evaluation and multidisciplinary management of neurofibromatosis 1 and neurofibromatosis 2. *JAMA.* 1997;278:51-57.
8. Shapiro SD, Abramovitch K, Van Dis ML, Skoczylas LJ, Langlais RP, Jorgenson RJ, et al. Neurofibromatosis: oral and radiographic manifestations. *Oral Surg Oral Med Oral Pathol.* 1984;58(4):493-8.
9. D'Ambrosio JA, Langlais RP, Young RS. Jaw and skull changes in neurofibromatosis. *Oral Surg Oral Med Oral Pathol.* 1988;66(3):391-6.
10. Santoro R, Santoro C, Loffredo F, Romano A, Perrotta S et al. Oral Clinical Manifestations of Neurofibromatosis Type 1 in Children and Adolescents. *Appl. Sci.* 2020;10(4687):1-9.
11. Wotjiuk F, Hyon I, Dajeau-Trutaud S, Badran Z, Prud'homme T. Dental Management of Neurofibromatosis Type 1: A Case Report and Literature Review. *Int J Clin Pediatr Dent.* 2019;12(6):577-581.

12. Alves CS, Santana LAM, Felix FA, Ayres LGC, Silva ER, Takeshita WM. Atypical oral features of patient with neurofibromatosis type 1: case report. J Bras Patol Med Lab. 2021; 57: 1-5
13. Cunha KS, Rozza-de-Menezes RE, Andrade RM, Almeida L, Janini M, Geller M. Oral manifestations of neurofibromatosis type 1 in children with facial plexiform neurofibroma: report of three cases. J Clin Pediatr Dent. 2015;39(2):168-71
14. Deng L, Wang Y, Xiang X, Chen C, Bone absorption and deformity in mandible as initial symptom and manifestation of neurofibromatosis type 1: A case report and literature review, Oral Oncology Reports (2024), doi: <https://doi.org/10.1016/j.oor.2023.100132>.
15. Bergqvist C, Hemery F, Jannic A, Ferkal S, Wolkenstein P. Lymphoproliferative malignancies in patients with neurofibromatosis 1. Orphanet J Rare Dis. 2021;16(1):230.
16. Neville BW, Hann J, Narang R, Garen P. Oral neurofibrosarcoma associated with neurofibromatosis type I. Oral Surg Oral Med Oral Pathol. 1991;72(4):456-61.
17. Figatowska MB. A mini review on neurofibromatosis type 1 from the radiological point of view. J Rare Dis Res Treat. 2017; 2(6): 45-49.
18. Ahlawat S, Blakeley JO, Langmead S, Belzberg AJ, Fayad LM. Current status and recommendations for imaging in neurofibromatosis type 1, neurofibromatosis type 2, and schwannomatosis. Skeletal Radiol. 2020 ;49(2):199-219.

**Table 1- Difference between neurofibromatosis type 1 and 2**

	NF 1	NF 2
<b>Introduction</b>	Neurofibromatosis type 1 (NF1) is a genetic condition that causes changes in skin pigment and tumors on	Neurofibromatosis type 2 (NF2) is a genetic disorder characterized by the development of multiple tumors

	nerve tissue	involving the central nervous system (CNS).
<b>Mode of inheritance</b>	Autosomal dominant	Autosomal dominant
<b>Frequency</b>	1 in 3000 (90% of neurofibromatosis)	1 in 40 000-50 000 (10% of neurofibromatosis)
<b>Mutation</b>	Mutation in NF 1 gene located at chromosome 17q11.2	Mutation in NF 2 gene located at chromosome 22q12
<b>Protein product affected</b>	Neurofibromin	Merlin
<b>Predominant clinical features</b>	Cafe-au-lait macules Neurofibromas Axillary/inguinal freckling Optic glioma Lisch nodules Distinctive bone lesions Family history of NF1 in a first-degree relative	Vestibular schwannomas Meningiomas Spinal tumors Neuropathies Eye involvement- Cataracts, Retinal hamartoma,
<b>Other features</b>	<ul style="list-style-type: none"> <li>• Cognitive and learning deficits</li> <li>• Seizures</li> <li>• Hypertension</li> <li>• Malignant Peripheral Nerve Sheath Tumor</li> <li>• Other soft tissue sarcomas (Rhabdomyosarcoma, Gastrointestinal stromal tumor, glomus tumor)</li> <li>• Other glial and hamartomatous lesions of the CNS</li> <li>• Pheochromocytoma</li> </ul>	Cutaneous neurofibroma-less prominent Café au lait spots-few
<b>CNS lesions</b>	15-20%	100%
<b>Oral manifestation</b>	Common (upto 92%)	Rare

**Table 2. Diagnostic Criteria for Neurofibromatosis Type 1 (NF1)**

1)	6 or more cafe au lait macules (>5 mm in greatest dimension for prepubertal persons and >15 mm in greatest dimension for post pubertal persons)
2)	2 or more neurofibromas (any type) or At least 1 plexiform neurofibroma
3)	Axillary or inguinal freckles
4)	Optic glioma
5)	2 or more Lisch nodules
6)	Distinctive bone lesion such as Sphenoid dysplasia, thinning of long bone cortex with or without pseudoarthrosis.
7)	First-degree relative (parent, sibling or offspring) with a diagnosis of NF1
<b>A diagnosis of NF1 can be made in an individual with 2 or more of the above features</b>	

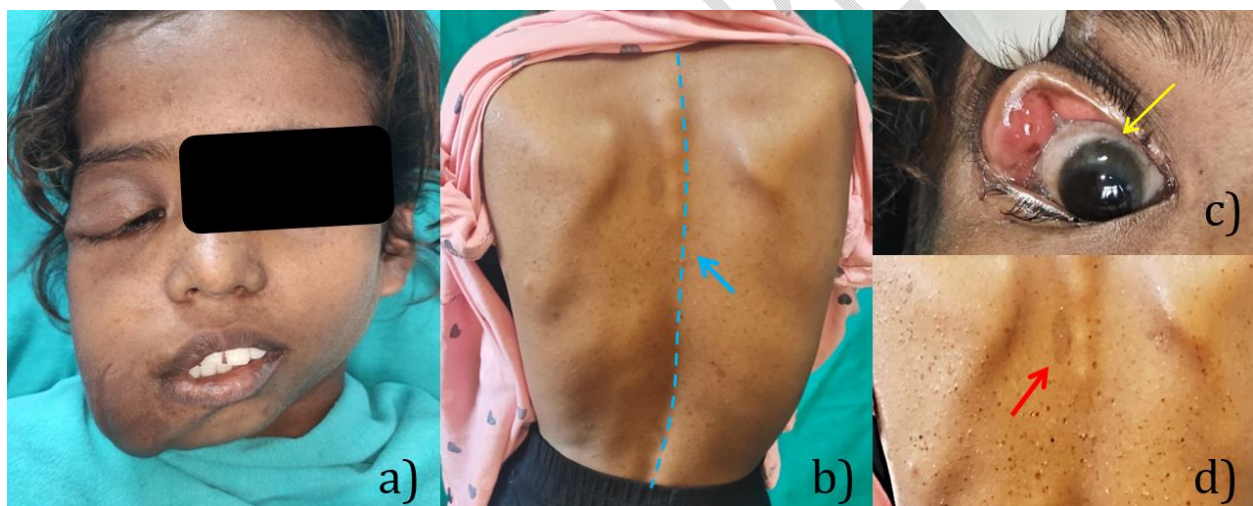


Figure 1: Case 1- a) Facial plexiform neurofibroma on the right side of face predominantly affecting lower 3<sup>rd</sup> involving upper and lower eyelid, upper lip and chin b) Scoliosis c) Lisch nodules d) Cafe au lait macules

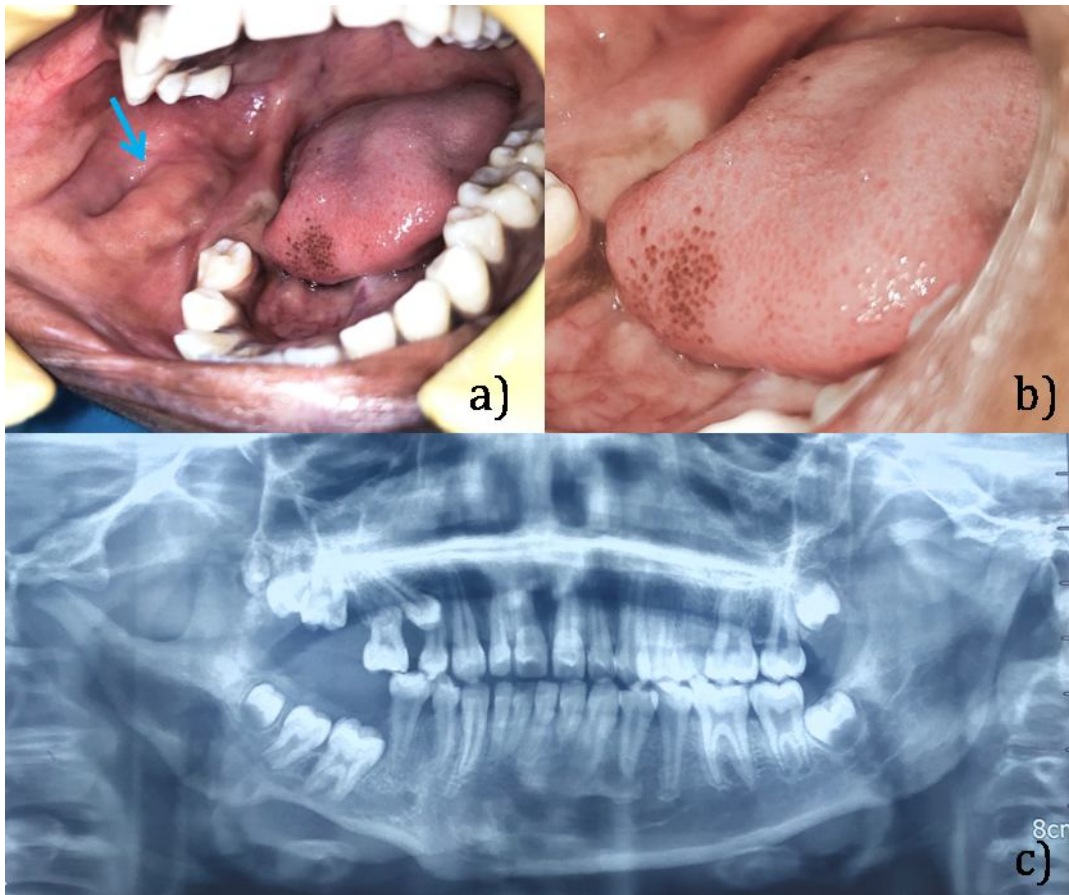


Figure 2- Case 1- a) Intraorally; large flaccid nodular swelling was detected in relation to right posterior buccal mucosa b) Enlarged fungiform papillae with blackish pigmentations with retained 55, missing 15, 16, 17, 46, 47, altered shape 45. c) A panoramic radiograph revealed osseous changes in right mandible such as irregular, depressed inferior border of body of mandible, enlarged mandibular foramen, angulated condylar process, elongation and narrowing of the condylar and coronoid processes, deepening of the mandibular notch and dental changes like thinned enamel in relation to upper and lower anterior, retained 55, impacted teeth(15, 16, 17, 46,and47), tooth bud 18, 28, 38 and 48.Periapical radiolucency with radiopaque lining was associated with 33,34, suspecting periapical cemental dysplasia as teeth were vital in vitality testing without any clinical sign of odontogenic issues.

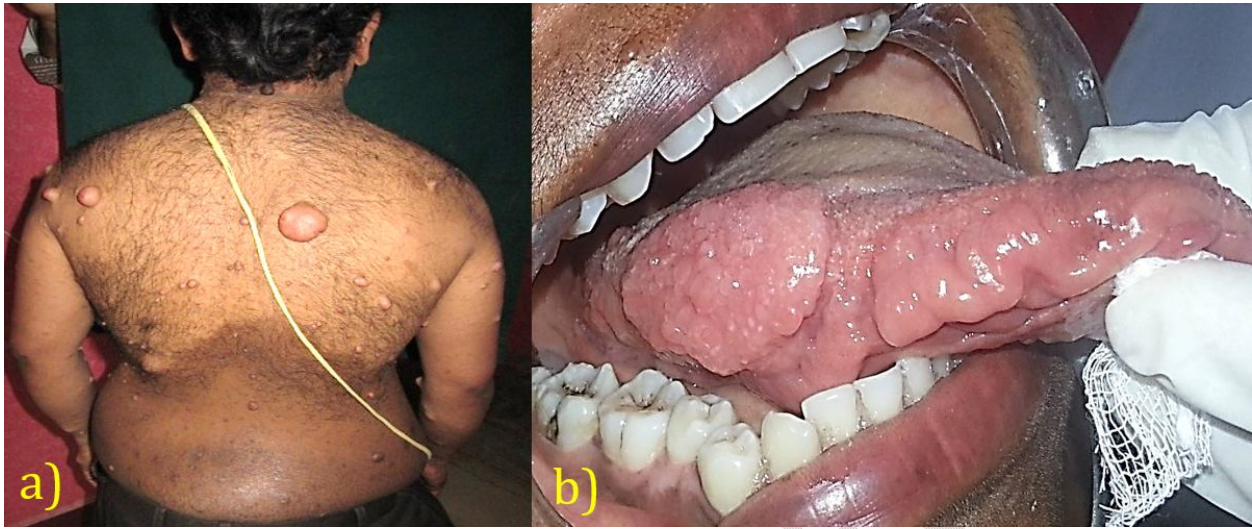


Figure 3- Case 2- Café-au-lait spots were observed, with largest patch involved complete lower back. Multiple numerous soft cutaneous nodules were identified on entire body, of variable sizes, most numerous on trunk and limbs, ranging from few millimeters to several centimeters in diameter (cutaneous neurofibromas). b) Intraoral examination reveals a nodular growth on right lateral border of tongue along with a lobulated lesion anterior to the nodular growth.