

Co-infection of Newcastle Disease and Avian Colibacillosis in a 4-week-old Broiler Flock in Maiduguri, Nigeria

ABSTRACT

Newcastle disease (ND) and avian colibacillosis (AC) outbreak occurred in a 200-bird commercial broiler flock in Maiduguri, Nigeria. Despite vaccinations, the flock experienced a 60% morbidity and 45% mortality rate. Symptoms observed among the flock included weakness, inappetence, diarrhea, nervous signs, and emaciation. Laboratory tests confirmed ND and AC infections. Haemagglutination and haemagglutination inhibition was used to identify NDV infection while bacteriological culture and identification was used for isolation of *Escherichia coli* (*E. coli*). The outbreak highlights the economic impact of these diseases on the poultry industry in Nigeria. Recommendations include improved biosecurity measures, regular vaccination, and timely treatment of secondary bacterial infections. Public health concerns also arise due to the zoonotic potential of ND. The vaccine failure in this case may be due to break in cold chain due to power outage, antigenic variation or inappropriate handling. Further research is needed to investigate vaccine failures and develop more effective prevention strategies.

Keywords: Newcastle disease; broilers; *Escherichia coli*; economic losses; poultry; zoonosis.

1. INTRODUCTION

Newcastle disease (ND) and avian colibacillosis (AC) are common infections in poultry. The combination of these diseases leads to high treatment costs, increased mortality, and elevated production expenses in the poultry industry (Landman *et al.*, 2017; Yehia *et al.*, 2023). Newcastle disease is caused by a virus of the family Paramyxoviridae. The virus is divided into five different pathotypes: viscerotropic velogenic strain which causes hemorrhagic lesions in the gastrointestinal tract (GIT) of chicken; neurotropic velogenic strain that is responsible for respiratory and nervous signs, and the leading cause of high mortality in birds; mesogenic strain which causes mild respiratory illness and low mortality; as well as lentogenic and asymptomatic enteric strains (Malik *et al.*, 2021). Newcastle disease is highly contagious and is transmitted via aerosol, water, feeds and contact with infected birds. The disease is endemic in Nigeria and the economic losses due to ND in Nigeria was estimated at 1.4 billion Naira (estimate, 10 million Dollars), representing a major economic drain in the poultry industry (Salihu *et al.*, 2013). ND is listed among the notifiable diseases by the World Organization for Animal Health (OIE) (Stear, 2005; Ashraf and

Shah, 2014). Colibacillosis, on the other hand, is a disease syndrome caused by *Escherichia coli* (*E. coli*). It is one of the most common bacterial diseases of birds, often associated with viral coinfection (Nolan *et al.*, 2013; Shehata *et al.*, 2024). Colibacillosis and viral coinfections are difficult to diagnose and treat or manage (Shehata *et al.*, 2024). *E. coli* infection is one of the common causes of high economic bacterial disease of poultry worldwide, with young and immuno-compromised birds the most susceptible (Shehata *et al.*, 2024). The occurrence of ND and AC coinfection is limited. Moreover, both diseases cause significant economic losses in poultry (Solomon *et al.*, 2012). This report discussed the clinical and microbiological characteristics of ND and AC in a four-week-old broiler flock in Maiduguri, Nigeria.

2. CASE PRESENTATION

2.1 Case History

The study was carried out in a poultry farm housing 200 commercial broilers at 4 weeks of age, in Maiduguri, Nigeria. The birds were reported to have been vaccinated against ND using ND LaSota vaccine, Infectious Bursal disease (IBD) using IBD (Gumboro) vaccine and

Marek's disease at day 1, week 2, and week 3 respectively. The case was reported to the University of Maiduguri Veterinary Teaching Hospital on 27th May 2023. The birds were reportedly reared under all-in, all-out system. They were transferred from one pen to another to create room for space because of the increase in the size of the birds, and for new arrivals. The old pen was slightly larger than the current pen. Three days after transfer, flock attendants observed weakness, in appetite, greenish/whitish diarrhea, (Fig. 1) and exhibited nervous signs in some birds. At day 2 of this investigation, 60 out of the 200 birds had died. The mortality rose to 100 on day 3. All the birds showed signs of sickness. The farmer administered a combination of antibiotics, but the mortality rate continued to rise. On physical examination, it was observed that the birds had soiled vents, were emaciated, and some had torticollis with diarrhea while others had diarrhea only. The feathers were roughed with signs of severe dehydration (panting, lethargy, pale wattle and combs). Postmortem lesions observed include congested lungs and trachea (Fig. 2), as

well as pinpoint hemorrhages at the caeca tonsil and small intestine (Fig. 3). The case was tentatively diagnosed as ND based on clinical manifestations, postmortem examination, history and farm visitation.

2.2 Laboratory Investigation

Pulled trachea, cloacal swab and blood samples were collected from affected chickens. Virus transport media (VTM) was used to stock the sample for about 12 hours before processing. The samples were divided into two, one part was transported to the Veterinary Microbiology Laboratory for bacteriological investigation while the remaining parts were transported to Virology Laboratory, University of Maiduguri for serological test. Bacteriological tests that were conducted included Gram's staining, culture, biochemical identification and antimicrobial susceptibility testing (AST). Disc diffusion method was used for the AST. Virology tests conducted include hemagglutination incubation (HI) and Hemagglutination (HA) tests (Fig. 4).



Fig. 1. Soiled vent (A) and greenish feces on the floor (B) in a broiler chicken

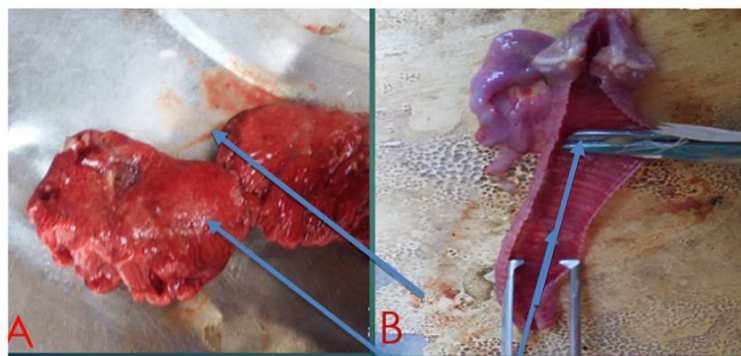


Figure 2: Post-mortem lesions showing congested lungs, and trachea of the affected broiler chicken

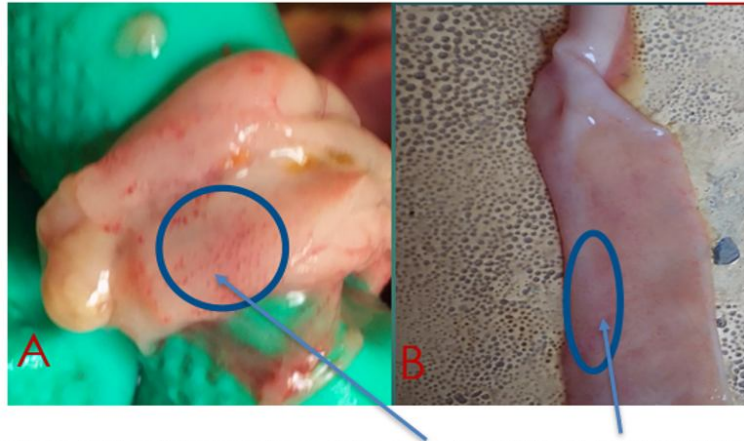


Figure 3: Pinpoint hemorrhages at the caeca tonsil (A) and intestine (B) in the affected



Please provide this figure

Fig. 4. Haemagglutination (A) and haemagglutination inhibition (B) titre plates

Table 1. Treatment plan

Drugs	Composition	Dose (gm/4litres)	Route of administration	Duration
Careceryl®	Streptomycin sulphate 3500mg Colistin sulphate 210000000 IU VitaminA 500000IU VitaminD3 200000IU VitaminE 200mg VitaminB1 200mg Panthothenate 1000mg VitaminK 200mg VitaminB6 200mg VitaminB2 400mg VitaminB12 1mg VitaminC 2000mg Inositol 100mg	5	Oral	X5/7
Glucose		10	Oral	X5/7

2.3 Treatment/Clinical Managenet

The flock was treated by using Careceryl® (antibiotics, and multivitamins combinations) and glucose for five days (Table 1). The birds showed remarkable improvement after day 3 of the treatment. The farmer was advised to improve nutrition and management, adequate biosecurity measures, and to ensure that vaccines are source from reputable suppliers.

3. RESULTS AND DISCUSSION

In this report, we identified ND virus by hemagglutination and, hemagglutination inhibition (HA, HI) tests and *E coli* by bacteriological culture, Gram's staining and biochemical tests. Based on epidemiological investigation, the morbidity rate at the farm was 60% (120/200), while the mortality rate was 45.0% (90/200). The results showed that the epidemiology of ND in this case was comparable to the average rate in commercial poultry breeds

in Nigeria (Lawal *et al.*, 2015). Previous research reported a 100% mortality in unvaccinated chickens (Abdul *et al.*, 2006). In vaccinated flocks, Newcastle disease typically causes minimal illness and few deaths (Dimitrov *et al.*, 2017). However, the current outbreak has seen an unusual surge in both illness and mortality rates among vaccinated birds. This may be due to a secondary infection with *E. coli*, which can weaken the birds' immune response and make them more susceptible to the virus.

Close habitation of the poultry flock with in-contact humans occasioned by housing the birds near the residential areas may be of serious public health concerns. This follows the fact that NDV can cause mild conjunctivitis because of zoonotic transmission through aerosols, contact with mucous membrane and other routes from infected birds to susceptible or immunocompromised humans (Fadiga *et al.*, 2013). Newcastle disease is considered a zoonotic disease, meaning it can be transmitted from animals to humans (UI Rahman *et al.*, 2022).

However, the risk of human infection is very low, and the disease is typically mild in humans (UI Rahman *et al.*, 2022). Newcastle disease virus can cause mild conjunctivitis among immunocompromised patients, particularly poultry handlers who are living with HIV/AIDS.

Newcastle disease virus coinfection with pathogenic *E. coli* may present a severe outcome. The *E. coli* strain isolated in this case was resistant to amoxicillin, ampicillin, and tetracycline (Table 2). The observed resistance in this report may be because of the indiscriminate use of antimicrobials by farmers in Nigeria, and excessive use of antibiotics for fattening and preventive measures. Also, the bacteria may have acquired a resistant gene from the environment through mobile genetic elements, transposons and insertion (Ejeh *et al.*, 2017). Hence, we recommend prompt action against secondary bacterial infection. Also, antimicrobial susceptibility testing is recommended to achieve effective treatment and minimize emergence of resistant strains (Ejeh *et al.*, 2017).

Table 2. Antimicrobial Susceptibility Profile of *E. coli* Isolated from Broiler coinfecting with Newcastle disease virus

S/NO	Antimicrobial agent	Sensitive (%)	Intermediate (%)	Resistance (%)
1.	Augmentin	Positive	Negative	Negative
2.	Amoxicillin	Negative	Negative	Positive
3.	Ampicillin	Negative	Positive	Positive
4.	Ciprofloxacin	Positive	Negative	Negative
5.	Cefotaxime	Positive	Negative	Negative
6.	Tetracycline	Negative	Negative	Positive
7.	Streptomycin	Positive	Negative	Negative
8.	Ofloxacin	Positive	Negative	Negative
9.	Levofloxacin	Negative	Positive	Negative
10.	Gentamycin	Positive	Negative	Negative

The identification of NDV antigen in a vaccinated flock presents a serious economic and veterinary challenge. The possible explanations for this observation may be because of break in cold chain, antigenic variation, and reversion to virulence (Solomon *et al.*, 2012). We, therefore, recommend further studies to identify the cause of vaccine failures or the non-protection of vaccinated flock from infection as observed in this report.

The identification of NDV antigen in a vaccinated flock is a concerning issue. Potential explanations for vaccine failure include breaks in the cold chain, antigenic variation, and reversion to virulence (Bala, 2023). Further research is

needed to investigate the underlying causes of vaccine failure and to develop more effective vaccination strategies to protect poultry flocks from NDV infection.

4. CONCLUSION

This case study identified NDV and *E. coli* in a broiler flock vaccinated against ND. The presence of drug-resistant *E. coli* highlights the importance of timely and appropriate antimicrobial therapy to control secondary bacterial infections. The case was successfully managed with palliative treatment.

5. RECOMMENDATIONS

1. Strict Biosecurity Measures: Implement rigorous biosecurity measures to prevent the introduction and spread of NDV and other infectious diseases.
2. Vaccination Programs: Adhere to recommended vaccination protocols, ensuring proper vaccine storage, handling, and administration.
3. Antimicrobial Stewardship: Promote responsible use of antimicrobials to minimize the emergence of drug-resistant bacteria.
4. Surveillance and Monitoring: Conduct regular surveillance and monitoring programs to detect and control outbreaks of NDV and other poultry diseases.
5. Public Health Education: Raise awareness about the potential zoonotic risks associated with poultry diseases and encourage good hygiene practices.

By following these recommendations, it is possible to mitigate the impact of NDV and other poultry diseases on both poultry and public health.

ACKNOWLEDGEMENT

The authors acknowledge the contribution of the staff of the Veterinary Microbiology Laboratory, University of Maiduguri, Nigeria and the 600 level students in the faculty of Veterinary Medicine who participated in the case.

DISCLAIMER (ARTIFICIAL INTELLIGENCE)

Authors hereby declare that NO generative AI technologies such as Large Language Models (ChatGPT, COPILOT, etc.) and text-to-image generators have been used during the writing or editing of this manuscript.

COMPETING INTERESTS

Authors have declared that no competing interests exist.

Please mention highlighted references in APA format inside the text

REFERENCES

Abdisa, T., & Tagesu, T. (2017). Review on Newcastle disease of poultry and its public health importance. *J. Vet. Sci. Technol*, 8(3), 441.

Abdu, P. A., Tekdek, L. B., Umoh, J. U., Usman, M., & Oladele, S. B. (2006). Newcastle disease in Nigeria. *Nigerian Veterinary Journal*, 27(2), 23-32.

Ahmed, A. A., Salem, H. M., Hamoud, M. M., & Amer, M. M. (2025). Avian Colibacillosis, Multidrug Resistance, Antibiotic Alternatives: an Updated Review. *Egyptian Journal of Veterinary Sciences*, 1-21.

Amoia, C. F. A. N. G., Nnadi, P. A., Ezema, C., & Couacy-Hymann, E. (2021). Epidemiology of Newcastle disease in Africa with emphasis on Côte d'Ivoire: A review. *Veterinary World*, 14(7), 1727.

Ashraf, A., & Shah, M. S. (2014). Newcastle disease: present status and future challenges for developing countries. *African Journal of Microbiology Research*, 8(5), 411-416.

Bala, N. (2023). *Studies on thermostable Newcastle Disease Virus induced cytokine expression in chicken embryo fibroblast* (Doctoral dissertation, University of Veterinary and Animal Sciences).

Daodu, O. B., Aiyedun, J. O., Kadir, R. A., Ambali, H. M., Oludairo, O. O., Olorunshola, I. D., ... & Baba, S. S. (2019). Awareness and antibody detection of Newcastle disease virus in a neglected society in Nigeria. *Veterinary World*, 12(1), 112.

Dimitrov, K. M., Afonso, C. L., Yu, Q., & Miller, P. J. (2017). Newcastle disease vaccines—A solved problem or a continuous challenge?. *Veterinary Microbiology*, 206, 126-136.

Ejeh, F. E., Lawan, F. A., Abdulsalam, H., Mamman, P. H., & Kwanashie, C. N. (2017). Multiple antimicrobial resistance of *Escherichia coli* and *Salmonella* species isolated from broilers and local chickens retailed along the roadside in Zaria, Nigeria. *Sokoto Journal of Veterinary Sciences*, 15(3), 45-53.

Fadiga, M. L., Jost, C., & Ihedioha, J. (2013). Financial costs of disease burden, morbidity and mortality from priority livestock diseases in Nigeria: Disease burden and cost-benefit analysis of targeted interventions. *ILRI Research Report*.

Getabalew, M., Alemneh, T., Akebernegn, D., Getahun, D., & Zewdie, D. (2019). epidemiology, Diagnosis & Prevention of Newcastle disease in poultry. *Am J Biomed Sci Res*, 16, 50-9.

Landman, W. J. M., Vervaet, C., Remon, J. P., Huyge, K., & Van Eck, J. H. H. (2017). Primary Newcastle disease vaccination of

- broilers: comparison of the antibody seroresponse and adverse vaccinal reaction after eye–nose drop or coarse spray application, and implication of the results for a previously developed coarse dry powder vaccine. *Avian Pathology*, 46(4), 451-461.
- Lawal, J. R., Jajere, S. M., Mustapha, M., Bello, A. M., Wakil, Y., Geidam, Y. A., ... & Gulani, I. A. (2015). Prevalence of newcastle disease in Gombe, Northeastern Nigeria: a ten-year retrospective study (2004–2013). *British Microbiology Research Journal*, 6(6), 367-375.
- Malik, Y. S., Arun Prince Milton, A., Ghatak, S., Ghosh, S., Malik, Y. S., Arun Prince Milton, A., ... & Ghosh, S. (2021). Newcastle disease and other avian paramyxoviruses. *Role of Birds in Transmitting Zoonotic Pathogens*, 79-91.
- Nolan, L. K., Barnes, H. J., Vaillancourt, J. P., Abdul-Aziz, T., & Logue, C. M. (2013). Colibacillosis. *Diseases of Poultry*, 751-805.
- Saliu, O. J., Sanda, M. E., Dairo, F. A. S., & Salihu, I. (2013). An Analysis of Benefit and Cost of Local Chicken Production By the Adopters and on–Adopters of Newcastle Disease Vaccination in Kogi–State, Nigeria. *Nigerian Journal of Animal Science*, 15, 229-240.
- Shehata, A. A., & Hafez, H. M. (2024). Colibacillosis. In *Turkey Diseases and Disorders Volume 1: Bacterial and Fungal Infectious Diseases*(pp. 29-45). Cham: Springer International Publishing.
- Solomon, P., Abolnik, C., Joannis, T. M., & Bisschop, S. (2012). Virulent Newcastle disease virus in Nigeria: identification of a new clade of sub-lineage 5f from livebird markets. *Virus Genes*, 44, 98-103.
- Stear, M. J. (2005). OIE Manual of Diagnostic Tests and Vaccines for Terrestrial Animals (Mammals, Birds and Bees) 5th Edn. Volumes 1 & 2. World Organization for Animal Health 2004. ISBN 92 9044 622 6. €140. *Parasitology*, 130(6), 727-727.
- UI Rahman, A., Ishaq, H. M., Raza, M. A., & Shabbir, M. Z. (2022). Zoonotic potential of Newcastle disease virus: Old and novel perspectives related to public health. *Reviews in Medical Virology*, 32(1), e2246.
- Weerts, E. A., Matthijs, M. G., Bonhof, J., van Haarlem, D. A., Dwars, R. M., Gröne, A., ... & Jansen, C. A. (2021). The contribution of the immune response to enhanced colibacillosis upon preceding viral respiratory infection in broiler chicken in a dual infection model. *Veterinary Immunology and Immunopathology*, 238, 110276.
- Yehia, N., Salem, H. M., Mahmmud, Y., Said, D., Samir, M., Mawgod, S. A., ... & Zanaty, A. M. (2023). Common viral and bacterial avian respiratory infections: an updated review. *Poultry Science*, 102(5), 102553.

Disclaimer/Publisher's Note: The statements, opinions and data contained in all publications are solely those of the individual author(s) and contributor(s) and not of the publisher and/or the editor(s). This publisher and/or the editor(s) disclaim responsibility for any injury to people or property resulting from any ideas, methods, instructions or products referred to in the content.