

Case report

METASTATIC COLON CANCER WITH PERITONEAL OLIGOPROGRESSION: SURGERY FIRST OR DEFERRED SURGERY- CASE REPORT

ABSTRACT:

Colon cancer may give rise to peritoneal metastases, which, if few in number and resectable in an operable patient, may benefit from curative therapeutic management, essentially local treatment (mainly surgery) and chemotherapy; surgery first or chemotherapy requires specialist advice, especially when these peritoneal metastases are not the first. Case report: We report the case of a diabetic patient undergoing dietary hygiene measures, diagnosed with a moderately differentiated and infiltrating colonic adenocarcinoma, with mutation in RAS status and microsatellite stability; and 4 synchronous hepatic metastatic lesions. The patient received neo-adjuvant chemotherapy followed by liver surgery; and FOLFOX-based adjuvant chemotherapy followed by colon surgery. One year after primary surgery, a peritoneal nodule appeared in the pouch of Douglas. The patient was operated on immediately and then treated with adjuvant chemotherapy (capecitabine). Conclusion: it is possible to standardize therapeutic approaches to colon cancer oligo-metastatic to the liver, especially in case of synchronous metastases and absence of other distant lesions; but when it comes to the peritoneum, treatment would be on a case-by-case basis.

KEYWORDS: colorectal cancer, oligo progression, peritoneum, treatment

INTRODUCTION:

Colorectal cancer is the most common digestive cancer, and the fourth in the world after lung, prostate and breast cancer. In recent years, colorectal cancer has benefited from scientific advances in both diagnosis and treatment, thanks to a better understanding of carcinogenesis, molecular biology, and the identification of biological markers that can be used to guide treatment. It is a disease for which screening is possible, essentially in the case of a personal or family history of adenomatous polyps, inflammatory bowel diseases or colorectal cancer. [1] [2]

Metastatic colon cancer is not synonymous with palliative treatment, especially in the case of resectable liver or peritoneal metastases. The indication for chemotherapy CT is clear in the case of hepatic metastases; but location of this systemic treatment in relation to surgery in the case of peritoneal metastases is not always obvious, particularly in a patient already treated for secondary hepatic lesions, and who has received chemotherapy on several occasions. [3]

In this context, we report the case of a patient followed for colon cancer with synchronous liver metastases, treated with surgery and chemotherapy, who subsequently developed a peritoneal metastasis.

CASE PRESENTATION

CLINICAL OBSERVATION:

The patient is 59 years old, with type II diabetes on dietary therapy since 2021, operated in 1999 for haemorrhoids and in 2006 for an ectopic pregnancy. The patient has no family history of colorectal disease or cancer.

2 months before diagnosis (at the beginning of 2022), the patient had lost weight, which convinced her to consult a doctor. As part of the exploratory workup, a TAP CT scan was ordered, which showed 4 hepatic nodules (right liver), suggestive of secondary localizations (subsequently confirmed on liver MRI). Colonoscopy conducted by a gastrologist showed a tumour process in the left colic flexure, and biopsy was in favor of a moderately differentiated and infiltrative colonic adenocarcinoma, with mutated RAS status and stable microsatellite profile. PET scan showed no other lesions apart from liver metastases.

The patient received 2 cycles of FOLFOX followed by 2 cycles of FOLFIRINOX. A TAP CT scan performed after this chemotherapy showed a 16% of response to neo-adjuvant treatment; and so, surgery for the liver metastases was performed (controlled right hepatectomy + cholecystectomy), followed by adjuvant chemotherapy (3 months of FOLFOX), then surgery for the primary lesion (segmental colectomy and colo-colic anastomosis).

A biological monitoring in early 2024 revealed a rise in CEA levels, justifying a thoracic CT scan, abdominal MRI and colonoscopy, which were all free of suspicious lesions.

A PET scan revealed a 60-mm hypermetabolic nodule in the recto-uterine pouch, raising the suspicion of a single recurrent peritoneal disease. Biopsy of this nodule led to the diagnosis of a moderately differentiated adenocarcinoma compatible with the patient's known colonic cancer.

Commented [AP1]: Include more context on the patient's history, such as the duration and impact of symptoms before diagnosis.

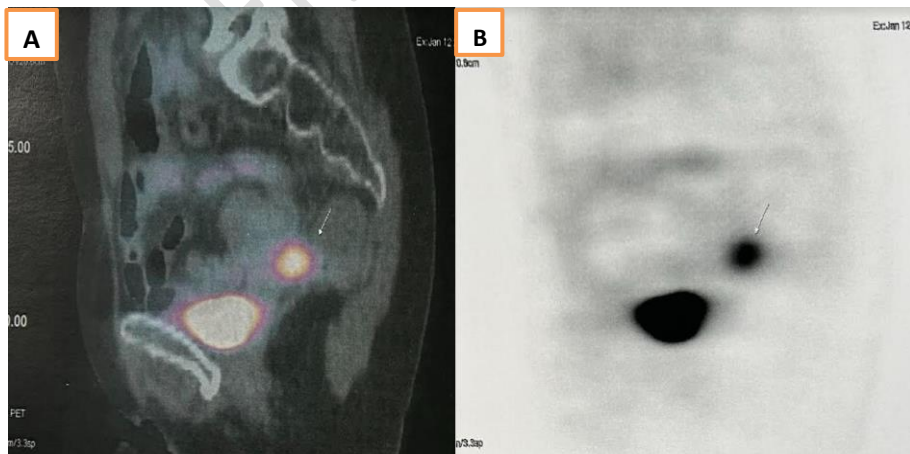

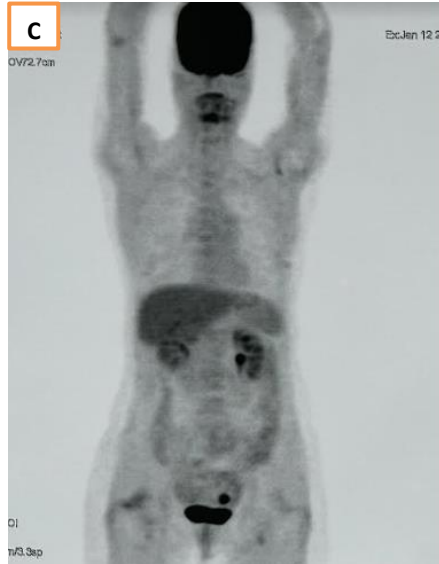


Figure :

(A) Sagittal section PET-CT showing a pathological hypermetabolic nodule in the recto-uterine pouch with tracer fixation.

(B) PET-CT (MIP image) sagittal section showing a pathological hypermetabolic foci in the recto-uterine pouch

(C) PET-CT (MIP image) in frontal section showing pathological hypermetabolic foci

We were faced with a colon cancer metastatic to the liver (synchronous metastases) treated with chemotherapy, surgery for metastases, chemotherapy then surgery for the primary cancer, which subsequently developed a single peritoneal metastasis.

The nodule was resectable from the outset; and in accordance with recent recommendations from the scientific societies of Medical Oncology, and after a medical staff, the decision was made to operate without any neo-adjuvant treatment.

The patient was put on capecitabine after surgery.

DISCUSSION:

For patients whose oligo-metastatic disease is confined to a single organ, or few organs or sites (mainly visceral metastases), there is a potentially curative approach; and complete tumor eradication can be achieved by R0 surgical resection and/or A0 ablation. In this context, long-term survival, or even cure, can be achieved in 20-45% of patients who undergo complete resection of their metastases. [4] [5]

The visceral metastases concerned hepatic, pulmonary or peritoneal; [6] [7]

Commented [AP2]: Discuss more in detail why surgery was prioritized over chemotherapy in this specific case.

and the histological subtype in colorectal cancer may influence the site of metastasis. [8]

The management of peritoneal metastases is more complicated than that of liver metastases, and requires multidisciplinary consultation meetings at an expert center.

- In the event of synchronous peritoneal metastasis, discovered at the same time as the primary colon cancer, and if the latter is not symptomatic, a complete pre-therapeutic work-up is required, including colonoscopy, Morpho-PET, laparoscopy and biopsies preferably performed by the team that will perform the cytoreductive surgery ± diffusion MRI. CT -PET is also beneficial in this case. [9]

+If, after a multidisciplinary consultation meeting, surgery is deemed possible (resectable disease and operable patient), it should be performed in a center of expertise; cytoreductive surgery is the standard. However, patients with involvement of six or more regions of the abdominal cavity, or grossly incomplete cytoreduction, may have a grave prognosis. [10] [11]

+If not, systemic chemotherapy is proposed first.

- In the event of metachronous peritoneal metastasis, the therapeutic procedures become even more complicated, especially in patients who have already been treated for metastatic colorectal disease (liver, lung or other). This raises a number of questions: should chemotherapy be given before operating on the peritoneal lesion, or go to surgery directly? Is it possible to start a neo-adjuvant systemic treatment when the patient has recently been treated with chemotherapy? What adjuvant treatment should be introduced?

The latest research in oncology is helping to clarify treatment decisions: resectability and time between the last course of chemotherapy and occurrence of metastases must be taken into consideration.

- In case of unresectable metachronous peritoneal metastases, in a patient whose last cycles of FOLFOX or CAPEOX-based chemotherapy were more than 12 months ago, or who has never been treated with chemotherapy, systemic treatment is indicated. The treatment options are FOLFOX, CAPEOX, FOLFIRI or FOLFIRINOX. [12]

In fragile patients, fluoropyrimidine alone without oxaliplatin can be retained.

Resectability should be reassessed 2 months later.

If last cycles of chemotherapy do not exceed 12 months, FOLFOX cannot be indicated, so either FOLFIRI (with or without bevacizumab, aflibercept, ramucirumab or anti EGFR if RAS/ BRAF WT in left colon), or even encorafenib, trastuzumab or others.

And reassess resectability 2 months later.

For peritoneal metastases that may become resectable, it is recommended that a CT protocol giving a high response rate be preferred with a view to secondary resectability: tri-CT or bi-CT plus biotherapy. Four phase III trials have demonstrated higher RECIST objective response rates with bi-CT combined with cetuximab than bi-CT combined with bevacizumab, in the absence of RAS mutation.

- In case of resectable metachronous peritoneal metastases, whether the patient was previously treated with chemotherapy or is naïve to this treatment, we can start with 2 to 3 months of FOLFOX, CAPEOX, capecitabine or 5-FU/leucovorin followed by resection; otherwise, resection from the beginning. Adjuvant treatment can then be proposed (observation, capecitabine, 5-FU/leucovorin, CAPEOX, FOLFOX or FOLFIRI +/- biotherapy). But the place of bevacizumab is not always clear, given the risk of early post-operative complications. [13]

According to some knowledge centers, complete resection from the beginning seems to be the best option when the peritoneal carcinosis is isolated, resectable and with moderate extension (PCI < 15) in a patient in good general condition and without visceral insufficiency. Cytoreductive surgery without intraperitoneal chemotherapy should be performed in an expert center.

For patients at high risk of developing colorectal peritoneal metastases, systematic second-look surgery plus oxaliplatin-HIPEC did not improve disease-free survival compared with standard surveillance. Currently, essential surveillance appears to be adequate and effective in terms of survival outcomes. [14]

CONCLUSIONS:

Oligo-metastatic colon cancer is not a rare disease, but its particularity concerns the site of metastases, their numbers, timing of occurrence, and previous treatments.

All these factors require us to ask questions, and unravel them one by one.

COMPETING INTERESTS DISCLAIMER:

Authors have declared that they have no known competing financial interests OR non-financial interests OR personal relationships that could have appeared to influence the work reported in this paper.

REFERENCES:

- [1] P. Rawla, T. Sunkara, et A. Barsouk, « Epidemiology of colorectal cancer: incidence, mortality, survival, and risk factors », *Prz Gastroenterol*, vol. 14, n° 2, p. 89-103, 2019, doi: 10.5114/pg.2018.81072.
- [2] H. T. Nguyen et H.-Q. Duong, « The molecular characteristics of colorectal cancer: Implications for diagnosis and therapy (Review) », *Oncology Letters*, vol. 16, n° 1, p. 9-18, juill. 2018, doi: 10.3892/ol.2018.8679.
- [3] E. T. J. Chandy, H. J. Saxby, J. W. Pang, et R. A. Sharma, « The multidisciplinary management of oligometastases from colorectal cancer: a narrative review », *Annals of Palliative Medicine*, vol. 10, n° 5, Art. n° 5, mai 2021, doi: 10.21037/apm-20-919.

Commented [AP3]: Summarize the clinical implications concisely. Mention how the findings from this case report could guide future decision-making in similar cases.

[4] A. Cervantes *et al.*, « Metastatic colorectal cancer: ESMO Clinical Practice Guideline for diagnosis, treatment and follow-up », *Annals of Oncology*, vol. 34, n° 1, p. 10-32, janv. 2023, doi: 10.1016/j.annonc.2022.10.003.

[5] R. Yokoi *et al.*, « Optimizing Treatment Strategy for Oligometastases/Oligo-Recurrence of Colorectal Cancer », *Cancers*, vol. 16, n° 1, Art. n° 1, janv. 2024, doi: 10.3390/cancers16010142.

[6] M. Riihimäki, A. Hemminki, J. Sundquist, et K. Hemminki, « Patterns of metastasis in colon and rectal cancer », *Sci Rep*, vol. 6, p. 29765, juill. 2016, doi: 10.1038/srep29765.

UNDER PEER REVIEW

- [7] D. Goéré *et al.*, « Is there a possibility of a cure in patients with colorectal peritoneal carcinomatosis amenable to complete cytoreductive surgery and intraperitoneal chemotherapy? », *Ann Surg*, vol. 257, n° 6, p. 1065-1071, juin 2013, doi: 10.1097/SLA.0b013e31827e9289.
- [8] N. Hugen, C. J. H. van de Velde, J. H. W. de Wilt, et I. D. Nagtegaal, « Metastatic pattern in colorectal cancer is strongly influenced by histological subtype », *Annals of Oncology*, vol. 25, n° 3, p. 651-657, mars 2014, doi: 10.1093/annonc/mdt591.
- [9] Gauthé M, Richard-Molard M, Cacheux W et al. Role of fluorine 18 fluorodeoxyglucose positron emission tomography/computed tomography in gastrointestinal cancers. *Dig Liver Dis*. 2015, 19:S1590-8658
- [10] Elias D, Lefevre JH, Chevalier J, Brouquet A et al. Complete cytoreductive surgery plus intraperitoneal chemohyperthermia with oxaliplatin for peritoneal carcinomatosis of colorectal origin. *J Clin Oncol*. 2009; 27:681-5
- [11] Verwaal VJ, van Ruth S, de Bree E, van Sloothen GW et al. Randomized trial of cytoreduction and hyperthermic intraperitoneal chemotherapy versus systemic chemotherapy and palliative surgery in patients with peritoneal carcinomatosis of colorectal cancer. *J Clin. Oncol*. 2003; 21:3737-3743
- [12] G. Masi *et al.*, « Treatment with 5-fluorouracil/folinic acid, oxaliplatin, and irinotecan enables surgical resection of metastases in patients with initially unresectable metastatic colorectal cancer », *Ann Surg Oncol*, vol. 13, n° 1, p. 58-65, janv. 2006, doi: 10.1245/ASO.2006.03.094.
- [13] Eveno C, Passot G, Goéré D et al. Bevacizumab doubles the early postoperative complication rate after cytoreductive surgery with hyperthermic intraperitoneal chemotherapy (HIPEC) for peritoneal carcinomatosis of colorectal origin. *Ann Surg Oncol*. 2014; 21:1792-800.
- [14] Goéré D, Glehen O, Quenet F, et al. Second-look surgery plus hyperthermic intraperitoneal chemotherapy versus surveillance in patients at high risk of developing colorectal peritoneal metastases (PROPHYLOCHIP-PRODIGE 15): a randomised, phase 3 study. *Lancet Oncol*. 2020;21(9):1147-1154.