

Case report

A case report on Ventricular tachycardia on a young patient with hemochromatosis

ABSTRACT

Background Hemochromatosis is characterized by excessive iron accumulation in tissues, particularly in the liver, but also in the heart. In young patients, this iron overload can cause serious cardiac complications, including ventricular arrhythmias.

Case presentation We present the case of a 16-year-old patient who was diagnosed with hepatic hemochromatosis at the age of 10 years without cardiologic follow-up. He was admitted because of palpitations and malaise. His ECG showed ventricular tachycardia (VT) and echocardiography revealed nonobstructive hypertrophic cardiomyopathy with left ventricular systolic function of 30%. Genetic testing was performed and showed no mutation.

The patient was treated with Cordarone to stabilize his heart rhythm, then treatment for heart failure was started and treatment with iron chelators was proposed to the family but not carried out due to lack of funds, and an implantable cardioverter defibrillator was considered for secondary prevention.

and implantable cardioverter defibrillator (ICD) for secondary prevention.

Conclusion This case highlights the importance of cardiologic follow-up in patients with hemochromatosis for early administration of effective treatments such as iron chelators to prevent serious complications such as VT.

Keywords: *Ventricular tachycardia, hemochromatosis, palpitations, case report*

1. INTRODUCTION

Iron overload disorders have multiple causes. They may be primary, associated with a genetic abnormality, or secondary.

Iron overload disease mainly affects people of Northern European origin, where the prevalence rate in the general population is estimated to be between 1 and 4 per thousand.

In adults, it causes generalized iron overload, the clinical consequences of which are all the rarer the earlier it is diagnosed.

Although hepatic manifestations are the most commonly described, this accumulation of iron also affects other organs, including the heart, joints and pancreas. Cardiac iron overload, also known as cardiac hemochromatosis, is a dreaded complication because it can lead to cardiomyopathy, heart failure, and arrhythmias, including malignant ventricular arrhythmias such as ventricular tachycardia (VT) and ventricular fibrillation.

The cardiac involvement of hemochromatosis may manifest as dilated or hypertrophic cardiomyopathy, the latter being less common but equally dangerous. Excessive iron accumulation in the myocardium leads to myocardial fibrosis, which is an arrhythmogenic substrate and increases the risk of VT. In young patients, this complication can be insidious, making rigorous screening and cardiologic follow-up essential.

We report here the case of a 16-year-old patient diagnosed with hepatic hemochromatosis at the age of 10 years, with no significant cardiac history, who presented with symptomatic VT. This case highlights the importance of cardiac monitoring in hemochromatosis as well as the challenges of managing arrhythmic complications in this young population.

2. CASE PRESENTATION

A 16-year-old male was diagnosed with hepatic hemochromatosis at the age of 10. Although he was regularly monitored for liver function, he had never had a cardiac evaluation.

On admission, he reported frequent palpitations and severe fatigue. He also presented multiple episodes of syncope.

The patient was admitted to the emergency department for palpitations and syncope. Physical examination revealed regular ventricular tachycardia with a rate of 170 beats per minute, correct blood pressure of 123/72 mm Hg, and no clinical signs of heart failure.

The ECG (Figure 1) showed regular monomorphic VT with large complexes, suggesting a threatening ventricular arrhythmia that required rapid stabilization with Cordarone 300 mg followed by a maintenance dose of 900 mg/24h.

An ECG (Figure 2) was repeated 30 minutes after the loading dose of Cordarone and showed a return to sinus rhythm.

A transthoracic echocardiogram (TTE) (Figure 3) showed non-obstructive hypertrophic cardiomyopathy with a thickened interventricular septum of 19 mm and left ventricular systolic function of 30%.

As the patient stabilized, cardiac MRI was performed as part of the etiologic work-up, which revealed myocardial iron overload, confirmed by a marked reduction in T2*, indicating diffuse myocardial fibrosis.

Serum ferritin level was elevated to 2200 ng/mL and transferrin saturation reached 95%, confirming iron overload.

Genetic testing was performed and no mutation was found.

Treatment for cardiac insufficiency based on cardioversion enzyme inhibitors and beta-blockers was started, and iron chelation treatment was proposed to the family but not carried out due to lack of funds, and an implantable cardioverter defibrillator was considered for secondary prevention.

A 1-year follow-up showed stabilization of cardiac damage with no arrhythmias or conduction disturbances.

FIGURE 1. EKG REVEALED SUGGESTING A VENTRICULAR ARRHYTHMIA

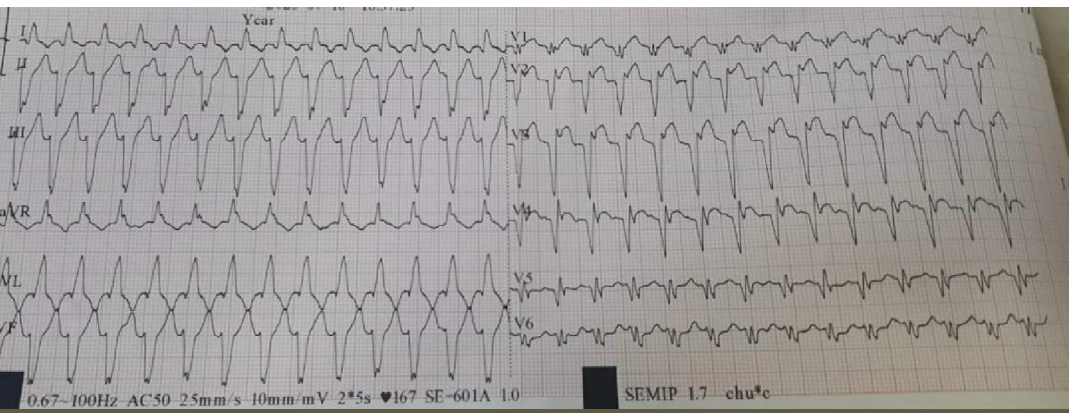


FIGURE 2. EKG SHOWING A RETURN TO SINUS RHYTHM

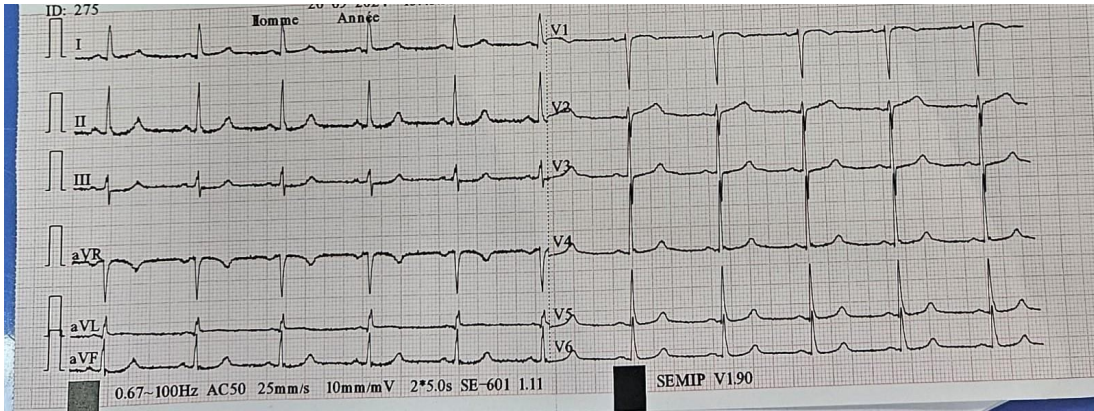
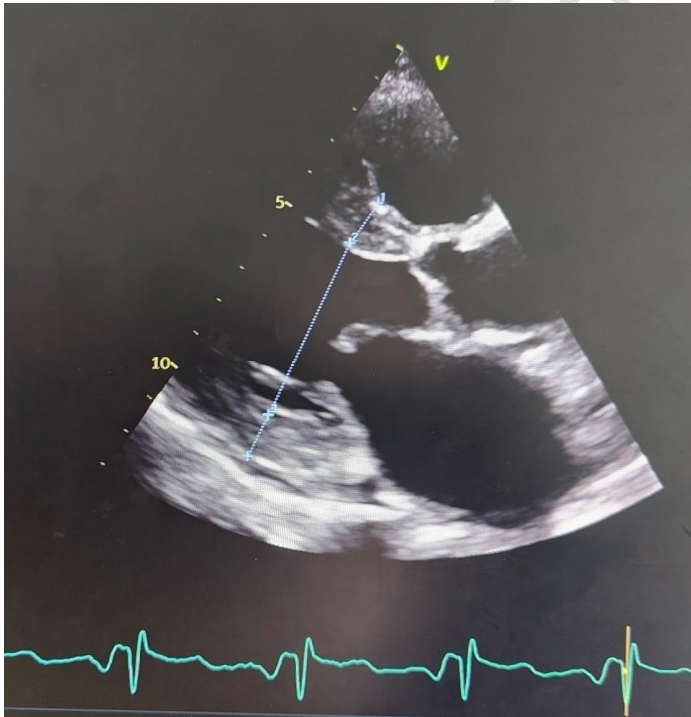


FIGURE 3. TTE REVEALED NON-OBSTRUCTIVE HYPERTROPHIC CARDIOMYOPATHY



3. DISCUSSION

Hemochromatosis affects the liver, but iron can also be deposited in the myocardium, leading to structural and functional abnormalities.

Iron deposited in cardiomyocytes induces increased peroxidation of membrane lipids in the sarcolemma and mitochondria through the formation of free radicals.

This leads to impaired activity of the Na⁺/K⁺ -ATPase pump, increased fragility of lysosomes and impaired activity of the mitochondrial respiratory chain.

The subsequent consequence of iron overload is cavitory dilatation and thickening of the ventricular walls. Impaired left ventricular relaxation is the first manifestation of myocardial iron overload.

The study by Parkes [1] showed that iron enters the cell in both ferrous and ferric forms, although the ferrous form is more effective. The cellular entry of iron is facilitated by L-type calcium channels, with competition between ferrous iron and the calcium required for muscle contraction.

Since ferric iron must hypothetically be reduced to ferrous iron by a ferricyanide reductase in order to enter the cell, the hijacking of the role of calcium channels could explain the relaxation disorders observed.

The suppression of the role of calcium channels could explain the observed relaxation abnormalities. However, the use of calcium channel inhibitors partially invalidates this latter hypothesis. This study shows the persistence of intracellular penetration of the 2 ionic forms of iron [1].

Compliance disorders and left ventricular systolic dysfunction appear later in the course of hemochromatosis, as do rhythmic complications such as ventricular and conductive tachycardia, which can be fatal.

Initially, myocardial iron deposition leads to restrictive cardiomyopathy and diastolic dysfunction with preserved systolic function. Iron tends to accumulate initially in the ventricular myocardium, followed by the atrial myocardium [2], with predominant deposition in the subepicardial layer [3].

Iron deposition in the myocardium is the major cause of diastolic left ventricular dysfunction, which, in combination with immunologic and genetic factors, contributes to left ventricular systolic dysfunction and failure [4, 5].

Further damage to the myocardium is secondary to the production of free radicals, as unbound iron is highly reactive. Irreversible dilated cardiomyopathy may occur later with the development of left ventricular systolic dysfunction as a result of LV remodeling, left ventricular chamber dilation and reduced LVEF [6-7].

-Echocardiography can provide a baseline assessment of ventricular size and function. Evaluation of diastolic function using transmitral E and A waves, tissue Doppler, strain rate imaging, and estimation of pulmonary artery systolic pressure (tricuspid regurgitant jet velocity) are important tools to provide a complete assessment of diastolic function and pulmonary hypertension, which are characteristic of iron overload cardiac dysfunction. [8]

-MRI is essential for the diagnosis of hemochromatosis, and evaluation of T2* relaxation time is an excellent noninvasive correlate of myocardial iron deposition and is a useful technique for monitoring response to iron chelation therapy. [9]

Left ventricular systolic dysfunction and heart failure occur late in the disease process, are often resistant to treatment, and carry a poor prognosis [10].

-A Serum transferrin saturation greater than 45%, a serum ferritin level greater than 200 mg/L in premenopausal women, and a serum ferritin level greater than 300 mg/L in men and postmenopausal women are indicators of primary hemochromatosis [11].

-Serum ferritin is also commonly elevated in patients with secondary iron overload, and although it correlates poorly with myocardial iron deposition, it remains a useful screening test for secondary iron overload[12].

Genetic screening for the C252Y and H52D mutations in type 1 primary hemochromatosis provides a basis for family-based counseling.

-The mainstay of therapy for excessive iron deposition in patients with primary and secondary hemochromatosis is phlebotomy and iron chelation, respectively, which are designed to promote systemic iron removal.

The goal is to maintain a serum ferritin concentration of 50 ng/mL or less[13].

Unfortunately, patients with primary hemochromatosis are often diagnosed and treated after iron overload has progressed. [13]

In patients with secondary iron overload, iron chelation therapy is the main therapy available, using the parenteral iron chelator, deferoxamine, or the oral iron chelators, deferiprone and deferasirox.

Chelation has been shown to improve ventricular function, prevent ventricular arrhythmias, and reduce mortality in patients with secondary iron overload[14].

Oral deferiprone is more effective than deferoxamine in removing myocardial iron[14] and, compared with standard chelation monotherapy with deferoxamine, combination treatment with deferiprone reduced myocardial iron and improved cardiac and endothelial function in thalassemia major patients with cardiac iron overload[16].

In patients with heart failure, management is based on the same principles as in patients with dilated cardiomyopathy and systolic heart failure[15] Clearly, early use of angiotensin-converting enzyme inhibitors and b-adrenergic blockers along with device therapy should be routine therapy for patients with iron overload-induced systolic heart failure based on current clinical practice guidelines[17] Combined heart and liver transplantation may be considered in cases of severe refractory iron overload cardiomyopathy[18].

Although iron chelation therapy is widely used to treat iron overload, recent data have shown that iron overload cardiomyopathy and increased mortality are still common in these patients [3].

-Long-term patient follow-up studies have shown that the degree of cardiac iron accumulation is directly correlated with both cardiac morbidity and mortality.

Diastolic dysfunction has been shown to be an independent prognostic marker of increased mortality in patients with iron overload [8].

Chronic iron overload can lead to a variety of arrhythmias, including atrioventricular block, conduction defects, bradyarrhythmias, tachyarrhythmias, and sudden cardiac death. [19]

This case highlights the importance of regular cardiological surveillance in patients with hemochromatosis, even in the absence of initial symptoms. Proactive monitoring with non-invasive cardiac imaging tests, such as T2* cardiac MRI, would allow early detection of myocardial iron overload and optimize therapeutic management.

4. CONCLUSION

Iron overload cardiomyopathy is an important and potentially reversible cause of heart failure worldwide and is associated with diastolic dysfunction, increased susceptibility to arrhythmias and late-stage dilated cardiomyopathy. Iron studies, cardiac MRI with T2* measurement, echocardiographic assessment and plasma BNP levels are important diagnostic and prognostic tools in the evaluation of patients with iron overload cardiomyopathy. Iron overload cardiomyopathy is reversible if therapy is initiated before the onset of overt heart failure and effective therapy is available, including phlebotomy and iron chelation for primary hemochromatosis and secondary iron overload, respectively.

This case study confirmed that myocardial iron overload, although often initially asymptomatic, can rapidly progress to serious complications such as ventricular tachycardia, and demonstrated the importance of cardiologic follow-up in hemochromatosis, particularly in young patients, given the reversibility of the condition if effective treatment is initiated early.

Acknowledgements

We thank the patient for their approval of publishing this case report.

Funding

None to declare.

Availability of data and materials

The data of this case report includes the echocardiography film and all other patient's data that we had a consent to publish. These data are available from the corresponding author on reasonable request.

Disclaimer (Artificial intelligence) : Author(s) hereby declare that NO generative AI technologies such as Large Language Models (ChatGPT, COPILOT, etc.) and text-to-image generators have been used during the writing or editing of this manuscript.

Ethics approval Our institution does not require ethical approval for reporting individual cases or case series

Consent for publication

Written informed consent was obtained from the parents for publication of this case report and accompanying images

REFERENCES

- 1- Parkes JG, Olivieri NF, Templeton MD. Characterization of Fe²⁺ and Fe³⁺ transport by ironloaded cardiac myocytes. *Toxicology*. 1997; 117: 141-51.
2. Kremastinos DT, Farmakis D (2011) Iron overload cardiomyopathy in clinical practice. *Circulation*. 124(20):2253–2263
- 3-Olson LJ, Edwards WD, McCall JT, Ilstrup DM, Gersh BJ (1987) Cardiac iron deposition in idiopathic hemochromatosis: histologic and analytic assessment of 14 hearts from autopsy. *J Am Coll Cardiol* 10(6):1239–1243
- 4- Kell DB (2009) Iron behaving badly: inappropriate iron chelation as a major contributor to the aetiology of vascular and other progressive inflammatory and degenerative diseases. *BMC Med Genet* 2:2
- 5- van Bokhoven MA, van Deursen CT, Swinkels DW (2011) Diagnosis and management of hereditaryhaemochromatosis. *BMJ (Clinical research ed)* 342:c7251
- 6- Oudit GY, Trivieri MG, Khaper N, Liu PP, Backx PH (2006) Role of L-type Ca²⁺ channels in iron transport and iron-overload cardiomyopathy. *J Mol Med (Berlin, Germany)* 84(5):349–364
- 7-Kremastinos DT, Tsiapras DP, Tsetsos GA, Rentoukas EI, Vretou HP, Toutouzas PK (1993) Left ventricular diastolic Doppler characteristics in beta-thalassemia major. *Circulation*. 88(3):1127–1135
8. Sachdev V, Machado RF, Shizukuda Y, Rao YN, Sidenko S, Ernst I, et al. Diastolic dysfunction is an independent risk factor for death in patients with sickle cell disease. *J Am Coll Cardiol*2007;49:472e9
9. Leonardi B, Margossian R, Colan SD, Powell AJ. Relationship of magnetic resonance imaging estimation of myocardial iron to left ventricular systolic and diastolic function in thalassemia. *JACC Cardiovasc Imaging* 2008;1:572e8.
10. Kremastinos DT. Heart failure in beta-thalassemia. *Congest Heart Fail* 2001;7:312e4.
11. Andrews NC. Disorders of iron metabolism. *N Engl J Med* 1999;341: 1986e95.
12. Alizad A, Seward JB. Echocardiographic features of genetic diseases: part 2. Storage disease. *J Am Soc Echocardiogr* 2000;13: 164e70.
13. Muhlestein JB. Cardiac abnormalities in hemochromatosis. In: Barton JC, Edwards CQ, editors. *Hemochromatosis: genetics, pathophysiology, diagnosis, and treatment*. Cambridge: Cambridge University Press; 2000. p. 297e310.
14. Pennell DJ, Berdoukas V, Karagiorga M, Ladis V, Piga A, Aessopos A, et al. Randomized controlled trial of deferiprone or deferoxamine in beta-thalassemia major patients with asymptomatic myocardial siderosis. *Blood* 2006;107:3738e44.
15. Hahalis G, Alexopoulos D, Kremastinos DT, Zoumbos NC. Heart failure in beta-thalassemia syndromes: a decade of progress. *Am J Med* 2005;118:957e67.
16. Tanner MA, Galanello R, Dessi C, Smith GC, Westwood MA, Agus A, et al. A randomized, placebo-controlled, double-blind trial of the effect of combined therapy

with deferoxamine and deferiprone on myocardial iron in thalassemia major using cardiovascular magnetic resonance. *Circulation* 2007;115:1876e84

17. Hunt SA, Abraham WT, Chin MH, Feldman AM, Francis GS, Ganiats TG, et al. ACC/AHA 2005 Guideline Update for the Diagnosis and Management of Chronic Heart Failure in the Adult: a report of the American College of Cardiology/American Heart Association Task Force on Practice Guidelines. *Circulation* 2005; 112:e154e235.

18. Olivieri NF, Liu PP, Sher GD, Daly PA, Greig PD, McCusker PJ, et al. Brief report: combined liver and heart transplantation for end-stage iron-induced organ failure in an adult with homozygous beta-thalassemia. *N Engl J Med* 1994;330:1125e7.

19. Olivieri NF, Nathan DG, MacMillan JH, Wayne AS, Liu PP, McGee A, et al. Survival in medically treated patients with homozygous beta-thalassemia. *N Engl J Med* 1994;331:574e8.

UNDER PEER REVIEW