

# Case report

## Inverted papilloma of the bulla ethmoidalis: An uncommon epicenter for a benign yet aggressive tumor

---

### ABSTRACT

Inverted papillomas are benign tumours known for their locally aggressive behaviour, characterised by local tissue destruction, a high tendency to recur if resection is incomplete, and a risk of carcinomatous evolution into squamous cell carcinoma. Although most cases arise from the nasal wall and paranasal sinuses, inverted papillomas originating from the bulla ethmoidalis are exceedingly rare. We report the case of a 67-year-old man who presented with progressive right-sided nasal obstruction and rhinorrhoea. Imaging and histopathological findings confirmed the diagnosis of inverted papilloma arising from the right bulla ethmoidalis. Surgical excision was performed, and complete resection was achieved. The patient had an uneventful postoperative recovery, and follow-up will be crucial for monitoring potential recurrence. This case highlights the importance of early recognition, appropriate imaging, and thorough surgical planning in managing inverted papillomas, particularly in rare locations such as the bulla ethmoidalis, to ensure optimal outcomes and reduce the risk of recurrence and malignancy.

*Keywords: inverted papilloma, bulla ethmoidalis, mulberry-like mass, focal hyperostosis*

### 1. INTRODUCTION

Inverted papillomas, also known as Schneiderian papillomas, are benign sinonasal tumours that commonly arise from the lateral nasal wall and middle meatus, but they may develop from any part of the Schneiderian membrane in the nose and paranasal sinuses (1). Although inverted papillomas are typically benign, they are characterised by locally aggressive behaviour, a high potential for recurrence, and an association with malignant transformation into squamous cell carcinoma (2).

### 2. CASE PRESENTATION

A 67-year-old non-smoker with underlying hypertension and hyperlipidaemia presented with progressive right nasal blockage and rhinorrhoea for the past 2 months. He had a history of nasal surgery at a private centre 12 years ago.

Anterior rhinoscopy and endoscopy revealed a grade IV right nasal cavity mass arising from the osteomeatal complex. A biopsy was taken from the right nasal cavity mass, and

histopathological study suggested an inverted sinonasal papilloma. Computed tomography (CT) showed a soft tissue density mass arising from the right middle turbinate, extending to the posterior choana, with minimal calcification seen at the superior margin of the mass at the anterior ethmoidal air cells' origin. The right osteomeatal complex was patent, and there was no mass effect on surrounding structures.

The patient underwent endoscopic right medial maxillectomy and right ethmoidectomy, which revealed a pale, glistening polypoidal, mulberry-like mass arising from the right bulla ethmoidalis (Figure 1, 2). Pathological examination of the excised mass confirmed the diagnosis of inverted sinonasal papilloma.

### 3. DISCUSSION

Inverted papillomas are benign neoplasm originating from the Schneiderian membrane, the mucosa lining the nasal cavity and paranasal sinuses. According to the World Health Organization (WHO) classification, nasal papillomas can be divided into three types: inverted, exophytic (fungiform), and oncocytic (columnar or cylindrical) papillomas (3).

A study by Schneyer et al. identified 90 attachment sites in a cohort of 83 patients (4). For inverted/cylindrical papillomas, the maxillary sinus (42%) is the most common site of attachment, followed by the ethmoid sinus (18%), nasal cavity (15%), middle/superior turbinate (12%), sphenoid sinus (1.5%), and cribriform plate (1.5%). Fungiform papillomas have been described as originating from the septum or nasal vestibule, whereas inverted and cylindrical papillomas are more commonly found in the paranasal sinuses or lateral nasal wall.

The exact pathogenesis of inverted papilloma remains unclear, but several theories have been proposed. Metaplasia of the respiratory epithelium into a stratified squamous epithelium is the most widely accepted theory. This metaplastic process is thought to be induced by irritant exposure, chronic inflammation, or viral infections like human papillomavirus (HPV) (5).

Radiologic assessment plays an important role in the preoperative evaluation of inverted papilloma, as it allows for precise determination of tumour extension, location, and surgical mapping for excision. There is insufficient evidence to suggest one specific modality as providing optimal imaging for inverted nasal papilloma. CT scanning is the initial modality of choice to evaluate the extent of the disease (6), although the appearance on CT is non-specific. Inverted papillomas may present on CT as isodense unilateral homogeneous lesions, generally centred on the meatus nasi medius. Microcalcifications within the lesion are found in about 20% of cases, and bone lysis may suggest malignancy. Lee et al. found a strong correlation (89%) between focal hyperostosis seen on CT bone window settings and the surgically identified attachment site of inverted papillomas (7). Focal hyperostosis is an eccentric bone thickening and sclerosis that involves only a limited portion of the wall of a given paranasal sinus. In this case, calcification was observed at the superior margin of the mass at the anterior ethmoidal air cells (Figure 3).

Surgery is the treatment of choice, either through an endonasal endoscopic or external approach, depending on the extension of the disease, tumour characteristics, and tailored according to the patient's condition (8). Postoperative follow-up is critical for early detection of local relapse, which can occur early but may also present later. The seriousness of this pathology lies in the risk of carcinomatous evolution, which may be diagnosed at the outset or at recurrence during follow-up.

## 4. CONCLUSION

Although inverted papillomas comprise only 0.5–7% of all primary nasal tumours (9), they should be suspected in cases of unilateral polyps arising from the lateral nasal wall, particularly in male patients in the fifth to seventh decades of life. Diagnosis relies on a combination of imaging studies and histopathological examination. The mainstay of treatment for inverted papilloma, regardless of its site of origin, is surgical excision. Complete resection is essential to minimise the risk of recurrence and malignant transformation. In conclusion, while inverted papilloma is most commonly found on the lateral nasal wall and middle meatus, it can arise from various rare sites. Early recognition, appropriate imaging, and thorough surgical planning are key to achieving a favourable outcome.

## COMPETING INTERESTS

Authors have declared that there are no competing interests in handling this case.

## CONSENT (WHEREEVER APPLICABLE)

All authors declare that written informed consent was obtained from the patient and patient agreed for publication of this case report and accompanying images. A copy of the written consent is available for review by the Editorial office/Chief Editor/Editorial Board members of this journal whenever needed.

## REFERENCES

1. Murphy, J. T., Chandran, A., Strachan, D. R., & Sood, S. (2010). *Bilateral inverted papilloma: A report of two cases and review of the current literature. Indian Journal of Otolaryngology and Head & Neck Surgery*, 62(3), 313–316
2. Lisan, Q., Laccourreye, O., & Bonfils, P. (2016). *Sinonasal inverted papilloma: From diagnosis to treatment. European Annals of Otorhinolaryngology, Head and Neck Diseases*, 133(5), 337–341
3. Barnes L, Tse L, Hunt JL. Schneiderian papillomas. In: Barnes L, Eveson JW, Reichert P, eds. World Health Organization Classification of Tumours. Pathology and Genetics of Head and Neck Tumours. IARC Press; 2005:28-32
4. Schneyer MS, Milam BM, Payne SC. Sites of attachment of Schneiderian papilloma: a retrospective analysis. *Int Forum Allergy Rhinol*, 2011; 1:324–328
5. Kakkad J, Deshmukh P, Gaurkar S (November 08, 2023) Inverted Papilloma From Nasal Septum: A Rare Case Presentation. *Cureus* 15(11): e48486
6. Karkos PD, Khoo LC, Leong SC, Lewis-Jones H, Swift AC (2009) Computed tomography and/or magnetic resonance imaging for pre-operative planning for inverted nasal papilloma: review of evidence. *J Laryngol Otol* 123(7): 705–709
7. Lee DK, Chung SK, Dhong HJ, et al. Focal hyperostosis on CT sinonasal inverted papilloma as a predictor of tumor origin. *Am J Neuroradiol*. 2007;28:618–621.
8. Busquets JM, Hwang PH. Endoscopic resection of sinonasal inverted papilloma: a meta-analysis. *Otolaryngol Head Neck Surg*. 2006;134(3):476–482.
9. Barnes L (2002) Schneiderian papillomas and nonsalivary glandular neoplasms of the head and neck. *Mod Pathol* 15:279–297

## ABBREVIATIONS

CT: Computer tomography

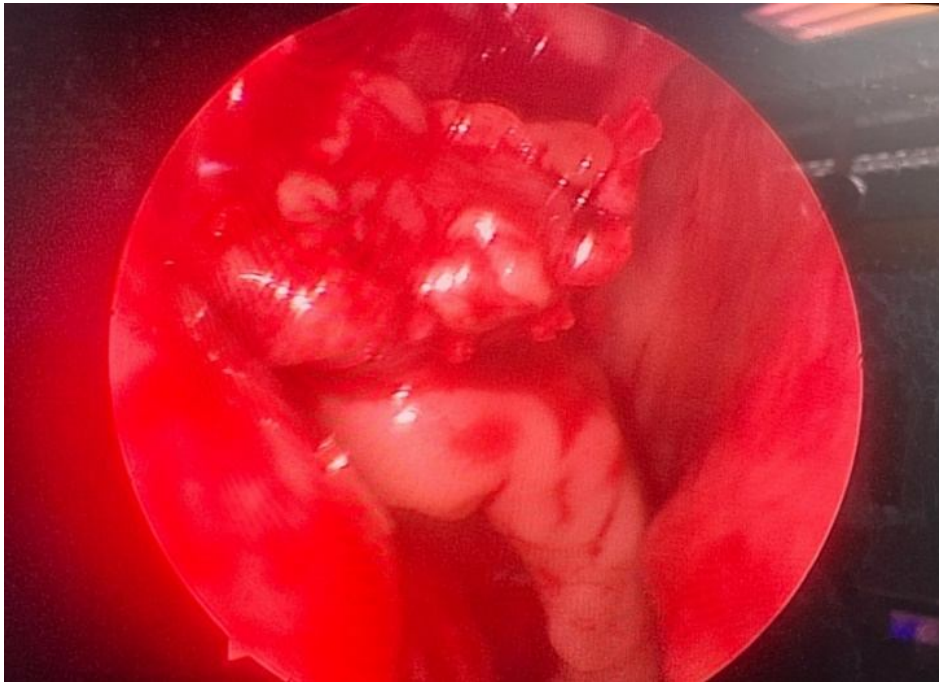

Figure 1: Intraoperative nasal endoscopy shows mulberry liked mass arising from right bulla ethmoidalis

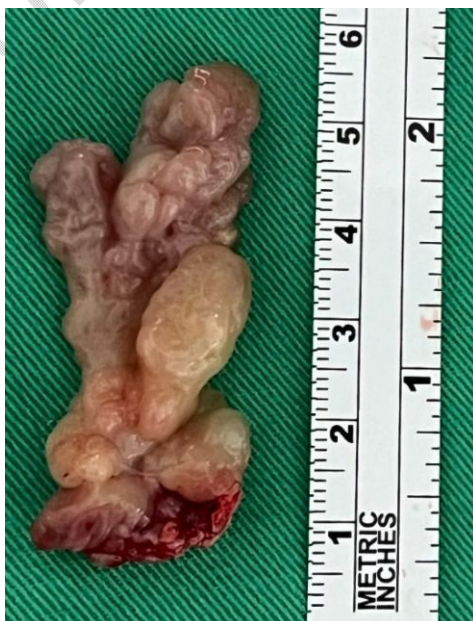

Figure 2: Excised mass from right bulla ethmoidalis

200x magnification

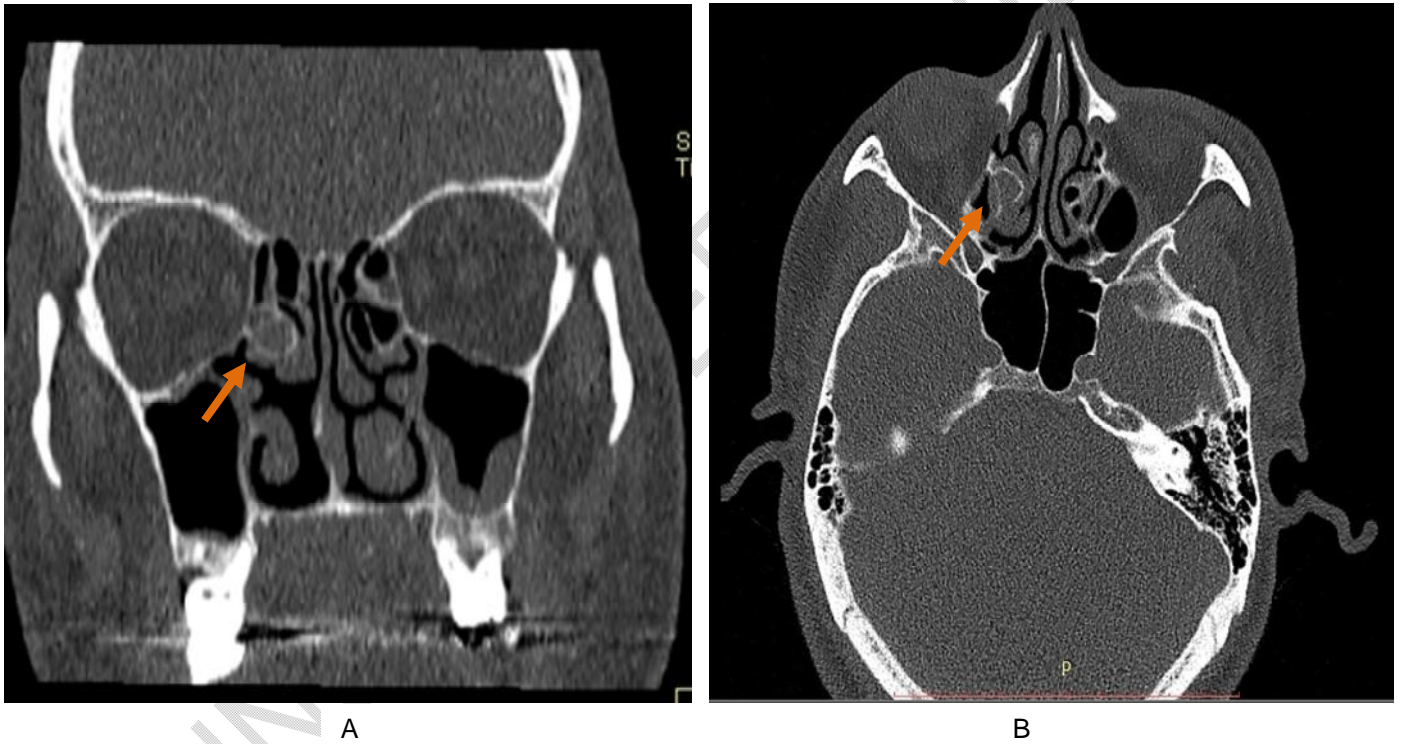


Figure 3: (A) Coronal view (B) Sagittal view of CT Paranasal Sinus bone window setting showing mass at the anterior ethmoidal air cells with focal hyperostosis