

## Case study

# An Unexpected Origin of Coma in a Patient with Atrial Fibrillation: Bilateral Paramedian Thalamic and Midbrain Stroke Secondary to Artery of Percheron Occlusion

---

### ABSTRACT

The thalamus is a part of the arousal system; its infarction can lead to varying levels of impaired consciousness (from hypersomnia to coma). It is mainly supplied by small perforating arteries arising from the posterior cerebral artery (PCA). There are several variants of this vascularization, the artery of Percheron (AOP) is one of those variants which takes the form of a solitary arterial trunk that arises from one of the proximal segments of the PCA and bifurcates to supply both paramedian thalami. Its occlusion results in bilateral paramedian thalamic infarction with or without midbrain involvement. Clinical presentation is varied and non-specific, it usually presents with altered mental status, hypersomnolence and ocular motor disorders. We report a rare case of acute coma in a 71-year-old man with atrial fibrillation (AF) secondary to a bilateral thalamus stroke due to AOP occlusion. Early diagnosis is challenging as it is often missed on a conventional Computed Tomography (CT), and diffuse-weighted magnetic resonance imaging (MRI) demonstrates the ischemic lesions after 48 hours. Antithrombotic drugs, supporting therapy, and rehabilitation were performed and patient's mental status gradually improved.

*Keywords: bilateral paramedian thalamic, midbrain, stroke, artery of percheron occlusion, atrial fibrillation, coma*

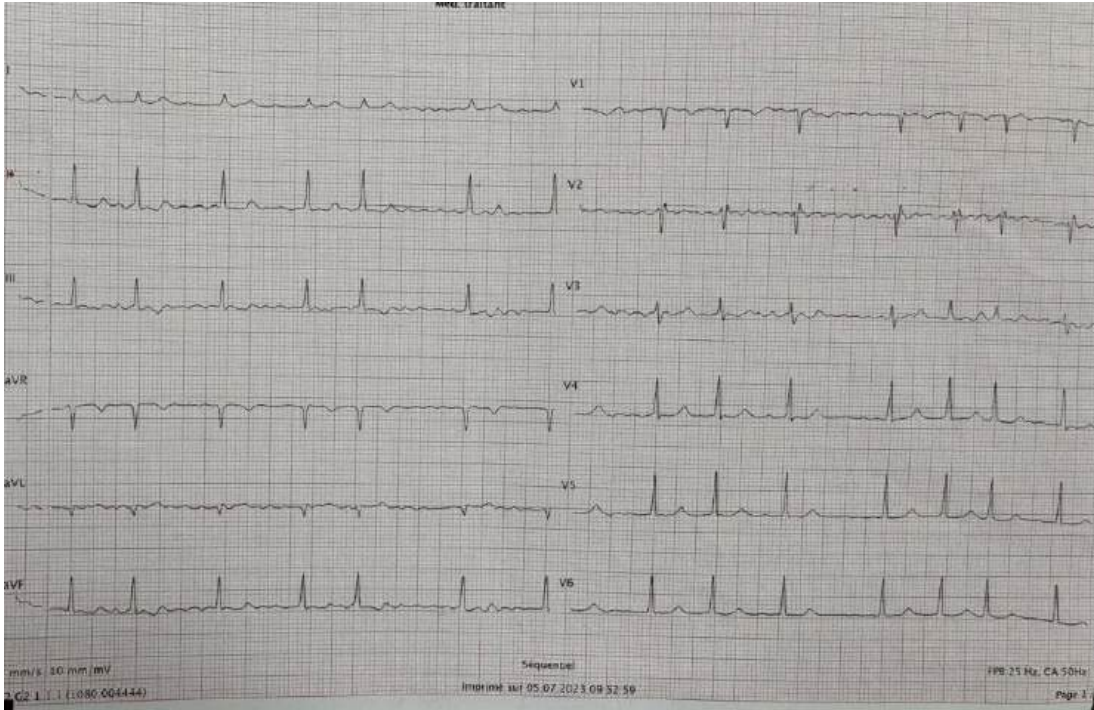
### 1. INTRODUCTION

Disorders of consciousness can result from several causes; in patients with atrial fibrillation, ischemic strokes are most often suspected, especially in the territories of the carotid artery. The thalamus is a part of the arousal system which regulates consciousness, sleep and vigilance by relaying information from the limbic system; its infarction can lead to varying levels of impaired consciousness. Bilateral thalamic infarction is a relatively rare presentation of posterior circulation stroke; its incidence is estimated at 0.1–2% of all ischemic strokes, and 4–18% of all thalamic infarcts [1]. We report a rare case of acute coma in a patient with

atrial fibrillation (AF) secondary to bilateral thalamic infarction due to occlusion of the artery of Percheron (AOP). This artery is a rare vascular variant which was first described by Gérard Percheron in 1973 [2] characterized by a solitary arterial trunk that arises from one of the proximal segments of either posterior cerebral artery (PCA) and bifurcates to supply both paramedian thalami [1-3]. The AOP incidence is estimated at 4% to 12% of the population [1]. Its occlusion leads to bilateral paramedian thalamic infarction sometimes extending to the midbrain [2-4]. In addition to the anatomical variability of vascular territories, the interindividual variability in the extent of infarcted territories makes its clinical picture highly polymorphic and often **delay delays** the diagnosis of this rare stroke, it is therefore rare for thrombolytic therapy to be carried out within the therapeutic window, which may further worsen the prognosis. We highlight the rarity of this lesion as origin of an acute coma, these mechanisms and the diagnostic difficulties encountered.

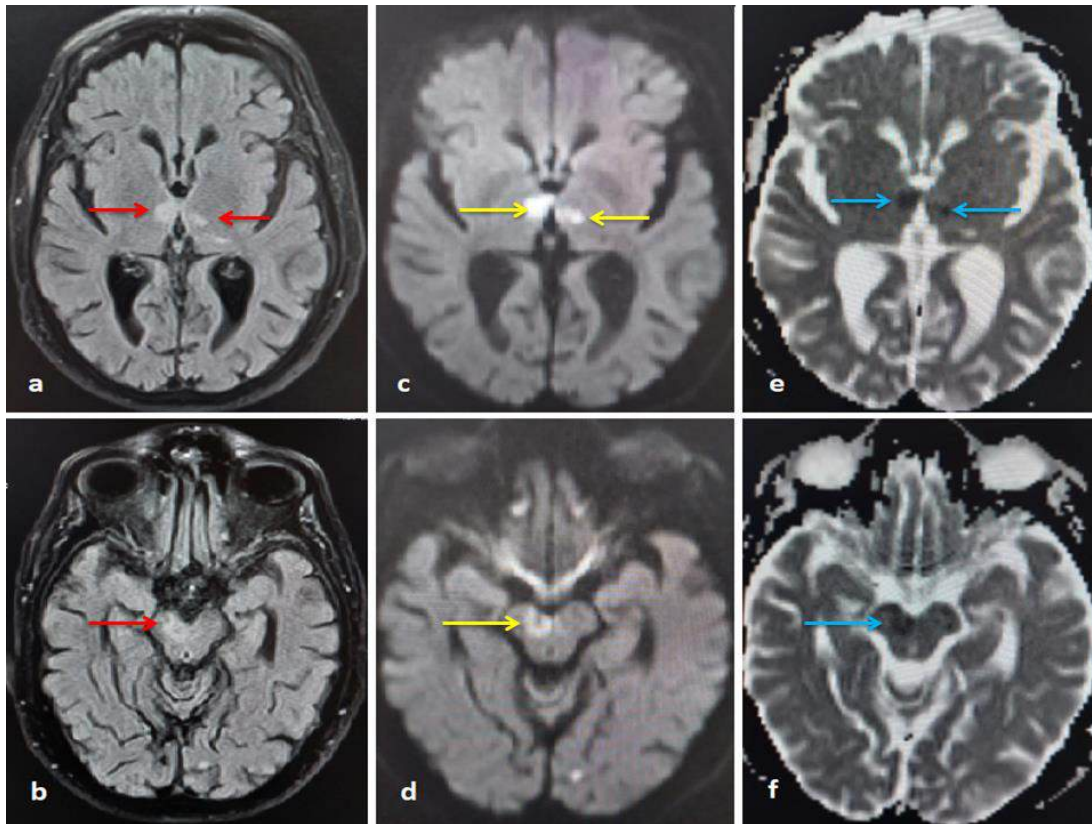
## 2. PRESENTATION OF CASE

A 71-year-old patient presented to the emergency department with sudden loss of consciousness. His past medical history **includes** poorly monitored diabetes **militus, mellitus, dyslipidemia dyslipidemia and ,and** non-documented arrhythmia. The patient has no recent history of trauma, fever, seizure or headache. He was on insulin and simvastatin 20 mg/day. Clinical examination revealed a Glasgow Coma Scale (GCS) of 8/15 (E2V2M4), symmetrical pupils with positive light reflex in both eyes, there was no significant motor deficit in the four limbs. The National Institutes of Health Stroke Scale (NIHSS) score was 25. The patient was **aperytic apyretic** with a supple neck, a random glucose test was 150 mg/dL, blood pressure of 150/90 **mmhg, mmHg**, heart rate of 95 beats/min, pulse oximetry of 94 % on room air. Blood work, especially tests looking for infectious origin, hormonal or electrolyte imbalances were without significant abnormalities: White cell count 7500 / $\mu$ L, C-Reactive Protein 6.4 mg/L, Sodium level 134 mEq/L, Calcium 8.5 mg/dL, Blood urea 0.45 g/L, Serum creatinine 11.0 mg/L, Thyroid-stimulating hormone and Thyroxine were within normal range. Brain CT scan was also without abnormalities. Urine and blood toxicological tests and cytobacteriological study of cerebrospinal fluid were **all**-negative. ECG reveals an AF with a rate of 83 beats/min (Fig. 1).



**Fig. 1. Patient Electrocardiogram showing an atrial fibrillation with a rate of 83 beats per minute**

The patient was admitted to ICU for close monitoring and supporting therapies. Electroencephalography did not show any epileptic activity. A brain MRI was performed after 48 hours and showed areas of; abnormal restriction of water diffusion on diffusion-weighted imaging (DWI), increased fluid attenuated inversion recovery (FLAIR) signal, and low signal intensity on apparent diffusion coefficient (ADC) maps of both paramedian thalami and right midbrain (Fig. 2), leading to suspicion of AOP occlusion. MR angiography was normal.



**Fig. 2. Axial brain MRI images showing areas of restricted diffusion on DWI sequences (red arrows) in bilateral paramedian thalami (a) and right midbrain (b), hyperintense signals in corresponding areas on FLAIR sequences (yellow arrows) in bilateral paramedian thalami (c) and right midbrain (d), and low signal intensity on ADC maps (blue arrows) in bilateral paramedian thalami (e) and right midbrain (f)**

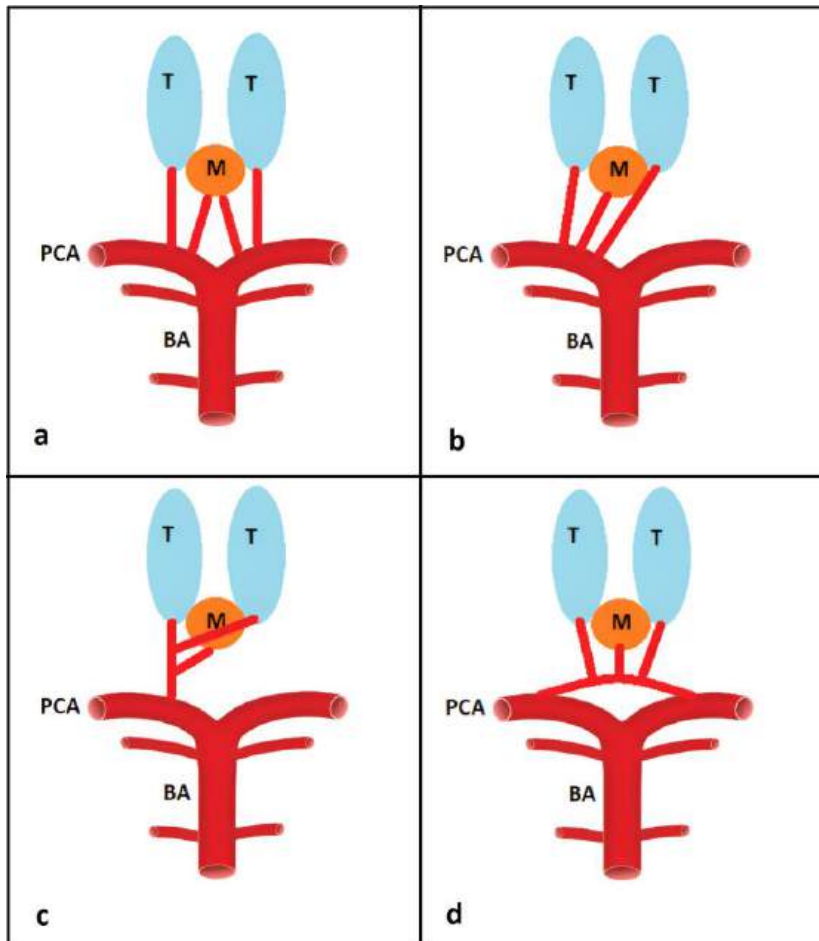
To further investigate the origin of stroke in this patient, a transthoracic echocardiogram was obtained showing mild ischemic **cardiopathy** **cardiopathy** with no significant thrombus images. Ultrasound of the supra-aortic trunks was without abnormalities. The cardioembolic origin was retained in view of the history of non-anticoagulated AF. Thrombolytic therapy was not used due to late diagnosis of AOP infarction. The patient was put on low-molecular-weight–heparin (Enoxaparin), oral acetylsalicylic acid, insulin **and** **and** rehabilitation therapy. His state of consciousness began to improve gradually during the following days in ICU. However, other signs, mainly ophthalmological (**bilateral vertical gaze palsy and right ptosis**) that were initially masked by coma **are beginning to be discovered** **began to dissolve**, **bilateral vertical gaze palsy and right ptosis**. On the fifth **day** **day**, the patient's GCS was 14/15 (E4V4M6), with an excessive tendency to hypersomnia, confusion, episodes of agitation, and dysarthria with memory impairment. **Oculomotor** **Oculomotor** disorders and right ptosis persisted without any clear regression affecting patient's autonomy. Hemodynamic and respiratory status remained stable. After ten **day** **days** in ICU, the patient was discharged to neurology department for continued care and then to his home with oral anticoagulation, antiplatelet drugs and continued rehabilitation after a month's stay in hospital. When he was discharged home, the patient was not completely independent in his daily life and required close assistance. Long term follow up information was not available.

### 3. DISCUSSION

The thalami are mainly supplied by small perforating arteries arising from the PCA and communicating arteries [5]. Four vascular territories were described: anterior (tubero-thalamic), infero-lateral, paramedian and posterior [1]. The paramedian territories are perfused by arteries which branch from the first portion (P1) of PCA [1,4,5]. Variants of this arterial anatomy were first studied by Gérard Percheron who described three types of vascularization from the PCA [2]; Type I, the most common variant: arteries arise from each P1 segment. Type II can take two forms: IIa; the two paramedian arteries arise from the same P1 segment, and IIb; the paramedian arteries originate from a common trunk which arises from P1 called the "artery of Percheron" (AOP). The last variant (type III) is an arcade of perforating arteries arising from an artery bridging both P1 segments [1,2] (Fig. 3). Additionally, the arteries supplying the rostral midbrain—the superior mesencephalic arteries— can arise separately from P1 or share a common trunk with the paramedian arteries [1,6]. Occlusion of the AOP results in bilateral paramedian thalamic infarcts with four possible presentations: 1) bilateral paramedian thalamic infarct with midbrain involvement (43%), 2) bilateral paramedian thalamic without midbrain (38%), 3) bilateral paramedian thalamic with anterior thalamus and midbrain (14%), and 4) bilateral paramedian thalamic with anterior thalamus without midbrain (5%) [1].

[100% Plagiarized Content](#)

<https://eurorad.org/case/11074>



**Fig. 3. Anatomical variants of the thalamic paramedian and midbrain arteries. (a) Type I. (b) Type IIa. (c) Type IIb. (d) Type III. AOP: artery of Percheron, BA: basilar artery, M: midbrain, PCA: posterior cerebral artery, T: thalamus.**

Bilateral thalamic infarcts by occlusion of the AOP have been subject of several publications revealing a significant clinical polymorphism and semiological richness, and consequently, the diagnostic challenge they represent [1,4,7,8]. This is explained by the multiple variations in thalamic vascular anatomy together with the wide range of functions that this structure ensures, and also depending of on the anatomical areas of thalamus and or midbrain involved [6]. The most common clinical signs encountered in this stroke are ophthalmological signs, disturbances of consciousness and cognitive disorders [1,7]. Impaired consciousness is the most frequent symptom, it may present as coma (42%), hypersomnia (35%) or reduced alertness (12%) [8]. The onset of symptoms is usually sudden, and they can last from several hours to days or weeks [8]. Our patient presented with the three common manifestations of this “stroke syndrome”, initially an acute coma and then ophthalmological signs with cognitive impairment after regression of coma. The bilateral thalamic infarction was an unexpected cause in our patient. In fact, given the history of poorly monitored diabetes an acute complication of diabetic disease was suspected initially such as hypoglycemia, ketoacidosis or hyperosmolar coma, but glycemic levels on admission did not explain this. Laboratory blood tests ruled out other metabolic, toxic or infectious encephalopathy. Ischemic origin was not suspected in view of the absence of any deficit

sign. Even ophthalmological signs which could point to this etiology were initially masked by the depth of coma. Disturbances of consciousness and coma in our case have been attributed to interruption of arousal dopaminergic and noradrenergic pathways that are relayed from ascending reticular activating system through the thalamus and diffusely to the cortex [1]. Whereas, **oculomotor oculomotor** disorders are likely due to the midbrain involvement, they have also been observed in patients without midbrain lesions, a finding that may be explained by disruption of cortical inputs that traverse the thalamus to reach the rostral interstitial medial longitudinal fasciculus [9]. The right ptosis in our patient is explained by damage of the third right cranial nerve nucleus located in the midbrain. Cognitive and behavioural disorders usually mimic a frontal syndrome and are most often explained by interruption of the thalamo-fronto-limbic loop by damage to the tuberothalamic territory [7].

CT scan is not very sensitive to this type of lesion, particularly in the acute phase, and may show bithalamic paramedian hypodensity which appears on average six hours after the onset of clinical signs. MRI still the gold standard for diagnosing AOP infarcts early, especially thanks to FLAIR and DWI sequences [1, 6]. It shows a restriction of water diffusion on DWI and increased FLAIR signal in infarcted areas. Nonvisualization of AOP in CT angiography or MR angiography does not exclude its presence, due to its possible occlusion and especially its small size [6], therefore conventional angiography is not systematically indicated for routine diagnosis of bilateral thalamic infarction caused by AOP occlusion. When clinical signs and MRI appearance are suggestive, the diagnosis should be considered.

Several causes have been reported in bilateral paramedian thalamic infarctions; However, cardioembolism and small artery disease remain the most common etiologies [10,11]. Risk factors include arterial hypertension, diabetes, AF, systemic hypotension, neoplasm, coagulopathy, vertebral artery dissection, inflammation, and cardiac aneurysms [12]. In our patient cardioembolism was likely the cause of this stroke in the course of AF, dyslipidemia and diabetes mellitus. The mean age and sex predilection of infarcts by occlusion of the AOP are unknown due to its rarity. However, PCA infarcts affect men at a mean age of 61.5 years in 58% of the cases [13].

Bilateral thalamic lesions can result from other types of infarcts apart from occlusion of AOP; especially deep cerebral venous thrombosis (DCVT) as well as "top of the basilar artery" syndrome. However, **Top top** of basilar syndrome involve also the superior cerebellar artery, PCA and pontine arteries territories. The lack of such associated lesions in our patient excluded this diagnosis [1,6,14]. DCVT may also be confused with AOP infarction, however, DCVT results in both bilateral thalamic and basal ganglia lesions, in addition, the appearance on MRI suggests vasogenic oedema rather than arterial infarcts **wich which** is discordant with our patient findings [14,15]. Other differential diagnoses were also included in our case such as Wernicke's encephalopathy, osmotic myelinosis, hypertensive encephalopathy, and Creutzfeldt- Jakob disease [15]; these diagnoses have been ruled out based on clinical criteria and radiological features.

The course of clinical disorders in AOP infarcts is also variable, ranging from total regression (13% of cases) [8], to cognitive and **oculomotor sequelaes oculomotor sequelae** (21%), to death in some cases. Usually severe disorders of consciousness regress in the following hours or days [12]. Recovery is generally regarded as having a better prognosis than from a cerebral or another subcortical area of infarct in all age groups [16]. Nonetheless, AOP infarcts with midbrain involvement demonstrates poor long term prognosis [17]. Persistence of some **sequelaes sequelae** depends on the severity of the initial clinical presentation; the size of infarction, and whether or not the ventricular system is involved [16]. In our patient, the regression of consciousness disorders was progressive over 3 days after being placed in

optimal condition in ICU, although cognitive disorders and oculomotor dysfunctions persisted and affected daily life activity despite medical therapy and rehabilitation. The poorer regression of cognitive abnormalities is explained by the bilateral nature of thalamic lesions, due to the bihemispheric representation of cognitive functions and cerebral plasticity in the case of unilateral damage [18].

As with other ischemic strokes, the most effective treatment for AOP infarction is intravenous heparin and thrombolysis especially for those within the therapeutic window (4.5-6 h) [11]. However, due to the usually delayed diagnosis, seldom could thrombolysis be used in clinic practice [19]. Some rare cases of successful tissue plasminogen activator therapy for AOP occlusion **was** **were** reported in the literature [19,20]. In our case, diagnosis was confirmed after 48 hours since the onset of symptoms, which has been outside of the thrombolysis window. A low-molecular-weight-heparin and antiplatelet drugs were prescribed to prevent future episodes. Li et al suggested that patient with AOP occlusion should continue long-term anticoagulant therapy [11].

#### **4. CONCLUSION**

Our case illustrates the importance of considering ischemic stroke in AOP territory in the differential diagnosis of acute disturbance of consciousness in elderly patients, especially in case of nonanticoagulated AF. In fact, complexity and diversity of the clinical presentation explain the difficulty of making the diagnosis on the basis of physical examination alone, MRI plays an important role in this case especially as CT scans can be falsely reassuring and often lead to misdiagnosis and therapeutic delay.

#### **CONSENT**

We as authors declare that written informed consent was obtained from the patient for publication of this case report and accompanying images.

#### **ETHICAL APPROVAL**

This case report has no breach of Helsinki declaration. All departmental and institutional protocols were followed in the process of acquisition and use of clinical information. The patient's data has been completely de-identified for confidentiality.

#### **REFERENCES**

[1] Lazzaro NA, Wright B, Castillo M, Fischbein NJ, Glastonbury CM, Hildenbrand PG et al. Artery of Percheron Infarction: Imaging Patterns and Clinical Spectrum. *Am J Neuroradiol.* 2010; 31(7):1283-9. DOI: 10.3174/ajnr.A2044

[2] Percheron G. The anatomy of the arterial supply of the human thalamus and its use for the interpretation of the thalamic vascular pathology. *Z Neurol.* 1973; 205:1-13. DOI: 10.1007/BF00315956

[3] Percheron G. Arteries of the human thalamus. II. Arteries and paramedian thalamic territory of the communicating basilar artery. *Rev Neurol (Paris)*. 1976; 132:309-24.

[4] Slamia LB, Jemaa HB, Benammou S, Tlili-Graïess K. Occlusion of the artery of percheron: clinical and neuroimaging correlation. *J Neuroradiol*. 2008; 35:244-5. DOI: 10.1016/j.neurad.2008.02.001

[5] Cosson A, Tatu L, Vuillier F, Parratte B, Diop M, Monnier G. Arterial vascularization of the human thalamus: extraparenchymal arterial groups. *Surg Radiol Anat*. 2003; 25:408-15. DOI: 10.1007/s00276-003-0153-7

[6] Matheus MG, Castillo M. Imaging of acute bilateral paramedian thalamic and mesencephalic infarcts. *Am J Neuroradiol*. 2003; 24:2005-8.

[7] Lamboley JL, Le Moigne F, Have L, Tsouka G, Drouet A, Salamand P et al. Artery of Percheron occlusion: Value of MRI. A review of six cases. *J Radiol*. 2011; 92(12):1113-21. DOI: 10.1016/j.jradio.2011.08.007

[8] Monet P, Garcia PY, Saliou G, Spagnolo S, Desblache J, Franc J, et al. Bithalamic infarct: Is there an evocative aspect? Radioclinical study. *Rev Neurol (Paris)*. 2009; 175:178-84. DOI: 10.1016/j.neurol.2008.08.012.

[9] Clark JM, Albers GW. Vertical gaze palsies from medial thalamic infarctions without midbrain involvement. *Stroke*. 1995; 26:1467-70. DOI: 10.1161/01.str.26.8.1467

[10] Jiménez Caballero PE. Bilateral paramedian thalamic artery infarcts: report of 10 cases. *J Stroke Cerebrovasc Dis*. 2010; 19:283-9. DOI: 10.1016/j.jstrokecerebrovasdis.2009.07.003

[11] Li X, Agarwal N, Hansberry DR, Prestigiacomo CJ, Gandhi CD. Contemporary therapeutic strategies for occlusion of the artery of Percheron: a review of the literature. *J Neurointerv Surg*. 2015; 7:95-8. DOI: 10.1136/neurintsurg-2013-010913

[12] Agarwal N, Chaudhari A, Hansberry DR, Prestigiacomo ChJ. Redefining thalamic vascularization vicariously through Gerald Percheron: a historical vignette. *World Neurosurg*. 2014; 81(1):198-201. DOI: 10.1016/j.wneu.2013.01.030

[13] Yamamoto Y, Georgiadis AL, Chang HM, Caplan LR. Posterior cerebral artery territory infarcts in the New England Medical Center Posterior Circulation Registry. *Arch Neurol*. 1999; 56(7):824-32. DOI: 10.1001/archneur.56.7.824

[14] Ameridou I, Spilioti M, Amoiridis G. Bithalamic infarcts: embolism of the top of basilar artery or deep cerebral venous thrombosis? *Clin Neurol Neurosurg*. 2004; 106(4):345-7. DOI: 10.1016/j.clineuro.2004.01.004

[15] Brami-Zylberberg F, Meary E, Oppenheim C, Gobin-Metteil MP, Delvat D, De Montauzan-Riviere I et al. Abnormalities of the basal ganglia and thalami in adults. *J Radiol*. 2005; 86(3):281-93. DOI: 10.1016/s0221-0363(05)81357-5

[16] Sulena, Singh P, Kaur R, Kumar N. Ischemic stroke due to occlusion of the artery of Percheron. *Indian J Crit Care Med*. 2016; 20:251-2. DOI: 10.4103/0972-5229.180052

[17] Arauz A, Patiño-Rodríguez HM, Vargas-González JC, Arguelles-Morales N, Silos H, Ruiz-Franco A et al. Clinical spectrum of artery of Percheron infarct: clinical-radiological correlations. *J Stroke Cerebrovasc Dis*. 2014; 23:1083-8. DOI: 10.1016/j.jstrokecerebrovasdis.2013.09.011

[18] Hermann DM, Siccoli M, Brugger P, Watcher K, Mathis J, Achermann P et al. Evolution of neurological, neuropsychological and sleep-wake disturbances after paramedian thalamic stroke. *Stroke*. 2008; 39:62-8. DOI: 10.1161/STROKEAHA.107.494955

[19] Kostanian V, Cramer SC. Artery of Percheron thrombolysis. *AJNR Am J Neuroradiol*. 2007; 28:870-1.

[20] Cao W, Dong Q, Li L, Dong Y. Bilateral thalamic infarction and DSA demonstrated AOP after thrombolysis. *Acta Radiol Short Rep*. 2012; 1:5. DOI: 10.1258/arsr.2012.110004