

Case report

Conservative management of a **radicular cyst**, associated with a pulpectomised primary molar followed by bonded space regainer for eruption of premolar: A case report

ABSTRACT

Background: Pulpectomy is considered as a conservative treatment option for pulpally involved primary teeth. Although it is safe, there are certain undesirable consequences, one of which being odontogenic cysts. **Peri-radicular** cysts associated with endodontically treated primary molars show specific clinical features such as large size, rapid growth, buccal expansion, and displacement of succedaneous teeth.

Treatment options for a radicular cyst involving primary teeth include extraction of the involved primary tooth or extraction and then decompression of the cyst, marsupialization or enucleation of the lesion.

Case description: A radicular cyst associated with a pulpectomised mandibular primary molar in a 10-year-old male patient is described here along with the radiographic and histopathological findings. **The cyst was treated by extraction of the involved primary tooth followed by marsupialization for decompression.** This case is still under follow up and the outcome 1 year after decompression is presented here. The eruption of blocked out succedaneous tooth was facilitated by placing a bonded space regainer using **Nickel-titanium (NiTi) wire**. 3 mm of the lost space was regained within 8 weeks using the bonded space regainer.

Conclusion: Extraction of the involved primary teeth followed by decompression of the cyst and preservation of the permanent teeth appeared to be the most suitable treatment option for large lesions in a developing dentition.

Clinical significance: Non-invasive treatment option should be considered for the management of radicular cysts in pediatric patients. Bonded space regainer is an efficient treatment modality for regaining lost space.

Keywords: Pulpectomised primary teeth, Radicular cyst, Decompression, Bonded space regainer

INTRODUCTION

Primary teeth with deep caries and pulpal involvement are managed by vital or non-vital pulp therapies. But studies show an association between endodontically treated primary molars and cyst formation. These cysts can either be radicular cysts or inflammatory dentigerous cysts of corresponding premolars (1,2). Other negative outcomes reported are, deviation of

permanent tooth bud, delay in eruption, malposition and enamel opacities in successor teeth (2). Radicular cysts involving primary teeth are found in the inter radicular area and around the roots in contrast to its periapical location in permanent teeth. Literature review reveals that only 112 cases of radicular cysts that derived from primary dentition have been reported from 1927 to 2004(3), of which 56% were thought to have resulted from pulp therapy (4). Grundy *et al.* have documented periapical pathosis, mainly cyst, in relation to primary teeth that has undergone both vital and non-vital pulp therapy(5).

Peri-radicular cysts that are associated with endodontically treated primary molars seem to show specific clinical features such as large size, rapid growth, buccal expansion, and displacement of succedaneous teeth (5). Treatment options for radicular cysts include total enucleation in the case of small lesions, and marsupialization followed by decompression of large ones. Normal alignment of the displaced succedaneous teeth will occur spontaneously, in most cases even if the initial position was highly unfavourable (6). This is a rare case of radicular cyst associated with a pulpectomised primary molar, managed by decompression and use of bonded space regainer to facilitate the eruption of blocked out succedaneous tooth.

CASE PRESENTATION:

A boy aged 10 years reported to the department out patient (OP) clinic with a swelling in the lower jaw on the left back teeth region noticed since 2 days. According to the patient's dental history, at the age of four, he had a pulpectomy on his lower left primary second molar. On extraoral examination, a non-tender, immobile, diffuse bony hard swelling measuring 4.5 × 2.5 cm was observed on the left side of mandibular corpus (Figure 1a). Intraorally, there was an expansion of the buccal cortical plate, extending from distal aspect of tooth number 73 to mesial aspect of 36 (Figure 1b). The erupted 34 was rotated distally and exhibited slight pathological mobility. The orthopantomogram (OPG) illustrated a massive unilocular radiolucency with a well-defined border extending from the distal aspect of 33 to the developing mesial root of 37 and inferiorly extending to the lower border of mandible. A radiopacity was noticed in the pulp chamber of 75, suggestive of previous pulp therapy (Figure 1c).

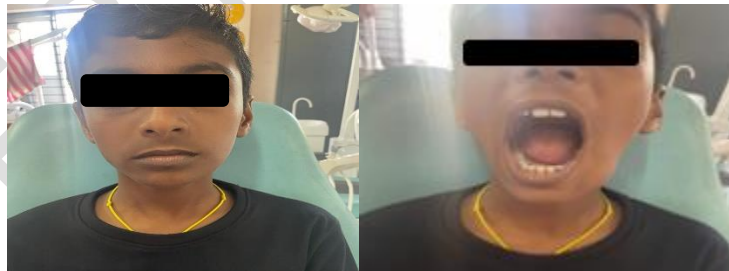


Fig. 1a. Preoperative extraoral photograph showing diffuse swelling on the left side of mandibular corpus .

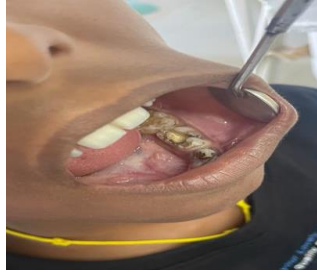

Fig. 1b. Preoperative intraoral photograph showing expansion of the buccal cortical plate, extending from distal aspect of tooth number 73 to mesial aspect of 36.

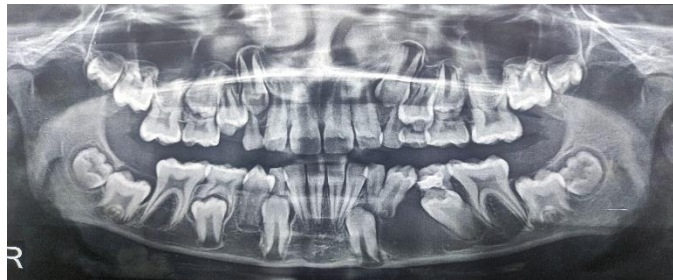


Fig. 1c. OPG showing a unilocular radiolucency with a well-defined border extending from the distal aspect of 33 to developing mesial root of 37 and inferiorly extending to lower border of mandible.

Upon aspiration, a pale yellow fluid was obtained. Aspiration cytology revealed the presence of neutrophils, sporadic dispersed macrophages, and a few lymphocytes with no atypical cells. Based on the patient's history, clinical and radiographic findings, a provisional diagnosis of radicular cyst was given after aspiration cytology. Extraction of involved primary tooth and decompression of cyst was planned as a conservative approach to prevent any damage to the permanent tooth buds. Preoperative blood tests were conducted, and all indices were within normal ranges. The cystic cavity was opened and the cystic fluid was drained following the extraction of 75 under local anesthesia. The lining of the cyst beneath was soft and thick. For histological analysis, a portion of the cystic lining was incised from the lesion's wall. Cortical plates were compressed, and the cavity was irrigated with povidone-iodine and saline solutions. A gauze pack with iodoform paste was placed in the cystic cavity. Instruction was given to the patient's mother to irrigate the cystic cavity with normal saline twice daily and to maintain oral hygiene. Histological examination revealed stratified squamous epithelium showing an arcading pattern of proliferation overlying a fibrillary connective tissue stroma. The stroma was having diffuse chronic inflammatory cell infiltrate and numerous forming, formed and engorged blood vessels were seen. The clinical, radiographic, and histologic findings confirmed the diagnosis of the radicular cyst.

One week later, the clinical symptoms had improved, the extraction wound's edges had epithelialized, and 34 became stable. A decompression stent was placed (Figure 2a) to maintain the patency of the cystic cavity. The patient was recalled for follow-up every 2 weeks for evaluation, and the resin projection was trimmed gradually to allow the eruption of the permanent tooth. After 4 months, OPG was taken to evaluate healing of the cystic lesion after decompression and the position of erupting 35. New bone formation was noted within the cystic lesion with trabecular structure reconstruction. There was further mesial tipping of 36 and distal tipping of 34 which resulted in space deficiency for eruption of 35 (Figure 2b).

Bonded space regainer using Nickel- Titanium (NiTi) wire was given to upright the teeth number,34 and 36 and the patient was recalled for follow-up every 2 weeks for evaluation (Figure 3a).The bonded space regainer was placed by bonding a composite dimple on the buccal side of 36 and, with the help of an explorer, burrowing a tunnel into the mesial of the dimple. A piece of 0.016-inch Nickel -Titanium wire is then bonded on the buccal side of 34 and extended beyond the dimple. After the composite had set on both the teeth, with the help of a birdbeak plier, the free end of the wire is directed into the tunnel made in the dimple of 36; thereby, an activated loop of Nickel -Titanium wire is created to upright-tipped 34 and 36. A small amount of bonding material is placed in the opening of the tunnel to make the attachment more permanent. Up righting of 36 and 34 was achieved within 8 weeks and 35 erupted into the gained space (Figure 3b). Orthodontic alignment of the crowded anterior teeth is planned at a later stage.

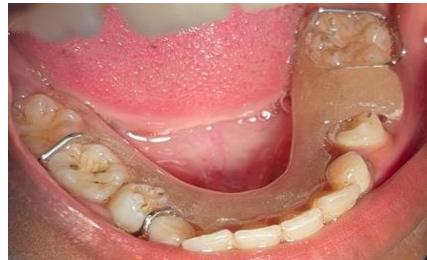

Fig. 2a. Insertion of a decompression stent with resin extension into the cystic cavity to maintain patency following decompression surgery.

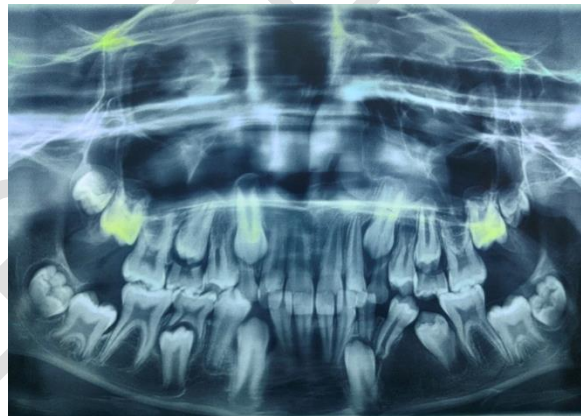


Fig. 2b . OPG at 4-month follow-up showing healing of the lesion and mesial tipping of 36 , distal tipping of 34 and locked out erupting 35

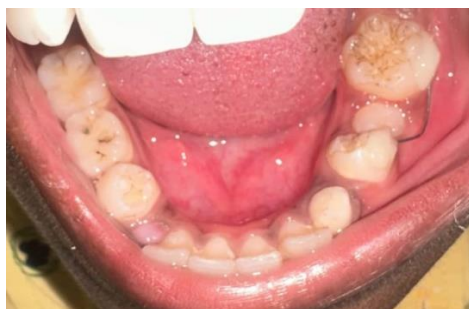

Fig. 3a . Pre treatment photograph of bonded Nickel -Titanium regainer.

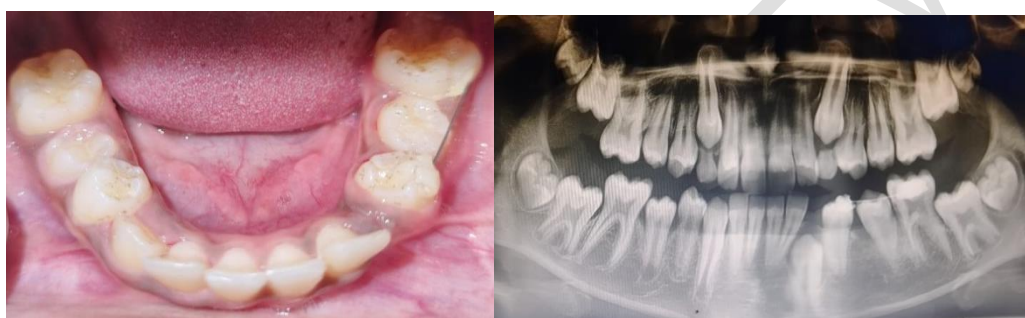

Fig. 3b . A 12-month follow-up showing bonded Nickel -Titanium regainer and erupting 35 with continued root formation.

DISCUSSION

Radicular cysts are uncommon in primary dentition, accounting for just 0.5–3.3% of all radicular cyst cases in the permanent and primary dentitions(7). Mass et al analyzed primary molars with radiolucent lesions ranging from 4-15 mm in diameter and suggested that radicular cysts associated with primary teeth are not rare, but merely overlooked (8). Goswami et al pointed out some reasons for rarity of radicular cyst in primary dentition. They are asymptomatic in nature as the accessory canals in primary teeth drains pulp and interradicular infections and are left unnoticed until detected by routine radiographic examination. The radicular radiolucency associated with primary teeth is usually neglected because of their short life span which usually resolve on their own following the extraction/exfoliation of related tooth. Periapical radiolucency of primary teeth may be misdiagnosed as a chronic apical periodontitis or a dentigerous cyst of the permanent successor due to inadequate pathological investigation after extraction/exfoliation of the primary teeth (7). An association of cyst development in relation to the mandibular second primary molars having carious lesions or endodontically treated has been mentioned in literature (9). The mandibular second primary molar is more closely associated with its successor's follicle and this can more easily facilitate the spread of inflammation in comparison with other primary teeth.

Aetiology for radicular cyst associated with primary teeth is invasion of bacteria from necrotic pulp to the periapical region stimulating the multiplication of epithelial cell remnants of

Malassez where as in endodontically treated cases, medicaments used for pulp therapy becomes antigenic in combination with tissue protein, eliciting a humoral and cell-mediated immune responses (5). Hill *et al*, Grundy *et al*, Bhat SS *et al*, Elango *et al* have reported cyst cases associated with formocresol as intra canal medicaments(3). Sandhyarani B *et al* (10) and Truong-Nhu-Ngoc *et al* (3) showed cases of cysts involved in primary teeth with a history of endodontic treatment with zinc oxide eugenol and gutta percha (as successor was missing) respectively. The etiology behind the cysts could be antigenic stimulus either because of infection left behind during pulpectomy procedure or the zinc oxide eugenol material. Other materials reported in literature are creosote, iodoform and arsenic oxide. It is controversial as to whether the treatment of dental pulp is a causative factor in the development of radicular cysts of the primary teeth. There are studies contradicting that radicular cysts were not related to the treatment of dental pulp (8,11). **In this case**, no records were available regarding the pulpectomy procedure or the material used as it was done from another clinic.

Grundy *et al* (5) recorded a time lapse of 5 months to 3 years between the pulp therapy and the detection of buccal bone expansion with an average of 20 months. In this child the cyst was diagnosed after a time period of 6 years since pulpectomy. The swelling went unnoticed as it was asymptomatic. This study supports the findings of Grundy *et al* and Savage *et al*, that specific clinical features such as large size, rapid growth, buccal expansion, and displacement of succedaneous teeth are associated with cysts seen in relation to endodontically treated primary teeth. Radicular cysts of the primary teeth involving radiolucent areas of more than 20 mm in diameter appear to be rare, and it is possible that pulpal therapeutic agents cause rapid growth of cystic lesions (12). **Here, the cyst** was 50mm*25 mm size at the time of initial presentation.

Chavan *et al* from their findings and literature suggested criteria for differentiating radicular and dentigerous cysts related to primary teeth. Features of radicular cyst are carious or endodontically treated primary molar; more chances of signs of infection, radiolucency around the roots and furcation area of involved teeth, complete premolar tooth bud looks engulfed in the lesion on OPG. And for dentigerous cyst, no carious lesion with primary molar; severe displacement of involved developing premolar as well as adjacent premolar; radiographically. After excision, lesion looks typically around premolar crown, even if it is displaced (1). In the present study, the involved tooth was endodontically treated 75 with expansion of buccal cortical plate. Premolar tooth bud looked engulfed in the lesion with no displacement as seen on OPG which fulfilled the mentioned criteria for radicular cyst.

Treatment options for a radicular cysts involving primary teeth include extraction of the involved primary tooth or extraction and then decompression of the cyst, lesion marsupialization or enucleation. The selection of the most appropriate treatment depends on various factors, including the cyst's location, size, the integrity of the cystic wall, and its proximity to vital anatomical structures. **Cystostomy** of the large cyst has drawbacks like reducing bone support, destroying the inner blood vessels and nerves that feed the teeth, adjacent to the surgical site, damaging the mental foramen, lower alveolar nerve branch, and/or anatomical structures such as the artery, nasal cavity, and maxillary sinus, the formation of anatomical defects, and postoperative pain (13). Hence, it may not be appropriate for a pediatric patient. Pei *et al*. conducted a retrospective study and concluded that decompression is an effective and less invasive treatment in radicular cysts associated with primary teeth (14). So the cystic lesion in this case was treated with extraction of the pulpectomized primary tooth and decompression of the cyst rather than of the entire cyst, as the margins of the cyst were seen extending to the lower border of the mandible. The succedaneous tooth, 35, was seen to be in a favorable position for spontaneous eruption, though slightly rotated and locked under the tipped 34 and 36. Here space had to be

regained for facilitating the eruption of the succedaneous tooth, 35. The shape memory property of Nickel -Titanium wire was utilised to regain the lost arch space. The other advantages of this space regainer are single visit chairside procedure, no banding or any other complicated lab procedure, improved patient compliance and easy maintenance of oral hygiene. 3 mm of lost space was regained within 8 weeks, similar to that reported in studies by Jana *et al* and An *et al* (15) (16).

There are currently no objective criteria to assess healing after decompression cases (17). Nonetheless, research suggests that radiographic characteristics such as altered densities within the lesion, trabecular structure reconstruction, lamina dura formation in the apical region, asymptomatic tooth formation during clinical examination, and the appearance of healthy soft tissues may indicate the effectiveness of treatment (13).Decompression was found to be effective in this case as new bone formation was noted within the cystic lesion with trabecular structure reconstruction ,lamina dura formation in the apical region of 34, 35, and 36 in OPGs taken at 4th and 12th month follow-up.Pei *et al* has reported that all lesions with mean initial area of $3.66 \pm 2.00 \text{ cm}^2$ were reduced after decompression within 2 to 10 months. Mean rate of reduction was $0.77 \pm 0.44 \text{ cm}^2/\text{month}$ and large lesions ($> 3.5 \text{ cm}^2$) had higher reduction rate compared to smaller ones. In this case bone formation in cystic lesion was achieved in 4 months. Mean decompression time in patients < 18 years old is significantly less than that of adults which implies higher osteogenic activity in children (18) (14).

Long-term follow-up of succedaneous teeth after treatment for cysts of primary teeth was recommended by Pei *et al*. In his study, 46% of teeth had root development problems such as ectopic eruptions, wide root canals, insufficient dentin deposition, and root dilacerations upon eruption.Here 35 erupted in a slightly rotated position and showed a root dilaceration at the apical third. Decompression procedures have been criticized for leaving residual pathological tissue in place, which can lead to recurrence. Although inflammatory cysts do not recur after adequate treatment (19), to address recurrences, strict follow-up is recommended, and secondary enucleation may be required (17). Hence child is still under follow up and further orthodontic treatment is being planned.

CONCLUSION

Endodontically treated primary teeth should be observed until they are shed as there is a chance for the chronic inflammation in the periapical region leading towards cyst formation. If any signs of failures of pulp therapy, such as peri-radicular rarefaction, root resorption, and enlarged follicular space of the succedaneous tooth is seen, it should be treated by extraction. Follow-up should be maintained until normal eruption of the succedaneous tooth. Though radicular cysts involving primary teeth are rare, it can be seen associated with non-vital or endodontically treated primary teeth. Extraction of the involved teeth and decompression of the cyst is an effective and less invasive treatment option for radicular cyst involving primary teeth in pediatric patients.

CONSENT

As per international standards, parental written consent has been collected and preserved by the author(s).

ETHICAL APPROVAL

As per international standard or university standard guideline participant consent and ethical approval has been collected and preserved by the authors.

ABBREVIATIONS

OP – Out Patient

OPG – Orthopantomogram

Disclaimer (Artificial intelligence)

Author(s) hereby declare that NO generative AI technologies such as Large Language Models (ChatGPT, COPILOT, etc.) and text-to-image generators have been used during the writing or editing of this manuscript.

REFERENCES

1. Chavan A, Dewalwar V, Manekar VS, Wadde K. Cysts in Periradicular Region of Deciduous Molars in Mixed Dentition: Retrospective Study of Five Cases. *International Journal of Clinical Pediatric Dentistry*. 2014 Dec;7(3):229–35.
2. Asián-González E, Pereira-Maestre M, Conde-Fernández D, Vilchez I, Segura-Egea JJ, Gutiérrez-Pérez JL. Dentigerous Cyst Associated with a Formocresol Pulpotomized Deciduous Molar. *Journal of Endodontics*. 2007 Apr;33(4):488–92.
3. Truong-Nhu-Ngoc V, Vu-Thai-Lien N, Minh-Hang L, Thanh-Tung D, Thi-Nga V, Pham-The H, et al. Radicular cyst in a primary molar following pulp therapy with gutta percha: A case report and literature review. *J Clin Exp Dent*. 2019;0–0.
4. Talukdar M, Kumar A, Goenka S, Mahajani M, Ambhore M, Tattu V. Management of radicular cyst in deciduous molar: A case report. *J Family Med Prim Care*. 2020;9(2):1222.
5. Grundy GE, Adkins KF, Savage NW. Cysts associated with deciduous molars following pulp therapy. *Australian Dental Journal*. 1984 Aug;29(4):249–56.
6. Chiu WK, Sham ASK, Hung JNM. Spontaneous alignment of permanent successors after enucleation of odontogenic cysts associated with primary teeth. *British Journal of Oral and Maxillofacial Surgery*. 2008 Jan;46(1):42–5.
7. Goswami M, Chauhan N. Radicular Cyst with Primary Mandibular Molar: A Rare Occurrence. *International Journal of Clinical Pediatric Dentistry*. 2023 Nov 10;16(5):769–73.

8. E M, I K, A H. A clinical and histopathological study of radicular cysts associated with primary molars. *Journal of oral pathology & medicine* : official publication of the International Association of Oral Pathologists and the American Academy of Oral Pathology [Internet]. 1995 Nov [cited 2024 Jan 11];24(10). Available from: <https://pubmed.ncbi.nlm.nih.gov/8600282/>
9. Lustig JP, Schwartz-Arad D, Shapira A. Odontogenic cysts related to pulpotomized deciduous molars Clinical features and treatment outcome. *Oral Surgery, Oral Medicine, Oral Pathology, Oral Radiology, and Endodontology*. 1999 Apr;87(4):499–503.
10. Sandhyarani B, Noorani H, Shivaprakash P, Dayanand Ah. Fate of pulpectomized deciduous teeth: Bilateral odontogenic cyst? *Contemp Clin Dent*. 2016;7(2):243.
11. Nagata T, Nomura J, Matsumura Y, Yanase S, Fujii T, Oka T, et al. Radicular cyst in a deciduous tooth: a case report and literature review. *J Dent Child (Chic)*. 2008;75(1):80–4.
12. Sakurai A, Taniguchi Y, Hayashibara T, Senzui S, Homma H, Hashida T, et al. Two cases of less invasive treatment for radicular cyst in primary dentition. *Pediatric Dental Journal*. 2011;21(1):78–84.
13. Zan R. Nonsurgical Endodontic Treatment Of A Large Periradicular Lesion. *Turk Endod J* [Internet]. 2017 [cited 2024 Oct 16]; Available from: https://www.journalagent.com/tej/pdfs/TEJ_2_1_21_24.pdf
14. Pei J, Zhao S, Chen H, Wang J. Management of radicular cyst associated with primary teeth using decompression: a retrospective study. *BMC Oral Health*. 2022 Dec 1;22(1):560.
15. Jana DD, Chakraborty DA, Dey DB, Jana DS, Roy DN, Nandi DB. NITI-LIGHT CURE COMPOSITE SPACE REGAINER: A CASE REPORT. 9(10).
16. An H, Kim S, Choi N. Minor Orthodontic Treatment Using NiTi Wire Exerting Light Force: Case Reports. *J Korean Acad Pediatr Dent*. 2022 Nov 30;49(4):505–13.
17. Umer F, Javed F. Decompression strategy for critical-sized lesions: A case series and literature review. *Aust Endodontic J*. 2021 Dec;47(3):731–40.
18. Anavi Y, Gal G, Miron H, Calderon S, Allon DM. Decompression of odontogenic cystic lesions: clinical long-term study of 73 cases. *Oral Surg Oral Med Oral Pathol Oral Radiol Endod*. 2011 Aug;112(2):164–9.
19. Penumatsa NV, Nallanchakrava S, Muppa R, Dandempally A, Panthula P. Conservative Approach in the Management of Radicular Cyst in a Child: Case Report. *Case Reports in Dentistry*. 2013;2013:1–3.

UNDER PEER REVIEW