

Case report

X-LINKED RETINITIS PIGMENTOSA REVEALED BY TAPETAL LIKE REFLEX : WHEN YOU ALL NEED FOR DIAGNOSIS IS A FUNDUS PICTURE- A CASE REPORT AND LITTÉRATURE REVIEW

ABSTRACT

The tapetal-like reflex (TLR) is a rare, golden, bright, scintillating, particulate reflection observed during indirect ophthalmoscopy, typically sparing the fovea. It resembles the reflection seen in the eyes of certain vertebrates (1). TLR has been noted in female carriers of X-linked retinitis pigmentosa (RP) and has also been observed in a healthy young male. (2)

INTRODUCTION

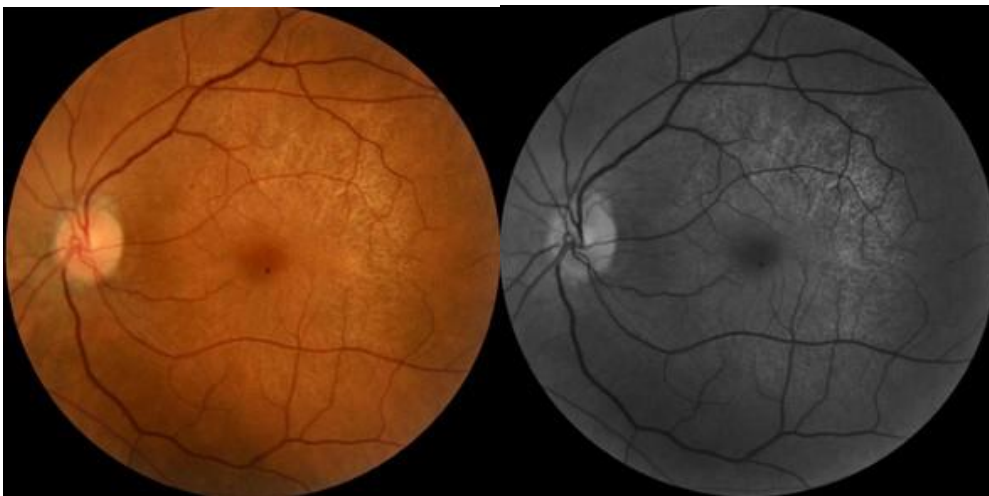Retinitis pigmentosa (RP) refers to a group of inherited retinal disorders characterized by the gradual degeneration of rod and cone photoreceptors, (3) leading to vision loss. These conditions are genetically diverse, with more than 100 genes linked to their development. (4) Retinal function typically deteriorates, as measured by electroretinography, long before individuals experience symptoms such as night blindness, visual field defects, or reduced visual acuity. (5,6)

X-linked retinitis pigmentosa (XLRP) is caused by mutations in the RPGR gene, located on the X chromosome. RPGR encodes a GTPase-binding protein that plays a crucial role in photoreceptor cells. (7) It is localized in the connecting cilium, a structure that links the inner and outer segments of photoreceptor cells, and is involved in regulating cargo transport between these segments. (8)

Case Report

We report the case of a 45-year-old woman who presented with complaints of decreased vision in her left eye (LE). Her best-corrected visual acuity was 10/10 in the right eye (RE) and 06/10 in the left eye. The anterior segment examination of both eyes (BEs) was unremarkable. There was no history of night blindness or vision problems among family members. Fundus examination revealed retinal pigment epithelial (RPE) hypopigmentation and atrophy at the posterior pole, along with an enhanced golden tapetal sheen in the posterior pole of the left eye (Figure 1A). Fundus autofluorescence showed a crescent-shaped hyperautofluorescence in the LE (Figure 1B). Spectral-domain optical coherence tomography (SD-OCT) revealed a normal foveal contour in the left eye, with thinning of the photoreceptor layer at the macula and small drusen (Figure 2). Based on these multimodal imaging findings, we suspected early manifestations of retinitis pigmentosa. Genetic analysis confirmed a mutation in the X-linked RPGR/RP3 gene. The patient was advised to undergo observation and routine follow-up.

Comment [J1]: Family history should be mentioned before examination findings



A

B

FIGURE 1

A : fundus photo showing tapetal like reflex in left eye

B : fundus autofluorescence showing hyperreflectivity of the posterior pole by atrophy starting of the retinal pigmented epithelium

Comment [J2]: It is not the picture of autofluorescence, It is red free photo of retina

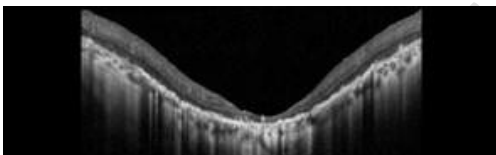


FIGURE 2 : macular oct of left eye showing extreme thinning of photoreceptor layer with small drusens

Comment [J3]: OCT capital letter, drusewn should be marked in figure

DISCUSSION

TLR has been observed in female carriers of X-linked retinitis pigmentosa (XLRP) and has also been noted in a healthy young male. (3) Abnormal fundus reflections in male patients have been reported in conditions like Oguchi disease, X-linked retinoschisis, cone-shaped retinal dystrophy, and early-stage XLRP. TLR typically appears beneath the retinal vasculature, at the level of the outer retina and retinal pigment epithelium (RPE). (3) This may result from deposits, thickening, or degeneration of Bruch's membrane, retinal deposits, or changes at the RPE-photoreceptor interface. In this study, we report an enhanced TLR in the midperiphery of a patient with sector retinitis pigmentosa (RP), supporting its association with inherited retinal degenerations. However, the exact cause and origin of this phenomenon remain unclear, and further research is needed to better understand this unique observation.

The global prevalence of RP ranges from 1 in 3,000 to 1 in 7,000, including both simple and syndromic forms of the disease. While there is generally no gender preference, males are slightly more affected than females due to X-linked RP, as observed in our patient. RP does not have ethnic specificity, but certain forms related to specific gene mutations are more

common in consanguineous populations, such as the USH3 gene associated with Usher syndrome type III. (9)

Most cases of retinitis pigmentosa are monogenic, yet the disease remains genetically diverse. (10) At least 45 loci have been identified where mutations cause RP, and these genes account for the disease in just over half of all cases. (11) Since the first report linking an RP locus to a DNA marker on human chromosome X in 1984, (12) more than 40 genes have been associated with the condition. Non-syndromic or "simple" RP cases can be inherited in autosomal dominant (20-25%), autosomal recessive (15-20%), X-linked recessive (10-15%), or sporadic/simple (30%) patterns, with 5% being early-onset cases classified as Leber congenital amaurosis (LCA). Rarer forms of RP include X-linked dominant, mitochondrial, and digenic inheritance (involving mutations in two different genes). (9) XLRP is due to mutations in six genes located on the X chromosome, but only two have been identified so far: the retinitis pigmentosa GTPase regulator (RPGR) and the RP2 protein (RP2). (13) Mutations in these two genes are responsible for 80% of clinical cases of XLRP, making them good targets for small molecule drug and gene therapy approaches. (14)

CONCLUSION

Tapetal like reflex is frequently an incidental fundoscopic finding associated with many retinal diseases like XLRP and may appear years before symptoms and vision loss.

Well understanding of the phenotypes and genes included in RP is the key to be more efficient in developing new treatments of the disease including gene specific approaches, transplantation replacing retinal loss tissue and implanting electrical devices.

REFERENCES

- 1-Kalitzeos A, Samra R, Kasilian M, et al. Cellular imaging of the tapetal-like reflex in carriers of RPGR-associated retinopathy. *Retina* 2019;39:570–80.
- 2- Schatz P, Bregnhøj J, Arvidsson H, et al. A tapetal-like fundus reflex in a healthy male: evidence against a role in the pathophysiology of retinal degeneration? *Mol Vis* 2012;18:1147–55
- 3- Meindl A, Dry K, Herrmann K, Manson F, Ciccodicola A, Edgar A, Carvalho MR, Achatz H, Hellebrand H, Lennon A, Migliaccio C, Porter K, Zrenner E, Bird A, Jay M, Lorenz B, Wittwer B, D'Urso M, Meitinger T, Wright A (May 1996). "A gene (RPGR) with homology to the RCC1 guanine nucleotide exchange factor is mutated in X-linked retinitis pigmentosa (RP3)". *Nature Genetics*. 13 (1): 35–42. doi:10.1038/ng0596-35. PMID 8673101. S2CID 31695757.
- 4- Roepman R, van Duijnhoven G, Rosenberg T, Pinckers AJ, Bleeker-Wagemakers LM, Bergen AA, Post J, Beck A, Reinhardt R, Ropers HH, Cremers FP, Berger W (Jul 1996). "Positional cloning of the gene for X-linked retinitis pigmentosa 3: homology with the guanine-nucleotide-exchange factor RCC1". *Human Molecular Genetics*. 5 (7): 1035–41. doi:10.1093/hmg/5.7.1035. hdl:2066/22748. PMID 8817343.
- 5- Murga-Zamalloa CA, Atkins SJ, Peranen J, Swaroop A, Khanna H (Sep 2010). "Interaction of retinitis pigmentosa GTPase regulator (RPGR) with RAB8A GTPase: implications for cilia dysfunction and photoreceptor degeneration". *Human Molecular Genetics*. 19 (18): 3591–8. doi:10.1093/hmg/ddq275. PMC 2928130. PMID 20631154. Jump up to:^a ^b "Entrez Gene: RPGR retinitis pigmentosa GTPase regulator".

- 6-Khanna H (October 2015). "Photoreceptor Sensory Cilium: Traversing the Ciliary Gate". *Cells*. 4 (4): 674–86. doi:10.3390/cells4040674. PMC 4695852. PMID 26501325.
- 7- Churchill JD, Bowne SJ, Sullivan LS, Lewis RA, Wheaton DK, Birch DG, et al. (February 2013). "Mutations in the X-linked retinitis pigmentosa genes RPGR and RP2 found in 8.5% of families with a provisional diagnosis of autosomal dominant retinitis pigmentosa". *Investigative Ophthalmology & Visual Science*. 54 (2): 1411–6. doi:10.1167/iovs.12-11541. PMC 3597192. PMID 23372056.
- 8-Glomset JA, Farnsworth CC (1994). "Role of protein modification reactions in programming interactions between ras-related GTPases and cell membranes". *Annual Review of Cell Biology*. 10: 181–205. doi:10.1146/annurev.cb.10.110194.001145. PMID 7888176.
- 9- Stefano Ferrari¹, Enzo Di Iorio¹, Vanessa Barbaro¹, Diego Ponzin¹, Francesco S. Sorrentino² and Francesco Parmeggiani²
- 10-Hartong, D. T., Berson, E. L., & Dryja, T. P. (2006). Retinitis pigmentosa. *The Lancet*, 368(9549), 1795–1809. doi:10.1016/s0140-6736(06)69740-7
- 11--Hardcastle AJ, Thiselton DL, Zito I, et al. Evidence for a new locus for X-linked retinitis pigmentosa (RP23). *Invest Ophthalmol Vis Sci* 2000; 41: 2080–86.
- 12-Gorbatuyk, M.S, Knox, T, La Vail, M.M, Gorbatuyk, O.S ; Lewin, A.S, Restoration of visual fonction in P23H rhodopsin transgenic rats by gene delivery of *bip/grp78*, *proc.natl.acad,sci USA* 2010
- 13-Vettel.S, Wittinghoffer, A. RPGR and RP2 : targets for the treatment of x-linked Retinitis pigmentosa ? *Expert.Opin.Ther.Targets* 2009, 13(10), 1239-1251
- 14-Vervoort.R ; Lenon, A. ; Bird, A.C ; Tulloch, B ; Axton, R ; Miano, M.G, Mutational hotspot within a new RPGR exon in X-linked retinitis pigmentosa m. *Nat, Genet* 2000, 25(4), 462-466