

Original Research Article

A study of adult male circumcision (MC) using a circular stapler

Abstract

Background: Male circumcision (MC) is defined as the surgical removal of the foreskin from the penis. A new device for circumcision, called a circular stapler, has been developed for commercial purposes. It consists of two components: an inner bell meant to shield the glans and an outer bell that includes a circular blade for cutting the foreskin and staples to secure the wound for hemostasis.

Aims: study of adult male circumcision (MC) using circular stapler.

Objectives: The main objective of the research on adult male circumcision (MC) employing a circular stapler regarding operation duration, pain levels, blood loss, healing duration, patient satisfaction, postoperative stay, and postoperative complications.

Methodology: A study was conducted on 20 patients and data was collected based on detailed history, systematic clinical examination, pre-op investigation, period of procedure, period of hospital stay, and post-op complications were recorded.

Result: In study of 20 patients with circumcision 2 patients have phimosis, 8 have recurrent balanoposthitis and 6 have recurrent UTI ,13 patients have sexual satisfaction , average operating time was 6.8 min, average bloodless is 1.8ml, average pain score is 4, average healing time is 12.5 days, average hospital stay 2.2 day ,

Conclusion: Stapler circumcision reduce operative time, reduce pain score, reduce bloodloss, reduce postop stay, reduce postop complications, and increase healing time

Key words: circumcision, circular stapler, male

Introduction

The process of male circumcision (MC) involves the surgical removal of either some or all of the foreskin on the penis. It is one of the most common surgical procedures in the world. It has been practiced since as early as 4000 BCE.

In the US it is a common surgical procedure to carry out during the first few weeks of life. Male circumcision (MC) was one of the first surgical techniques that mankind has known. This procedure may reduce the transmission risk of sexually transmitted diseases such as human papilloma virus, genital ulcer disease and infection with human immunodeficiency virus (HIV) [1].

Furthermore, it enhances penile application care and minimizes the chances of acquiring balanitis and penile cancer. The World Health Organization has recommended three conventional methods of MC; “these are the dorsal slit, the forceps guided method and sleeve resection of the foreskin. Infact, blood loss, swelling and its unsatisfactory cosmetic effect still remain as complications to many of these patients undergoing Male circumcision (MC)”, besides, ordinary Male circumcision (MC) is laborious [2].

Recent years have seen the global use of Shang Ring that originated in China. The application of this device makes it possible to shorten the operation time, reduce blood loss, and minimize the amount of surgery and its complications following it. Nevertheless, application of the Shang Ring does have some disadvantages: longer time is required for scar maturation, the patient suffers pain for around a week has to 16 days for the ring to be removed, and since removal of the ring involves no sutures, partial separation of the edge of wound after the ring removal is quite common [3].

In China, there has been the introduction of a new disposable circumcision device called the circular stapler, which has two distinguishing parts. It has an inner and outer bell. The inner bell is designed to shield the glans. The outer bell has a circular blade that cuts away the foreskin as well as staples that are used to seal the cut for hemostasis to take place without any delay.

Aim and Objective;

The principal aim of the study is to evaluate adult male circumcision (MC) using a circular stapler.

The main objective of the research on adult male circumcision (MC) employing a circular stapler regarding operation duration, pain levels, blood loss, healing duration, patient satisfaction, postoperative stay, and postoperative complications.

Methodology

Study design: Prospective observational type of study

Study site: Department of general surgery at SMT SMS Multispecialty hospital, Ahmedabad

Data source: Patients hospitalized at SMS Hospital with cases of Phimosis, balanoposthitis, recurrent balanoposthitis, balanitis xerotica obliterans (BXO), and recurring urinary tract infections (UTI).

Sample size: 20 adult male of stapler circumcision.

Criteria for Inclusion; spiritual or ethnic, balanitis xerotica obliterans, phimosis, balanoposthitis, persistent balanoposthitis, frequent urinary tract infections, and male over 18 years old

Criteria for Exclusion; hypospadias, concealed penis, any sexually transmitted infections (STD), paraphimosis, and male under 18 years old

A prospective randomized clinical trial served as the study's foundation. Every instance that met the inclusion criteria was added to the study. Using a standard, semistructured, prevalidated case paper proforma, data was obtained from a thorough history of the patient, systematic clinical examination, routine pre-op investigations, procedure period, hospital stay, total cost, post-operative analgesia, and post-operative immediate and delayed complications. Procedure steps (1-9) mention below.

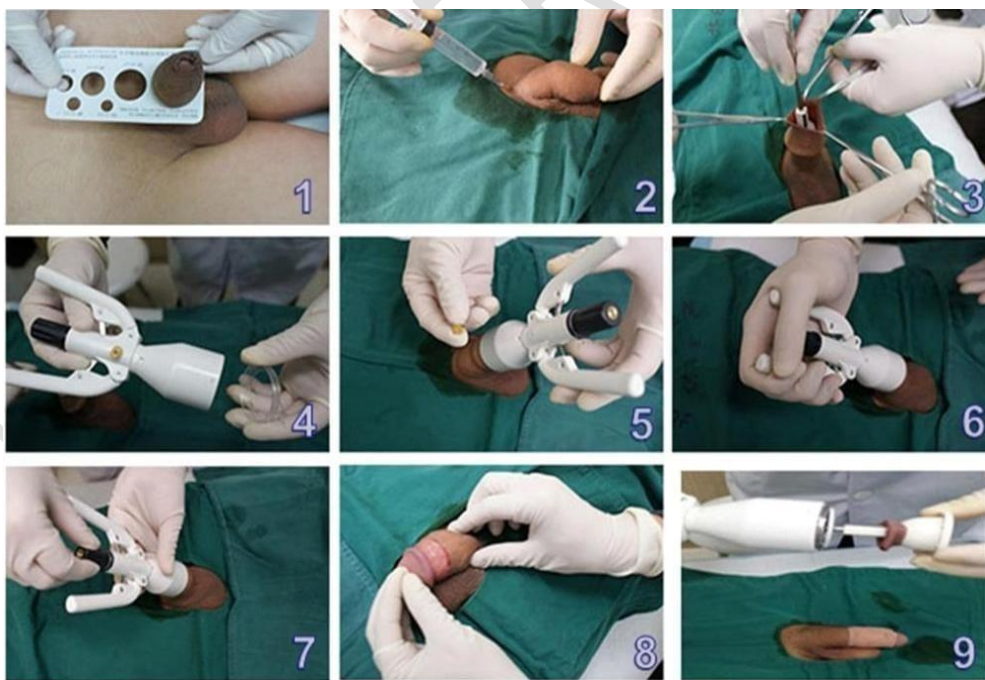

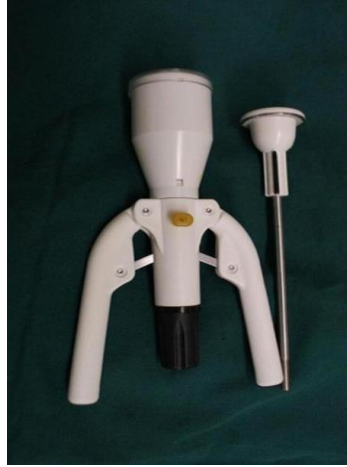


Figure 1: Device use for the study

- To choose the right size for the stapling device, the penis is measured immediately below the glans.
- After scrubbing the penis with povidone iodine a dorsal penile nerve block and circumferential block are performed with one percent lidocaine.
- The inner bell is situated within the foreskin to shield the glans; the rim of the bell aligns with the coronal sulcus. In cases of severe phimosis in the patient a dorsal slit should be performed to properly place the inner bell.
- The protective shield is taken off the external bell.
- The inner bell is covered by the outer bell. The frenulum must remain unbroken. The safety pin is subsequently taken out.
- The screw is turned clockwise to firmly compress the foreskin; the handles are activated to sever the foreskin while simultaneously closing the wound with staples.
- The appliance is unscrewed and taken off.
- The injury on the foreskin is examined and applied with gauze piece for 1 to 2 minutes to cessation any bleeding.
- Hemostasis is attained with a compression wrap.

Result

Distribution of age;

In current research we evaluated the age distribution of the study population. We noted that most of the study participants were in the age range of 26 to 35 years (40%), with the next group being 36 to 45 years (20%) [Figure - 2].

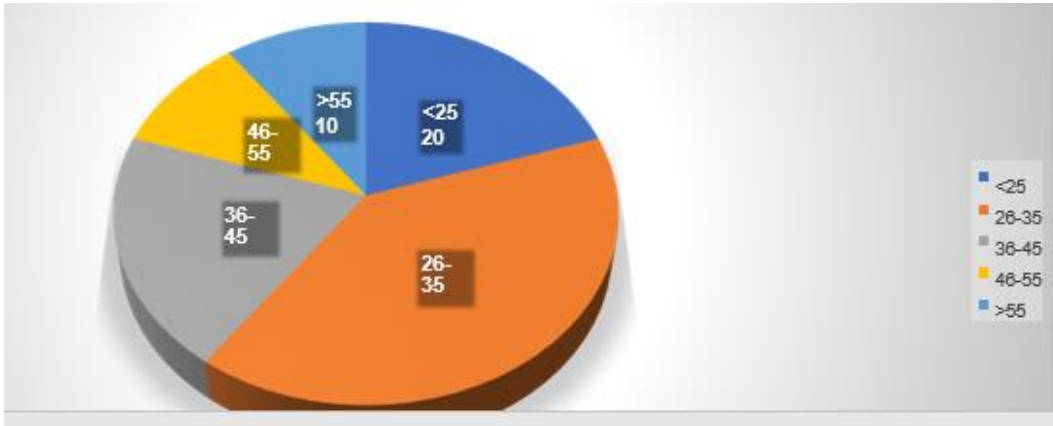


Figure 2: Pie chart showing age distribution

Diagnosis;

In the present study, we evaluated the Diagnosis within the study participants. We noted that Balanitis Xerotica Obliterans (BXO) was noted in 4 individuals, congenital phimosis was noted in 2 individuals, recurrent balanoposthitis was noted in 8, and recurring UTI was noted in 6 individuals [Figure -3].

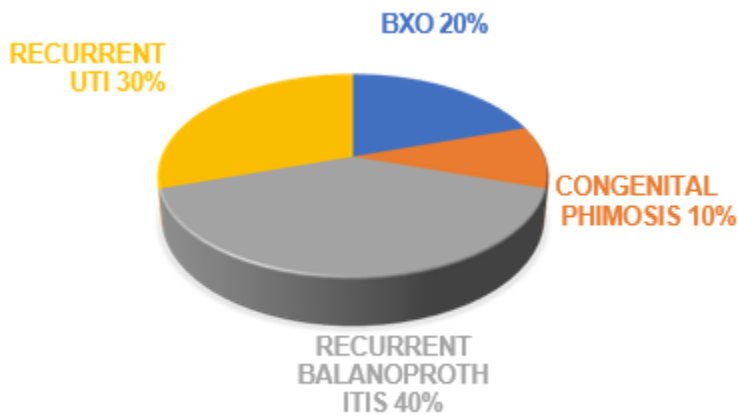


Figure 3: Pie chart showing treatment diagnosis

Sexual gratification;

In present research, we evaluated sexual satisfaction within the study population. We found that 65% of patients experience sexual satisfaction.

Intra-operative factors;

In the current study we assessed intra-operative constraints among the study population. We observed that mean operating period was 6.8 min, Mean blood loss was 1.8 ml, Mean Pain score was 4 [Table 1].

Table 1: Intra operative parameters

Parameters	Patient group	Significance
Mean Operating time	6.8 ± 1.5 min	t value = 18.66649 p value < 0.00001

Mean Blood loss	1.8 ± 0.68 ml	t value = 19.86633 p value < 0.00001
Mean Pain score	4 ± 0.70	t value = 6.23149 p value < 0.0001

“The result is significant by p <0.05”

Post-operative factors;

In this study we have evaluated postoperative factors among the participants. We noted that the average healing time was 12.5 days; average satisfaction was 92%, and postoperative hospital stay was 2.2 days [Table 2].

Table 2: Post-operative parameters

Parameters	Patient group	Significance
Mean Healing time	12.5 ± 1.05 days	t value = 5.06803 p value = 0.00001
Mean Satisfaction	92 ± 1.77 %	t value = 3.1225 p value = 0.00231
Post-operative hospital stay	2.2 ± 0.43 days	t value = 6.94022 p value < 0.0001

“The result is significant by p <0.05”

Complication:

In this study we evaluated complications experienced by the participants. We noted that 15% of cases experience complications such as postoperative edema, 10% bleeding, 0% wound dehiscence, and 5% postoperative infection [Figure 4].

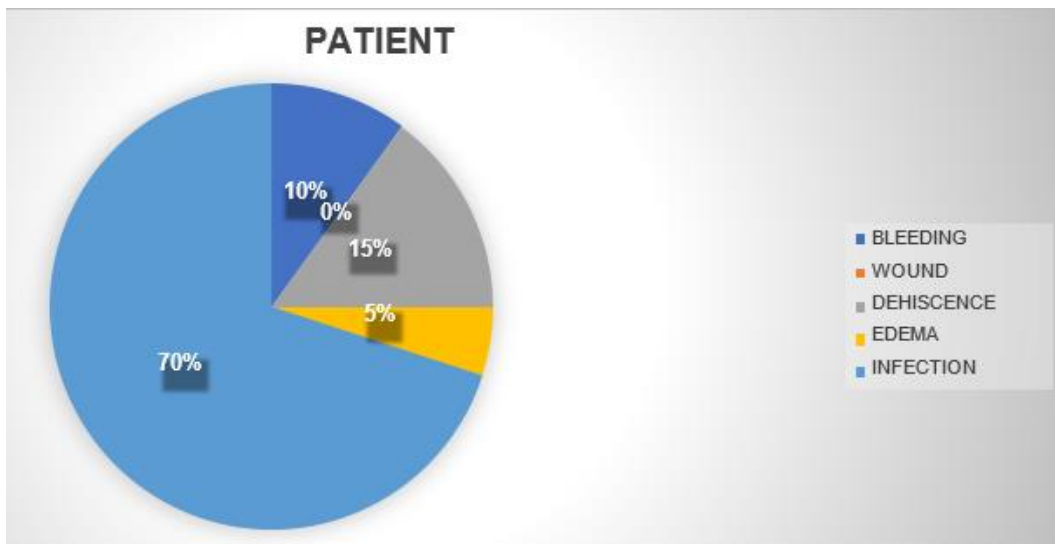


Figure 4: Pie chart showing patient complications

Discussion

Male circumcision (MC) is a common and prevalent manifestation in the childhood of boys in many communities around the world today. Nonetheless, there is a lack of suitable and adequate scientific understanding regarding this phenomenon and its complex aspects [4].

Male circumcision (MC) involves the surgical removal of the foreskin-prepuccial skin from the penis. The World Health Organization-WHO indicates that worldwide estimates show that 30% of men are circumcised. In India, the incidence of circumcision amongst the general populace is roughly 33%. The majority of circumcisions are carried out in adolescence due to cultural or religious motivations [5].

The circular stapler is a novel instrument employed for executing circumcision. It was developed for commercial use in China and is utilized in several Chinese hospitals. Consistent with research conducted by Yuan et al., our findings indicate that using a stapler for MC offers several benefits: reduced operative duration, slight discomfort, and a low amount of blood loss, similar to that observed with another modern circumcision tool, the Chinese Shang Ring. Consequently, the stapler may also be suitable for high-volume environments by healthcare professionals with limited training and experience due to its ease of use, brief operative, and recovery durations. At present, the primary barrier to its broad adoption is expense. A reusable model of the circular stapler could be a potential solution [6].

MC is the procedure that urologists perform most often. Roughly 1.4 million MC procedures occur each year in medical facilities across the US. The WHO suggests three standard practices for carrying out circumcision, and these methods are utilized globally. Nevertheless, traditional circumcision does have certain limitations: it necessitates training, it can lead to a significant complication rate,

particularly in some African nations where it is frequently carried out by inadequately trained and poorly equipped medical personnel; and it is time-consuming, even when conducted by skilled surgeons, which complicates the scaling up of medical interventions for HIV prevention in Africa. The circular stapler is a novel instrument utilized for carrying out circumcision [7].

It was commercially produced in China and is utilized in a few Chinese hospitals. According to research conducted by Yuan et al., the stapler can also be utilized in high-volume environments by healthcare providers who have limited training and experience, due to its ease of use and brief operative and recovery durations. At present, its primary obstacle to widespread adoption is expense. A reusable variant of the circular stapler could be an answer. Our research indicates that stapler circumcision results in fewer complications compared to traditional circumcision, particularly regarding severe swelling and wound separation. The benefits of stapler circumcision could be attributed to the brief surgical duration, limited tissue damage, and absence of electrocautery [8, 9].

A comparison of complication frequencies among studies has been hindered by varying research methodologies and a lack of standardization. Drawing from our experience and existing literature. We think that the stapler retains certain benefits compared to the Shang Ring. Initially, the foreskin is entirely severed with the stapler, resulting in reduced discomfort post-surgery. Conversely, patients who have circumcision using the Shang Ring endure pain for 7 to 16 days until the ring is taken off. According to patients' self-reports, this postoperative pain may be extremely intense when spontaneous or nighttime erections happen [10]. Secondly, individuals receiving stapler circumcision experience a reduced healing period compared to those treated with the Shang Ring. The foreskin is removed through necrosis, resulting in a somewhat ischemic border. Third, patients who have stapler circumcision experience reduced wound dehiscence. Patients undergoing treatment with the Shang Ring have a higher likelihood of wound dehiscence since no sutures are applied around the wound. Wound dehiscence typically arises when there is a spontaneous or nighttime erection. Nevertheless, these benefits ought to be examined further in a properly structured head to head randomized clinical trial. In certain countries, circumcision in children is primarily conducted for religious purposes. A study indicated that neonatal MC is economically beneficial for preventing diseases [11]. The circular stapler described here could eventually be used on children and infants due to its ease of use and quick operation and recovery periods.

Conclusion

The most common presentations among the patients were Balanitis Xerotica Obliterans, recurrent balanoposthitis (BXO), recurring UTI, and inborn phimosis. The stapler circumcision is a simple and straightforward method for conducting male circumcision (MC). It is linked to a reduced operative duration, lesser blood loss, and a decrease in postoperative complications. This innovative method could significantly simplify and standardize circumcision practices.

Ethical Approval:

As per international standards or university standards written ethical approval has been collected and preserved by the author(s).

Consent

As per international standards or university standards, patient(s) written consent has been collected and preserved by the author(s).

Disclaimer (Artificial intelligence)

Author(s) hereby declare that NO generative AI technologies such as Large Language Models (ChatGPT, COPILOT, etc.) and text-to-image generators have been used during the writing or editing of this manuscript.

References

1. circumcision male-trends 2.Circumcision Male-methods ISBN 978 92 4 159616 9 (WHO) ISBN 978 92 4 173633 1 (UNAIDS)
2. Siegfried N, Muller M, Deems JJ, Volmink J. Male circumcision (MC) for prevention of heterosexual acquisition of HIV in men. *Cochrane Database Syst Rev.* 2009 Apr 15 ;(2):CD003362. Doi: 10.1002/14651858.CD003362.pub2. PMID: 19370585.
3. Jada, R. M., Angara, N. R., & Janugade, H. B. (2022). A comparative study of conventional and sutureless circumcision. *International Journal of Health Sciences*, 6(S2), 301823028.
4. Ahmady. *Blade of Tradition in the name of Religion: A phenomenological investigation into male circumcision (MC) in Iran*. Technical and publication: Ghasem Ghareh-Daghi Published by: Avaye Buf; Available from: https://avayebuf.com/wp-content/uploads/2023/08/blade-of-tradition-final_avayebuf.pdf
5. Ritual male circumcision (MC) a brief history; medical aspects of circumcision *JR CollPhysians Edition* 2005:35:279-285 2005 Royal College of Physicians of Edinburgh
6. *Brazilian journal of medical and biological research* 2015 ISSN1414-431X Adult male circumcision (MC) with a circular stapler versus conventional circumcision: A prospective randomized clinical trial.
7. Wilcken A, Keil T, Dick B. Traditional male circumcision (MC) in eastern and southern Africa: a systematic review of prevalence and complications. *Bulletin of the World Health Organization.* 2010;88:907-14.
8. Yuea C, Ze-juna Y, Wua KR, Sua XJ, Hua JS, Maa JW, Guoa CM, Fanga HW, Sua R, Zhangb Y, Zhange QH. A Randomized Clinical Study of Circumcision with a Ring Device Versus Conventional Circumcision (Retraction of vol 188, pg 1849, 2012). *JOURNAL OF UROLOGY.* 2012 Dec 1;188(6):2443-10.
9. Wu X, Wang Y, Zheng J, Shen W, Yan JA, Ji H, Li X, Zhang H, Zhou Z. A report of 918 cases of circumcision with the Shang Ring: comparison between children and adults. *Urology.* 2013 May 1;81(5): 1058-63.11.
10. El Bcheraoui C, Zhang X, Cooper CS, Rose CE, Kilmarx PH, Chen RT. Rates of adverse events associated with male circumcision (MC) in US medical settings, 2001 to 2010. *JAMA pediatrics.* 2014 Jul 1;168(7):625-34.12.
11. Kim HH, Goldstein M. High complication rates challenge the implementation of male circumcision (MC) for HIV prevention in Africa. *Nature Clinical Practice Urology.* 2009 Feb;6(2):64-5.

UNDER PEER REVIEW