

Original Research Article

Sub Acute Toxicity Study of Mixed Fungal Culture Filtrates Isolated From Maize Stalks of Shivamogga District in Rats

ABSTRACT

Aim: To assess effects of the toxicity caused by consuming the fungal contaminated fodder by the cattle in the field conditions.

Study design: Study was conducted in 3 groups of Wistar Albino rats.

Place and Duration of Study: Department of Veterinary Pharmacology and Toxicology and Department of Veterinary Pathology, Veterinary College Shivamogga, Karnataka, between August 2024 to October 2024.

Methodology: A repeated-dose 28-days oral sub acute toxicity study was performed with three groups (n=6) of Wistar Albino rats. The group I (control) received oral gavage of potato dextrose broth @ dose of 2 mL/100g, where as groups II and III received mixed fungal culture filtrate of *Aspergillus flavus* and *Aspergillus niger* at the doses of 1 and 2 mL/100 g respectively.

Results: Treated groups (group II and III) showed increase in serological parameters (Aspartate Transaminase, Alanine transaminase, Creatinine, Blood urea nitrogen) and decrease in hematological parameters (PCV, Hb, TLC, TEC).

Conclusion: The findings of the present study inferred that the fungal culture filtrates of fungus isolated from contaminated maize stalk caused toxicity in rats, which was attributed for the presence of a toxic principle components in the fungal culture filtrates.

Keywords: [*Aspergillus flavus*, *Aspergillus niger*, toxicity study, rats]

1. INTRODUCTION

Livestock sector is most important subsector of agriculture. Animal husbandry provide livelihood support 2/3 of rural household. The Food and Agriculture Organization (FAO) has estimated that worldwide, about 25% of crops are affected annually with mycotoxins and hence the farmers should have awareness about fodder storage conditions to avoid contamination by any type of fungi or bacteria. Another point to consider is that, once there is contamination of fodder with mycotoxins there are no methods to remove it. Such type of contaminated fodder should not be fed to the animals. If fed, animals may show the symptoms of mycotoxicosis, which in turn will lead to reduction in the productivity and performance of the animals (Przystaś, 2013).

The primary factors influencing the production of mycotoxin in feedstuffs after harvest are temperature, water content, and insect activity. Environmental conditions such as high temperature and humidity increase the risk of fungal growth and mycotoxin production (Rodrigues, 2014). The Food and Agriculture Organization (FAO) has estimated that worldwide, about 25% of crops are affected annually with mycotoxins (Yu and Pedroso, 2023).

During the disease investigation process, peculiar symptoms were noticed in the cattle of dairy farms and other cattle at the Sominakoppa, Maisavalli and surrounding villages of Shivamogga district, Karnataka state. All the affected animals were exhibiting the clinical signs of loss of body condition, ruminal atony, dry and rough hair coat, decreased milk yield, feed refusal and gradual emaciation, dry muzzle, nasal discharge and abortions in pregnant cows. The detailed clinical investigation and history revealed that the dry maize stalks were fed to these animals had blackish spots or specks indicative of fungal infection. Hence, the present study was undertaken to evaluate the possible toxic potential of fungal contaminated maize stalks in rats.

2. MATERIAL AND METHODS

Fungal contaminated maize stalk fodder samples were collected from two dairy farms. Prior to performing mycological procedures, laboratory was fumigated with Potassium permanganate and formalin. The laminar airflow was UV sterilized. 25 ppm of streptomycin was added to the Potato Dextrose Agar (PDA) containing flask to avoid bacterial contamination and mixed well.

The PDA (10 mL) was poured into the sterilized Petri-plate in front of a Bunsen burner in the UV sterilized vertical laminar flow inoculation chamber. The Petri- plates were then allowed to cool for 30 min or until the media solidifies. Maize stalk parts were placed on prepared Petri plates in front of a Bunsen burner. The inoculation plates were incubated for 3-5 days at room temperature. In around 5 days, the fungal growth on the sample became visible. The fungal colonies were moved to another plate with PDA media and cultured for 5 days at 37°C, for obtaining pure isolates of fungi. The pure culture was inoculated into conical flasks with Potato dextrose broth. For optimal fungus growth, the flasks were kept at 37°C for 28 days. The mycelial-free content was decanted carefully into a new sterile container and used according to the preset protocol.

2.1 Identification of the fungi

Identification of the fungal species was done by molecular identification of the fungi species in the culture using Sanger sequence method (Petria Life Science, Bengaluru).

2.2 Sub-acute toxicity study in rats

In the present study, apparently healthy young Wistar albino rats in the age group of 6 to 7 weeks with the body weight ranging from 160 ± 20 g were used. The animals were obtained from Kedhar Biolabs, D.No.17-2-2-/2, Telugu Geri, Boyapally, Mahbubnagar, (Reg No: 2150/PO/Bt/S/2022/CCSEA). All animals were maintained as per the guidelines of the Committee for Control and Supervision of Experiments on animals, in the small animal house, Veterinary College, Shivamogga at controlled temperature of 22± 3 °C and relative humidity of 55 ± 5 % and 12 h light/dark cycle. The animals were acclimatized for one week prior to the actual experiment. The study was conducted following approval by the Institutional Animal Ethics Committee, Veterinary College, Shivamogga with the approval Number: No VCS/IAEC/SA-101/2024-25 Dated 30-08-2024.

2.3 Experimental design

Table 1: Groupings of experimental rats for sub-acute oral toxicity study of fungal contaminated maize stalk.

Sl. No	Groups	Animals per group	Treatment	Dosing
1	Group I	n=6	Control	Administered (<i>per os</i>) with potato dextrose broth(Dose: 2 mL/100 g)
2	Group II	n=6	Mixed fungal culture filtrates of <i>Aspergillus flavus</i> (50%) + <i>Aspergillus niger</i> (50%)	Administered (<i>per os</i>) with Mixed culture filtrate of <i>Aspergillus flavus</i> (50%) + <i>Aspergillus niger</i> (50%)(Dose: 1mL/100 g)
3	Group III	n=6	Mixed fungal culture filtrates of <i>Aspergillus flavus</i> (50%) + <i>Aspergillus niger</i> (50%)	Administered (<i>per os</i>) with Mixed culture filtrate of <i>Aspergillus flavus</i> (50%) + <i>Aspergillus niger</i> (50%)(Dose: 2mL/100 g)

The Subacute oral toxicity was conducted in Wistar Albino rats for a period of 28 days as per OECD guidelines (OECD No: 407).

2.4 Procedure

The mixed culture filtrate was gavaged based on the hypothesis that, in the field conditions, the animals might have consumed the maize stalks contaminated with *Aspergillus flavus* and *Aspergillus niger* in equal or different proportions. In order to know the interaction of the mycotoxins in rats, the different proportions of two identified fungi were used. The rats were weighed individually on Day 0, Day 14 and Day 28. The rats in each test group were gavaged with the PD broth fungal culture filtrate as a fungal infected material once daily for a period of 28 days (OECD, 2001; Vinay, 2007).

2.5 Clinical observations

General clinical observations were recorded daily. The health condition of the animals was recorded. Daily all the animals were observed for morbidity and mortality. At the end of the study, the animals were sacrificed humanely and necropsy was done and organs were collected for histopathological studies.

2.6 Clinical biochemistry

The purpose of this study was to look at the hazardous effects of fungal culture filtrate on vital organs of the body, viz., liver, heart and kidney functions. Blood was obtained from rats by retro-orbital plexus puncture approach using Micro Haematocrit Capillary tubes. Serum biochemical parameters were analyzed on day 0, 14 and 28th day using biochemical analyzer Alphachem Pro AVECON Semi Auto Biochemistry Analyzer and ALPHA LINE Clinical chemistry reagents by Alpha technologies. Using these the serum biochemical parameters viz., Alanine aminotransferase (ALT), Aspartate aminotransferase (AST), Creatinine (Cr) and Blood urea nitrogen (BUN) were estimated.

2.7 Clinical haematology

Present study was done to investigate the toxic effect of the fungal culture filtrate on different organs of the body especially on the liver, heart and kidney functions. The blood samples were drawn from rats by retro-orbital plexus puncture method using Micro-Hematocrit capillary tubes. Using automatic haematological analyzer. The haematological parameters viz., Haemoglobin (Hb), Total leukocyte count (TLC), Total erythrocyte count (TEC) and Packed cell volume (PCV) were estimated on day 0, 14 and 28th day.

2.8 Pathological study

At the end of the study period, all the survived experimental rats were humanely sacrificed and subjected to detailed postmortem examination and observed for any gross changes in the organs. For histological investigation, representative tissue samples of the liver, kidney, spleen, heart, lung and intestine (duodenum) were collected in 10% neutral buffered formalin (NBF).

2.9 Tissue processing

The collected tissues were treated using the paraffin embedding procedure for histological investigation. Using a microtome and disposable blades, the sections (4-5 μ) were cut and then sliced sections were put into the tissue floatation bath then on to the slides to the next step. Hematoxylin and Eosin dyes were used to stain the sections (Alghamdi et al., 2021).

3. RESULTS AND DISCUSSION

3.1 Identification of the fungi

In the present study, isolated pure fungus stained with lactophenol cotton blue were subjected to direct microscopic examination in the laboratory. The microscopic identification results were shown in Fig. 1

and Fig. 2 respectively. The molecular identification results were shown in Fig. 3 and Fig. 4 respectively. The fungi isolated were *Aspergillus flavus* and *Aspergillus niger*.

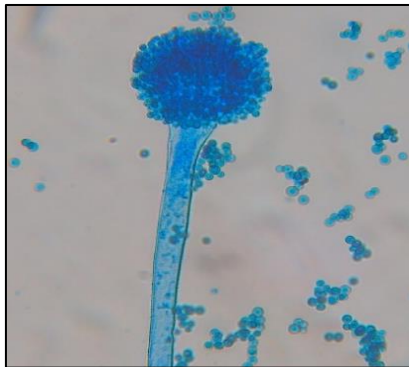


Fig.1 Microscopic appearance of *Aspergillus flavus* showing stipe and vesicle.




Fig.2 Microscopic appearance of *Aspergillus niger* showing stipe and vesicle.

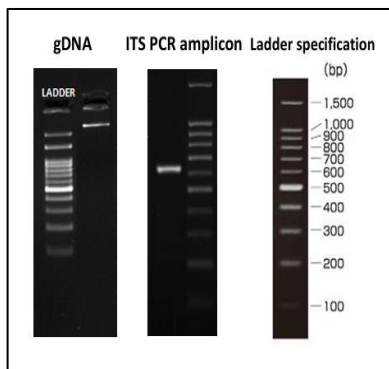


Fig. 3 gDNA and ITS Amplicon QC data of *Aspergillus flavus*

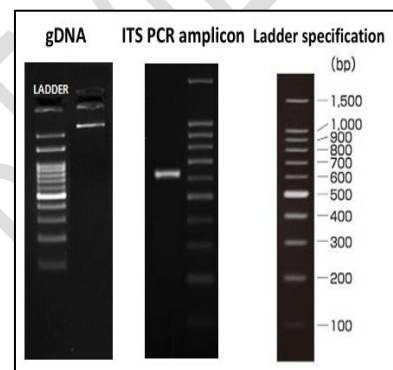


Fig. 4 gDNA and ITS Amplicon QC data of *Aspergillus niger*

3.2 Biochemical parameters

3.2.1 Serum alanine aminotransferase (ALT)

On day 14 serum ALT concentrations were significantly ($P < 0.01$) increased in group II and III compared to group I (Control). On day 28 serum ALT concentrations were significantly ($P < 0.001$) increased in group II and III compared to group I (Control). In the study conducted by Xu (2021), AFB1-induced mice liver injury involving mitochondrial dysfunction, it was noticed that significant increase in serum ALT levels supported findings of the present study.

Table 2: Effect of mixed fungal culture filtrates at different doses on ALT (U/L) in rats during repeated dose 28-day oral toxicity study.

Groups	ALT (U/L)		
	Day 0	Day 14	Day 28
Group I	37.26± 0.47	40.87± 0.64	43.94± 0.75
Group II	40.96±1.42	58.79 ± 1.691**	59.98 ±1.61***
Group III	41.54±0.73	59.48 ± 1.124**	64.91 ± 1.03***

Values are mean \pm SEM, n = 6, ** P < 0.01, *** P < 0.001.

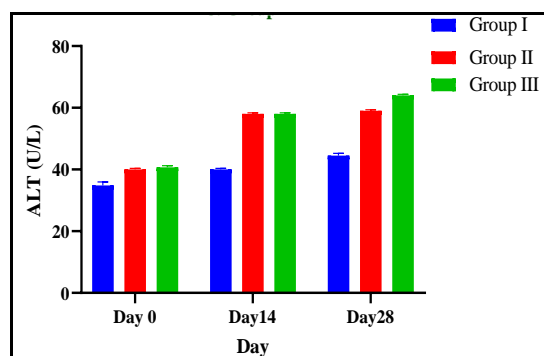


Fig.5: Effect of mixed fungal culture filtrates at different doses on ALT (U/L) in rats during repeated dose 28-day oral toxicity study.

3.2.2 Serum aspartate aminotransferase (AST)

On day 14 serum AST concentrations were significantly (P < 0.01) increased in group II and III compared to group I (Control). On day 28 serum ALT concentrations were significantly (P < 0.001) increased in group II and III compared to group I (Control). In an analysis of seventy-two cattle intoxicated with AFB1 feed showed a significant increase in alanine amino transferase (ALT) and aspartate amino transferase (AST) levels (Elgioushy, 2020) supported findings of the present study.

Table 3: Effect of mixed fungal culture filtrates at different doses on AST (U/L) in rats during repeated dose 28-day oral toxicity study.

Groups	AST (U/L)		
	Day 0	Day 14	Day 28
Group I	102.51 \pm 1.41	102.68 \pm 1.28	102.03 \pm 0.37
Group II	101.36 \pm 0.34	129.16 \pm 1.251**	134.85 \pm 1.70***
Group III	101.76 \pm 0.73	129.18 \pm 0.921**	141.26 \pm 1.03***

Values are mean \pm SEM, n = 6, ** P < 0.01, *** P < 0.001.

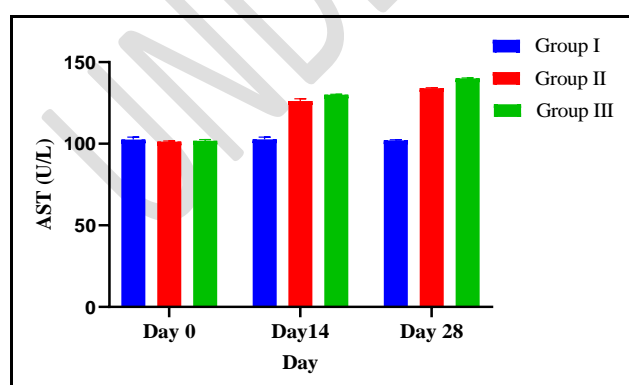


Fig.6: Effect of mixed fungal culture filtrates at different doses on AST (U/L) in rats during repeated dose 28-day oral toxicity study.

3.2.3 Blood urea nitrogen (BUN)

On day 14 serum BUN concentrations were significantly ($P < 0.01$) increased in group II and III compared to group I (Control). On day 28 serum BUN concentrations were significantly ($P < 0.001$) increased in group II and III compared to group I (Control).

In the study of l-proline alleviated kidney injury caused by AFB1 and AFM1 through regulating excessive apoptosis of kidney cells, that apoptosis of kidney cells leads to higher levels of creatinine and BUN in the AFB1 and AFM1 treatment groups of mice than the control reported similar findings (Li, 2019).

Table 4: Effect of mixed fungal culture filtrates at different doses on BUN in rats during repeated dose 28-day oral toxicity study.

Groups	BUN (mg/dl)		
	Day 0	Day 14	Day 28
Group I	31.82± 0.49	29.84 ± 1.55	31.40± 0.54
Group II	32.57±1.01	41.09 ± 0.912**	53.31 ±0.60***
Group III	30.12±0.46	43.20 ± 0.771**	55.06± 0.72***

Values are mean ± SEM, n = 6, ** P < 0.01, *** P < 0.001.

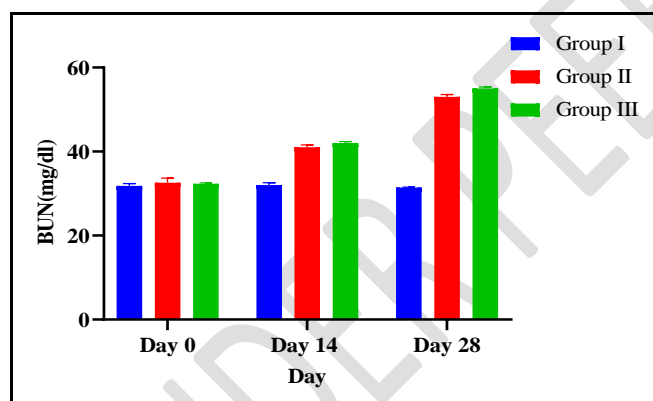


Fig.7: Effect of mixed fungal culture filtrates at different doses on BUN(mg/dl) in rats during repeated dose 28-day oral toxicity study.

3.2.4 serum creatinine

On day 14 serum Creatinine concentrations were significantly ($P < 0.01$) increased in group II and III compared to group I (Control). On day 28 serum Creatinine concentrations were significantly ($P < 0.001$) increased in group II and III compared to group I (Control).

The study conducted by Rekha (2014), stated that there would be increased serum creatinine concentration in the rats treated with mixed fungal culture filtrate of *Aspergillus niger*, *Aspergillus terreus*, *Rhizoctonia bataticola* and *Rhizopus stolonifera* which was attributed to the kidney damage.

Table 5: Effect of mixed fungal culture filtrates at different doses on Creatinine (mg/dl) in rats during repeated dose 28-day oral toxicity study.

Groups	Creatinine (mg/dl)		
	Day 0	Day 14	Day 28
Group I	0.24± 0.01	0.35± 0.01	0.35± 0.02
Group II	0.28±0.03	0.59±0.381**	0.76±0.27***
Group III	0.28±0.01	0.60± 0.231**	0.96±0.35***

Values are mean ± SEM, n = 6, ** P < 0.01, *** P < 0.001.

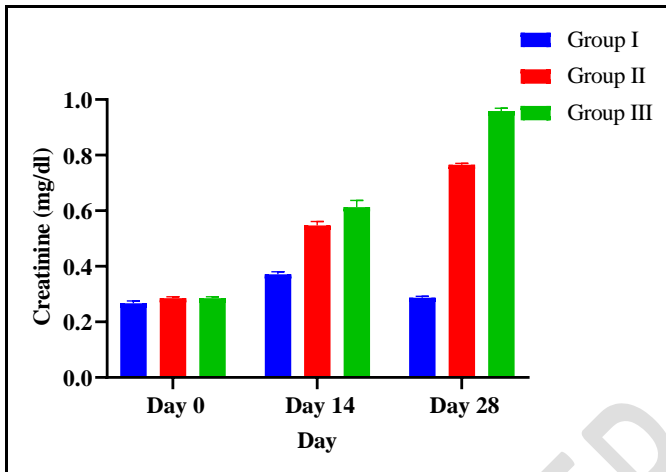


Fig.8: Effect of mixed fungal culture filtrates at different doses on creatinine (mg/dl) in rats during repeated dose 28-day oral toxicity study.

3.3 Hematological parameters

3.3.1 Total leucocyte count (TLC)

On day 14 TLC was significantly ($P < 0.05$) decreased in group II and III compared to group I (Control). On day 28 TLC were significantly ($P < 0.01$) increased in group II and III compared to group I (Control). In a study of effect of aflatoxin on hematological and biochemical alteration in broilers by Rathod et al. (2017), exhibited that broilers fed with aflatoxin diet revealed values of hemoglobin, total erythrocyte count and total leukocyte count were significantly decreased compared with control diet.

In the study of Donmez (2012). effects of aflatoxin on some hematological parameters and protective effectiveness of esterified glucomannan in Merino rams resulted in decreased erythrocyte, leukocyte count, hemoglobin and hematocrit levels. Aflatoxicosis caused the lymphocytopenia and monocytopenia but increased percentage of neutrophil counts in aflatoxin treated group compared with the other groups.

Table 6: Effect of mixed fungal culture filtrates at different doses on TLC (10^3 cells/mm³) in rats during repeated dose 28-day oral toxicity study.

Groups	TLC (10^3 cells/mm ³)		
	Day 0	Day 14	Day 28
Group I	8.86±0.21	8.49±0.11	8.22±0.01
Group II	8.72±0.22	7.59±0.33**	7.32±0.273**
Group III	8.93±0.18	7.31±0.42 **	7.19±0.462**

Values are mean \pm SEM, n = 6, * P <0.05, ** P < 0.01.

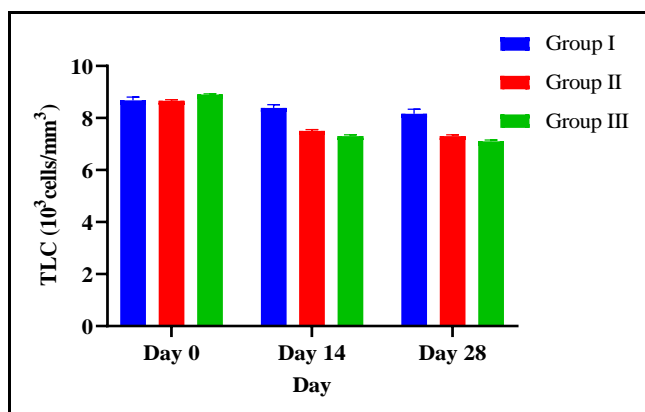


Fig.9: Effect of mixed fungal culture filtrates at different doses onTLC (10^3 cells/mm³)inrats duringrepeated dose 28-day oral toxicity study.

3.3.2 TOTAL ERYTHROCYTE COUNT (TEC)

On day 14 TEC was significantly (P < 0.01) decreased in group II and III compared to group I (Control). On day 28 TEC were significantly (P < 0.001) decreased in group II and III compared to group I (Control).In study of Uluisik (2020), effects of curcumin on hematological parameters in Aflatoxin B1 applied rats by erythrocytes count, haemoglobin concentration, hematocrit value and MCHC level in the aflatoxin applied rats significantly decreased compared to the control group (p <0.05) supported the findings of present study.

Table 7: Effect of mixed fungal culture filtrates at different doses on TEC (10^6 cells/mm³) in rats during repeated dose 28-day oral toxicity study.

Groups	TEC (10^6 cells/mm ³)		
	Day 0	Day 14	Day 28
Group I	8.24 \pm 0.21	8.91 \pm 0.01	8.62 \pm 0.01
Group II	8.52 \pm 0.22	8.12 \pm 0.334**	6.90 \pm 0.27***
Group III	8.95 \pm 0.18	7.95 \pm 0.421 **	6.82 \pm 0.46***

Values are mean \pm SEM, n = 6, ** P <0.01,*** P < 0.001.

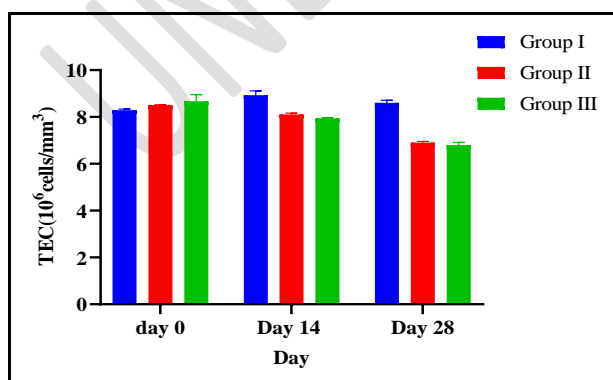


Fig. 10: The effect of mixed fungal culture filtrates on TEC (10^6 cells/mm³) in rats during repeated dose 28-day oral toxicity study.

3.3.3 Hemoglobin

On day 28 hemoglobin concentrations were significantly ($P < 0.001$) decreased in group II and III compared to group I (Control). A study conducted by Khaled and Thalij(2021), concluded that feeding of corn samples and its products contaminated with Aflatoxin B1 to rats fed for 21 days showed the decrease in the number of red blood cells and hemoglobin when compared with the control group rats.

Table 8: Effect of mixed fungal culture filtrates at different doses on Hb (g/dl)in rats during repeated dose 28-day oral toxicity study.

Groups	Hb (g/dl)		
	Day 0	Day 14	Day 28
Group I	16.65±0.21	17.30±0.01	17.20±0.01
Group II	17.27±0.22	16.20±0.33	13.33±0.27***
Group III	17.33±0.18	16.16±0.42	12.43±0.46***

Values are mean ± SEM, n = 6, *** P < 0.001.

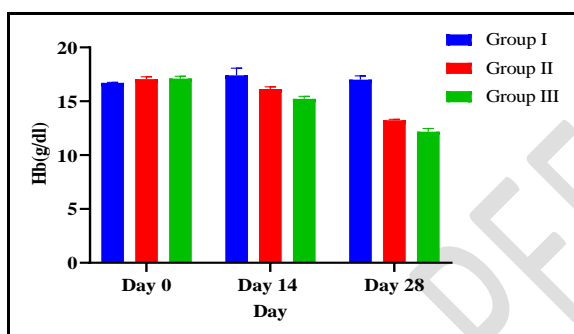


Fig. 11: The effect of mixed fungal culture filtrates on in rats Hb (g/dl) during repeated dose 28-day oral toxicity study.

3.3.4 Packed cell volume (PCV)

On day 28 PCV were significantly ($P < 0.001$) decreased in group II and III compared to group I (Control). In a study of haematological and haemostatic changes in aflatoxin, curcumin plus aflatoxin and curcumin treated rats, observed macrocytic hypochromic anemia, which was confirmed by the reduction in RBCs count, Hb, PCV, MCH and MCHC with increased MCV (Allah, 2017).

Table 9: Effect of mixed fungal culture filtrates at different doses on Hb (g/dl)in rats during repeated dose 28-day oral toxicity study.

Groups	PCV (%)		
	Day 0	Day 14	Day 28
Group I	45.65±1.21	45.30±0.51	48.20±0.52
Group II	46.27±0.22	42.60±0.33	38.33±0.27***
Group III	45.33±0.18	41.96±0.42	36.43±0.46***

Values are mean \pm SEM, n = 6, *** P < 0.001.

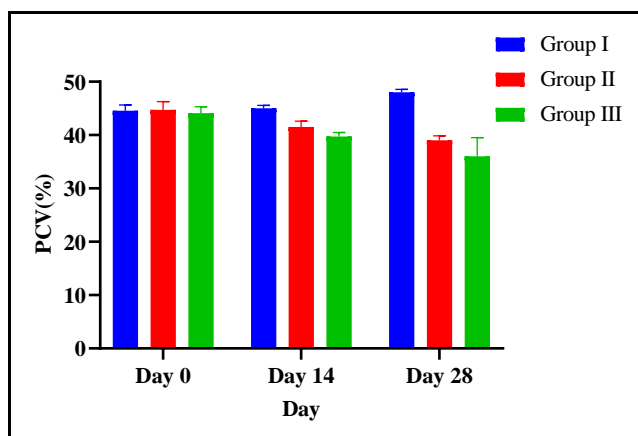


Fig.12: The effect of mixed fungal culture filtrates on PCV (%) in rats during repeated dose 28-day oral toxicity study.

4.PATHOLOGY

4.1 Gross pathology

In all the treated groups of rats there was congestion of lungs, liver, kidney and heart. Lungs of group III showed the emphysematous changes and fibrosis. Hepatomegaly and distended appearance of liver was seen in group III.

4.2. Histopathology

Various changes reported in Group III were as follows.

Heart shown congested blood vessels in myocardium with focal degenerative changes in cardiomyocytes. Lungs shown alveolar emphysema, congestion and interstitial pneumonia was observed. Liver showed infiltration of mononuclear cells in portal area. Kidney showed glomerular congestion, necrosis of proximal convoluted tubule cells, debris in lumen. Spleen showed loss of architecture, depleted lymphocytes in red pulp and white pulp. Intestine showed increased goblet cell activity and focal loss of epithelium.

5. CONCLUSION

The findings of the present study inferred that the mixed fungal culture filtrate of fungus isolated from contaminated maize stalk resulted in toxicity in rats, which was attributed for the presence of a toxic principle component in the fungal culture filtrate.

Disclaimer (Artificial intelligence)

Author(s) hereby declare that NO generative AI technologies such as Large Language Models (ChatGPT, COPILOT, etc.) and text-to-image generators have been used during the writing or editing of this manuscript.

REFERENCES

- Alghamdi, R. S., Alharbi, T. S. & Alsubaie, W. R. (2021). Quality standards of histopathology laboratory and work facilities in a developed country. *Archives of Pharmacy Practice*, 12 (1-2021): 90-97.
- Allah Abd, O. A., Fararh, K. M., Farid, A. S. & Gad, F. A. (2017). Hematological and hemostatic changes in aflatoxin, curcumin plus aflatoxin and curcumin treated rat. *Journal of veterinary medicine*, 32 (2): 151-156.
- Donmez, N., Donmez, H. H., Keskin, E. & Kisadere, I. (2012). Effects of aflatoxin on some haematological parameters and protective effectiveness of esterified glucomannan in Merino rams. *The Scientific World J.*, 212: 1-5.
- Elgioushy, M.M., Elgaml, S.A., El-Adl, M.M., Hegazy, A.M., & Hashish, E.A. (2020). Aflatoxicosis in cattle: clinical findings and biochemical alterations. *Environmental Science and Pollution Research*, 27, 35526-35534.
- Khaled, M. Q. & Thalij, K. M. (2021). Effect of Aflatoxin B1 contaminated corn and their products on some physiology parameters in laboratory rats. *IOP Conference Series: Earth and Environmental Science*, 910 (1): 121-133.
- Li, H., Li, S., Yang, H., Wang, Y., Wang, J. & Zheng, N. (2019). L-Proline alleviates kidney injury caused by AFB1 and AFM1 through regulating excessive apoptosis of kidney cells. *Toxins*, 11(4), 226.
- OECD, (2001). Organization for economic cooperation and development guidelines 403, 408, 425 and 426, for testing of chemicals. Paris, France.
- Przystaś, W., Zabłocka-Godlewska, E and Grabińska-Sota E. 2013. Effectiveness of dyes removal by mixed fungal cultures and toxicity of their metabolites. *Water, Air & Soil Pollution*. (224):1-9
- Rathod, P., Gangadhar, K., Gangane, G. & Bhojane, N. (2017). Effect of aflatoxin on haematological and biochemical alteration in broilers. *International Journal of Environmental Science and Technology*, 6: 824-831.
- Rekha, Y. (2014). Toxicity study of fungal isolates from maize straws in rats. M.V.Sc thesis, Karnataka Veterinary, Animal and Fisheries Sciences University, Bidar, India.
- Rodrigues, I. (2014). A review on the effects of mycotoxins in dairy ruminants. *Animal production science*, 54 (9): 1155-1165.
- Uluişik, D., Keskin, E. & Hatipoğlu, D. (2020). Effects of curcumin on hematological parameters in aflatoxin B1 applied rats. *Turkish Journal of Sport and Exercise*, 22(2), 265-270.
- Vinay, P. T. (2007). Toxicity studies of fungal isolates from groundnut hay in rats and mice. M.V.Sc. thesis, Karnataka Veterinary, Animal and Fisheries Sciences University, Bidar, India.
- Xu, F., Li, Y., Cao, Z., Zhang, J., & Huang, W. (2021). AFB1-induced mice liver injury involves mitochondrial dysfunction mediated by mitochondrial biogenesis inhibition. *Ecotoxicology and environmental safety*, 112-213.
- Yu, J. & Pedroso, I. R. (2023). Mycotoxins in cereal-based products and their impacts on the health of humans, livestock animals and pets. *Toxins*, 15 (8): 480-495.

UNDER PEER REVIEW

Fig.1 Microscopic appearance of *Aspergillus flavus* showing stipe, and vesicle.