

## **Rare case of Pulmonary Tuberculosis presenting as subcutaneous swelling and nodular pleural thickening: a Case Report**

### **Abstract:**

Tuberculosis (TB) is a global health concern and can affect various organs, including the pleura<sup>1</sup>. Pleural involvement in TB often presents as pleural effusion and smooth pleural thickening<sup>2</sup>. We present a case of a 12-year-old male who presented with complaints of fever, weight loss and painful subcutaneous swelling below the lower left 9<sup>th</sup> rib. Ultrasound screening was done to evaluate the painful soft tissue lesion in the lower left antero-lateral chest wall, findings revealed a collection with necrotic areas within on the left side along with minimal right sided pleural effusion. HRCT Chest Imaging revealed nodular right pleural thickening with minimal right pleural effusion along with other findings as seen on the left side on USG. The patient was diagnosed with tuberculous pleural thickening based on cartridge based nucleic acid amplification test (CBNAAT) examination of the fine needle aspiration cytology (FNAC) guided pleural fluid aspiration and analysis. The case highlights the importance of considering TB as a potential etiology for nodular pleural thickening, even in a young patient, particularly in high TB burden regions.

**Keywords:** Tuberculosis, fever, weight loss, fine needle aspiration cytology (FNAC), cartridge based nucleic acid amplification test (CBNAAT)

### **Introduction:**

Tuberculosis (TB) remains a significant global health problem especially in the developing countries<sup>2</sup>. While pulmonary involvement is the most common presentation, extrapulmonary manifestations are also observed<sup>2,3</sup>. Pleural involvement in TB typically presents as pleural effusion, but nodular tuberculous pleural thickening is a rare occurrence [6-10]. Nodular thickening of the pleura with associated effusion is often diagnosed incidentally or after investigating symptoms such as chest pain or dyspnea. While the most common causes of nodular pleural thickening include mesothelioma and pleural metastasis<sup>4</sup>. Here, we present a case of nodular tuberculous pleural thickening in a 12-year-old male, highlighting the need for clinical suspicion and appropriate diagnostic workup for tuberculosis in this rare presentation.

## Case Presentation:

A 12 year old male presented to the hospital with complaints of high grade fever of 101 degree centigrade with chills from the last 20 days, painful swelling in left lower antero-lateral chest wall of 6 days duration and history of significant weight loss.

The patient had no previous history of prior exposure to TB infection. On physical examination, decreased breath sounds were noted on the right side of the chest. Laboratory investigations, including complete blood count, renal and liver function tests, and inflammatory markers, were within normal limits.

On clinical examination BCG scar was not present.

Chest X-Ray was done, and it showed erosion of the antero-lateral aspect of the left 9<sup>th</sup> rib (as shown with solid blue arrow), with adjacent soft tissue swelling (as shown by solid red arrow) {Fig. 1 with inset showing lytic destruction of the antero-lateral aspect of left sided 9<sup>th</sup> rib } and inhomogeneous opacity in the right mid and lower lung zones along with bunting of the right costophrenic and cardiophrenic angles with linear homogeneous opacity along right lateral chest wall, likely suggestive of pleural effusion.

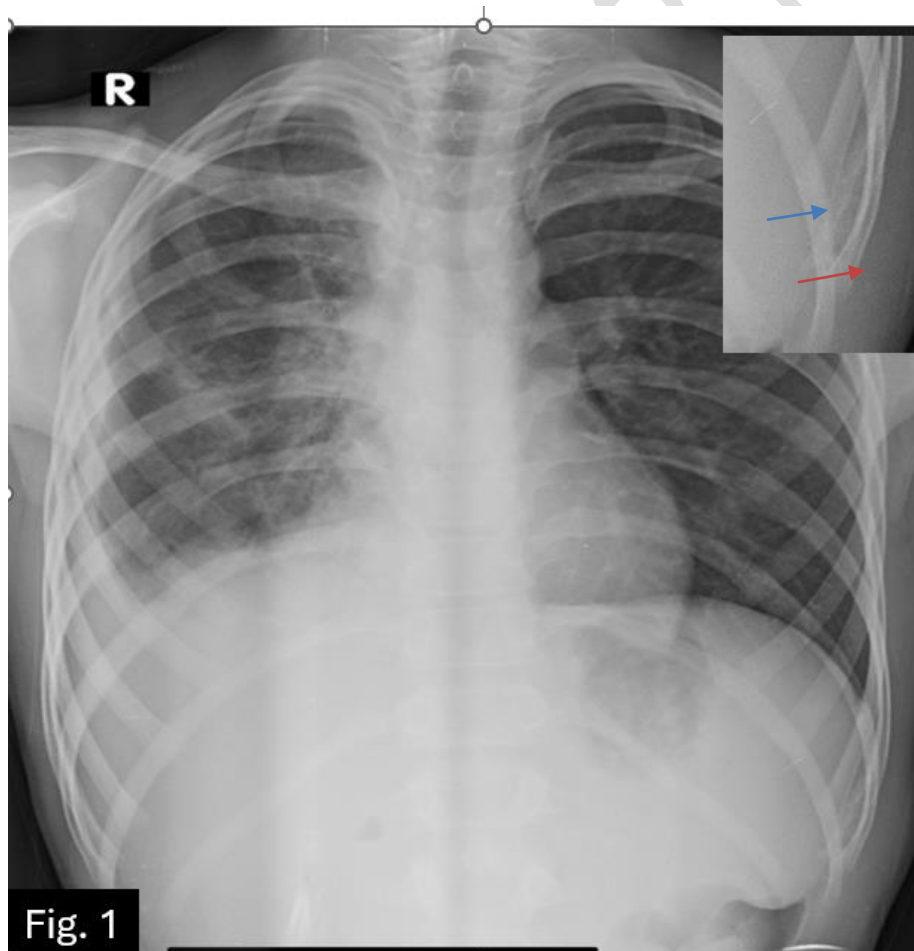


Fig 1 : Chest X-ray

Ultrasound screening was done to evaluate the painful soft tissue lesion in the lower left antero-lateral chest wall along with minimal right pleural effusion. Findings revealed a heterogeneous hypoechoic collection with necrotic areas within {Fig. 2} on the left side and minimal pleural effusion on the right side.

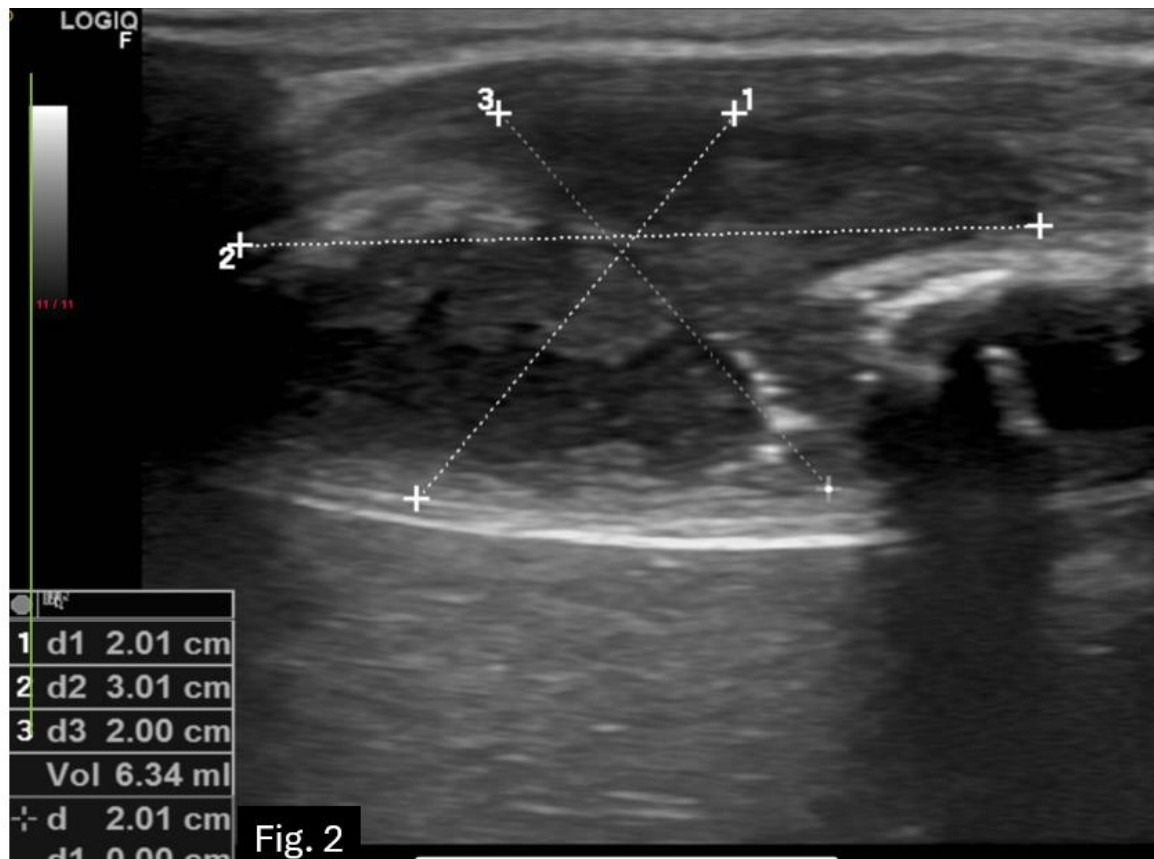


Fig. 2: USG image showing a heterogeneous hypoechoic collection with necrotic areas within in the lower left antero-lateral chest wall

As there was discrepancy with the radiograph and ultrasound findings in the quantity of the pleural effusion, CT scan was performed. Bone window showed lytic destruction of the antero-lateral aspect of the left 9<sup>th</sup> rib with an adjacent heterogeneous collection in the intramuscular and subcutaneous plane. Along with findings on the right side as seen on lung window, consolidation with air bronchograms in the right lower lobe {Fig. 3a}, a soft tissue attenuation nodule in the right upper lobe {Fig.3a} and areas of subsegmental collapse in the right middle lobe. Mediastinal window showed circumferential nodular right pleural thickening {Fig.3b & 3c} with minimal pleural effusion, loss of right lung volume and few prominent mediastinal lymph nodes. On CT, the possibility of infectious etiology (likely Pleural TB) was suspected, despite the unusual presence of diffuse thick

right nodular pleural thickening which is more likely to be encountered in other conditions like mesothelioma and pleural metastasis.

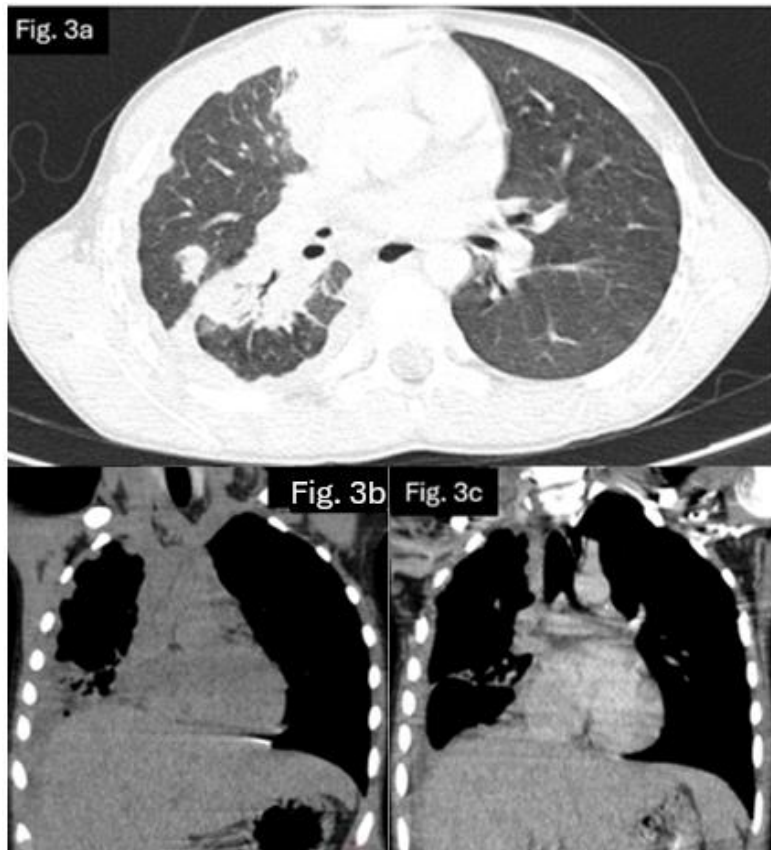


Fig. 3. a. CT Chest lung window Images showing consolidation. b. Plain and c. post contrast images in mediastinal window images showing diffuse circumferential nodular right pleural thickening.

The patient was then investigated further with sputum, pleural fluid sample analysis (CBNAAT). Sputum sample was negative and pleural FNAC fluid was positive for M. Tuberculosis. FNAC was performed from the left chest wall swelling which revealed inflammatory granulomatous smear.

The patient was started on a standard anti-tubercular regimen, including isoniazid, rifampicin, pyrazinamide, and ethambutol according to the weight-based dosages. The treatment was well tolerated, and the patient showed significant clinical improvement with resolution of fever and reduction in pain and the size of the swelling at six week follow up.

## Discussion:

Pleural tuberculosis can rarely present as nodular tuberculous pleural thickening even in the absence of significant pleural effusion and can be difficult to diagnose due to gradual onset of symptoms. It is important to consider tuberculosis as a potential cause of unexplained pleural thickening, especially in areas with high tuberculosis prevalence, to ensure timely diagnosis and treatment<sup>5</sup>. Maintaining a high level of suspicion, conducting a comprehensive diagnostic assessment, and promptly starting anti-tubercular therapy are crucial for achieving a positive clinical outcome.

### **Conclusion:**

This case highlights the importance of ruling out TB as a possible diagnosis in individuals with nodular pleural thickening. To ensure prompt diagnosis and effective treatment, which will eventually improve patient outcomes, healthcare personnel should maintain a high index of suspicion for tuberculosis, in areas where the disease is very prevalent.

### **Consent:**

All authors declare that written informed consent was obtained from the patient for publication of this case report and accompanying images.

### **Ethical approval:**

All authors hereby declare that all experiments have been examined and approved by the appropriate ethics committee and have therefore been performed in accordance with ethical standards.

### **Disclaimer (Artificial intelligence)**

#### **Option 1:**

Author(s) hereby declare that NO generative AI technologies such as Large Language Models (ChatGPT, COPILOT, etc.) and text-to-image generators have been used during the writing or editing of this manuscript.

#### **Option 2:**

Author(s) hereby declare that generative AI technologies such as Large Language Models, etc. have been used during the writing or editing of manuscripts. This explanation will include the name, version,

model, and source of the generative AI technology and as well as all input prompts provided to the generative AI technology

Details of the AI usage are given below:

- 1.
- 2.
- 3.

#### References:

1. Patel A, Choudhury S. Pleural tuberculosis presented as multiple pleural masses: An atypical presentation. *Lung India*. 2013 Jan 1;30(1):54-6.
2. Oh AL, Makmor-Bakry M, Islahudin F, Ting CY, Chan SK, Tie ST. Characteristics, predictors and consequences of tuberculosis treatment interruption: A multicentre retrospective cohort study. *Tropical Medicine & International Health*. 2024 May;29(5):434-45.
3. Cohen LA, Light RW. Tuberculous pleural effusion. *Turkish thoracic journal*. 2015 Jan;16(1):1.
4. Leung AN, Müller NL, Miller RR. CT in differential diagnosis of diffuse pleural disease. *AJR. American journal of roentgenology*. 1990 Mar;154(3):487-92.
5. Sureka B, Thukral BB, Mittal MK, Mittal A, Sinha M. Radiological review of pleural tumors. *Indian Journal of Radiology and Imaging*. 2013 Oct;23(04):313-20.
6. Kaul S, Jakhar D, Mehta S, Singal A. Cutaneous tuberculosis. Part II: Complications, diagnostic workup, histopathologic features, and treatment. *Journal of the American Academy of Dermatology*. 2023 Dec 1;89(6):1107-19.
7. Kaul S, Kaur I, Mehta S, Singal A. Cutaneous tuberculosis. Part I: Pathogenesis, classification, and clinical features. *Journal of the American Academy of Dermatology*. 2023 Dec 1;89(6):1091-103.
8. Maloney ME, Cohen B. Cutaneous tuberculosis in the pediatric population: a review. *JAAD international*. 2023 Sep 1;12:105-11.
9. Yadav S. Clinical drug-resistant cutaneous tuberculosis presenting as lupus vulgaris ulcerative type in an indian female with poncet's disease: a first-of-its-type report. *Cureus*. 2024 Mar;16(3).
10. Kozińska M, Augustynowicz-Kopeć E, Gamian A, Chudzik A, Paściak M, Zdziarski P. Cutaneous and Pulmonary Tuberculosis—Diagnostic and Therapeutic Difficulties in a Patient with Autoimmunity. *Pathogens*. 2023 Feb 15;12(2):331.