

Case report

Right Aortic Arch with Left Subclavian Artery Atresia and Heart Failure with Reduced Ejection Fraction in a 43-Year-Old Male; First Case in Literature

Abstract:

An incidentally discovered right-sided aortic was absent from the first part of the left subclavian artery in a 43-year-old male, who is a newly diagnosed heart failure with reduce ejection fraction (HFrEF).

Commented [MO1]: This section requires proper sentence phrasing

Commented [MO2]: Change aortic to a

Introduction:

The right aortic arch is a rare anatomical anomaly in which the aortic arch is on the right side rather than the left, with a reported incidence of 0.1% (1). There are three main subtypes based on Edward's classification: type I—right aortic arch (RAA) with mirror image branching; type II—RAA with an aberrant left subclavian artery; and type III—RAA with an isolated subclavian artery. Type II is the most common subtype (2). Other rare subtypes include RAA with isolation of the innominate artery and right circumflex aorta. Type III is a RAA with isolated subclavian artery. Right aortic arch (RAA) with an isolated subclavian artery result from the regression of the embryological left arch at two segments adjacent to the left subclavian artery (Figure 6). The left subclavian artery may arise from either the vertebral artery or the ductus arteriosus (3). Patients typically exhibit features of subclavian steal syndrome and may report weakness in the left arm (4). Phase-contrast magnetic resonance angiography, if performed, will reveal flow reversal in the left vertebral artery. Unlike type II RAA, type III is associated with an increased incidence of congenital heart defects such as truncus arteriosus, tricuspid atresia, or tetralogy of Fallot (5, 6). The treatment approach involves creating a bypass graft to connect the common carotid artery and the subclavian artery.

Commented [MO3]: As per citation 2 the RAA with mirror image branching therefore inaccurate

Commented [MO4]: Results from is cor

Case Presentation:

This is a 43-year-old male with a known history of bronchial asthma, dyslipidaemia, migraine headaches, and obesity (BMI 30). He was referred to cardiology from the family medicine clinic due to experiencing atypical chest pain and occasional palpitations. His ECG showed a left bundle branch block (LBBB), which was not a new finding.

Commented [MO5]: This section requires framing

Upon referral, a transthoracic echocardiogram (TTE) and a cardiac CT were ordered. The TTE revealed a dilated left ventricle (LV) with a severely impaired LV ejection fraction (EF) of 25% and global hypokinesia. The patient was admitted to the coronary care unit (CCU) as a case of newly diagnosed heart failure with reduced ejection fraction (HFrEF) for further evaluation.

Upon assessment, we found that the patient had differing blood pressure readings (right arm: 122/99 mmHg, left arm: 95/60 mmHg). According to the patient, this discrepancy has been present for a long time, but it has not been addressed until now.

Right-sided Aortic arch was noted by chest x ray. (Fig 1). Cardiac CT showed a calcium score of zero and normal coronary arteries, but it also revealed a right-sided aortic arch.

A chest CT angiogram was recommended for further evaluation.

Commented [MO6]: Add the words which follow the following findings

The chest CT angiogram revealed a right-sided aortic arch and descending thoracic aorta of normal calibre. The branching pattern of the thoracic aorta, from right to left, is as follows: right subclavian artery, right common carotid artery, and left common carotid artery. The first part of the left subclavian artery is absent (atresia), with filling of the left subclavian from the left vertebral artery (steal phenomenon). There was no evidence of aortic aneurysm or dissection.

Mild cardiomegaly with left ventricular dilatation was noted. The descending abdominal aorta followed a normal course with a normal branching pattern. The visualised lung parenchyma showed no abnormal focal or diffuse lesions. Both the pleural and pericardial sacs were clear. The remaining branches of the aortic arch were normal, and the left vertebral artery was patent (Fig 2,3,4,5).

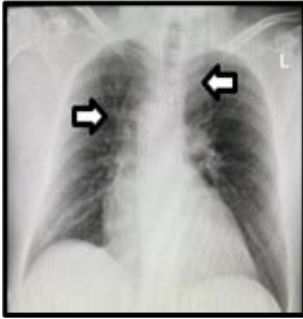


Figure 1: Chest X- ray

The patient was diagnosed with non-ischemic cardiomyopathy and initiated on guideline-directed medical therapy (GDMT). The second diagnosis was a right-sided aortic arch with atresia of the left subclavian artery.

Commented [MO7]: Specify the management detail

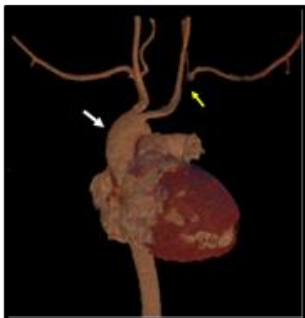

Figure 2: 3D reconstruction of the heart and thoracic aorta. There is a right sided aortic arch (white arrow). The first part of the left subclavian artery is absent (yellow arrow) with filling of the left subclavian from the left vertebral artery (steal phenomenon).

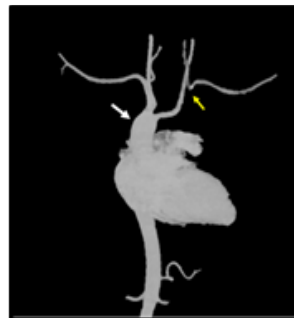

Figure 3: 3D MIP angio view of the heart and thoracic aorta. There is a right sided aortic arch (white arrow). The first part of the left subclavian artery is absent (yellow arrow) with filling of the left subclavian from the left vertebral artery (steal phenomenon).

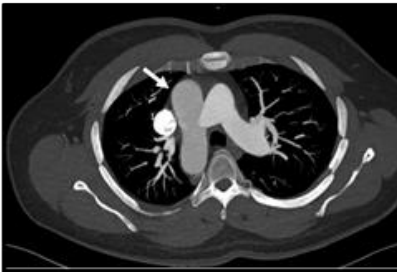

Figure 4: Axial MIP of the chest mediastinum window at the aortic arch level. There is a right sided aortic arch (white arrow).

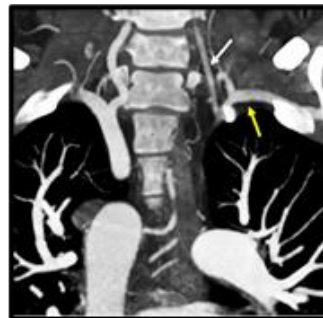

Figure 5: Coronal MIP of the chest mediastinum window. The left subclavian artery (yellow arrow) is taking its supply from the left vertebral artery (white arrow) steal phenomenon.

Discussion:

A right-sided aortic arch with an aberrant left subclavian artery is one of the anomalies occurring in approximately 0.05% to 0.1% of the population. Most cases are asymptomatic; however, some may present with symptoms of oesophageal or respiratory compression (7, 8).

Steward et al. reported 298 cases of right aortic arches, with isolation of the left subclavian artery occurs in only 0.8% of such cases (9).

Although a right aortic arch with an isolated left subclavian artery is rare, it should be considered in patients with a right aortic arch evident on a chest X-ray, along with decreased blood pressure or a delayed and dampened pulse in the left upper extremity during physical examination. It presents a characteristic angiographic appearance when delayed films are obtained. Recognising this anomaly is clinically significant, as it can lead to vertebrobasilar or left upper extremity ischemia, which can be surgically corrected. Additionally, the incidence of associated congenital heart disease, particularly tetralogy

Commented [M08]: This section requires proper sentence structuring for easy readability.

of Fallot, is high. Failure to identify the isolated left subclavian artery may result in unsuccessful attempts to create a left Blalock-Taussig shunt (10).

The case we present involves an incidentally discovered right-sided aortic arch with left subclavian artery atresia, with filling of the left subclavian from the left vertebral artery (steal phenomenon). The patient also has heart failure with reduced ejection fraction (HFrEF).

To our knowledge, there is no published literature describing heart failure in conjunction with a right aortic arch. This case is the first to document a patient with heart failure alongside a right aortic arch. However, it raises the question of whether there is a relationship between right aortic arch and the development of heart failure in this patient, and if so, what the underlying mechanism might be, or if it is merely a coincidence. While we cannot provide an answer to this question, future published cases may offer insights. This case may serve to highlight the potential link between heart failure and right aortic arch.

Reference:

1. D'Antonio F, Khalil A, Zidere V, et al. Fetuses with right aortic arch: a multicenter cohort study and meta-analysis. *Ultrasound Obstet Gynecol* 2016; 47:423-32.
2. García-Guereta L, García-Cerro E, Bret-Zurita M. Multidetector Computed Tomography for Congenital Anomalies of the Aortic Arch: Vascular Rings. *Rev Esp Cardiol Engl Ed* 2016; 69:681-93.
3. Sun AM, Alhabshan F, Branson H, et al. MRI diagnosis of isolated origin of the left subclavian artery from the left pulmonary artery. *Pediatr Radiol* 2005; 35:1259-62.
4. Arnoult AC, Blaise S. Late discovery of a rare anomaly of the right aortic arch and an isolated left subclavian artery. *J Vasc Surg* 2016; 64:1853-4.
5. Carano N, Piazza P, Agnetti A, et al. Congenital pulmonary steal phenomenon associated with tetralogy of Fallot, right aortic arch, and isolation of the left subclavian artery. *Pediatr Cardiol* 1997; 18:57-60.
6. Priya, S., Thomas, R., Nagpal, P., Sharma, A., Steigner, M. Congenital anomalies of the aortic arch, *Cardiovascular Diagnosis and Therapy*, volume {8}, {Sup1}, 2017.
7. Lincoln JC, Deverall PB, Stark J, Aberdeen E, Waterston DJ. Vascular anomalies compressing the oesophagus and trachea. *Thorax*. 1969; 24:295–306.
8. Arazińska A, Polgaj M, Szymczyk K. Right aortic arch analysis Anatomical variant or serious vascular defect? *BMC Cardiovasc Disord*. 2017; 17:102.
9. Stewart JR Kincaid OW Titus JL Right aortic arch: plain film diagnosis and significance. *Am J Roentgenol*. 1966; 97: 377-389
10. Right Aortic Arch with Isolation of the Left Subclavian Artery: Case Report and Review of the Literature. Patrick H. Luetmer, M.D. Gary M. Miller, M.D. *Mayo Clinic Proceedings*, volume 65, issue 3, P407-413, March 1990