

## Case report

### Therapeutic Management of Chocolate Toxicity in a Rottweiler Dog

#### Abstract

A seven years old Rottweiler dog was presented to Veterinary Clinical Complex, College of Veterinary and Animal Sciences, Kishanganj, in lateral recumbency with history of anorexia, vomiting and diarrhea over the previous two days. History taking revealed excessive consumption of chocolates (both milk chocolate and dark chocolate) by the dog two days earlier. The case was diagnosed as chocolate toxicity based on confirmed history by the owner. As there is no specific antidote for chocolate poisoning, the dog was treated with Normal saline solution, Propranolol hydrochloride, Ondansetron, Ranitidine hydrochloride, Cefotaxime and Vitamin B complex. Complete clinical recovery was observed after 3<sup>rd</sup> day of treatment. Such cases of chocolate toxicity can be successfully managed with appropriate supportive treatment and diligent monitoring of the patient.

**Key words:** chocolate, dog, tachycardia, tachypnea, toxicity

#### 1. Introduction

Keeping pets is becoming popular trend in Indian families to reflect their modern lifestyle and socio-economic status. Amongst pet animals, dogs are the most common, followed by cats in India. Generally pet owners are providing their pets with a variety of foods that they consume. Dog owner express their love and care by offering treats to their dogs. Chocolates are consumed for its delightful flavour and taste in every household in India. Chocolate poisoning is caused by consuming an excessive amount of chocolate products. Although many species of animals are susceptible to chocolate poisoning, but dogs are the most commonly affected with chocolate intoxication or accidental poisoning. This is primarily attributed to their indiscriminate eating habits and lack of knowledge among owners about the dangers of chocolate for dogs.

The toxicity of chocolate is attributed to the presence of two methylxanthines: theobromine (3,7-dimethylxanthine) and caffeine (1,3,7-trimethylxanthine) (Kovalkoviova *et al.*, 2009). The amount of these methylxanthines (theobromine and caffeine) level depends on the type of chocolate. Chocolates that are rich in cocoa content, such as dark chocolate and baking chocolate, contains a considerably higher amount of methylxanthine than milk chocolate (Zoumas *et al.*, 1980; Dolder, 2013). The consumption of darker and more bitter chocolate is more dangerous to dogs, as they do not have the same ability as humans to metabolize theobromine and caffeine. While chocolate ingestion is rarely fatal but it can induce serious illness. Although the quantity ingested may not be toxic, dogs may suffer from illness due to the fat and sugar content found in chocolate. Many pet owners are not aware about the chocolate toxicity. Taking this into consideration, the present case report depicts the clinical presentation and successful therapeutic management of chocolate intoxication in a dog.

## **2. Case presentation and observation**

A seven years old, male Rottweiler dog weighing 28 kg, was presented to Veterinary Clinical Complex, College of Veterinary and Animal Sciences, Kishanganj, in lateral recumbency (Fig.1) with history of anorexia, vomiting and diarrhea for the last two days. The dog was dull and depressed, and when the patient was examined clinically, it was not able to hold its position in sternal recumbency. The conjunctival mucous membrane was congested (Fig. 2) and rectal temperature was 102.8 °F. Tachycardia (Heart rate, 184 beats/minutes) and tachypnea (Respiration rate, 42 breaths/minutes) were noticed on cardiac and lung auscultation, respectively. The dog had proper record of vaccination and regular deworming. Following a thorough investigation, the owner disclosed the information that the dog had fed with an excessive amount of chocolates (both milk chocolate and dark chocolate), which were received as gifts during the Diwali festivities two days ago. The case was diagnosed as chocolate intoxication, corroborated by the owner's confirmed history of ingesting an excessive amount of chocolate by the dog two days ago.

The complete blood cell counts of the dog did not showed any significant change; WBC ( $8.1 \times 10^3/\mu\text{l}$ ), Granulocyte percent (68.9 %) Lymphocyte percent (25.2 %), Monocyte percent (4 %) and Eosinophil percent (1.9 %), RBC ( $5.23 \times 10^6/\mu\text{l}$ ), Hemoglobin (11.3g/dl), Hematocrit (33.6 %), MCV (64.2 fL), MCH (21.6 pg), MCHC (33.6 g/dl), Platelet count ( $548 \times 10^3/\mu\text{l}$ ), RDW-CV (12.8 %), RDW-SD (32.9 fL) and PCT (0.36 %).



Fig 1: Affected dog presented in lateral recumbency

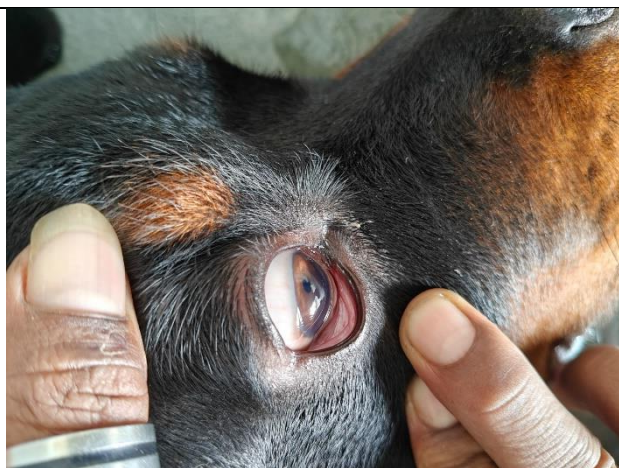


Fig 2: Congested conjunctival mucous membrane in affected dog

### 3. Treatment

There is no antidote for treatment of chocolate toxicity. Therefore, the dog was treated with inj. Normal saline solution 500 ml Intravenously (IV) BID, inj. Ondansetron @ 0.5 mg/kg, slow IV BID, inj. Ranitidine Hydrochloride @ 0.5 mg/kg, slow IV BID, inj. Propranolol hydrochloride @ 0.02 mg/kg slow IV over 5 min, Inj. Cefotaxime @50 mg/kg IV, BID, Inj. Vitamin B complex 2ml IM, OD. The owner was advised not to feed the dog *per os* for 48 hours.

Animal started showing improvement in the condition from 2<sup>nd</sup> day of treatment. Animal was active and alert. The rectal temperature, heart rate and respiration rate were normal, and vomiting and diarrhea was not occurred on 2<sup>nd</sup> day following presentation. Except Propranolol, same treatment was given on day 2<sup>nd</sup> and 3<sup>rd</sup>. Dog showed complete clinical recovery after 3<sup>rd</sup> day of treatment. The case was followed up 15 days later to ascertain the status of the dog. No complications were reported after recovery.

### 4. Discussion

In India, festivals are celebrated with family and friends, and sweets play a significant role in celebrations. Until few years ago, sweets made up of milk and dry fruits were being considered as delicacy gifts in important festivals like Diwali, Holi, Rakhi in India. Owing to the cost of dry fruits, adulteration in sweets, difficulty in carrying sweets for long time (as these are perishable items), chocolates are becoming popular choice of people over traditional sweets in

festivities. Chocolates are easily available even at a local grocery, are very easy to carry and people adore its taste. Moreover, advertisement of this industry, attractive packaging of the chocolates has made the associations of people with chocolates for almost all celebration including festivals. In festival seasons, people are more inclined towards gifting chocolates gift hampers. The demand of chocolates is increasing as it has become a common delight across age groups and its market is growing rapidly in India. Dog and cats are popular pets in Indian families and are considered to be family members. Due to lack of knowledge, pets are frequently being fed chocolates by the kids or even by adult family members due to love and affection. Dog owners express their love and care by offering treats to their dogs, as most of the pet owners do not have adequate knowledge about the chocolate toxicosis in pets.

The clinical signs of chocolate poisoning exhibited by the patient are contingent upon the type and amount of chocolate consumed. Theobromine is found in higher concentrations in chocolate than caffeine; however, the clinical effects of these two methylxanthines are quite similar. Clinical symptoms may be observed at a theobromine dose of 20 mg/kg, which can manifest as tachycardia, hyperthermia, hypertension, arrhythmias, muscle stiffness, ataxia, seizures, and coma (Dolder, 2013). In chocolate intoxication, patients commonly exhibit clinical signs associated with the cardiovascular, neurological, and gastrointestinal systems (Weingart *et al.*, 2021). Usually, the signs of chocolate toxicosis occurs within 6 to 12 hours of chocolate ingestion (Beasley *et al.*, 1999). Vomiting, diarrhea, increased thirst, panting or restlessness, polyuria, and tachycardia are the most common clinical signs of chocolate poisoning (Hooser and Beasley, 1986; Beasley *et al.*, 1999). A high proportion of sugar and fat present in chocolate can lead to gastrointestinal signs. Excessive urination, ataxia, tremors, and seizures may also occur in severe cases. Premature ventricular contractions, tachypnea, cyanosis, hypertension, hyperthermia and coma are some of the serious consequences (Kovalkoviova *et al.*, 2009). Bradycardia and hypotension have been observed in some cases of chocolate poisoning but though they occur less frequently. Hypokalemia may develop in the later stages of the poisoning, leading to cardiac dysfunction. There is possibility of fatalities in some cases (Drolet *et al.*, 1984; Dolder, 2013). Death is usually attributed to cardiac arrhythmias, respiratory failure or hyperthermia (Jansson *et al.*, 2011).

Caffeine reaches its maximum serum levels within 30 to 60 minutes after being ingested. In contrast, the absorption rate of theobromine is slower than that of caffeine, reaching its

maximum plasma concentration approximately two hours' post-consumption. Due to its long half-life, theobromine remains in the bloodstream for a longer period of time, which may result in symptoms from high doses persisting for several days. Furthermore, caffeine is metabolised to theobromine, reaching its peak plasma concentration approximately 6 to 8 hours' post-consumption (Loffler *et al.*, 2000a; 2000b). The metabolism of both methylxanthines occurs in the liver, followed by excretion through the bile ducts and go through enterohepatic circulation (Dolder, 2013).

Theobromine and caffeine act as competitive inhibitors of cellular adenosine receptors, thereby inhibiting the activity of adenosine on the central nervous system (CNS). This inhibition results in CNS stimulation, which induces contraction of cardiac muscle, leading to tachycardia, as well as relaxation of smooth muscles, resulting in bronchodilation and diuresis (Choi *et al.*, 1988). Moreover, methylxanthines increase intracellular calcium concentration by facilitating the influx of calcium into cells while simultaneously decreasing the intracellular sequestration of calcium in the sarcoplasmic reticulum of striated muscles. This results in enhanced the contractility of skeletal muscles. Furthermore, methylxanthines also inhibit the reabsorption of calcium by cells, which increases the levels of free calcium and subsequently improves the contractility of both the cardiac and skeletal muscles (Papsa and Vassalle, 1984). Methylxanthines exert an additional effect by inhibiting phosphodiesterase, which leads to an increase in cAMP concentration, thereby producing a sympathomimetic effect. Furthermore, methylxanthines also elevate the concentration of epinephrine and norepinephrine in the blood.

In the present case, intravenous fluid therapy was given to stabilize the cardiovascular function and hasten urinary excretion of methylxanthines and their metabolites as these can be reabsorbed from the urinary bladder. B blocker was given to treat tachyarrhythmia of ventricular origin which are frequently observed in chocolate poisoning. Use of corticosteroids in treatment of chocolate toxicosis should be avoided, as they prolong the excretion of methylxanthines (Kovalkoviova *et al.*, 2009). Gastrointestinal decontamination, such as gastric lavage, inducing emesis and administering activated charcoal to prevent theobromine absorption from gastrointestinal tract should be performed once the patient is stable or when presented prior to the development of clinical signs, preferably within one hour following ingestion. Gastrointestinal decontamination was not performed in the present case to avoid aspiratory

pneumonia as the dog was laterally recumbent and presented to clinic after two days of intoxication.

## 5. Conclusion

Chocolate poisoning is a critical health issue that requires immediate medical attention. If there is any suspicion that your pet has consumed chocolate, it is crucial to seek veterinary assistance immediately to avoid serious complications. Since there is no specific antidote for chocolate poisoning, patient must be managed based on the clinical manifestations. Pet owners should be made aware of potential adverse effect and toxicoses caused by feeding of chocolates to their pets. By understanding the potential risks, the likelihood of accidental exposure or chocolate poisoning in pets can be avoided.

## References

- Beasley, V. R., Dorman, D. and Fikes, J. (1999). A Systems Affected Approach to Veterinary Toxicology. University of Illinois College of Veterinary Medicine, Urbana, IL, pp. 116-120.
- Choi, O. H., Shamim, M. T., Padgett, W. L. and Daly, J. W. (1988). Caffeine and theophylline analogues: correlation of behavioral effects with activity as adenosine receptor antagonists and as phosphodiesterase inhibitors. *Life sciences*, 43(5),387-398.
- Dolder, L. K. (2013) Methylxanthines: caffeine, theobromine, theophylline. In: *Small Animal Toxicology*. 3<sup>rd</sup> edn. Eds M. E. Petersen and P. A. Talcott. WB Saunders, pp 647-652.
- Drolet, R., Arendt, T. D. and Stowe, C. M. (1984). Cacao bean shell poisoning in a dog. *Journal of the American Veterinary Medical Association*, 185(8), 902-902.
- Hooser, S.B. and Beasley, V. R. (1986). Methylxanthine poisoning (chocolate and caffeine toxicosis). In: *Current Veterinary Therapy for Small Animal Practice IX*. WB Saunders, Philadelphia, PA, pp 191-192.
- Jansson, D.S., Galgan, V., Schubert, B. and Hard af Segerstad, C. (2001). Theobromine intoxication in a red fox and a European badger in Sweden. *Journal of Wildlife Diseases*, 37, 362-365.
- Kovalkovicova, N., Sutiakova, I., Pistl, J. and Sutiak, V. (2009). Some food toxic for pets. *Interdisciplinary toxicology*, 2(3), 169-176.
- Loffler, B., Kluge, K., Ungemach, F. R. and Kietzmann, M. (2000b). Concentrations of caffeine, theophylline and theobromine in plasma and urine of dogs after application of coffee, tea and chocolate and its relevance to doping. *Tierärztliche Praxis Ausgabe K Kleintiere Heimtiere*, 28(2), 79-86.

- Loffler, B., Kluge, K., Ungemach, F. R. and Kietzmann, M. (2000a). Investigation on the pharmacokinetics of caffeine, theophylline and theobromine in the dog. *Tierärztliche Praxis Ausgabe Kleintiere Heimtiere*, 28(2), 71-78.
- Paspa, P. and Vassalle, M. (1984). Mechanism of caffeine-induced arrhythmias in canine cardiac Purkinje fibers. *The American Journal of Cardiology*, 53(2), 313-319.
- Weingart, C., Hartmann, A. and Kohn, B. (2021). Chocolate ingestion in dogs: 156 events (2015-2019). *Journal of Small Animal Practice*, 62(11), 979-983. doi: 10.1111/jsap.13329.
- Zoumas, B. L., Kreiser, W. R. and Martin, R. A. (1980). Theobromine and caffeine content in chocolate products. *Journal of Food Science*, 45(2), 314-316.

UNDER PEER REVIEW