

Evaluation of Radiographic Methods for Detecting Left Atrial Enlargement in Dogs with Mitral Valve Disease

ABSTRACT:

Aim: To evaluate the utility of four radiographic methods for assessing cardiomegaly and left atrial enlargement in dogs with myxomatous mitral valve disease (MMVD)

Study design: Thirty-one client owned dogs with varying severity of mitral valve disease were subjected to thoracic radiography and echocardiography.

Place and Duration of Study: Department of Veterinary Surgery and Radiology, DGCN College of Veterinary and Animal Sciences, between July 2023 to July 2024

Methodology: Thirty-one dogs with varying MMVD severity underwent thoracic radiography and echocardiography. Vertebral heart size (VHS), vertebral left atrial size (VLAS), radiographic left atrial dimension (RLAD), and left atrial (LA) Width were measured and compared with echocardiographic parameters.

Results: Radiographic indices (VHS, VLAS, RLAD, and LA Width) increased progressively with MMVD stage (B1, B2, and C). RLAD, and LA Width correlated significantly with echocardiographic LA/Ao ratio ($P < 0.01$). VHS, VLAS, and LA Width were easier to measure than RLAD.

Conclusion: Radiographic VLAS, RLAD, and LA Width are reliable alternatives to echocardiography for identifying left atrial enlargement in MMVD-affected dogs, with VHS offering utility when other measures are unavailable.

Key words: dogs, left atrial size, mitral valve disease, radiographic measurements

1.INTRODUCTION

Myxomatous mitral valve disease (MMVD) is the most common acquired heart disease in dogs characterized by progressive left sided cardiac remodeling leading to mitral regurgitation, left atrial volume and pressure overload. As disease advances, increased left atrial pressure causes increase in pulmonary capillary pressure resulting in life threatening pulmonary edema and left sided congestive heart failure (Borgarelli and Buchanan, 2012).

Left atrial enlargement is well-established as a precursor to congestive failure and is a strong prognostic indicator of MMVD in dogs (Borgarelli and Buchanan, 2012). Many diagnostic tools are available for identifying cardiomegaly and left atrial enlargement in dogs (Reid *et al.* 2020, Frost *et al.* 2021, Sun and Zhang, 2022). Echocardiography is recommended for definitive diagnosis and disease staging of MMVD but it is not necessarily available nor affordable to every dog, especially in the general practice setting. Thoracic radiography on the other hand is less expensive, easily available, and easy to perform. As such, the recently updated American College of Veterinary Internal Medicine (ACVIM) consensus statement for MMVD recommends the use of thoracic radiography, namely the vertebral heart size (VHS) and vertebral left atrial size (VLAS), to identify dogs with stage B2 MMVD, when echocardiography is unavailable to identify cardiac enlargement by which stage B2 is defined (Keene *et al.* 2019). When echocardiography is unavailable, assessment of left atrial size via thoracic radiography is a necessary criterion for classification of disease severity in dogs with myxomatous mitral valve disease (Lam *et al.* 2021).

Recently, number of objective radiographic measurements like vertebral heart score (VHS) to detect cardiomegaly (Atkins *et al.* 2009, Lamb *et al.* 2001), and vertebral left atrial size (VLAS), radiographic left atrial dimension (RLAD) and left atrial width (LA_{width}) to detect left atrial enlargement in MMVD stage B2 dogs have been proposed (Malcolm *et al.* 2018, Sanchez *et al.* 2018, Stepien *et al.* 2020, Wu *et al.* 2023). Early detection of preclinical (stage 2) MMVD will help in initiating standard treatment for congestive heart failure and slowing progression into clinical or end stage disease (stage D) which is refractory to standard therapy.

The objective of this study was to investigate the utility of radiographic measurements of the left atrium and the left ventricle as surrogates for echocardiographic criteria in identifying dogs with stage B2 myxomatous mitral valve disease.

2. MATERIALS AND METHODS

Thirty-one client owned dogs with varying severity of MMVD, aged 1.5 year to 16 years (mean age = 9.62 ± 3.53) and weighing 5.6 to 54 kg (mean body weight = 22.23 ± 13.20 kg) having complaint of lethargy, weight loss, exercise intolerance, respiratory distress, syncope, and abdominal distension were grouped into MMVD stages viz. stage B1, stage B2 and stage C as per the American College of Veterinary Internal Medicine (Keene *et al.* 2019).

Stage B1 (n=11, mean age= 9.81 ± 3.31 year; 6-16 years, mean body weight= 24.35 ± 11.53 kg; 8.4 to 50 kg) included asymptomatic dogs with systolic heart murmur and mitral regurgitation without echocardiographic left atrial enlargement. Stage B2 (n=3, mean age= 6.16 ± 5.34 year; 5-12 years, mean body weight= 15.66 ± 10.01 kg; 6-26 kg) included asymptomatic dogs with mitral regurgitation, echocardiographic left atrial and left ventricular enlargement described by a left atrium to aorta ratio (LA/Ao) ≥ 1.6 and normalized left ventricular internal dimension at end diastole (NLVIDd (cm) / body weight (kg)^{0.294}) ≥ 1.7 (Hansson *et al.* 2002, Cornell *et al.* 2004). Stage C (n=17, mean age= 10.11 ± 3.23 years; 3-15 years, mean body weight= 22.01 ± 14.83 kg; 5.6-54 kg) included symptomatic dogs with mitral regurgitation, severe left atrial enlargement, and previous or current clinical signs of congestive heart failure. Dogs with pleural and pericardial effusions were excluded from study.

2.1. THORACIC RADIOGRAPHIC MEASUREMENTS

Thoracic radiographic exposure was performed using an Allengers HF MARS 80' X-ray machine from Allengers Medical Systems, India, accompanied by a stationary grid with a grid ratio of 6:1. Exposed X-ray plates were subsequently subjected to scanning through a computed radiography system, Regius 110 from Konika Minolta Healthcare Pvt Ltd. The acquired images were processed using the Image Pilot software system, and all biometrical parameters were quantified utilizing the digital scale integrated into the software. Following radiographic measurements were taken:

2.1.1. Vertebral heart size (VHS)

Vertebral heart size was measured as per Buchanan and Bucheler (2000). Long axis (L) was measured from the ventral border of the largest main stem bronchus (carina) in cross section to the most distant ventral contour of cardiac apex. To include left atrial body, short axis (S) of heart in the central third region perpendicular to the long axis was measured starting at the level of the dorsal edge of the caudal vena cava (CVC). The caliper was repositioned over the vertebral column beginning with the cranial edge of T4 and distance spanned by caliper was estimated to the nearest 0.1 vertebral body length. The VHS was expressed as total units of vertebral length. Long and short axis dimensions was added to obtain a vertebrae or heart sum that indicated the heart size relative to body length. A measurement example is displayed in Figure

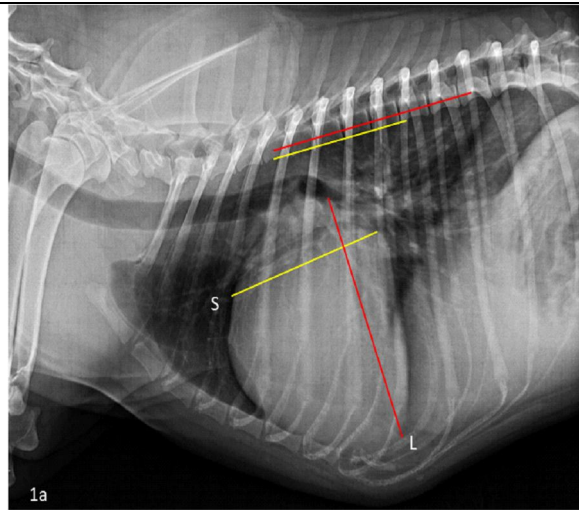
1a. The VHS was 13.8 vertebral units.

2.1.2. Vertebral left atrial size (VLAS)

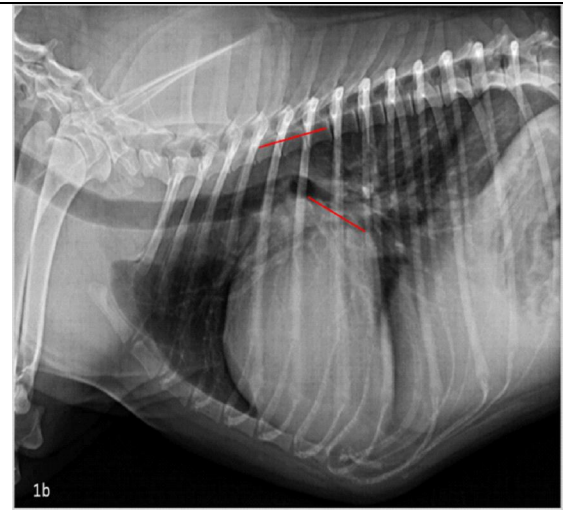
Vertebral left atrial size was measured as described by Malcolm *et al.* (2018). First line was drawn from the center of most ventral aspect of carina to the most caudal aspect of left atrium where it intersected with the dorsal border of caudal vena cava. Second line equal in length to the first was drawn beginning at the cranial edge of T4 and extending caudally just ventral and parallel to the vertebral canal. The VLAS was defined as the length of the second line expressed in vertebral-body units to the nearest 0.1 vertebra. A measurement example is displayed in Figure 1b. The VLAS was 3.0 vertebral body units.

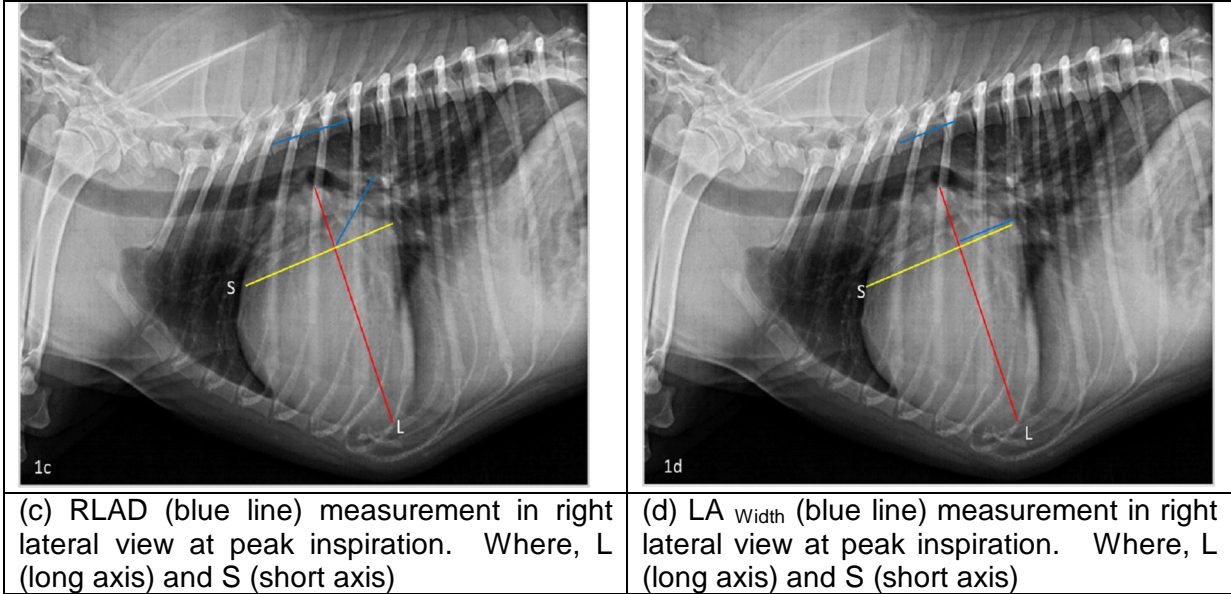
Fig.1. Radiographic measurements of heart and left atrium in dogs with mitral valve disease

(a) VHS measurement in right lateral view at peak inspiration. Where, L (long axis) and S (short axis)



(b) VLAS measurement (red line) in right lateral view at peak inspiration.





2.1.3. Radiographic left atrial size (RLAD)

Radiographic left atrial size was measured as described by Sanchez *et al.* (2018). A line was drawn bisecting the 90° angle formed by the intersection of the VHS long (L) and short (S) axes, extending from this point to the radiographic projection of the dorsal edge of the left atrium. Similar, to VHS a second line of equal length to that of bisecting line was drawn, starting at the cranial edge of T4 and extending caudally just ventral and parallel to the vertebral canal. RLAD was defined as the length of the bisecting line, expressed in vertebral-body units, measured to the nearest 0.1 vertebra. A measurement example is displayed in Figure 1c. The RLAD was 3.0 vertebral body units.

2.1.4. Left atrial width (LA_{width})

Left atrial width was measured as per Stepien *et al.* (2020). Similar for measuring the RLAD, two axes were drawn similarly as described for the VHS. The long axis was measured as for VHS and RLAD. Afterwards, the LA width line was drawn at a 90° angle at the height of the dorsal intersection between the cardiac silhouette and the caudal vena cava. This line was finally applied to the vertebral column beginning at the fourth thoracic vertebra, and the number of encompassed vertebrae was recorded as LA_{width}. A measurement example is displayed in Figure 1d. The LA_{width} was 2.2 vertebral body units.

2.2 ECHOCARDIOGRAPHIC MEASUREMENTS

2.2.1 Patient preparation and echocardiographic examination

Right side of thorax from 3rd to 6th rib and 1-5 cm lateral to sternum was prepared for echocardiographic examination. Dogs were manually restrained in right lateral recumbency. Echocardiography was performed using ACUSON X300 Premium Edition Diagnostic Ultrasound System by Siemens Medical Solutions USA, Inc., equipped with a 4.0-8.0 MHz multi-frequency phased array transducer. Left atrium to aorta ratio (LA/Ao) in right parasternal short-axis view in early diastole and left ventricular internal dimensions in diastole in right parasternal long axis view (LVIDD) were determined for identifying stage B2 preclinical MMVD. The LVIDDN was calculated using formula $LVIDDN = LVIDD / (\text{body weight [kg]}^{0.294})$ (Cornell *et al.* 2009) and the LA/Ao was calculated as described by Hansson *et al.* (2002).

2.3 STATISTICAL ANALYSIS

Data was analyzed by IBM SPSS Statistics 29.0 software. Means \pm standard deviation (SD) was calculated for each measurement. One-way analysis of variance (ANOVA) was used to compare mean values between different stages of MMVD. A P value $< .01$ was considered statistically significant.

3 RESULTS AND DISCUSSION

A total of 31 dogs (26 males;5 females) representing different breeds were grouped into MMVD stages, stage B1 (n=11), stage B2 (n=3) and stage C (n=17) as per the American College of Veterinary Internal Medicine (Keene *et al.* 2019) (Table 1). Mean age and body weight differed significantly ($P < .01$) between stages of MMVD. Dogs in stage B2 dogs were significantly ($P < .01$) younger and weighed less compared to dogs in stage B1 and stage C.

Comparison of radiographic and echocardiographic measurements in different stages of MMVD

All radiographic measurements of left atrial and left ventricular size increased with increasing severity of MMVD. Significant ($P < .01$) differences in the radiographic VHS, VLAS, RLAD, LA_{width} and echocardiographic LA/Ao and LVIDDN was observed between different MMVD stages. Radiographic VHS, VLAS, RLAD and LA_{width} and echocardiographic LA/Ao and LVIDDN were significantly ($P < .01$) higher in stage B2 and C of MMVD compared to stage B1 (Table 1), **in line with findings of Levicar *et al.* (2022)**. The values obtained were compared with reference values from literature (Table 2)

Vertebral heart size (VHS)

In stage B1, VHS was near to value reported by Lam *et al.* (2021) but lower than value reported by Vezzosi *et al.* (2021) and Levicar *et al.* (2022). In stage B2, VHS was near to value reported by Levicar *et al.* (2022) but slightly lower than values reported by Stepein *et al.* (2020), Lam *et al.* (2021) and Vezzosi *et al.* (2021). VHS in stage C was slightly greater than values reported in previous studies (Lam *et al.* 2021, Vezzosi *et al.*2021 and Levicar *et al.* 2022). Difference in VHS measurement in different studies could simply be because of variation in study samples, multiple breed associated variation (Lamb *et al.* 2001, Bavegems *et al.* 2005, Bodh *et al.* 2016), influence of respiratory and cardiac cycle (Olive *et al.* 2015), interobserver variability and variation in observer's selection of reference points and transformation of long and short axis dimensions into VHS units (Hansson *et al.* 2005) and different patterns of left atrial enlargement in different stages of MMVD.

In current study, a VHS of 11.2 vertebrae in stage B2 and 12.57 vertebrae in stage C to identify an echocardiographic LA/Ao ≥ 1.6 was greater than cutoff (10.5 vertebrae) recommended by the ACVIM guidelines for diagnosis of stage B2 MMVD (Keene *et al.* 2019). However, Poad *et al.* (2020) reported that vertebral heart size > 11.7 identifies dogs with echocardiographic left heart enlargement while vertebral heart size ≤ 10.8 excludes dogs with echocardiographic left heart enlargement.

Because VHS assesses overall cardiac silhouette rather than left atrial size, other radiographic measurements must be used for detecting a potential left atrial enlargement due to chronic mitral valve regurgitation in MMVD (Borgarelli and Buchanan 2012).

Table 1: Descriptive data for dogs with various stages of myxomatous mitral valve disease

Variable	Stage B1	Stage B2	Stage C	Overall	P value
Total dogs	11	3	17	31	-
Male/Female	9/2	2/1	15/2	26/5	

Breed	Non-descript (4) Labrador Retriever (2) Rottweiler (2) German Shepherd (2) Pug (1)	Pomeranian (2) Pointer (1)	Pomeranian (6) Non-descript (3) Labrador Retriever (3) French mastiff (2) Golden Retriever (2) Pointer (1)	Pomeranian (8) Non-descript (7) Labrador Retriever (5) German shepherd (2) Golden Retriever (2) Rottweiler (2) French mastiff (2) Pointer (2) Pug (1)	-
Age (year)	9.81 ± 3.31 ^a	6.16 ± 5.34 ^b	10.11 ± 3.23 ^c	9.62 ± 3.53	< .01
Body weight (kg)	24.35 ± 11.53 ^c	15.66 ± 10.01 ^b	22.01 ± 14.83 ^b	22.23 ± 13.20	<.01
VHS	10.3±0.46 ^a (9.5-11.3)	11.2±0.8 ^b (9.6-11.2)	12.57±1.04 ^c (11.0-14.2)	11.40±1.39 (9.5-14.2)	< .01
VLAS	2.02 ± 0.10 ^a (1.5-2.1)	2.5 ± 0.40 ^b (1.8-2.5)	2.83 ± 0.26 ^c (2.4-3.2)	2.28 ± 0.68 (3.7- 1.1)	< .01
RLAD	1.66 ± 0.32 ^a (1.1-2.1)	2.13 ± 0.25 ^b (1.9-2.4)	2.85 ± 0.45 ^c (2.3-3.7)	2.28 ± 0.68 (3.7- 1.1)	< .01
LA _{width}	1.46 ± 0.25 ^a (1.0-1.7)	1.7 ± 0.26 ^b (1.5-2.7)	2.26 ± 0.26 ^c (1.8-2.7)	1.87 ± 0.46 (2.7- 1.0)	< .01
LA/Ao	1.14±0.19 ^a	1.72±0.12 ^b	2.32±0.60 ^c	1.83 ±0.72	<.01
LVIDDN	1.25±0.19 ^a	1.79±0.10 ^b	1.99±0.35 ^c	1.71±0.75	<.01
Means with SDs provided for age, body weight, VHS, VLAS, RLAD, LA width, LA/Ao, LVIDDN ^a Significantly different compared to stages B2 and C (<i>P</i> < .01), ^b Significantly different compared to stages B1 (<i>P</i> < .01), ^c Significantly different compared to stages B1 and B2 (<i>P</i> < .01) Value within parathesis () indicate minimum and maximum values of each measurement Abbreviations: RL, right lateral VHS, vertebral heart size; VLAS, vertebral left atrial size; RLAD, radiographic left atrial dimension, LA _{width} , left atrial width, LA/Ao, left atrium- to-aortic root ratio; LVIDDN normalized left ventricular internal diameter at end diastole					

Table 2. Subjective comparison of radiographic and echocardiographic measurements with published reference values in dogs with myxomatous mitral valve disease

Variables	MMVD stage	Present study	Stepein <i>et al.</i> 2020	Lam <i>et al.</i> 2021	Vezzosi <i>et al.</i> 2021	Levicar <i>et al.</i> 2022
Radiographic measurements						
VHS	Stage B1	10.3 ±0.46	-	10.28 ±0.46	10.4 (9.2-11.6)	10.39 ±0.54
	Stage B2	11.2 ±0.8	11.6±0.9	11.61 ± 0.93	11.4 (9.9-13.6)	11.28 ± 0.72
	Stage C	12.57 ±1.04	-	12.04 ± 1.52	12.3 (10.6-13.5)	12.15 ± 1.12
VLAS	Stage B1	2.02±0.10	-	1.93 ± 0.33	2.1 (1.5-2.3)	2.09 ± 0.31
	Stage B2	2.59±0.32	2.7±0.5	2.66 ± 0.36	2.5 (1.8-3.5)	2.53 ± 0.4
	Stage C	2.83±0.26	-	2.92 ± 0.54	2.8 (2.0-3.6)	2.98 ± 0.45
RLAD	Stage B1	1.66 ± 0.32	-	1.54 ± 0.42	1.4 (1.1-2.0)	1.66 ± 0.34
	Stage B2	2.13 ± 0.25	-	2.34 ± 0.43	2.4 (1.8-3.3)	2.06± 0.48
	Stage C	2.85 ± 0.45	-	2.7 ± 0.66	2.8 (1.8-3.7)	2.72 ± 0.49
LA _{width}	Stage B1	1.46 ± 0.25	-	-	-	1.62 ± 0.29
	Stage B2	1.7 ± 0.26	2.0±0.3	-	-	2.02± 0.33
	Stage C	2.26±0.26	-	-	-	2.29±0.35
Echocardiographic measurements						
La/Ao	Stage B1	1.14±0.19	-	-	1.4 (1.2-1.8)	-
	Stage B2	1.72±0.12	2.0±0.4	-	2.0 (1.7-3.0)	-
	Stage C	2.32±0.60	-	6	2.5 (1.8-3.2)	-
LVIDDN	Stage B1	1.25±0.19	-	-	1.5 (1.1-1.8)	-

	Stage B2		2.0±0.2			
		1.79±0.10	-	-	1.9 (1.7-2.4)	-
	Stage C	1.99±0.35	-	-	2.1 (1.6-2.5)	-
VHS-vertebral heart score, VLAD- vertebral left atrial size, RLAD-radiographic left atrial dimension, LA-left atrium LA/Ao- Left atrium to aortic root ratio, LVIDDN- normalized left ventricular internal dimension at end diastole						

Vertebral left atrial size (VLAS)

VLAS in stage B1 was near to values reported by Vezzosi *et al.* (2021) and Levicar *et al.* (2022) and but higher than value reported by Lam *et al.* (2021). In stage B2, VLAS was near to values reported by Vezzosi *et al.* (2021) and Levicar *et al.* (2022) but lower than value reported by Stepein *et al.* (2020) and Lam *et al.* (2021). In stage C, VLAS was near to value reported by Vezzosi *et al.* (2021) but slightly lower than values reported by Lam *et al.* (2021) and Levicar *et al.* (2022) in dogs with MMVD (Table 2)

A VLAS ≥ 2.4 is considered best predictor of moderate to severe LA enlargement in dogs with MMVD (Lam *et al.* 2021). In current study, VLAS value of 2.5 vertebrae in stage B2 and 2.83 vertebrae in stage C to identify echocardiographic LA/Ao ≥ 1.6 was in line with originally proposed cut-off values of VLAS ≥ 2.3 vertebrae (Malcolm *et al.* 2018), ≥ 2.4 vertebrae (Lam *et al.* 2021), 2.3 vertebrae (Levicar *et al.* 2022), ≥ 2.5 vertebrae for stage B2 MMVD (Mikawa *et al.* 2020, Stepien *et al.* 2020)

Radiographic left atrial size (RLAD)

RLAD in stage B1 was greater than values reported by Lam *et al.* (2021) and Vezzosi *et al.* (2021) and but similar to the value reported by Levicar *et al.* (2022). In stage B2, RLAD was near to the value reported by Levicar *et al.* (2022) but slightly lower than value reported by Lam *et al.* (2021) and Vezzosi *et al.* (2021). In stage C, RLAD was near to value reported by Vezzosi *et al.* (2021) but slightly greater than value reported by Lam *et al.* (2021) and Levicar *et al.* (2022).

A RLAD ≥ 2.0 is the best predictor of moderate to severe left atrial enlargement (Vezzosi *et al.* 2021). In the present study, a RLAD of 2.13 in stage B2 and 2.85 in stage C was comparable with previously described cut-off values of RLAD ≥ 1.8 vertebrae (Sanchez *et al.* 2018, Vezzosi *et al.* 2021, Levicar *et al.* 2022) and ≥ 1.7 vertebrae (100% sensitive and 72.4% specific) (Lam *et al.* 2021) to detect left atrial enlargement.

Left atrial width (LA_{width})

Left atrial width in stage B1 and B2 of MMVD was lower than value reported by Levicar *et al.* (2022) but near to value reported by Levicar *et al.* (2022) in stage C MMVD

Correlation of VLAS, RLAD and LA_{width} with echocardiographically derived LA/Ao ratio

Positive but less significant correlation to LA/Ao for VLAS ($r = 0.38$; $P = 0.14$; Figure 2) was contrary to findings of Stepein *et al.* (2020) ($r = 0.46$; $P = <0.001$), Lam *et al.* (2021) ($r=0.76$, $P <.001$) and Vezzosi *et al.* (2021) ($r = 0.82$; $P < .0001$) who reported significant positive correlations between LA/Ao and VLAS in dogs with stage B2 MMVD. Significant positive correlation to LA/Ao for RLAD ($r=0.52$; $P = 0.03$; Figure 3) was in line with findings of Lam *et al.* (2021) ($r=0.75$, $P <.001$) and Vezzosi *et al.* (2021) ($r= 0.85$; $P < .0001$) in dogs with stage B2 preclinical MMVD. Significant positive correlation to LA/Ao for LA_{width} ($r = 0.57$; $P = 0.02$; Figure 4) was in line with findings of Stepein *et*

*al.*2020) ($r=0.54$; $P<0.001$) in dogs with preclinical myxomatous mitral valve disease.

Fig. 2 Correlation between radiographic vertebral left atrial size (VLAS) and echocardiographic left atrial to aortic root dimension ratio (LA/Ao)

Fig. 3. Correlation between radiographic left atrial size (RLAD) and echocardiographic left atrial to aortic root dimension ratio (LA/Ao)

Fig. 4. Correlation between radiographic left atrial width (LA_{Width}) and echocardiographic left atrial to aortic root dimension ratio (LA/Ao)

Comparison of difficulty in obtaining different radiographic measurements

VHS, VLAS and LA_{Width} measurement was easy to obtain compared to RLAD. The landmarks for the measurement of VHS, VLAS and LA_{Width} are more easily identifiable than the dorsal border of left atrium which represents one of the landmarks for measuring RLAD. The dorsal margin of left atrium was hard to identify in dogs having normal left atrial size (Stage B1) due to presence of neighbouring structures with radiopacity of soft tissues such as pulmonary vessels of caudal lung lobes, aorta or ribs superimposing on it (Sanchez *et al.* 2018, Vezzosi *et al.* 2021). However, presence of left atrial enlargement (stage B2 and stage C MMVD) makes it easier to distinguish dorsal margin of left atrium from neighbouring structures with soft tissue opacity. In addition, the dorsal margin of left atrium is not clearly identifiable in presence of cardiogenic pulmonary edema with perihilar and /or dorsocaudal distribution (Vezzosi *et al.* 2021). These points must be considered while identifying landmarks for the measurement of RLAD in clinical cases.

4. CONCLUSION

Radiographic VLAS, RLAD, and LA Width are reliable alternatives to echocardiography for identifying left atrial enlargement in MMVD-affected dogs, with VHS offering utility when other measures are unavailable.

DISCLAIMER (ARTIFICIAL INTELLIGENCE)

NO generative AI technologies such as Large Language Models (ChatGPT, COPILOT, etc) and text-to-image generators have been used during writing or editing of this manuscript.

Disclaimer (Artificial intelligence)

Option 1:

Author(s) hereby declare that NO generative AI technologies such as Large Language Models (ChatGPT, COPILOT, etc.) and text-to-image generators have been used during the writing or editing of this manuscript.

Option 2:

Author(s) hereby declare that generative AI technologies such as Large Language Models, etc. have been used during the writing or editing of manuscripts. This explanation will include the name, version, model, and source of the generative AI technology and as well as all input prompts provided to the generative AI technology

Details of the AI usage are given below:

- 1.
- 2.
- 3.

REFERENCES

- Bavegems, V., Van Caelenberg, A. & Duchateau, L. (2005). Vertebral heart size ranges specific for whippets. *Veterinary Radiology and Ultrasound*, 46(5), 400-403. <http://doi.10.1111/j.1740-8261.2005.00073.x>.
- Bodh, D., Hoque, M., Saxena, A. C., Gugjoo, M. B., Bist, D. & Chaudhary, J. K. (2016). Vertebral scale system to measure heart size in thoracic radiographs of Indian Spitz, Labrador retriever and Mongrel dogs. *Veterinary World*, 9(4), 371-376. <http://doi.10.14202/vetworld.2016.371-376>
- Borgarelli, M. & Buchanan, J. W. (2012). Historical review, epidemiology and natural history of degenerative mitral valve disease. *Journal of Veterinary Cardiology*, 14(1), 93-101. <https://doi.org/10.1016/j.jvc.2012.01.011>
- Borgarelli, M., Savarino, P. & Crosara, S. (2008). Survival characteristics and prognostic variables of dogs with mitral regurgitation attributable to myxomatous valve disease. *Journal of Veterinary Internal Medicine*, 22(1):120-128. <http://doi.10.1111/j.1939-1676.2007.0008.x>
- Buchanan, J.W. & Bucheler, J. (2000). Vertebral scale system to measure canine heart size in radiographs. *Journal of the American Veterinary Medical Association*, 216(2),210-214. <http://doi.10.2460/javma.2000.216.210>

- Cornell, C.C., Kittleson, M.D., Della Torre, P., Haggstrom, J., Lombard, C.W., Pedersen, H.D., Vollmar, A. & Wey, A. (2004). Allometric scaling of M-mode cardiac measurements in normal adult dogs. *Journal of Veterinary Internal Medicine*, 18(3), 311–321. <http://doi.10.1111/j.1939-1676.2004.tb02551.x>
- Duler, L., LeBlanc, N.L., Cooley, S., Nemanic, S. & Scollan, K.F. (2018). Inter reader agreement of radiographic left atrial enlargement in dogs and comparison to echocardiographic left atrial assessment. *Journal of Veterinary Cardiology*, 20 (5), 319–329. <https://doi.org/10.1016/j.jvc.2018.07.004>
- Frost, J. A., Ma, M., & Fox, P. R. (2021). Advances in imaging techniques for evaluating canine cardiac disease. *Journal of Veterinary Cardiology*, 33, 112–121. <https://doi.org/10.1016/j.jvc.2021.01.001>
- Hansson, K., Haggstrom, J. & Kvart, C. (2005). Interobserver variability of vertebral heart size measurements in dogs with normal and enlarged hearts. *Veterinary Radiology and Ultrasound*, 46(2):122-130. <http://doi.10.1111/j.1740-8261.2005.00024.x>
- Hansson, K., Haggstrom, J., Kvart, C. & Lord, P. (2002). Left atrial to aortic root indices using two-dimensional and M-mode echocardiography in cavalier King Charles spaniels with and without left atrial enlargement. *Veterinary Radiology and Ultrasound*, 43(6), 568–575. <http://doi.10.1111/j.1740-8261.2002.tb01051.x>
- Keene, B. W., Atkins, C. E., Bonagura, J. D., Fox, P. R., Haggstrom, J., Fuentes, V. L., Oyama, M. A., Rush, J. E., Stepien, R. & Uechi, M. (2019). ACVIM consensus guidelines for the diagnosis and treatment of myxomatous mitral valve disease in dogs. *Journal of Veterinary Internal Medicine*, 33:1127-1140. <http://doi.10.1111/jvim.15488>
- Lam, C., Gavaghan, B. J. & Meyers, F. E. (2021). Radiographic quantification of left atrial size in dogs with myxomatous mitral valve disease. *Journal of Veterinary Internal Medicine*, 35 (2),747-754. <http://doi.10.1111/jvim>
- Lamb, C. R., Wikeley, H., Boswood, A. & Pfeiffer, D. U. (2001). Use of breed-specific ranges for the vertebral heart scale as an aid to the radiographic diagnosis of cardiac disease in dogs. *Veterinary Record*,148:707-711. <http://doi.10.1136/vr.148.23.707>
- Levicar, C., Granados-Soler, J.L., Freise, F., Raue, J.F., Nolte, I. & Bach, J.P.(2022). Comparison of different radiographic scores with associated echocardiographic measurements and prediction of heart enlargement in dogs with and without myxomatous mitral valve disease. *Journal of Veterinary Cardiology*,44:1-12. <https://doi.org/10.1016/j.jvc.2022.08.004>
- Malcolm, E.L., Visser, L.C., Phillips, K.L. & Johnson, L.R. (2018). Diagnostic value of vertebral left atrial size as determined from thoracic radiographs for assessment of left atrial size in dogs with myxomatous mitral valve disease. *Journal of American Veterinary Medicine Association*, 253(8),1038–1045. <http://doi.10.2460/javma.253.8.1038>
- Mikawa, S., Nagakawa, M. & Ogi, H. (2020). Use of vertebral left atrial size for staging of dogs with myxomatous valve disease. *Journal of Veterinary Cardiology*, 30 (8),92-99. <http://doi.10.1016/j.jvc.2020.06.001>.

- Olive, J., Javard, R. & Specchi, S. (2015). Effect of cardiac and respiratory cycles on vertebral heart score measured on fluoroscopic images of healthy dogs. *Journal of American Veterinary Medicine Association*, 246(10),1091-1097. <http://doi.10.2460/javma.246.10.1091>.
- Poad, M. H., Manzi, T. J. & Oyama, M. A. (2020). Utility of radiographic measurements to predict echocardiographic left heart enlargement in dogs with preclinical myxomatous mitral valve disease. *Journal of Veterinary Internal Medicine*,34 (5),1728-1733. <http://doi.10.1111/jvim.15854>.
- Reid, K., Sullivan, M., & Meyer, M. (2020). Use of advanced imaging technologies in the assessment of canine heart diseases. *Journal of Small Animal Practice*, 61 (6), 325-332. <https://doi.org/10.1111/jsap.2020.61.issue-6>
- Sanchez Salguero, X. Prandi, D., Llabres-Diaz, F., Manzanilla, E.G., & Bussadori, C. (2018). A radiographic measurement of left atrial size in dogs. *Iranian Veterinary Journal*, 71, 1–7. <http://doi.10.1186/s13620-018-0137-x>.
- Stepien, R. L., Rak, M. B. & Blume L. M. (2020). Use of radiographic measurements to diagnose stage B2 preclinical myxomatous mitral valve disease in dogs. *Journal of American Veterinary Medicine Association*, 256(10),1129-1136. <http://doi.10.2460/javma.256.10.1129>.
- Sun, Y., Li, H., & Zhang, H. (2022). Comparative study of echocardiography and radiography for left atrial size assessment in dogs. *Veterinary Radiology & Ultrasound*, 63(5), 511-518. <https://doi.org/10.1111/vru.2022.63.issue-5>
- Vezzosi, T., Puccinelli, C., Citi, S. & Tognetti, R. (2021). Two radiographic methods for assessing left atrial enlargement and cardiac remodeling in dogs with myxomatous mitral valve disease. *Journal of Veterinary Cardiology*,34(4),55-63. <http://doi.10.1016/j.jvc.2021.01.002>
- Wu, J., Yang, S., & Liu, Y. (2023). New insights into heart size measurement techniques in canine cardiac disease. *Veterinary Journal*, 276, 105026. <https://doi.org/10.1016/j.tvjl.2023.105026>