

## **Case report**

# **Laparoscopic repair of ileal perforation post blunt abdominal trauma: A Case Report.**

### **Abstract**

Blunt trauma to the abdomen is considered one of the most leading causes of death among all age groups. Although the outcome of patients with blunt abdominal injury has improved in the last two decades, in patients with multiple organ injuries, the in-hospital mortality rate was reported as 3–10%. Delayed diagnosis of small bowel perforation can result in serious complications and death, making timely diagnosis critical in the treatment of these patients. The diagnosis of small bowel perforation is usually made by imaging techniques that detect the presence of fluids or gases in the peritoneum or mediastinum. There are different treatment options for small bowel perforation; conservative treatment is not favoured.

Herein, we present the case of a 35-year-old gentleman diagnosed with a perforated viscus following a road traffic accident. A diagnostic laparoscopy was performed, and a 1 cm perforation of the terminal ileum was repaired. Postoperative recovery was uneventful except for mild paralytic ileus. The patient was discharged 8 days later and

reviewed at the surgical outpatient department after one- and two-months post-surgery, with no reported complaints.

**Keywords:** Blunt abdominal trauma, Ileal perforation, laparoscopic repair, Road traffic accident.

## **Introduction**

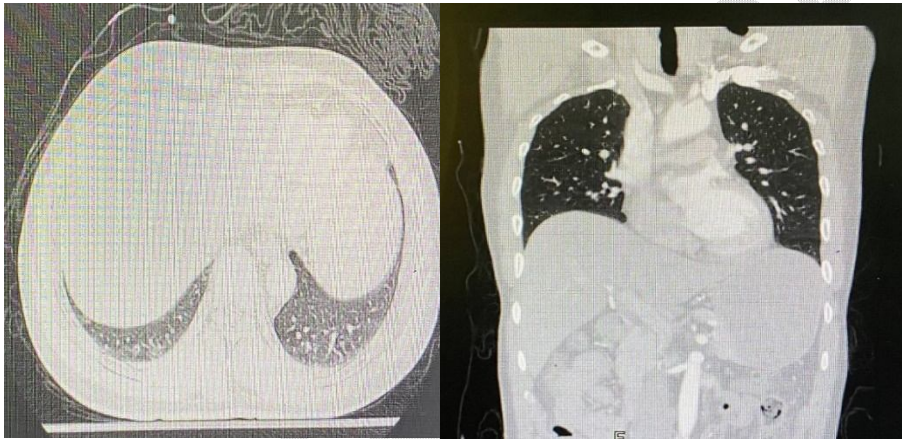
"Blunt trauma to the abdomen is considered one of the most leading causes of death among all age groups. Thus, it is an important topic of discussion and research"(1). "Although the outcome of patients with blunt abdominal injury has improved in the last two decades, in patients with multiple organ injuries, the in-hospital mortality rate was reported as 3–10%" (2). There are many causes of blunt abdominal trauma (BAT) such as assault, falls from height, and animal attacks. However, road traffic accidents (RTA) are considered the most common cause of BAT to the abdomen. (3,4). "The diagnosis of small bowel perforation in patients with BAT is infrequent as the injury needs to be severe to cause perforation. A hollow viscus injury is not usually suspected unless the clinical condition is highly suggestive"(4). "A delay in the diagnosis and treatment of the hollow viscus injury will cause the development of peritonitis, and hemodynamic instability leading to increased mortality and morbidity"(3). "Although small bowel perforation is rare, it is a clinically complex medical condition with high

mortality and should be diagnosed and managed early for a better prognosis" (5). Properly managing small bowel perforation can go through early stabilisation, administration of antibiotics, and surgical source control, with prompt operative intervention(6).

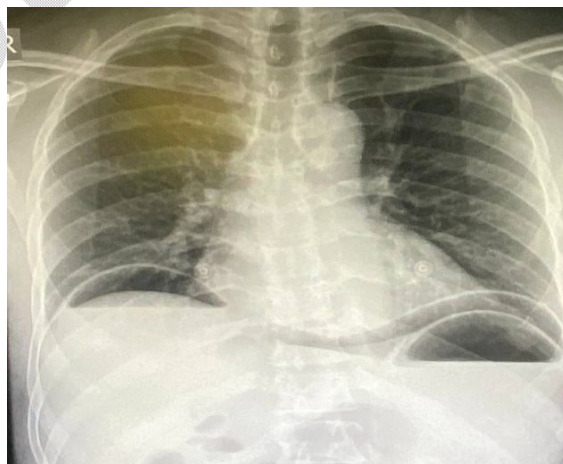
### **Case report**

A 35-year-old gentleman presented to the emergency room of the casualty department in an emergency center away from our hospital by about 80 Kilometers at 2:00 am following RTA, he was complaining of right-side abdominal pain. He was vitally stable, and his abdominal examination showed right-sided abdominal tenderness. His labs were normal (WBCs 8.5, Hb 12.4). He was managed according to the ATLS protocol. His chest and pelvic X-rays were normal. Pan computed tomography( PAN-CT) (brain, chest abdomen and pelvic) was requested, which revealed minimal pelvic free fluid with mild ascending colon oedema (Figure 1). At 5:00 am, the patient was admitted to our hospital for observation. A serial abdominal examination was started, but the abdominal examination revealed board-like rigidity at 9:00 am. The patient was shifted to the operating theatre at 9:30 am as an erect chest x-ray revealed massive air under the diaphragm (Figure 2). Diagnostic laparoscopy was started, and we found intestinal contents inside the peritoneal cavity then running of the small bowel was done

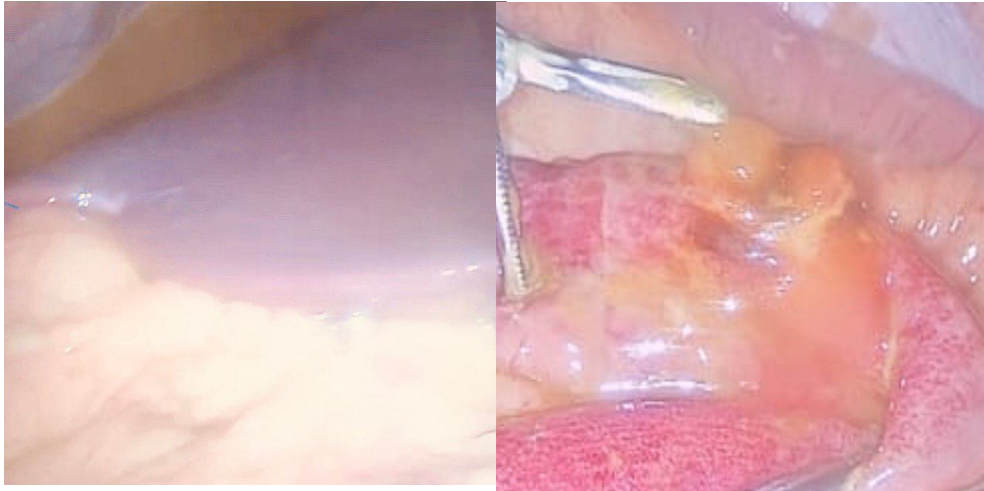
and revealed a 1 cm perforation at the ileum, about 120 cm from the ileocaecal junction (Figure3). Laparoscopic repair was done by Vicryl 2/0 in 2 layers and generous peritoneal washing with warm saline and 2 drains were fixed one in the pelvis and one subdiaphragmatic above the liver. post-operative recovery was complicated by paralytic ileus, and the patient was discharged after 8 days. After 1 month and 2 months, the patient was reviewed in the surgical outpatient clinic, and he has no complaints.



**Figure1: CT abdomen, NO pneumoperitoneum was detected.**



**Figure2:ERECT CHEST X-RAYshowing bilaterally massive pneumoperitoneum.**



**Figure3: Intraoperative finding of intestinal contents and the perforation of the ileum.**

## Discussion

Because of modern life, developments in industry, various transport systems and violence, there is an increase in the number of patients with BAT (7). The bowel injury following BAT is frequently undetected, so the diagnosis is usually too late despite advanced imaging techniques such as focused abdominal sonography for trauma and computed tomography scans (8). Apart from our patient, he was diagnosed within hours and was in the operating theatre within about 7-8 hours. Traumatic causes of small bowel perforation can be due to blunt or penetrating injuries (our case was after BAT) (9). The small bowel occupies the majority of the abdominal cavity, making it the most frequently injured hollow organ in the abdomen, particularly in cases of penetrating trauma such as stab wounds or gunshots. Blunt abdominal

trauma due to RTA is one of the most common causes of small bowel perforation (as seen in our case). Seat-belt users account for approximately 75% of gastrointestinal trauma with potential perforation(10). There are two types of small bowel perforation: free or contained perforation. Free perforations create an open hole that allows the intestinal material to escape into the normally sterile peritoneal cavity and can cause infection, inflammation, and other complications to the surrounding tissues and organs ( as you can see in our case). On the other hand, contained perforations are those in which an ulcer creates a full-thickness hole, but the adjacent organs seal it and prevent the free spillage of the intestinal content (11). "A high degree of suspicion of intra-abdominal injuries, even in cases following minor trauma will prevent the diagnostic errors. Early diagnosis and effective management of gastrointestinal perforations ( as revealed in our case) following BAT to the abdomen helps in decreasing overall morbidity and mortality among these patients" (12). "The symptoms of small bowel perforation may range from localised abdominal pain to systemic symptoms like fever, nausea, vomiting, and even shock. Additionally, rigidity, guarding, and other peritoneal signs which may appear later"(13). "Although erect plain X-rays are usually the first imaging option to start with and can detect signs of perforation, they cannot localise the site of perforation" (14). The abdominal computed

tomography scan is regarded as the imaging modality of choice for hemodynamically stable patients; however, negative results don't rule out the diagnosis of small bowel perforation (15)(as in our case, **NO** pneumoperitoneum in the abdominal computed tomography was detected). In the **EAST trial**, 13% of the study samples who were discovered to have a small bowel perforation at laparotomy had no positive findings before surgery (16). "Delays in the diagnosis of small bowel perforation can result in serious complications and death, making timely diagnosis critical in the treatment of these patients" (17). In trauma patients, laparoscopic interventions with normal haemodynamic parameters are an excellent modality to identify any abdominal injuries. Laparoscopy is more efficient and cost-effective and associated with fewer complications in comparison with traditional laparotomies (18). Although there are different options of treatments for the perforation of the small bowel, conservative treatment is not favoured (19). Laparoscopy and open surgery (primary repair, anastomosis, and stoma) are mainly used, which may be related to timely preoperative management, good resuscitation of septic shock, and timely application of broad-spectrum antibiotics in the perioperative period (20). The mortality rates among patients diagnosed with BAT with small bowel perforation are linked to the delay in initial diagnosis, development of multi-organ failure, and sepsis

as emphasized by the **EAST trial**, which reported a rise in mortality rate from 4% to 16% when the diagnosis is delayed for more than 24h. it was further highlighted that when small bowel perforation was present the mortality rate rose from 14% to 19% (10).

## **Conclusion**

Small bowel perforation following blunt abdominal trauma is rare. Thorough clinical assessment through serial abdominal examinations, alongside investigations that may sometimes be inconclusive, and timely surgical intervention can play a crucial role in reducing morbidity and mortality. The minimally invasive techniques such as laparoscopy offer an excellent option for the effective management of blunt abdominal trauma.

## **ETHICAL APPROVAL**

The author(s) have collected and preserved written ethical approval as per international or university standards.

## **CONSENT**

Written informed consent was obtained from the patient for publication of this case report and accompanying images.

**DISCLAIMER: NO generative AI technologies were used.**

Disclaimer (Artificial intelligence)

Option 1:

Author(s) hereby declare that NO generative AI technologies such as Large Language Models (ChatGPT, COPILOT, etc.) and text-to-image generators have been used during the writing or editing of this manuscript.

Option 2:

Author(s) hereby declare that generative AI technologies such as Large Language Models, etc. have been used during the writing or editing of manuscripts. This explanation will include the name, version, model, and source of the generative AI technology and as well as all input prompts provided to the generative AI technology

Details of the AI usage are given below:

- 1.
- 2.
- 3.

## References

- 1. Dauterive AH, Flancbaum L, and Cox EF.** Blunt Intestinal Trauma A Modern-day Review. Ann Surg J. 1985;201(02):198-203.
- 2. Mirzamohamadi S, HajiAbbasi MN, Baigi V, Salamati P, et al.** Patterns and outcomes of patients with abdominal injury: a multicenter study from Iran. BMC emergency medicine. 2024 May 31;24(1):91.
- 3. Hughes TMD and Elton C.** The Pathophysiology and Management of Bowel and Mesenteric Injuries Due to Blunt Trauma. Ann Surg J. 2002;33:120-8.

**4. Kurane SB and Ugane SP.** A clinical study of hollow viscus injury due to blunt trauma abdomen. *Int J Res Med Sci.* 2017;5(11):5017.

**5. Onken F, Senne M, Königsrainer A, and Wichmann D:** Classification and treatment algorithm of small bowel perforations based on a ten-year retrospective analysis. *J Clin Med.* 2022, 11:5748. 10.3390/jcm11195748

**6. Fakhry SM, Allawi A, Ferguson PL, Michetti CP, Newcomb AB, Liu C, and Brownstein MR:** Blunt small bowel perforation (SBP): an Eastern Association for the Surgery of Trauma multicenter update 15 years later. *J Trauma Acute Care Surg.* 2019, 86:642-650.

**7. Bouzat P, Valdenaire G, Gauss T, Charbit J, Arvieux C, Balandraud P, Bobbia X, David JS, Frandon J, Garrigue D, and Long JA.** Early management of severe abdominal trauma. *Anaesthesia Critical Care & Pain Medicine.* 2020 Apr 1;39(2):269-77.

**8. Yavaş Ö, Çelik A, Altuntaş G, Altuntaş M, Bilir Ö, and Ersunan G.** The role of repeated extended FAST in patients with stable blunt thoracoabdominal trauma. *Turkish Journal of Trauma & Emergency Surgery/Ulusal Travma ve Acil Cerrahi Dergisi.* 2023 May 1;29(5).

**9. Aljehaiman F, Almalki FJ, Alhusain A, Alsalamah F, Alzahrani K, Alharbi A, and Alkhulaiwi H.** Prevalence, Pattern, Mortality, and

Morbidity of Traumatic Small Bowel Perforation at King Abdulaziz Medical City: A Retrospective Cohort Study. *Cureus*. 2024 Jan 15;16(1):e52313.

**10. Staab V, Naganathan S, McGuire M, Pinto JM, and Pall H.** Gastrointestinal Perforation with Blunt Abdominal Trauma in Children. *Children (Basel)*. 2024 May 21;11(6):612.

**11. Hafner J, Tuma F, Hoilat GJ, and Marar O.** Intestinal perforation. *InStatPearls [Internet]* 2023 Aug 8. StatPearls Publishing.

**12. Gurav SP, Quraishi AH, Umare G, and Tongse PS.** A prospective observational study of gastrointestinal perforations following blunt trauma abdomen. *International Surgery Journal*. 2024 Apr 29;11(5):737-743.

**13. Katwal S, Ghimire A, and Joshi N.** Uncommon presentation: isolated small bowel perforation after blunt abdominal trauma in a pediatric patient; a case report. *Annals of Medicine and Surgery*. 2023 Dec 1;85(12):6222-6226.

**14. Kulinna-Cosentini C, Hodge JC, and Ba-Ssalamah A.** The role of radiology in diagnosing gastrointestinal tract perforation. *Best Practice & Research Clinical Gastroenterology*. 2024 Jun 7:101928.

**15. Bini R, Ronchetta C, Picotto S, Scozzari G, Gupta S, Frassini S, and Chiara O.** Importance of CT-scan predicting clinical outcomes in gastrointestinal perforation. *Annals of Translational Medicine.* 2020 Nov;8(21).

**16. Loftus TJ, Morrow ML, Lottenberg L, Rosenthal MD, Croft CA, Smith RS, Moore FA, Brakenridge SC, Borrego R, Efron PA, and Mohr AM.** Occult bowel injury after blunt abdominal trauma. *Am J Surg.* 2019 Aug;218(2):266-270.

**17. Fakhry SM, Allawi A, Ferguson PL, Michetti CP, Newcomb AB, Liu C, and Brownstein MR.** Blunt small bowel perforation (SBP): an Eastern Association for the Surgery of Trauma multicenter update 15 years later. *Journal of Trauma and Acute Care Surgery.* 2019 Apr 1;86(4):642-650.

**18. El-Bendary YB, Al-Adawi J, and Al-Qadhi H.** The Use of Laparoscopy in the Management of Trauma Patients: Brief review. *Sultan Qaboos Univ Med J.* 2016 Feb;16(1):e9-e14.

**19. Pouli S, Kozana A, Papakitsou I, Daskalogiannaki M, and Raissaki M.** Gastrointestinal perforation: clinical and MDCT clues for identification of aetiology. *Insights into imaging.* 2020 Dec;11:1-9.

**20. Li Z, Li S, Wu C, Liu Z, Zhao Y, Luan J, Miao S, and Wang P.** Diagnostic and therapeutic procedures of small bowel perforation: A retrospective monocentric cohort study. *World Journal of Surgical Infection*. 2023 Jan 1;2(1):7-11.

UNDER PEER REVIEW