

Splenic Lymphangioma in a 35 year old lady: A rare case report

ABSTRACT

Lymphangioma is a benign cystic neoplasm that results from congenital malformation of the lymphatic system. Among them, splenic lymphangioma is a rare entity accounting for only <0.007% of all tumors. This case highlights the importance of considering splenic lymphangioma in the differential diagnosis of cystic splenic lesions. Most of the patients are symptomless and it is detected incidentally. A 35-year-old lady presented to a tertiary care hospital of Dhaka, Bangladesh with abdominal pain and fatty food intolerance. On abdominal examination, splenomegaly was noted incidentally. Ultrasonography of whole abdomen showed features of chronic calculus cholecystitis with multiple hypoechoic area in spleen indicating multiple cystic lesion of spleen. Her echinococcal antibody tests were negative. Contrast CT scan of abdomen showed enlarged spleen with multiple cystic lesions indicating polycystic splenic disease associated with gall stones. After proper counseling, she underwent laparoscopic cholecystectomy with open splenectomy. Though she was planned for laparoscopic splenectomy, open conversion was required for huge size of spleen. Her post-operative period was uneventful. She was advised for post splenectomy vaccination and prophylactic antibiotics. Follow up after 1 and 3 months showed no abnormality.

Keywords: lymphangioma, Spleen, Splenectomy, Abdominal mass

INTRODUCTION:

Lymphangioma is a benign cystic neoplasm that results from congenital malformation of the lymphatic system.¹ This slow-growing tumor is usually seen in paediatric population.² Lymphangioma is rarely seen in adult patients. The commonly involved sites are the neck (75%) and axilla (20%).³ "The abdominal cystic lesions are preferably localized in the mesentery and the omentum".⁴ "When it involves several sites, it presents as lymphangiomatosis syndrome".⁴

Primary neoplasms of the spleen are an extremely rare condition presenting a challenge in diagnosis and management. They can be both benign and malignant. Among them, splenic lymphangiomas are an exceptional entity which is a benign tumor resulting from lymphatic malformation.⁵

Most of the patients are symptomless and it is detected incidentally. Sometimes, it can be presented as an abdominal mass with vague symptoms like abdominal pain, discomfort, nausea and vomiting. Rarely, complications like intracystic hemorrhage, coagulopathy, hypersplenism and portal hypertension are observed.⁶ Lymphangioma can be solitary or multiple in number. "The differential diagnosis of splenic lymphangioma includes hydatid cyst, hemangioma and splenic infarction".⁶ "There are two hypotheses for the formation of lymphangioma of the spleen: (1) congenital malformation of the spleen and (2) inflammation of the lymphatic system causing obstruction and resulting in formation of lymphangioma".⁶ In the first hypothesis, it is thought that lack of communication between

lymphatic ducts result in dilation of terminal ends and formation of large lymphatic sacs. On the contrary, in the second hypothesis it is mentioned that intrauterine or post-partum inflammations of lymphatic ducts may lead to obstruction of lymphatic ducts which resulted in formation of malformed large lymphatic sacs.

"Microscopically, these cysts are composed up of multiple vascular channels lined by single layer of endothelial cells and contain eosinophilic proteinaceous materials".⁷ "Lymphangiomas are classified into three types according to the size of the lymphatic channels: (1) capillary (2) cavernous and (3) cystic".⁷ Cystic lymphangiomas are the commonest variant and has a honeycomb appearance of varying sizes of cysts containing lymph lined by a thin endothelium.⁷

Radiological imaging is the main modality of diagnosis of splenic lymphangioma. Cystic lesions of the spleen are difficult to diagnose on radiological findings as they mimic parasitic cysts and other vascular malformations. Imaging tools like ultrasonography, CT scan or MRI are useful to detect splenic lymphangomas. "Ultrasound reveals numerous hypoechoic cysts with hyperechoic septa, as well as visible calcifications".⁸ "CT scan typically reveals subcapsular cysts that are finely defined, thin-walled and have low density".⁸ "IMMUNOHISTOCHEMICAL staining includes FVIII-Rag, CD31, CD34 and D2-40 (a selective marker for lymphatic endothelium) for the identification of endothelial cell lining".⁸ "Surgical resection is the mainstay of treatment of splenic lymphangioma to prevent possible complications like splenic rupture, hemorrhage and infection".⁹ "Although total splenectomy is gold standard for the management of splenic lymphangioma, partial splenectomy is becoming popular day by day".¹⁰ "But it has an increased risk of recurrence in the splenic remnant. Both open and laparoscopic approaches can be made based on patient characteristics, the surgeon's expertise and the extent of splenic enlargement".¹⁰

Here we present a rare case of splenic lymphangioma in a 35-year-old lady presented with gall stone disease.

PRESENTATION OF CASE:

A 35-year-old lady presented to a tertiary care hospital of Dhaka, Bangladesh with abdominal pain and flatulent dyspepsia. Her abdominal pain was in right hypochondriac region which was mild to moderate, dull aching, non-radiating aggravated on taking food and relieved by taking analgesics. On abdominal examination, splenomegaly was noted incidentally. Spleen was non tender, firm in consistency and enlarged about 9 cm from left coastal margin. Her blood picture including complete blood count, liver function and renal function tests were within normal limits. Ultrasonography of whole abdomen showed features of chronic calculus cholecystitis with multiple hypoechoic area in spleen indicating multiple cystic lesion of spleen. Her echinococcal antibody tests were negative. Contrast CT scan of abdomen showed enlarged spleen with multiple cystic lesions indicating polycystic splenic disease associated with gall stones (Fig-1).

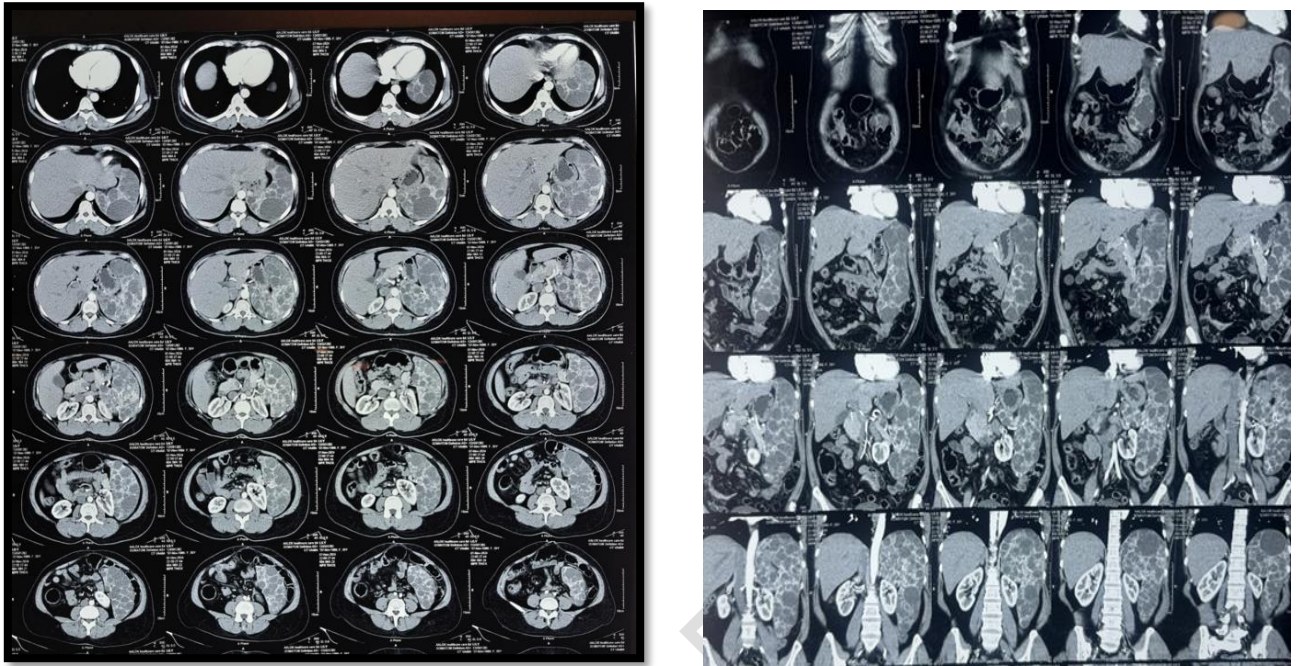


Fig-1 showing CT scan of the patient

After proper counseling, she underwent laparoscopic cholecystectomy with open splenectomy. Per operatively hugely enlarged spleen with multiple cystic lesions were observed (Fig-2). Initially she was planned for laparoscopic splenectomy but later converted to open procedure due to huge size of spleen and chance of intraoperative rupture of cyst. Her post-operative period was uneventful. She was discharged after 5th post-operative day and advised for post splenectomy vaccination for prevention of overwhelming post splenectomy infections (OPSI). Besides, for prophylaxis, she was also advised for taking phenoxymethylpenicillin. Her histopathological report revealed splenic cystic lymphangioma. Follow up visits after 1 and 3 months showed that she was in good health.

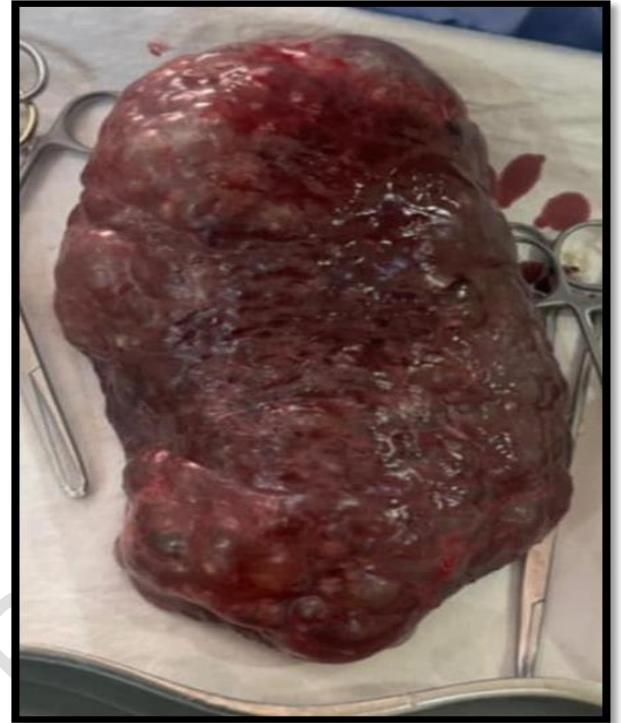
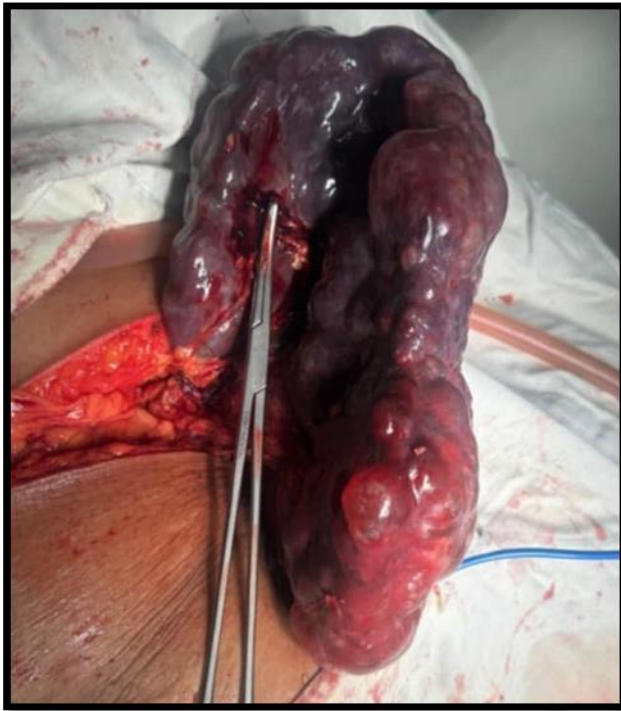
Fig-2 showing per-operative view

UNDER PEER REVIEW

DISCUSSION:

Splenic lymphangioma is a neoplasm of lymphatic system which is rarely seen and accounts for <0.007% of all tumor.¹¹ The tumor is benign in nature, usually manifested during childhood and hardly seen after 20 years of age.¹¹ During adulthood, the diagnosis is often made incidentally. In our present case, a 35 year old lady presented to us with features of chronic calculus cholecystitis with splenic lymphangioma which was diagnosed incidentally.

In 1885, Frink first reported about splenic lymphangioma.¹² So far, very few cases have been reported in the literature regarding splenic lymphangioma. In adults, most of the cases are observed in females above the age of 25.¹³ In our case, the patient was a 35 year old female showing similarities with previous reports.

Most of the patients of splenic lymphangioma usually do not show any symptoms as they are very slow growing. Occasionally they may present with mechanical discomfort, pain, nausea and vomiting. In our case, the patient originally presented to us for laparoscopic cholecystectomy but an additional diagnosis of splenic lymphangioma was made based on clinical and radiological findings.

Differential diagnoses of splenic lymphangioma include haemangioma, splenic abscess, parasitic cysts, simple cyst and post traumatic pseudocyst of spleen. Imaging modalities and blood picture are the tools to separate the differentials from lymphangioma.¹⁴

Among the imaging tools, ultrasonogram and CT scan of abdomen are most popular ones. It can detect the splenic pathology accurately. Besides, it can also give information about other abdominal pathologies which can help to manage the patient accordingly. In our case, the radiological diagnosis was made by CT scan of abdomen.

“There is a debate regarding splenic lymphangioma whether it is a neoplasm or a hamartoma”.¹⁵ “Most pathologists believe it is a hamartoma due to anomalous congenital dilation of the lymphatic vessels leading to formation of such neoplasm”.¹³ “Macroscopically, splenic lymphangioma can present as solitary, multiple or diffuse lymphangiomatosis”.¹³ It is usually located in subcapsular region consisting of a solitary large cyst with a thick fibrous wall or multiple cysts filled with clear fluid and separated by a fibrous septum.¹³ “Microscopically, these cysts are composed of acellular proteinaceous compounds lined by a thin wall. The surrounding tissue may be normal or may show congestion, fibrosis which is infiltrated by macrophages and lymphocytes”.¹⁴ Similar findings were also noted in our case.(fig-3)

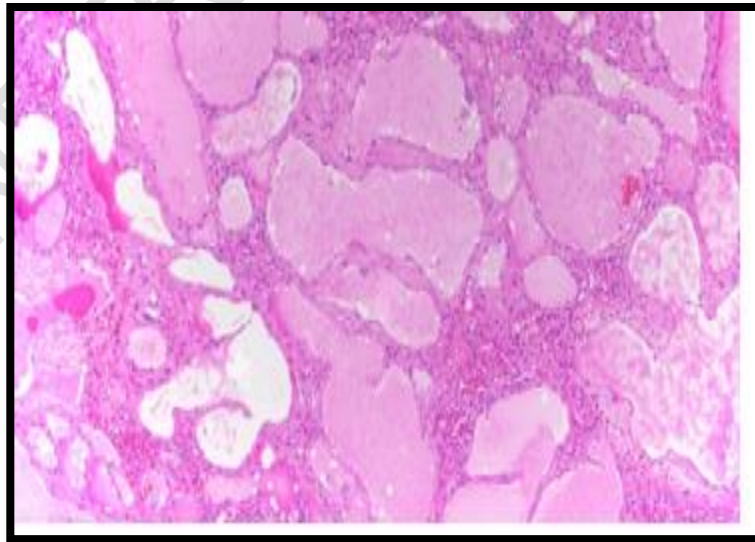


Fig3: Histopathology of splenic lymphangioma

Surgical resection is the treatment of choice in splenic lymphangioma.¹⁵ Surgery is done to avoid complications such as infection and rupture. Though laparoscopic splenectomy is getting popular day by day, open splenectomy is preferred because of its huge size and increased chance of per operative rupture of cyst. Total splenectomy is the surgical choice as partial splenectomy may give rise to recurrence.¹⁵ In the present case total splenectomy was performed as mentioned in different literature.¹⁵

CONCLUSION:

Lymphangiomas are benign neoplasms of the spleen that are infrequently found in adults. Most patients present with no symptoms and diagnosed incidentally. Though being uncommon, lymphangioma should be considered as a differential diagnosis of cystic lesions of the spleen. Splenectomy is the treatment of choice to provide better management to the patients.

CONSENT:

Patient's informed written consent was taken to publish her case for academic purpose.

ETHICAL APPROVAL:

As per international standards or university standards written ethical approval has been collected and preserved by the authors.

DISCALIMER (ARTIFICIAL INTELLEGENCE):

Author(s) hereby declare that NO generative AI technologies such as Large Language Models (ChatGPT, COPILOT, etc.) and text-to-image generators have been used during the writing or editing of this manuscript.

REFERENCES:

1. Ioannidis I, Kahn AG. Splenic lymphangioma. Arch Pathol Lab Med. 2015;139:278–282
2. Xiaoqing Hu, Lan Yu, Yu Wu, Feixiang Xiang, Solid splenic lymphangioma: Unveiling an atypical presentation in lymphatic system malformations, Journal of Clinical Ultrasound.2024; 52(7):964-966
3. Efared B, Atsame-Ebang G, Zabeirou A, Hammas N, Mazaz K, El Fatemi H, et al. Isolated splenic lymphangioma presenting as a huge mass causing anemia and abdominal distension in an adult patient: a case report. J Med Case Rep. 2018;12:97.
4. A. Perez, M. Perez, A.C. Yuga, B. Viray.Splenic lymphangioma in adulthood: a case report.Int. J. Surg. Case Rep.2020;65: 250-253
5. Golmohammadzadeh H, Maddah G, Shams Hojjati Y, Abdollahi A, Shabahang H. Splenic cysts: analysis of 16 cases. Caspian J Intern Med. 2016;7:217–221
6. Palas J., Matos A., Ramalho M. The spleen revisited: an overview on magnetic resonance imaging. Radiol. Res. Practice. 2013;23(3):123-28
7. Al-Shaikh S., Mubarak, Harb Z. Case report: splenic lymphangioma in an adult. Saudi Med. J. 2017;38(11):1148–1152.
8. Murshid MY, AlHawsah AO, AlSayed KT, Ansari FA. Isolated splenic lymphangioma in adulthood. J Surg Case Rep. 2024 Jun 11;2024(6):rjae411.doi: 10.1093/jscr/rjae411.
9. Boughdir M, Nechi S, Bellila S, Maamatou W, Jarray L, Hellal Y, Sebai MA. The Mangement of Splenic Cysts in Children. J. Adv. Med. Med. Res. 2021;33(18):188-95.
10. S. Oubaha, S. Benidamou, R. Hafidi, et al.Cystic lymphangioma of the spleen: report of an exceptional caseJ. Afr. Hépatol. Gastroentérol.2013;7:8-9

11. Thipphavong S, Duigenan S, Schindera ST, Gee MS, Philips S. Nonneoplastic, benign, and malignant splenic diseases: cross-sectional imaging findings and rare disease entities. *AJR Am J Roentgenol* 2014; 203: 315-322.
12. Verghese BG, Kashinath SK, Ravi Kanth R. Lymphangioma of the spleen. A rare Tumor rarely seen in an Adult: A case report and a comprehensive Literature review. *Euroasian J Hepato-Gastroenterol* 2013; 3: 64-69
13. Shi R, Yang P, Guo Y, Tang Y, Luo H, Qin C, Jiang T, Huang Y, Gao Z, Zeng X, Wang J. Laparoscopic anatomical partial splenectomy for extremely rare isolated splenic lymphangioma in an adult: a case report and literature review. *Front Oncol*. 2024; 4: 1460566. doi: 10.3389/fonc.2024.1460566.
14. Thorat S, Shaji FM. Splenic lymphangioma masquerading as splenic abscess managed by laparoscopic splenectomy: A case report. *World J Clin Oncol*. 2023;14(10):440-444
15. T. Ousmane, F.P. Mamadou, S.I. Sitor, N. Abdou, D. Madieng. Splenic lymphangioma, *International J. Surg. Case Rep.* 2019;62: 40-42

UNDER PEER REVIEW