

**WITHDRAWAL EFFECTS ON ANTIOXIDATIVE AND NEUROHISTOCHEMICAL DEFICITS
IN ACETAMINOPHEN INDUCED TOXICITY IN CEREBELLAR CORTEX OF ADULT
WISTAR RATS**

ABSTRACT

INTRODUCTION: Neurotoxicity refers to the harmful effects of chemical, biological, or physical agents on the nervous system. Acetaminophen, a common pain reliever whose abuse has been linked to neurotoxicity at high doses, causing oxidative stress and neuronal damage.

AIM: The present study aimed to assess the withdrawal effects of Acetaminophen use on the Cerebellar cortex of adult wistar rats.

METHODOLOGY: Thirty (30) Adult wistar rats weighing 200 ± 50 g were assigned into three groups ($n=10$) of Control (C), Treatment 1 (T1) and Treatment 2 (T2). The control group C received distilled water, while Treatment groups T1 and T2 received 200mg/kg of acetaminophen for 4 weeks. However, treatment group T2 were allowed a 2-week acetaminophen withdrawal period. At the end of exposure, all animals were sacrificed via cervical dislocation and eventual removal of cerebellar specimens which were processed for some Neurohistochemical staining reactions as well as Biochemical Quantifications of LDH enzyme and Antioxidative stress markers (SOD & CAT). Quantitative analyses of all data obtained including Body weight, brain weight and Cerebellum weight were analysed using GraphPad® (version 8) and plotted using ANOVA followed by Tukey's multiple comparisons test. Significance was set at $p<0.05^*$ (95% confidence interval).

RESULT: Results showed a significant increase in body weight ($P=.05$) and a decrease in cerebellum weight ($P =.01$) in both acetaminophen groups. SOD and CAT activity decreased significantly ($P =.01$) in the T1 groups while T2 groups shows a significant increase, LDH activities decreased significantly ($P =.01$) in both groups. The Neurohistochemical findings showed severe degeneration, loss of the Purkinje neurons and poorly differentiated DNA on the

T1 group compared to control group C while the withdrawal group showed onset of regenerative changes in neurons improved differentiation in DNA stained.

CONCLUSION: The study's findings suggest that long-term acetaminophen use can lead to neurotoxic effects on the cerebellum, but partial recovery is possible upon withdrawal.

KEYWORDS: Neurotoxicity, Acetaminophen, cerebellum, Purkinje Neurons.

1.0 INTRODUCTION

“Neurotoxicity pertains to the direct or indirect influence of substances that disrupt the nervous systems of both humans and animals. There are numerous chemicals capable of inducing neurotoxic diseases in humans, and many more are employed as research tools to investigate the molecular and cellular mechanisms affecting the physiology and pathophysiology of the nervous system in live animal tissues, in vitro, and in human neural progenitor cell lines” [1]. “Various neurotoxic substances disrupt neural function, while others alter the normal developmental course of the brain or inflict damage on the mature nervous system. These disturbances can manifest rapidly and then resolve, progress gradually over days or weeks before regressing over months or years, or result in lasting impairments” [2]. “Typically, neurotoxicity is self-limiting once exposure ceases and seldom advances without continued exposure. However, there might be a significant time gap between exposure and the appearance of neurotoxic effects”. [1].

“The nervous system, consisting of the central nervous system (CNS) encompassing the brain and spinal cord, along with the peripheral nervous system (PNS), functions as the body's communication network, controlling sensory perception, motor functions, and cognitive processes” [3].

Any disruption in the CNS operation can trigger a range of neurological symptoms and disorders. Neurotoxicity can be caused by exposure to various substances, including industrial chemicals,

heavy metals like lead and mercury, pesticides, drugs such as methamphetamine and certain pharmaceuticals, as well as naturally occurring toxins produced by some microorganisms [1]

Understanding the mechanisms that underlie neurotoxicity is crucial for grasping its effects on the nervous system. These mechanisms can involve oxidative stress, inflammation, disruption of neurotransmitter systems, compromise of the blood-brain barrier, and neuronal cell death. Certain neurotoxic agents, like heavy metals, can accumulate in the brain over time, leading to chronic neurotoxicity, which may contribute to the development or worsening of neurological diseases such as Alzheimer's, Parkinson's, and ALS [4,44,45].

Paracetamol, also known as Acetaminophen (APAP), is a commonly used antipyretic and analgesic with a mechanism of action distinct from nonsteroidal anti-inflammatory drugs (NSAIDs). While its exact mode of action is not fully understood, it appears to selectively inhibit cyclooxygenase (COX) in the brain. This selective action allows it to effectively reduce fever and alleviate pain. Additionally, it may inhibit the synthesis of prostaglandins in the central nervous system (CNS). Acetaminophen has a direct impact on the hypothalamus, leading to its antipyretic effects [5].

“In the brain, APAP is first deacetylated and then conjugated with arachidonic acid to form N-arachidonoyl-phenolamine (AM404) by the enzyme fatty acid amide hydrolase (FAAH) [6]. AM404 is a potent agonist of the vanilloid subtype 1 receptors (TRPV1) and it can also increase the levels of endogenous cannabinoids by inhibition of the anandamide membrane transporter (AMT). These are pathways responsible for inhibiting nociception and lowering body temperature” [7]. “Also, the activation of the endocannabinoid system regulates other important processes, such as movement control, learning and memory as well as emotional behaviour” [8]. Acetaminophen toxicity may be attributable to its common availability and the general perception of being extremely safe. Among the key mechanistic events associated with APAP toxicity,

increase in oxidative stress via generation of reactive oxygen species (ROS), glutathione disulfide (GSSG) formation, and nitric oxide (NO) derivatives generation are seen in association with toxic APAP exposure [9]. Alterations in brain function in individuals with APAP overdose are usually considered to be secondary adverse events of ALF. However, APAP can cross the blood brain barrier (BBB) and can be distributed homogeneously in the CNS [10]. Additionally, research has it that the administration of toxic doses of APAP decreases brain GSH content, produces an increase in ROS and thiobarbituric acid reactive species (TBARS) formation, and induces mitochondrial dysfunction [11]. It has also been demonstrated that a toxic APAP treatment of mice results in nuclear translocation of the oxidative stress sensor, Factor erythroid 2-related factor 2 (Nrf2), in the brain [5].

However, it has been stated that the direct effects of APAP intoxication on the structure and function of different areas of the brain when ALF is not present are poorly understood. It is not clear whether APAP intoxication can alter animal behaviour through in situ effects in different areas of the brain. While Acetaminophen is considered safe and effective when used within the recommended dosage, there have been concerns regarding its potential neurotoxicity, particularly with prolonged or excessive use. Research studies have suggested that high doses of Acetaminophen can lead to adverse effects on the CNS, including the cerebellum [12].

Accidental and intentional Acetaminophen poisoning has become a serious public health concern [13]. More than 100,000 calls made to the United States Poison Control Centers, 2600 hospital admissions, 56,000 visits to the emergency departments, and about 500 deaths were attributable to yearly use of Acetaminophen [14, 15].

The cerebellum is a vital brain region responsible for motor control, coordination, balance, and cognitive functions [16]. The cerebellar cortex is a sheet-like structure, made of a single sheet less than 1mm thick, and accordion-like folds fused at the midline [17]. Each fold is composed of an

inner white matter core that is covered by gray matter. The gray matter of the cortex divides into three layers: an external - the molecular layer; a middle - the Purkinje cell layer; and an internal - the granular layer. The molecular layer contains two types of neurons: the outer stellate cell and the inner basket cell [18, 19]. The Purkinje layer consists of Purkinje cells, which are large Golgi type I neurons. Their dendrites reach the molecular layer and have multiple branches. The axons are long, pass through the granular layer, enter the white matter, acquire a myelin sheath, and terminate in the intracerebellar nuclei. Their collateral branches make synaptic contacts with the basket and stellate cells of the granular layer. Climbing and mossy fibers provide the primary input to the cerebellar cortex. Mossy fibers use glutamate, while the climbing fibers use aspartate as their main excitatory neurotransmitter to provide excitatory signals to the Purkinje cells[20]. The climbing fibers are named so because they travel in the cortex like vine branches on a tree. They represent the terminal ending of the olivocerebellar tracts. The mossy fibers are the terminal branches of all other cerebellar afferent tracts. Each mossy fiber may stimulate thousands of Purkinje cells via multiple branching [20].

Recent study by [21] has shown that the cerebellum contains a significant number of neuronal cells and synapses compared with any other structure within the central nervous system. The functions of these wide arrays of neurons are determined by a set of biological stimuli (i.e. excitatory or inhibitory inputs). [21].

According to [22], excitatory inputs are generated by many mossy fibers which developed from the pontine nuclei and climbing fibers originating from the inferior olivary nucleus. On the other hand, large inhibitory inputs arise from the Purkinje cells situated in the cerebellar cortex. Observations made from the neurobiology of the cerebellum showed that there is need for integration between excitatory and inhibitory inputs so as to develop the output signal required for the functional integrity of the cerebellum [23]. The inhibitory input from a single cerebellar

nucleus is usually opposed by depolarizing potentials in the recipient cerebellar nuclei cells due to spontaneous depolarization activity in the presence of such an inhibitory input. The cerebellum contains the most elaborately patterned circuit of all the central nervous system structures, which may be essential for organising the large number of functional and topographic zonal circuits [24]

2.0 MATERIALS AND METHOD.

2.1 Experimental/Acclimation of Animals.

Thirty 30 healthy adult wistar rats (weighing 200 ± 50 g) were obtained from and afterwards housed in the animal holdings of Anatomy Department of Olabisi Onabanjo University under an optimal environmental conditions of humidity, temperature and light/dark cycle. They were fed freely food pellets and given distilled water only to drink.

2.2 Experimental Design and Grouping.

All the animals were randomly divided into three (3) groups' n=10 and exposed by oral administration as follows for 4 weeks:

Control group (C) Received distilled water, **Treatment groups (T1 and T2)** Received 100mg/kg Body weight of acetaminophen (Emzor Phamaceutical industrial Limited, Nigeria), however T2 were allowed an acetaminophen withdrawal period of 2 weeks.

2.3 Animal Sacrifice and Organ Collection.

At the end the exposure durations, all the animals were sacrificed via cervical dislocation and the brain specimens were carefully dissected out of the skull while the Cerebellar parts were carefully removed from the Brain specimen for histochemical and biochemical analysis

2.4 HISTOCHEMICAL ANALYSIS.

The cerebellar specimens obtained, were routinely processed for H&E stain [38], Cresyl violet stain, [39], Luxol fast blue, [16], Bielschowsky[38] and Feulgen stain[40]

2.5 BIOCHEMICAL ANALYSIS

The frozen cerebellar specimens obtained were homogenized and processed for biochemical quantifications of LDH, SOD and CAT as previously described by [41,42,43] respectively

2.6 PHOTOMICROGRAPHY

The slides of cerebellar sections obtained were examined and photographed using bright field compound Nikon microscope, YS100 (attached with Nikon camera),

2.8 STATISTICAL ANALYSIS

GraphPad Prism software (version 9.0, GraphPad Software, Inc.) was used for data analysis. All data are reported as mean values with standard deviation (mean \pm SD). One-way analysis of variance (ANOVA) followed by Tukey post hoc test was employed for multiple comparisons between groups. Significant difference was set at P = 0.05

3.0 RESULTS

3.1 Effect of Acetaminophen on Body Weight Change of Wistar rats

Assessment of the mean body weight (fig 1) of rats across groups following treatment with acetaminophen shows a significant increase in body weight change ($P = .05$) in rats administered acetaminophen group and withdrawal group when compared to the control group

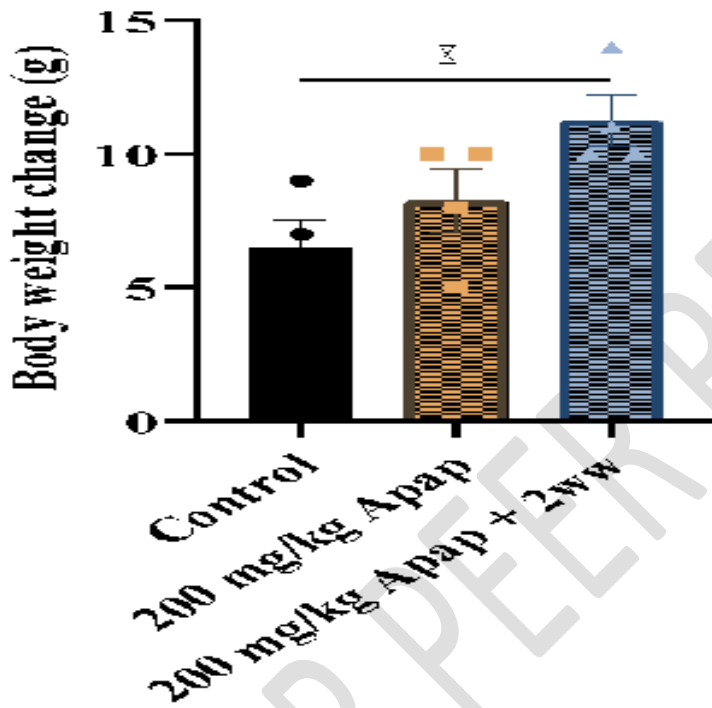


Fig 1: Body weight change in Wistar rats exposed to Acetaminophen (Apap). Data expressed as mean \pm SEM. One-way ANOVA followed by Tukey post hoc test. $*(P = .05)$. 2ww – two weeks withdrawal.

3.2 Effect of Acetaminophen on Brain Weight of Wistar Rats

The effect of the administration of acetaminophen on the brain weight is presented (fig 2). In this study acetaminophen administration for 4 weeks shows a significant decrease in the brain weight ($P = .01$). and withdrawal group result also revealed a significant decrease ($P = .01$). in brain weight of the wistar rats.

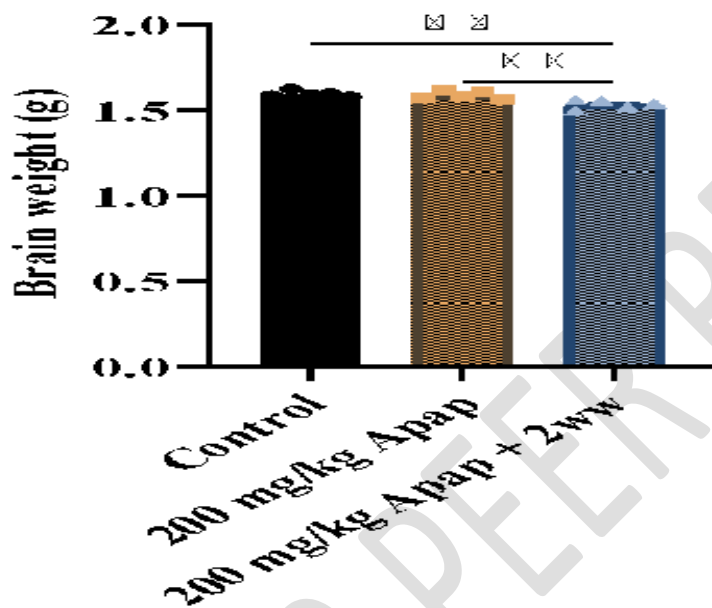


Fig 2: Mean Brain Weight in Wistar rats exposed to Acetaminophen (Apap). Data expressed as mean \pm SEM. One-way ANOVA followed by Tukey post hoc test. (** $p < 0.01$).

3.3 EFFECT OF ACETAMINOPHEN ON CEREBELLUM WEIGHT OF WISTAR RATS

The effect of acetaminophen administration on the cerebellum weight is shown in (fig 3). Result obtained shows that there was a significant decrease ($P = .01$) in cerebellum weight of chronic administration and withdrawal group

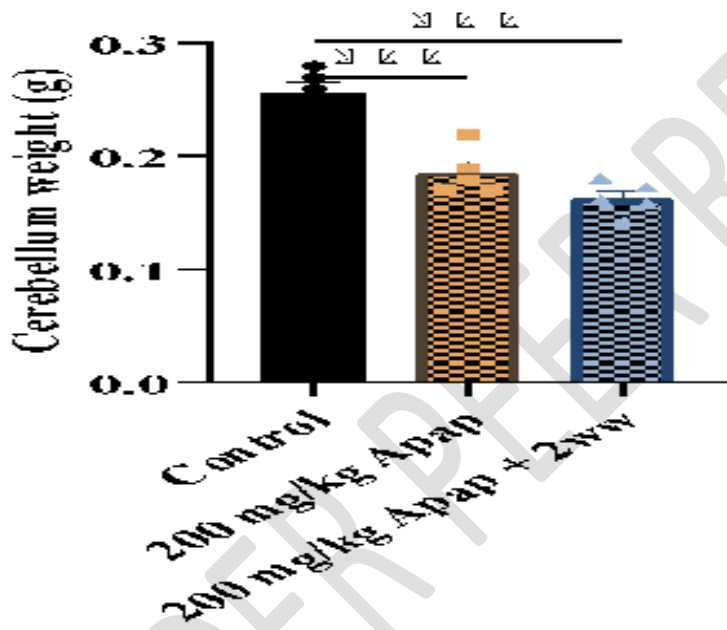


Fig 3: Mean Cerebellum Weight in Wistar rats exposed to Acetaminophen (Apap). Data expressed as mean \pm SEM. One-way ANOVA followed by Tukey post hoc test. ***($P = .01$).

3.4 EFFECT OF ACETAMINOPHEN ON SUPEROXIDE DISMUTASE (SOD) ACTIVITY IN WISTAR RATS

Superoxide Dismutase (SOD) activity of wistar rats administered chronic acetaminophen shows a significantly reduced ($P = .01$) value when compared to the control while the recovery group shows a significant increased ($P = .01$) when compare to the chronic administration group

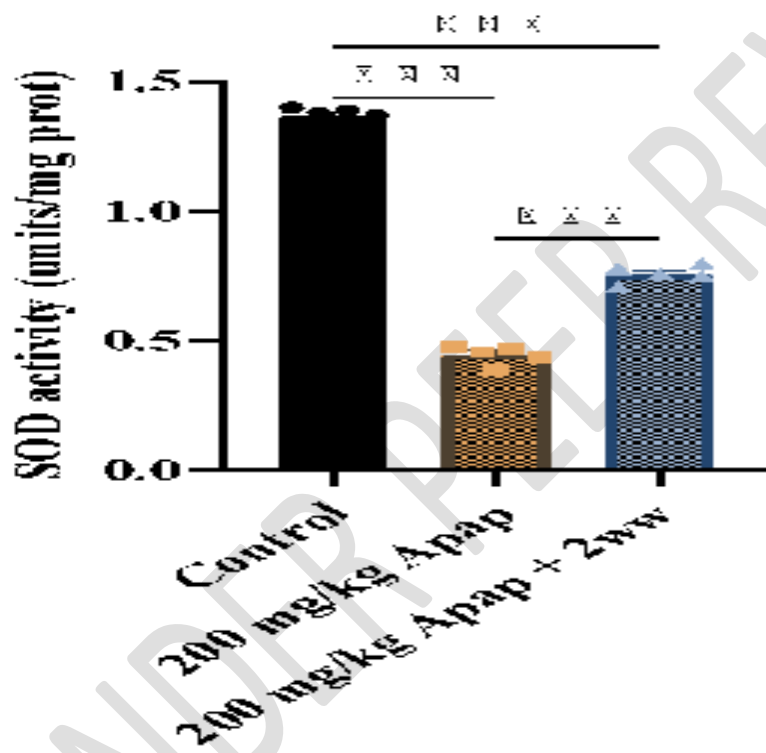


Fig 4: Mean Superoxide Dismutase (SOD) Activity in Wistar rats exposed to Acetaminophen (Apap). Data expressed as mean \pm SEM. One-way ANOVA followed by Tukey post hoc test.

***($P = .01$).

3.5 EFFECT OF ACETAMINOPHEN ON CATALASE ACTIVITY IN WISTAR RATS

Catalase (CAT) activity of wistar rats administered chronic acetaminophen shows a significantly reduced ($P = .01$) value when compared to the control group while the recovery group shows a significantly increased ($P = .01$) when compare to the chronic administration group

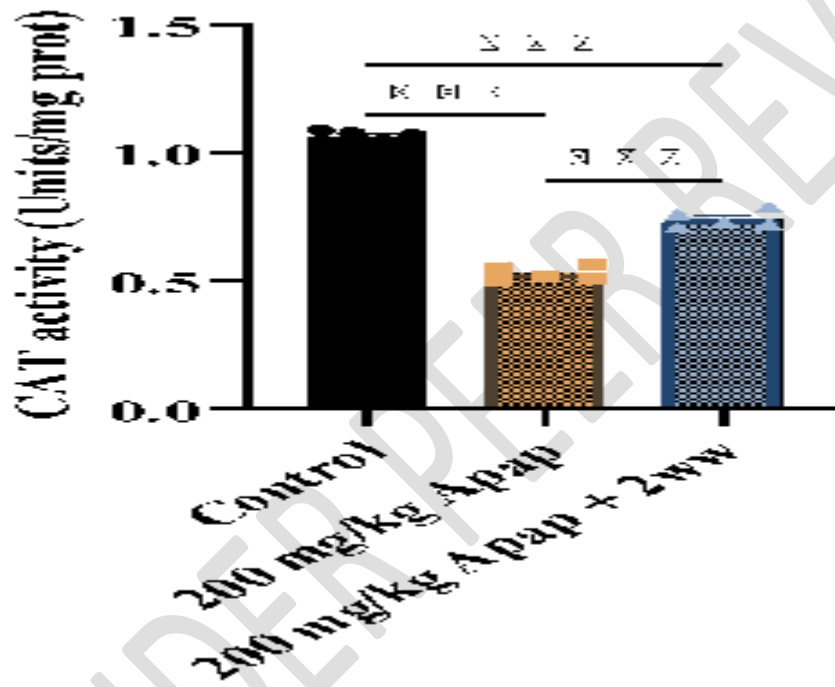


Fig 5 Mean Catalase (CAT) Activity in Wistar rats exposed to Acetaminophen (Apap). Data expressed as mean \pm SEM. One-way ANOVA followed by Tukey post hoc test. ***($P = .01$)

3.6 EFFECT OF ACETAMINOPHEN ON THE CONCENTRATION OF LACTATE DEHYDROGENASE (LDH) IN WISTAR RATS

Lactate Dehydrogenase (LDH) activity of wistar rats administered chronic acetaminophen shows a significantly reduced ($P = .01$) value when compared to the control group while the recovery group shows a significantly decreased ($P = .01$) value when compare to the chronic administration group




Fig 6: Mean Lactate Dehydrogenase Concentration in Wistar rats exposed to Acetaminophen (Apap). Data expressed as mean \pm SEM. One-way ANOVA followed by Tukey post hoc test. *** ($P = .01$) .

3.7 HISTOLOGICAL EFFECT OF ACETAMINOPHEN ON THE CEREBELLUM OF WISTAR RATS

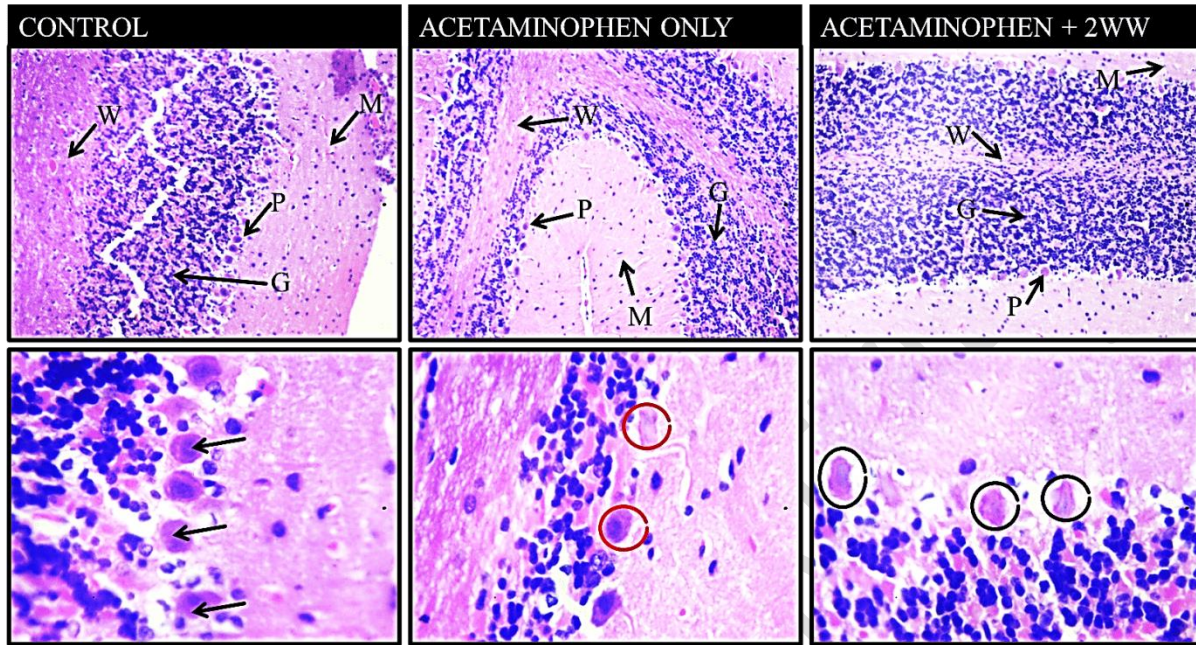


PLATE 1: Photomicrograph of the cerebellum tissue shows CONTROL group having a well-defined and organized Molecular layer (M), Granular layer (G) and the pyramidal neurons (black thin arrow) on the Purkinje layer. ACETAMINOPHEN (T1) group shows loss and irregular pyramidal neurons (red circle), Granular layer (G) and Molecular layer (M) with loss of glia cells. The WITHDRAWAL (T2) group shows regenerated pyramidal neurons (black circle), molecular layer (M) and granular layer (G). STAIN H&E Magnification. 100 and 400

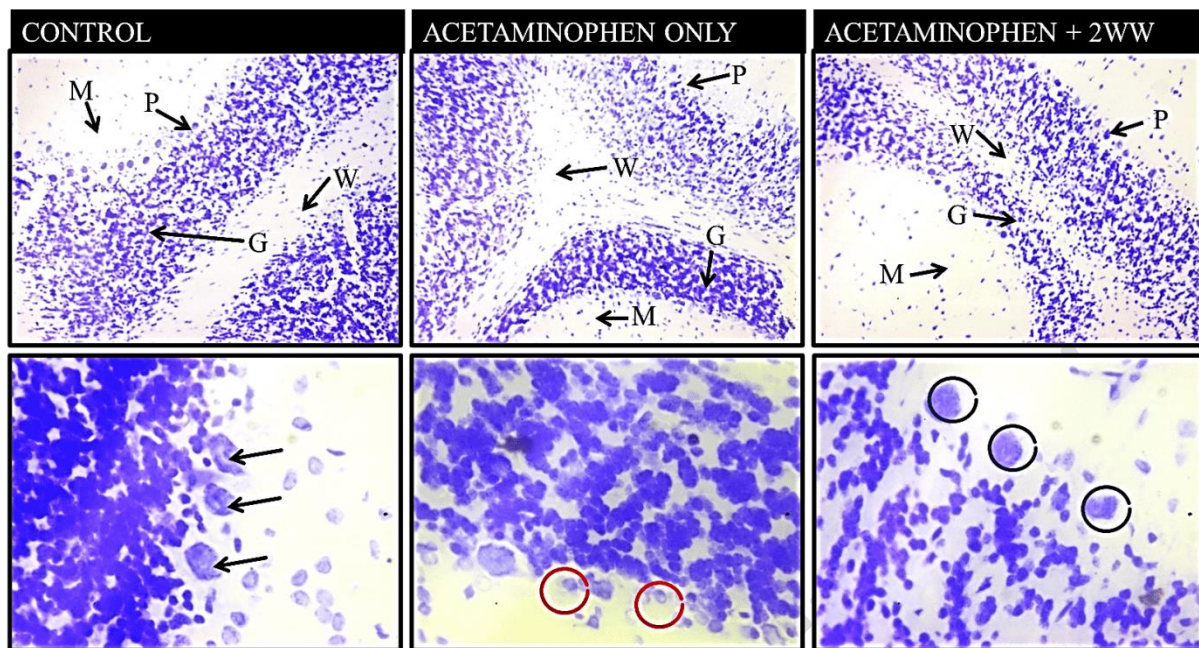


PLATE 2: Photomicrograph of the cerebellum tissue shows CONTROL group having a well-defined and organized Molecular layer (M), Granular layer (G) and the pyramidal neurons (black thin arrow) on the Purkinje layer. ACETAMINOPHEN (T1) group shows loss and atrophic pyramidal neurons (red circle), Granular layer (G) and Molecular layer (M) with loss of glia cells. The WITHDRAWAL (T2) group shows regenerated pyramidal neurons (black circle), well differentiated molecular layer (M) and granular layer (G). STAIN: CRESYL VIOLET Magnification. 100 and 400

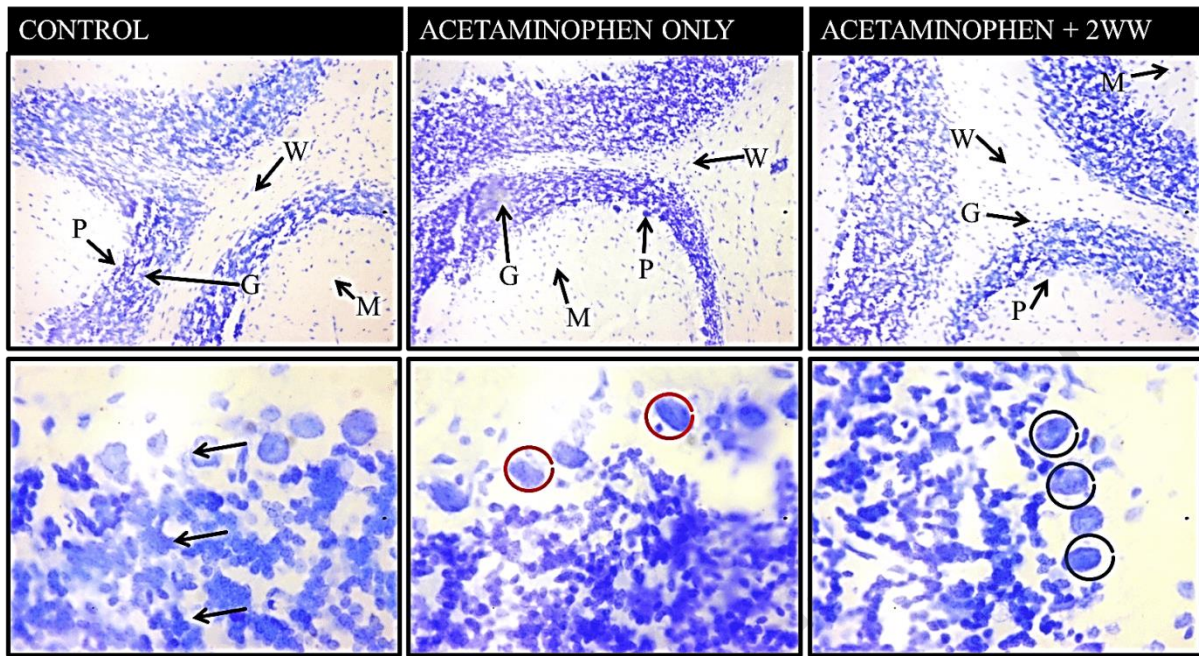


PLATE 3: Photomicrograph of the cerebellum tissue shows CONTROL group having a well differentiated and organized Molecular layer (M), Granular layer (G) and the pyramidal neurons (P) (black thin arrow) on the Purkinje layer. ACETAMINOPHEN (T1) group shows pyknotic and atrophic pyramidal neurons (red circle), Granular layer (G) and Molecular layer (M) with loss of glia cells. The WITHDRAWAL (T2) group shows regenerated pyramidal neurons (black circle), well differentiated molecular layer (M) and granular layer (G). STAIN: LUXOL FAST BLUE Magnification. 100 and 400

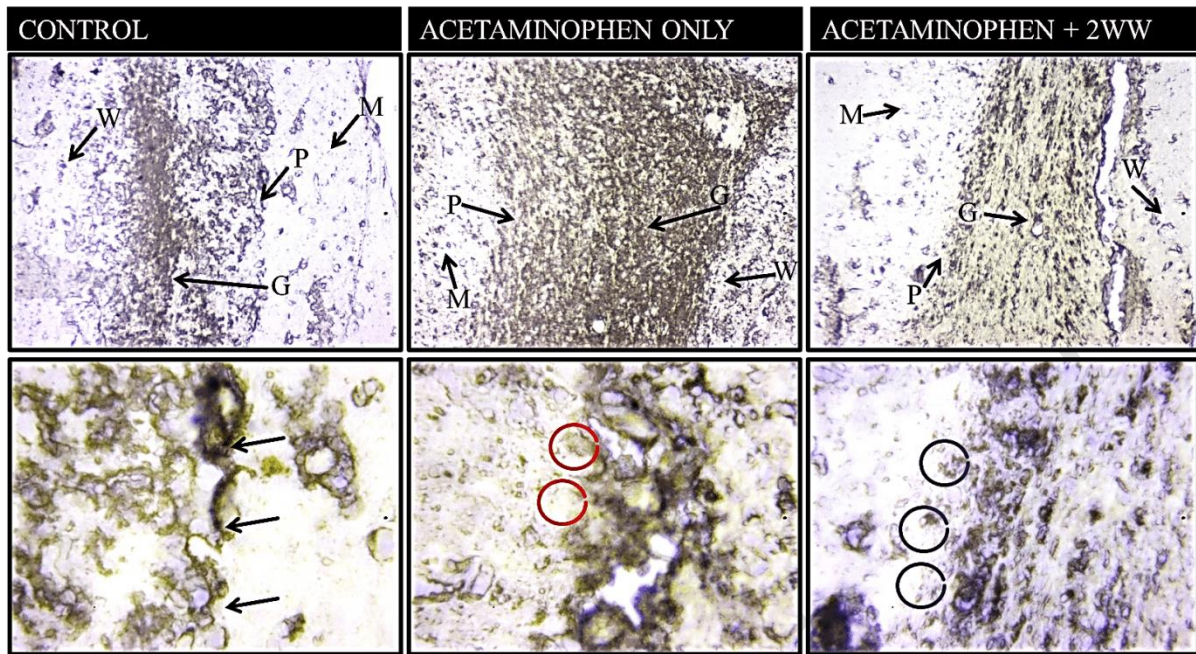


PLATE 4: Photomicrograph of the cerebellum tissue shows CONTROL group shows adequate and well distributed Neuro-fibers and having a well differentiated and organized cerebellum layers. ACETAMINOPHEN (T1) group shows thickened, irregular and overexpression of the Neuro-fibers distributions. The WITHDRAWAL (T2) group shows normal and even distributions and expression of the neuro-fibers. .STAIN: BIELCHOWSKY STAIN. Magnification. 100 and 400

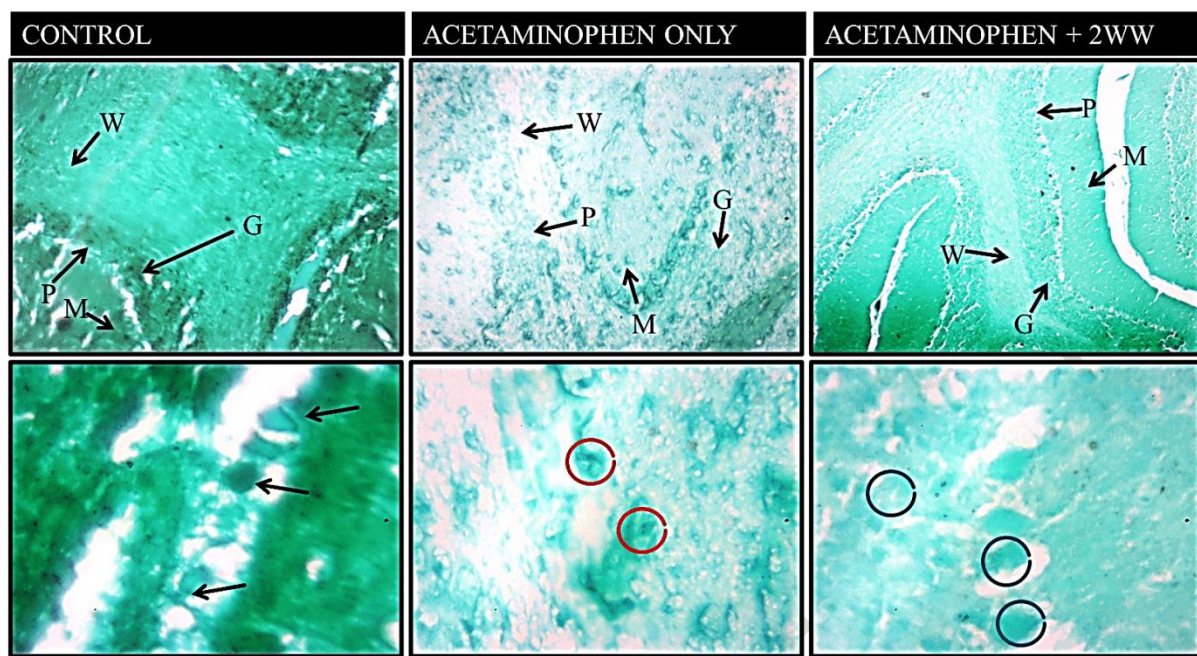


PLATE 5: Histochemical demonstration of DNA distribution across the layers of the cerebellar cortex in rats (MAG x100 and x400). The molecular cell layer (M), Purkinje cell layer (P), and granule cell layer (G) are demonstrated across study groups. The photomicrograph show the neurons of the control group stained well differentiated stained DNA (black arrow), Acetaminophen treated group shows distortion of DNA (dotted red circles) when compared to the control group, withdrawal group shows improvement in well differentiated staining of DNA in neurons(dotted black ring) compared to treated group, markings of improving regeneration of neuronal DNA contents.. FEULGEN STAIN x100 and 400 magnification

4.0 DISCUSSION

The cerebellum, a critical part of the brain, is primarily involved in motor control, balance, and coordination. Its significance extends to cognitive functions such as attention and language, as well as emotional regulation [26]. This project focuses on evaluating the neurotoxic effects of acetaminophen on the cerebellum of adult Wistar rats, examining histo-morphological and histochemical changes induced by this widely used analgesic. Understanding the impact of acetaminophen on cerebellar structure and function is vital, as chronic use or over dosage can lead to significant neurological impairments, a concern supported by studies on various neurotoxic agents [27].

Neurotoxicity refers to the capacity of chemical, biological, or physical agents to induce adverse effects on the structure or function of the central and peripheral nervous systems. Neurotoxic effects can result from direct damage to neural cells or interference with metabolic processes essential for neural function. Acetaminophen, while commonly used for pain relief, has been associated with neurotoxic effects at high doses, leading to oxidative stress and subsequent neuronal damage [28]. This project investigates these neurotoxic effects, focusing on histo-morphological changes in the cerebellum of wistar rats.

This study demonstrated a significant increase in body weight change in rats administered acetaminophen. This suggests that the metabolic disruptions induced by acetaminophen are potentially reversible. The observed weight gain in the recovery group aligns with findings by (29), indicating that metabolic normalization occurs after the cessation of acetaminophen. The role of dietary patterns in this process is critical, as [30] highlighted the impact of feeding habits on body weight. This recovery period is crucial for understanding how acetaminophen affects long-term metabolic processes and underscores the need for careful monitoring during therapy.

This study found a significant decrease in brain weight in rats treated with acetaminophen for 28 days and allowed to recover for two weeks compared to the control and acetaminophen-only groups. This indicates that chronic acetaminophen use can lead to significant brain atrophy, a finding supported by [28 and 26], who noted the critical role of the cerebellum in cognitive functions and motor control. The partial recovery observed suggests that some of the neurotoxic effects are reversible, which is promising for therapeutic interventions aimed at mitigating acetaminophen's long-term impact on brain health.

A significant decrease in cerebellum weight was observed in both the acetaminophen-only and the recovery groups compared to the control. This suggests that the cerebellum is particularly vulnerable to acetaminophen-induced damage. Findings from [31 and 27]) support this observation, as they documented cerebellar atrophy in various neurodegenerative conditions. Despite the recovery period, the persistent reduction in cerebellum weight highlights the need for cautious acetaminophen use, especially in conditions where cerebellar integrity is essential.

Superoxide dismutase (SOD) activity was significantly reduced in both acetaminophen-treated groups compared to the control. However, the recovery group showed a significant increase in SOD activity compared to the acetaminophen-only group, suggesting some reversibility of oxidative stress. Studies by [33 and 34] documented similar findings in neurodegenerative conditions, indicating reduced antioxidant enzyme activity. The recovery of SOD activity post-withdrawal underscores the potential for therapeutic strategies aimed at enhancing antioxidant defences to mitigate neurotoxic effects.

Catalase activity significantly decreased in both acetaminophen-treated groups compared to the control, but the recovery group showed a significant increase in catalase activity compared to the acetaminophen-only group. This decrease in catalase activity aligns with findings by [35], who reported impaired antioxidant enzyme activity in response to neurotoxic agents. The observed recovery supports the potential for antioxidant interventions to restore enzyme activity, highlighting the importance of developing treatments to counteract the oxidative damage caused by acetaminophen.

There was a significant decrease in LDH concentration in both acetaminophen-treated groups compared to the control, with the recovery group showing a further significant decrease compared to the acetaminophen-only group. This suggests ongoing cellular repair, consistent with findings by [36] and [29]. The significant reduction in LDH concentration highlights the metabolic disturbances caused by acetaminophen, indicating the need for extended monitoring and supportive care following acetaminophen toxicity.

Hematoxylin and Eosin (H&E) staining revealed significant differences between the control and acetaminophen-treated groups. In control rats, the cerebellar cortex showed a well-defined architecture with clearly visible layers, including the molecular layer (M), Purkinje cell layer (P), granule cell layer (G), and medullary layer of white matter (W). Purkinje cells, essential for motor control, exhibited conspicuous cell bodies and dendrites extending deep into the molecular layer.

In contrast, acetaminophen-treated rats displayed notable degeneration in these structures. The Purkinje cells showed pyknotic cell bodies and shortened dendritic processes, indicating cell death and reduced connectivity. The granule cell layer was loosely arranged, reflecting significant neurotoxicity.

Cresyl Fast Violet (CFV) staining focused on the Nissl substance and granule integrity. In the control group, granule neurons were densely packed, and the Nissl substance was heavily stained, indicating robust protein synthesis and neuronal metabolism. However, in the acetaminophen-treated group, the granule cells were loosely arranged, and the Nissl substance showed lighter pigmentation. This suggests impaired neuronal function and structural integrity due to acetaminophen exposure. These findings are consistent with studies by [37] which reported similar disruptions in neural transmission and protein synthesis in acetaminophen-treated models.

Luxol Fast Blue (LFB) staining assessed myelinated nerve fibers in the cerebellar cortex. Control rats exhibited well-differentiated myelinated fibers, essential for efficient neuronal communication. In contrast, acetaminophen-treated rats showed areas of degenerating myelinated fibers, reflecting demyelination and disrupted neural transmission. Interestingly, the withdrawal group exhibited signs of regeneration, suggesting that the neurotoxic effects of acetaminophen may be partially reversible upon cessation of treatment.

Bielschowsky silver staining revealed differences in neuronal and neurofibril morphology across the groups. Control rats showed well-differentiated neurons without pathological plaques, indicating healthy neurofibril structure. Acetaminophen-treated rats, however, exhibited areas of degenerating neurons, though without visible neurofibrillary tangles. This degeneration highlights the neurotoxic impact of acetaminophen, as supported by similar findings in neurotoxicity studies. The withdrawal group displayed improved neuronal differentiation, suggesting potential recovery of neuronal structure and function after discontinuing acetaminophen.

The histochemical analysis of DNA distribution revealed significant alterations in the cerebellar cortex. Control neurons showed well-differentiated DNA staining, indicating intact genetic material and cellular health. In contrast, acetaminophen-treated neurons exhibited distorted DNA, reflecting genetic damage and compromised cellular function. This genotoxic effect is consistent with the known mechanisms of acetaminophen-induced oxidative stress and mitochondrial dysfunction, leading to cell death. Interestingly, the withdrawal group demonstrated improved DNA staining, indicating partial regeneration of neuronal DNA content.

5. Conclusion

In this study, acetaminophen exhibited significant neurotoxic effects, as evidenced by changes in body weight, brain weight, cerebellum weight, antioxidant enzyme activity, LDH concentration, and hematological parameters in Wistar rats. The observed partial recovery upon withdrawal highlights the potential for reversibility of some toxic effects, suggesting avenues for therapeutic intervention.

Ethical Approval

Ethical considerations were ensured in consonance with the guiding rules and regulations for the use and care of animals, approval was obtained from the Ethical committee of Research of the Anatomy Department, Faculty of Basic Medical Sciences (FBMS) of Olabisi Onabanjo University Ogun State.

Disclaimer (Artificial intelligence)

Option 1:

Author(s) hereby declare that NO generative AI technologies such as Large Language Models (ChatGPT, COPILOT, etc.) and text-to-image generators have been used during the writing or editing of this manuscript.

Option 2:

Author(s) hereby declare that generative AI technologies such as Large Language Models, etc. have been used during the writing or editing of manuscripts. This explanation will include the name, version, model, and source of the generative AI technology and as well as all input prompts provided to the generative AI technology

Details of the AI usage are given below:

- 1.
- 2.
- 3.

REFERENCES

1. Spencer P.S. and Lein P.J. Encyclopedia of Toxicology (Fourth Edition). 2024; 6:727-740
2. Soleimani, S. M. A and Cadet, J. L. Drug induced Neurotoxicity. *Progress in Brain Research*. 2016;223:19-42.
3. Ayub, M., & Mallamaci, A. An Introduction: Overview of Nervous System and Brain Disorders. *The Role of Natural Antioxidants in Brain Disorders*. 2023;1-24.
https://doi.org/10.1007/978-3-031-41188-5_1.
4. Nath, B. D., Debnath, D., Pervin, R., & Hossain, M. A. Role of Environmental Toxicants and Inflammation in Parkinson's Disease. *Antioxidants and Functional Foods for Neurodegenerative Disorders*. 2021;37-69. [CRC Press].
5. Ghanem, C.I., Perez, M.J., Manautou, J.E., & Mottino, A.D. Acetaminophen from liver to brain: *New insights into drug pharmacological action. Biochimica Biophysica Acta(BBA)-General Subjects*. 2016;1860(5), 1094-1103
6. Högestätt E.D., Jönsson B.A., Ermund A., Andersson D.A., Björk H., Alexander J.P., Cravatt B.F., Basbaum A.I., Zygmunt P.M. Conversion of acetaminophen to the bioactive N-acylphenolamine AM404 via fatty acid amide hydrolase-dependent arachidonic acid conjugation in the nervous system. *J. Biol. Chem.* 2005;280:31405–31412. doi: 10.1074/jbc.M501489200.
7. Battista, N., Gasperi, V., Fezza, F., & Maccarrone, M.. The anandamide membrane transporter and the therapeutic implications of its inhibition. *Clinical Practice*.2005;2(1), 141.
8. Moreira, F. A., & Lutz, B. The endocannabinoid system: emotion, learning and addiction. *Addiction biology*. 2008; 13(2), 196-212.
9. Ramachandran, A., & Jaeschke, H. Oxidant stress and acetaminophen hepatotoxicity: mechanism-based drug development. *Antioxidants & redox signalling*. 2021; 35(9), 718-733.

10. María Belén Vigo, María Julia Pérez, Fernanda De Fino, Gimena Gómez, Sonia A Martínez, Veronica Bisagno, María Beatriz Di Carlo, Alejandra Scazziota, José E Manautou, Carolina I Ghanem. Acute acetaminophen intoxication induces direct neurotoxicity in rats manifested as astrogliosis and decreased dopaminergic markers in brain areas associated with locomotor regulation. *Biochemical Pharmacology*. 2019; 170, 113662.
11. Ashafaq, M., Hussain, S., Alshahrani, S., Madkhali, O., Siddiqui, R., Khuwaja, G. and Islam, F. Role of cinnamon oil against acetaminophen overdose induced neurological aberrations through brain stress and cytokine upregulation in rat brain. *Drug and chemical toxicology*, 2022. 45(2), 633-640.
12. Buhner, D.K., Berg, K.A., & Freeman, K.S. Acetaminophen-induced neurotoxicity: A review of the literature *Journal of Clinical Neuroscience*, 2021; 83, 34-41
13. Daifallah, A.A., Alrabiah, F.A., Alghamdi, J.S., Alzahrani, S.H., and Alotaibi F.N. Acetaminophen poisoning: A review of the literature. *Journal of Pharmacy Practice*, 2021; 34(3), 538-546
14. Bronstein, A.C., Spyker, D.A., Cantilena, L.R., Green, J.L., Rumack, B.H., & Giffin, S.L Annual Report of the American Association of Poison Control Centres National Poison Data System(NPDS). *Clinical Toxicology*, 2007; 45(8), 815-917
15. Caparrotta, L., Bentz, D., & Amico, P. Acetaminophen-induced hepatotoxicity: *Journal of Clinical and Translational Research* 2018; 4(3), 147-153
16. Shaheen, M.A. The cerebellum's role in motor control, coordination, balance and cognition. *Journal of Neuroscience Research*, 2023; 101(2), 257-266
17. Essen D. C. Folding of the cerebellar cortex. The Cerebellum: from structure to function. In J. Voogd, M. Wiesendanger & J. Van der want (Eds), 2018;15-30
18. Van Essen, D.C., Smith, S.M., Barch, D.M, & Buckner, R.L The human connectome: A structural description of the human brain. *Neuro, J. Neuron* 2018; 97(3), 537-548
19. Hawks, J., Hunley, K., Lee, S.H., & Wolpoff, M. Population bottlenecks and Pleistocene human evolution. *Journal of Archaeological Science* 2019; 18: 109-112

20. Yang, F., Xu, X., Li, Q., & Zhang, Y. Neural representation of uncertainty in the human brain. *Neuroimage*, 2014; 87, 312-321
21. Tang, Y., Yang, L., & Wang, X. The effects of mindfulness meditation on gray matter volume and cortical thickness: A systematic review. *Neuroscience and Biobehavioural Reviews* 2016; 71: 462-471
22. Heshmat, S. The Impact of social media on mental health. *Journal of behavioural Addictions*, 2016; 5(2), 462-471
23. White, S.J., & Sillitoe R.V. Development of the cerebellum: From embryonic origins to clinical implications. *Clinical Perinatology* 2013; 40(2), 291-306
24. Reeber, S.L., Otis, T.S., & Sillitoe, R.V. Acquisition of skilled locomotor movements in the cerebellum. *Journal of neuroscience*. 2013; 33(19) 8493-8502
25. Essawy E Amina., Afrah F. Alkhuriji & Ahmed A. Soffar . Paracetamol Overdose Induces Physiological and Pathological Aberrations. *Journal of Applied Pharmaceutical Sciences*. 2017;7(09) PP. 185-190
26. Diedrichsen, J., & Bastian, A. J. Cerebellar function. *The Cerebellum: Disorders and Treatment*, 2014; 45-70.
27. Jellinger, K. A. Basic mechanisms of neurodegeneration: a critical update. *Journal of Cellular and Molecular Medicine*. 2010; 14(3): 457-487.
28. Houk, J. C., & Miller, L. E. Motor learning, feedback, and the cerebellum. *Cognitive Neuroscience*. 2001; 12(3):367-375.
29. Sachs, B. D. Neurobehavioral and metabolic effects of chronic acetaminophen administration in adult male rats. *Neurotoxicology and Teratology*. 2014; 45:74-83.
30. Drapeau, V., (2004). Eating and dietary patterns and their relation to body weight status: Insights from the Quebec Family Study. *Physiology & Behavior*. 2004; 91(2-3): 291-297.
31. Franco-Pons N, Torrente M, Colomina M.T and Vilella E. Oxidative stress in the cerebellum and in the hippocampus of mice with experimental autoimmune encephalomyelitis. *Neuroscience*. 2007; 146(3), 1505-1517

32. Heck, D. H., & Sultan, F. Cerebellar involvement in movement control and motor learning. *Progress in Brain Research*. 2002; 142:41-55.
33. Beal, M. F. (1995). Aging, energy, and oxidative stress in neurodegenerative diseases. *Annals of Neurology*. 1995; 38(3), 357-366.
34. Lenaz G, Baracca A, Fato. R, Genova M.L and Solaini G. Mitochondria oxidative stress: Role of ubiquinone in aging and neurodegenerative diseases. *Mitochondria*. 2002; 2(1-2):1-10
35. Melissa, L. M., & Riyi, S. Axonal degeneration: Mechanisms and pathologic changes in animals and humans. *Acta Neuropathologica*. 2013; 126(1):63-79.
36. Cadenas, E., & Davies, K. J. A. Mitochondrial free radical generation, oxidative stress, and aging. *Free Radical Biology and Medicine*. 2000; 29(3-4):222-230.
37. Dixit V, Bagan J, Kumar N & Dhakad U. Neuroprotective effects of centella asiatica on cognitive dysfunction and oxidative stress in intracerebroventricular streptozotocin induced experimental model of Alzheimers disease in rats. *Pharmaceutical Biology*. 2015; 53(5):798-804
38. Carson, Freida L., and Christa Hladik Cappellano. Carson, Freida L., and Christa Hladik Cappellano . Histotechnology: A Self-instructional Text 4th ed. *Chicago: ASCP Press*, 2015; 196-199.
39. Venero, JL, Vizuete, ML, Revuelta, M, Vargas, C, Cano, J and Machado,A. Up regulation of BDNF mRNA and trkB mRNA in the nigrostriatal system and in the lesion site following unilateral transection of the medial forebrain bundle. *Exp. Neurol*. 2000;161:38–48
40. Bancroft, John D., and Marilyn Gamble. Bancroft, John D., and Marilyn Gamble. Theory and Practice of Histological Techniques Theory and Practice of Histological Techniques. 6th ed. *Oxford: Churchill Livingstone Elsevier*.2008; 224-225
41. Fakunle P.B., Ajibade A.J.,Ajani., R.A., Adefule A.K. Neurohistochemical evaluation of some dehydrogenases activities in superior colliculus of adult wistar rats following chronic simultaneous administration of ethanol and acetaminophen. *International Journal of Biological and Pharmaceutical Research*; 2013; 4(3):186–193

42. Misra, H.P. and Fridovich, I. The Role of Superoxide Anion in the Autoxidation of Epinephrine and a Simple Assay for Superoxide Dismutase. *Journal of Biological Chemistry*, 1972; 247, 3170-3175.
43. Goth L, Meszaros I, Nkmeth H. Serum catalase enzyme activity in acute pancreatitis. *Clin Chem*. 1982; 28: 1999-2000.
44. Otong, Eduitem S., Sunday A. Musa, Barnabas Danborno, and Sohnep J. Sambo. 2021. "Mitigation of Lead Neurotoxicity by Aqueous Fruit Extract of *Adansonia Digitata* in Adult Wistar Rats". *Journal of Complementary and Alternative Medical Research* 16 (4):71-82. <https://doi.org/10.9734/jocamr/2021/v16i430299>.
45. Orabi, Sahar H., Sherif M. Shawky, Gemechu Wirtu, Doaa A. Mansour, Samy A. Abdelaziz, and Hesham S. Elsabbagh. 2019. "Ginkgo Biloba Mitigates Aluminum Induced Neurotoxicity in Rats". *International Journal of Biochemistry Research & Review* 24 (4):1-14. <https://doi.org/10.9734/IJBCRR/2018/45780>.