

## Case report

### RIGHT MULTIPLE VENTRO-LATERAL TRAUMATIC ABDOMINAL HERNIA IN A 1½ -YEAR-OLD BALAMI RAM: A CASE REPORT

#### ABSTRACT

Hernia is a word derived from Latin referring to “bud” or “offshoot.” Acquired hernia can be due to trauma, excessive abdominal distension, frequent over feeding, pregnancy or trauma.

The condition is reported to be common in dogs and pigs but less so in other domestic animals. A Balami ram, was presented with a chief complaint of a large bulge on the right side of the abdomen. The client revealed that, the condition was first noticed about 5 months prior to presentation as a small swelling. The ram was said to had been involved in a fight with its pen mate a bull. The patient was aseptically prepared for surgery, draped and longitudinal skin incision made on each identified bulge, the hernia contents were evaluated and returned into their normal anatomical positions. The peritoneal sheet was then closed and the hernia ring edges refreshed and subsequently apposed using chromic catgut size 2 suture material. An uneventful recovery was achieved. We recommend that, rams should not be housed together with bulls.

**KEYWORDS:** Abdominal hernia; herniorraphy; Ruminant; Surgical repair

#### INTRODUCTION

Hernia is a word derived from Latin referring to “bud” or “offshoot.” Hernia is defined as protrusion of an organ, organ part or tissue through the structural envelopment housing it. Unless incarcerated, reducible hernias are generally painless (Kalang *et al.*, 2021; Mcbee *et al.*, 2022). Umbilical as well as groin (inguinal and femoral) hernia usually occur as a congenital defect however hernia can also be acquired. Acquired hernia can be due to trauma, like horn thrush, kick or violent contact with any blunt object (Bodinga *et al.*, 2021; Kalang *et al.*, 2021; Mcbee *et al.*, 2022). Excessive abdominal distension due to frequent over feeding, pregnancy or, violent straining during parturition can also predispose to hernia. The condition had been reported to be common in dogs and pigs, but less so in other domestic animals (Bodinga *et al.*, 2021; Kalang *et al.*, 2021; Hyowon *et al.*, 2023). Additional cause of hernia is abscessation in the abdominal wall (Duhu *et al.*, 2022). Based on location, hernia ring occurring ventral to the skin folds of the stifle are regarded as ventral abdominal wall hernia, while above the stifle skin folds are defined as lateral abdominal wall hernia (Sharun *et al.*, 2021). Abdominal hernia sac generally contains fat, omentum or/ and the intestine. Diagnosis can be obtained from the history, clinical signs and physical examination. However, herniography, a procedure where a non-ionic contrast medium like Omnipaque 300 is infiltrated into the hernia sac, guided by fluoroscopy. This is to ensure that the contrast was in the herniated tissue but not into the intestine. A radiograph is then obtained, the animal is then rolled-over to improve the distribution of contrast media before second radiographic exposure. This will demonstrate a clear bulge as well as the hernia ring, furthermore, the use of

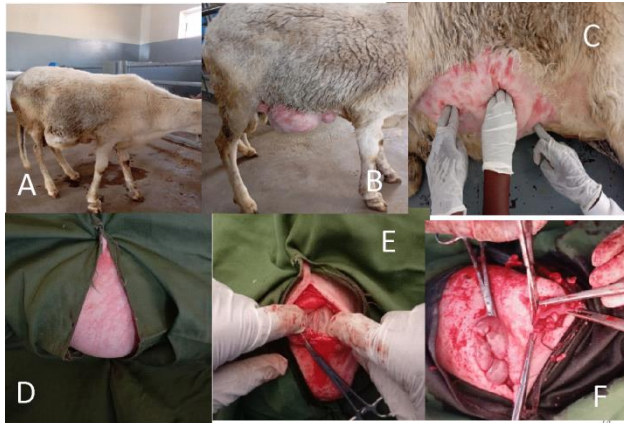
ultrasonography as well are both definitive (Heise *et al.*, 2002; Kalang *et al.*, 2021; Heemskerk *et al.*, 2022)

## **CASE REPORT**

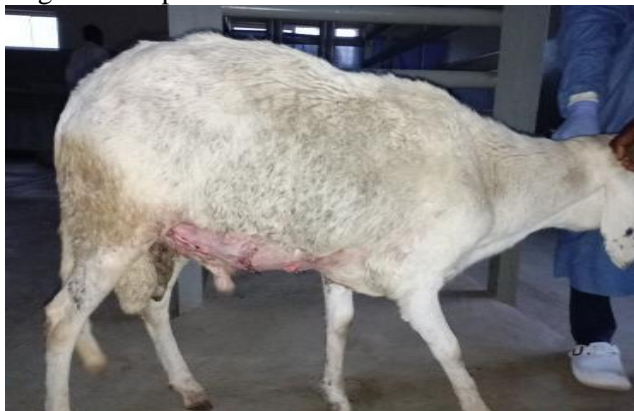A 1½-year-old Balami ram, from a flock of 15, weighing 44.4kg was presented to the Large Animal Clinic of the Veterinary Teaching Hospital, University of Jos, with a chief complaint of a large bulge on the right side of the abdomen. The client revealed that, the condition was first noticed about 5 months prior to presentation as a small swelling. The ram was involved in a fight with its pen mate (bull), after which small bulge were noticed in the ram. The bulge appears to be consistently progressive in size especially recently. The ram was evaluated clinically, the vital parameters were unaltered. Multiple protrusions on the right ventro-lateral abdominal wall region were felt as soft swellings. The ram was then placed on dorsal recumbency and the multiple number of bulges were reducible on maneuvering, with a ring palpated into the abdominal cavity through each swelling. The patient was then booked for surgical reduction of the multiple hernias.

## **SURGICAL MANAGEMENT**

The patient was prepared for surgery, the surgical site was prepared for asepsis. The ram was sedated using Inj. 20 mg Xylazine at 0.2 mg/kg, IV. Anaesthesia was achieved using Inj. 10mg Lidocaine at 2mg/kg, inverted “L” nerve block was achieved through local infiltration and the patient subsequently drapped. Longitudinal skin incision was made on each bulge, the hernia contents were evaluated and returned into their normal anatomical positions. The peritoneal sheet was then closed and the hernia ring edges refreshed and then apposed using chromic catgut size 2 suture material. Subcuticular suture pattern was then applied and the skin closed using horizontal mattress suture pattern. Post-operatively the animal was placed on Inj. 200mg. Amoxicillin 20mg/kg, IM, the injection was repeated every 48hr, for three consecutive administrations. Inj. 12.5mg. Diclofenac 1mg/kg, IM, and Inj. Vitamin C. 4mL, IV. Skin sutures were removed on day 14 post-surgery



**Fig. 1.** A- Showing the animal on presentation; B- Affected site been shaved; C- Hernia ring been identified; D-Triangular drapping; E-Exposed hernia ring after skin incision; F-Hernia rings been exposed



**Fig. 2.** A- The animal after surgical repair

## DISCUSSION

The obvious bulge on presentation and tenderness on palpation were similar to report by Fiordaliso *et al.* (2021) who noticed obvious hernia and tenderness of the mass on palpation. The hernia was observed to have been caused by blunt trauma about five months prior presentation, the presence of the hernia ring is specific for hernia as also reported by Sharun *et al.* (2021), who stated that, in confirming the diagnosis of a hernia, the especially the recognition of the hernial ring through palpation is the most critical part. Hence, from the case report its obvious that hernia due to blunt trauma is unlikely to be incarcerated within five months of occurrence except where complications are involved, Sato *et al.*, (2023) also report absence of any signs of incarceration in a calf three months after a bulge was noticed, he also reported, the absence of complications like abscess could be a factor. The occurrence of ventro-lateral abdominal hernia is relatively documented in literatures, however, multiple ventro-lateral abdominal hernia on same site of the animal is relatively rare. Mcbee *et al.* (2022) report repair as the definitive treatment for hernia and also, the use of mesh to relieve tension in hernia repair. Hernioplasty an alternative surgical repair was not employed because on reduction of the multiple rings it was observed that tension wasn't required. The

preference for longitudinal incision was aimed at reducing tension on the suture line, this is to prevent an incidence as reported by Sewoyo *et al.* (2023) who documented the occurrence of incisional hernia which is a case of reoccurrence after repair. The hernia rings were observed to have relatively significant sized of healthy inter-hernia-ring musculature, hence, the decision to close each ring individually. As linking the three rings together could result in a larger wound area for wound healing process as well as traumatizing healthy in-tacked inter-hernia-rings tissue. The linking of the three rings could also expose the incision line to relatively more pressure (weight) from the viscera, however, managing the rings individually tends to distribute the visceral weight on both the suture line and the healthy inter rings tissue. Munif *et al.* (2022), reported suturing large opening which cannot be closed by suturing and may require mesh, it was possible due to the availability of sufficient surrounding muscle flaps to adequately apposed the opening during the operation. The suturing of the peritoneal sheet prior apposition of the abdominal muscles was aimed at preventing the chances of adhesions between the viscera and the abdominal wall.

## **CONCLUSION**

Farmers should be discouraged from housing rams with bulls in the same pen. Hernia due to blunt trauma without complications are unlikely to be incarcerated within five months of occurrence in a ram, furthermore, longitudinal incision should be avoided as much as possible to reduce the chances of surgical wound dehensences.

## **Disclaimer (Artificial intelligence)**

Authors hereby declares that NO generative AI technologies such as Large Language Models (ChatGPT, COPILOT, etc.) and text-to-image generators have been used during the writing or editing of this manuscript.

## **Ethical Approval**

Animal Ethic committee approval has been collected and preserved by the author(s)

## **REFERENCES**

Bodinga, H. A., Abubakar, N., Ahmad, U. S. and Atabo, S. M. (2021). Ventral abdominal hernia in a 2- year-old Balami ewe. Nigerian society for animal production (NSAP) 46TH Annual conference – Dutsin-MA 2021 book of proceedings

Duhu. D. C., Eze. A. C. and Ugwu. N. E. (2022). Dystocia induced by ventral abdominal hernia in a periparturient goat: a case report. Nigerian Veterinary Journal, 43 (1): 71 - 75

Fiordaliso, M., Ahmad, S., Simic, S., Zoubi, H. and Karaorman, M. (2021). A case report of incarcerated inguinal hernia: Amyand's hernia with adenocarcinoma tumor International Journal of Surgery Case Reports 81 (2021) 105716

Heemskerk J, Leijtens, J. W. A. and Steensel, V. S. (2023). Primary lumbar hernia, review and proposals for a standardized treatment. *Journal of Abdominal Wall Surgery*, 2:11754

Heise, C. P., Sproat, I. A. and Starling, J. R. (2002). Peritoneography (Herniography) for detecting occult inguinal hernia in patients with inguinodynia. *Annals of Surgery*, 235(1); 140–144

Hyowon, K. I. M., Seungjun, L. E.E., Seohyun, C. H. O., Kihoon, K. I. M., Kidong, E. O. M. and Jaehwan, K. I. M. (2023). Abdominal hernia as a rare manifestation of feline mammary gland carcinoma: a case report. *The Journal of Veterinary Medical Science*. 85(10): 1116–1120, 2023

Kalang, J. J., Adaji, O. G., Babalola, S. A., James, A. A. and Avazi, D. O. (2021). Management of omphalocele in a 4 months-old Nigerian Indigenous Breed of Dogs and a 3 months-old Alsatian Puppy, *Indian Vet. J.*, November 2021, 98 (11): 35 - 37

McBee, P. J., Walters, R. W. and Fitzgibbons R. J. (2022). Current status of inguinal hernia management: A review. *Int J Abdom Wall Hernia Surg* 2022(5): 159-64

Munif, M. R., Masud, R. I. and Tasnim, S. (2022). Surgical treatment of right lateral abdominal hernia in a heifer. *Iranian Journal of Veterinary Science and Technology*, (14)3

Sato R, Kim S, Okada S, Ikedo T, Satoh H and Steiner A (2023) Case report: Abdominal hernia repair using a surgical wire and an autologous omental graft in a Japanese Black calf. *Front. Vet. Sci.* 10:1119034

Sewoyo, P. S., Purwitasari, M. S., Rabiulfa, P. and Wirata, I. W. (2023). Incisional hernia case management in a local cat. *Journal of Applied Veterinary Science and Technology*: 04(2).2023.115-121

Sharun, K., Manjusha, K. M., Kumar, R., Saxena, A. C., Kinjavdekar, P., De, U. K., Pawde., A. M., and Amarpal. 2021. Traumatic lateral hysterocele complicated with intestinal adhesions in a pregnant goat. *Large Animal Review* 2021; 27: 291-294 291