

Case report

Anterior Mediastinal Teratoma Masquerading as Left Lobar Pneumonia and Pericardial Effusion: A Short Report

Abstract

Introduction

Teratomas are very rare types of germ cell tumours containing tissues originating from two or more of the germ cell layers.

Case Reports

We present a case of an eight-year-old female child who had features initially suggestive of left lobar pneumonia and pericardial effusion. However, after poor response to chemotherapy, computerized axial tomography (CT) of the chest was done which suggested mediastinal teratomas. Excision of the mass was done but the mass reoccurred during follow up.

Commented [1]: Correct it "Report"

Commented [2]: Correct it "recurred"

Conclusion

Anterior mediastinal teratoma is a rare form of germ cell tumour located in the anterior mediastinal mediastinum. Persistent non-specific respiratory symptoms should not be overlooked in children, as they may be indicative of anterior mediastinal teratoma. Surgical resection is curative for most teratomas.

Keywords: mediastinal teratomas; child; excision; CT; case report

Introduction

Cardiac and thoracic insults are not uncommon in children. [1-3] However, anterior mediastinal teratoma are uncommon tumour which consists of fully developed tissues such as muscle, teeth, hair, and bone. [4] Though it could occur mainly in the testicles and ovaries, it could also occur elsewhere in the body. [4] Resectable malignant cases treated with surgery alone was 17% compared with 100% when resection is combined with multiagent chemotherapy. There is a very high mortality for unresected malignant lesions even with the use of multiagent chemotherapy. [5] Mediastinal teratomas are the commonest extra-gonadal germ cell tumours, accounting for about 25% in children and 50%-70% of mediastinal tumours. [6] These masses may be asymptomatic; however, it may present with mass effect, rupture leading to pleural effusion and impaired endocrine function. [6] Pleural effusion may lead to the diagnostic dilemma especially in a developing country [6]

We report a case of a mediastinal teratoma in an 8-year-old female who was previously been treated for lobar pneumonia. This is a rare case report as this the first time we are managing this case and chest teratomas are rare in this locale.

Methods

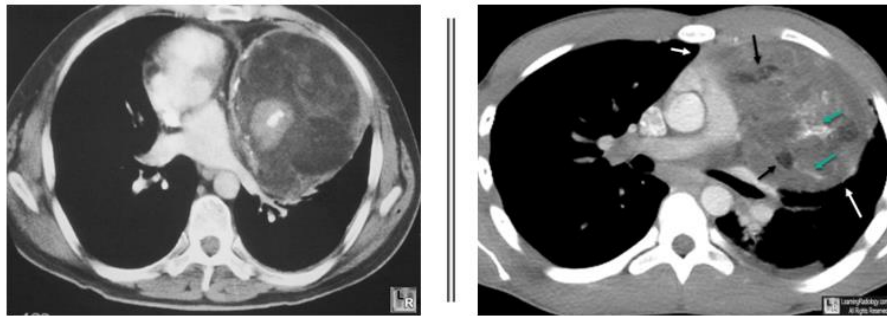
Computerized Axial tomography (CAT) scan was requested which showed a heterogeneous left anterior mediastinal mass that has obliterated the left cardiac margin. (Figure 1) A diagnosis of anterior mediastinal teratoma was made and she was referred to the cardio-thoracic surgeons for review. She also had a left anterolateral thoracostomy with excision of the anterior mediastinal mass and left lung decortication. She was discharged 6 days' post operation and is currently on follow-up. Repeat chest X-ray done 2 weeks' post-operation showed mature teratoma.

Commented [3]: In case report, this section should be mentioned under Case presentation

Case presentation

We report a case of AB, an eight-year-old female who presented with complaints of cough x 14/7, fever and chest pain x 12/7, difficulty in breathing x 6/7 all prior to presentation. Salient findings on presentation were pyrexia, respiratory distress, reduced chest expansion, increased tactile fremitus and vocal resonance and reduced air entry on the left hemithorax. A provisional diagnosis of Left Lobar Pneumonia and possible Koch's Disease was made. Cough and chest pain had persisted after medications. CT scan was requested which showed a heterogenous left anterior mediastinal mass that has obliterated the left cardiac margin. (Figure 1) A diagnosis of anterior mediastinal teratoma was made and she was referred to the cardiothoracic surgeons for review. She also had a left anterolateral thoracostomy with excision of the anterior mediastinal mass and left lung decortication. She was discharged 6 days post operation and is currently on follow-up. Repeat chest X-ray done 2 weeks post-operation showed mature teratoma.

Commented [4]: Kindly mention the histopathology findings



CHEST CT SCAN FILMS SHOWING MEDIASTINAL TERATOMA

Figure 1: CT scan of the index patient showing mediastinal Teratoma.

Discussion

Mediastinal teratomas are rare disease contributing 1-3% of childhood tumour. [7] They are of different variety with various manifestation depending on age and site of presentation, clinical outcomes and histology. [7] An incidence of 1 in 40,000 live births has been reported. It could be mature (well differentiated), pure immature (poorly differentiated) and immature with a malignant transformation. [8] Our Index case had a mature teratoma at the end of the clinical course. Most patients are asymptomatic (60%), however when symptoms occur, they are related to mass effect and tumour rupture. This was akin to our patient who had respiratory distress from the pressure effect of the mass. The index patient also presented with pericardial effusion that may have resulted from tumour rupture. Chest CT scan with contrast is the imaging modality of choice. [8] It gives information on the location and degree of extension to adjacent structures. Our patient had a CT scan report that showed a heterogenous left anterior mediastinal mass. [9,10]

Surgery is the mainstay of treatment. Surgical resection alone is curative for mature and immature teratomas. [9] Surgery was done for the index case with resection of the mass. Patients with immature teratoma with malignant transformation would require adjuvant chemotherapy after surgical resection for a period of 3-4 months, after which patient is reassessed for the need for further treatment. Our patient did not need any adjuvant chemotherapy since there were no malignant transformation. Prognosis is excellent for mature and pure immature teratomas. There is a 20% risk of recurrence in patients with immature teratoma with malignant transformation. This was also akin to our patient who had recurrence after resection of the mass. [8,10]

Conclusion

Anterior mediastinal teratoma is a rare form of germ cell tumour located in the anterior mediastinal mediastinum. Persistent non-specific respiratory symptoms should not be overlooked in children, as they may be indicative of anterior mediastinal teratoma. Surgical resection is curative for most teratomas.

Ethics Approval and Consent to participate: Not applicable

References

1. Chinawa AT, Chinawa JM. Compendium of cardiac diseases among children presenting in tertiary institutions in southern Nigeria: a rising trend. *Libyan J Med.* 2021 ;16(1):1966217.
2. Chinawa JM, Obu HA, Eke CB, Eze JC. Pattern and clinical profile of children with complex cardiac anomaly at University of Nigeria Teaching Hospital, Ituku-Ozalla, Enugu State, Nigeria. *Niger J Clin Pract.* 2013 Oct-Dec;16(4):462-7. doi: 10.4103/1119-3077.116890.
<https://bmcsresnotes>.
3. Chinawa, J.M., Eze, J.C., Obi, I, Arodiwe I, Ujunwa F, Adiele K et al. Synopsis of congenital cardiac disease among children attending University of Nigeria Teaching Hospital Ituku Ozalla, Enugu. *BMC Res Notes* 6, 475 (2013). <https://doi.org/10.1186/1756-0500-6-475>.com/articles/10.1186/1756-0500-6-475#citeas
4. Sana Mosbahi, Sahla Sallemi, Nouha Ben Abdejelil, Salma Mani, Sabrine Ben Youssef, Samia Belhassen et al. Excision of Giant Retroperitoneal Immature Teratoma with post-operative chylous ascites. *Journal of Pediatric Surgery Case Reports* 2021;67: 2213-5766,
5. Katoto PDMC, Byamungu LN. Mediastinal cystic teratoma misdiagnosed as pleural tuberculosis: A case report and review of 53 cases revealed by pleural effusion. *Clin Case Rep* 2021;9(6):04139. doi: 10.1002/ccr3.4139

6. Qureshi SS, Kammar P, Kembhavi S. Excision of retroperitoneal germ cell tumor in children: a distinct surgical challenge. *J Pediatr Surg* 2017; 52:1344-1347
7. Ni PK, Ketut A, Aank AN, Luh PI, Gusti IA. Teratoma in Children: Three cases experience in Sanglah Hospital, Bali, Indonesia. *GSC Advanced Research and Reviews*, 2021, 06(02), 013–019
8. Kurt S, Avşar HA, Doğan ÖE, Saatli HB, Saygılı U. Effects of mature cystic teratoma on reproductive health and malignant transformation: A retrospective analysis of 80 cases. *J Turk Ger Gynecol Assoc*. 2019 May 28;20(2):84-88. doi: 10.4274/jtgga.galenos.2018.2018.0003.
9. Masaya Kawaguchi, Hiroki Kato, Yoshifumi Noda, Natsuko Suzui, Tatsuhiko Miyazaki, Tatsuro Furui, Ken-Ichirou Morishige, Masayuki Matsuo, CT and MRI characteristics of ovarian mature teratoma in patients with anti-N-methyl-D-aspartate receptor encephalitis, *Diagnostic and Interventional Imaging* 2021; 102: 447-453
10. Santos PC, Mala CP, Pereira JC, Oliveira TC. Giant mediastinal teratoma found during surgery after thoracic trauma. *Braz J Cardiovasc Surg*. 2007;22(2):252-254