

**Effect of *Alstonia boonei* and *Morinda lucida* in Renal Histology of wistar rats infected with *Trypanosoma brucei brucei***

**Abstract**

Animal African trypanosomiasis is a protozoan disease caused by trypanosomes and transmitted through the bite of an infected tsetse fly. The disease has an adverse effect to the economy of the affected areas and drugs used for the treatment of the disease are faced with several challenges ranging from resistance to the parasite to high level of toxicity. Our study aimed at evaluating the effect of *Alstonia boonei* and *Morinda lucida* plant extracts on the renal histology of wistar rats infected with *Trypanosoma brucei brucei*. Phytochemical screening of the methanol extracts indicated the presence of alkaloids, saponins, tannins, flavonoids, carbohydrates, phenols and steroids/terpenes, while glycosides were not detected. Only four of the eight constituents tested for were detected in the chloroform leaf extract of *A. boonei*, namely, alkaloids, tannins, flavonoids, and carbohydrates. Alkaloids, tannins flavonoids, and carbohydrates were detected in both the chloroform and methanol extract of *Morinda lucida*. Histological lesions of the infected-untreated rats revealed severe cellular degeneration in the renal cortex of *T. brucei* infected rats. Furthermore, the glomerular tufts were shrunken leaving a large Bowman's. The renal photomicrographs of rat treated with 500mg/kgbw of *Alstonia boonei* revealed that the renal cortex presented apparently normal histological features of Malpighian renal corpuscle containing glomerulus and Bowman's space with slightly shrunken glomerulus. The proximal convoluted tubules had narrow lumina and were lined with cuboidal cells with rounded vesicular basal nuclei. Groups treated with 1000mg/kgbw revealed erythrocytic remains of degenerated renal cells with scanty inflammatory cells in the cortical region of kidney of the wistar rats. However, the

glomerulus, the proximal and distal convoluted tubules presented normal histological features. The results indicated that treatment with graded doses of methanol extract of *A. boonei* elicited varying effects on the visceral organs of the infected animals. It was noted that *Alstonia boonei* ameliorated the effect of the infection on the kidney of the infected animals with the histology sections being comparable with those treated with the reference anti-trypanosomal drug (Diminazine aceturate) and the uninfected rats. However, *Morinda lucida* had little or no ameliorative effect on the kidney of wistar rats infected. Therefore, we recommend that extracts of *Astonia boonei* should be characterized and active components responsible for this ameliorative effect be detected and elucidated structurally.

**Keywords:** Trypanosomiasis, Parasitaemia, Phytochemicals, Toxicity

## INTRODUCTION

Animal trypanosomosis has a serious effect of ravaging both lower and higher ruminants in sub-saharan Africa and is caused by a protozoan parasite of the genus *Trypanosoma* [1]. The species responsible for this disease known as nagana in Africa are *Trypanosoma vivax*, *Trypanosoma congolense* and to a lesser extent *Trypanosoma brucei brucei*. The disease is transmitted through the bite of an infected tsetse fly of the *Glossina* specie. It is implicative in causing severe anaemia, weight loss, reduced productivity, infertility and abortion, with death occurring in some animals during the acute and chronic phase of the infection [2].

In Nigeria, studies of ethno medicinal plants used in the traditional management of trypanosomiasis indicated both significant *in vitro* and *in vivo* anti-trypanosomal activity [3]. The country is richly endowed with indigenous plants, which are used in herbal medicine to cure

diseases and heal injuries, some of these plants are used as food or medicine. These indigenous plants exhibit a wide range of biological and pharmacological activities such as anticancer, anti-inflammatory, diuretic, laxative, antispasmodic, antihypertensive, antidiabetic and antimicrobial functions. It is generally assumed that the active medicinal constituents contributing to these protective effects are the phytochemicals, vitamins and minerals. Some of these secondary metabolite can act singly or in synergy to bring about healing [4].

Currently, homidium chloride, isometamidium and diminazene aceturate are used for the treatment of this disease. Each of these drugs has one or more of these challenges: expensive, highly toxic, need parenteral administration and parasites increasing resistance. Also, attempt to produce vaccine for the prevention of trypanosomiasis proves abortive because of the parasite changing its antigenic identity. Therefore, the need for alternative new molecules that are safe, effective and affordable is urgent [5].

Scientific studies revealed that natural products derived from plants offer novel possibilities to obtain new drugs that are active against trypanosomes and investigation of antitrypanosomal activity of traditionally used plants has been a major area of concern [5,6]. There is need for the development of new agents to complement the existing drugs for the treatment of African trypanosomiasis. *Alstonia boonei* and *Morinda lucida* are used as traditional remedy for several infectious and noninfectious diseases including antihelminthic, anti-inflammatory, analgesic/pain-killing, antimalaria/antipyretic, antidiabetic (mild hypoglycaemic), antimicrobial and antibiotic properties [7]. These justify the need to explore these plants as potent drugs for trypanosomiasis.

## **Materials and Methods**

## **Plants Materials**

The plant materials were harvested in the morning in, Zaria Local Government Area of Kaduna State. It was authenticated in the herbarium, Department of Biological Science, Kaduna State University and given the voucher number (A765 and Q567) for *Alstonia boonei* and *Morinda locida* respectively. It was air dried at room temperature, pulverized in a mortar using pestle to obtain fine powder.

## **Experimental Animals**

Sixty (60) wistar rats were used for this study. The animals were purchased from the animal house of Nigerian Institute for Trypanomiasis Research, Kaduna. They were kept in a standard rat cage, fed with standard pellet diet with water *ad libitum* for thirty (30) days.

## **Infection of Animals with Trypanosomes**

The parasite *Trypanosoma brucei brucei* was obtained from Nigerian Institute for Trypanomiasis Research, Kaduna. The animals were inoculated with 1000 parasite per ml of blood intraperitoneally. The number of parasite was compared with Harbert and Lumsden rapid matching method [8].

## **Extraction from Plant Materials**

Extraction was done using Soxhlet apparatus. One thousand grams (1000g) of the powdered plant was divided into five hundred (500g) each. 2,000ml of each of methanol and chloroform were used for the extraction of each of the powdered plant. The solvent was recovered and concentrated in vacuo to obtain the extract.

## **Phytochemical Analysis of the Plant Parts**

The phytochemical analysis was carried out according to the method of Sofowora. The presence of tannins, saponins, flavonoids, glycosides, anthraquinones, carbohydrate, phenols, terpenes and alkaloids was tested qualitatively [9].

## **Histopathological Examination of Harvested Organs**

The kidney specimens from each rat was stored immediately in 10% v/v formalin in normal saline after gross histological examination and dehydrated using increasing Concentrations of isopropyl alcohol (80e100%). Paraffin sections at 5mm thickness was made from the paraffin embedded organs using a Leica rotary microtome (Bright B5143 Huntington, England). This was followed by routine staining with hematoxylin and eosin which involved the process of deparaffinization, hydration, staining, rinsing and clearing in xylene. Slides was viewed under light microscope with photomicrographs taken with a Leica DM750 Camera Microscope (400 X) [10]. Histopathological lesions were scored using semi-quantitative approach as follows:

0 for normal, 1 (1%e30%) for mild, 2 (31%e70%) for moderate, and 3 (>70%) for severe.

## **Ethical Clearance**

Ethical clearance for the use of laboratory animals was obtained from Kaduna State Ministry of Agriculture and Forestry, Kaduna.

## **Statistical Analysis of Data**

Values of the data obtained from the study was summarized and expressed data analysis was performed using Statistical Package for Social Science (SPSS) 2018 version 23.0.

## RESULTS

### **Phytochemical Constituents Screening of Extracts of *Alstonia boonei* and *Morinda lucida* Using Methanol and Chloroform as Solvents**

The results of the phytochemical constituents and screening of the methanolic leaf extract of *Alstonia boonei* indicated the presence of seven constituents, namely, alkaloids, saponins, tannins, flavonoids, carbohydrates, phenols and steroids/terpenes, while glycosides were not detected. Only four of the eight constituents tested for were detected in the chloroform leaf extract of *A. boonei*, namely, alkaloids, tannins, flavonoids, and carbohydrates. Four phytoconstituents namely, alkaloids, tannins, flavonoids, and carbohydrates were detected in the methanol extract of *Morinda lucida*. In the chloroform extract of *M. lucida*, only three of the eight phytoconstituents were detected namely, alkaloids, tannins, and flavonoids; saponins, glycosides, carbohydrates, phenols, and steroids were not detected. All three constituents that were present in the chloroform extract of *M. lucida* were detected in relatively high quantities. Glycosides were not detected in all the solvents leaf extracts of the plants, while carbohydrates were detected, albeit in relatively minute quantities, in the methanol and chloroform extracts of *A. boonei* and in the methanol extract of *M. lucida*. Phenols as well as terpenes were detected in the methanol extract of *A. boonei*; none was detected in the chloroform extract of the plant nor in either the methanol or chloroform extracts of *M. lucida* (Table.1).

**Table 1 Phytochemical Screening of the Methanol and Chloroform Leaf Extracts of *Alstonia boonei* and *Morinda lucida***

Phytochemical Constituents	ABME	ABCE	MLME	MLCE
Alkaloids	+++	+++	+++	+++
	+++	+++	+++	+++
Saponins	+++	---	---	---
Tannins	+++	+++	+++	+++
Flavonoids	+++	+++	+++	+++
Glycosides	---	---	---	---
Carbohydrates	+	+	+	---
Phenolic compounds	+++	---	---	---
Terpenes	++	---	---	---

ABME: *Alstonia boonei* Methanol Extract; ABCE: *Alstonia boonei* Chloroform Extract; MLME:

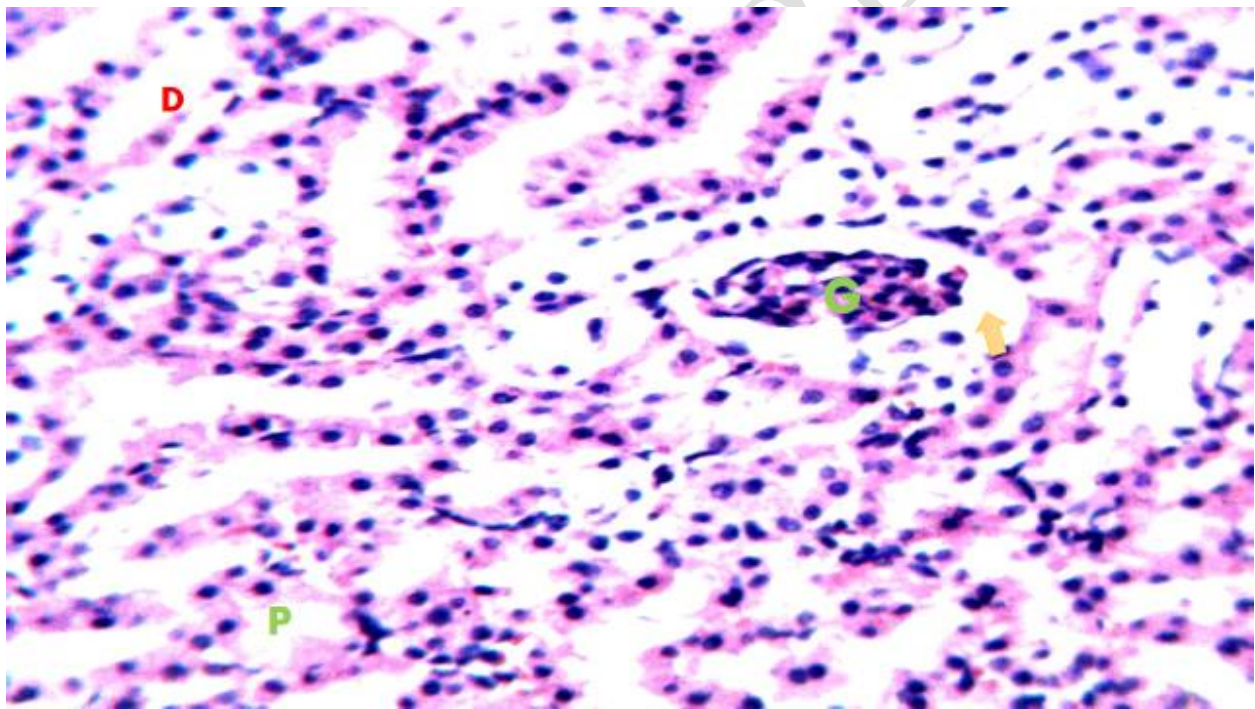
*Morinda lucida* Methanol Extract; MLCE: *Morinda lucida* Chloroform Extract

+++ : highly present; ++ : moderately present; + : present; --- : undetected

**Histopathological Studies of Kidney Organs of *Trypanosoma brucei brucei* Infected Wistar Rats Treated with Leaf Extracts of *Alstonia boonei boonei* and *Morinda lucida***

**Effect of 500 mg/kgb.wt of the methanol extract of *Alstonia boonei* on kidney histology of *Trypanosoma brucei brucei* infected rats**

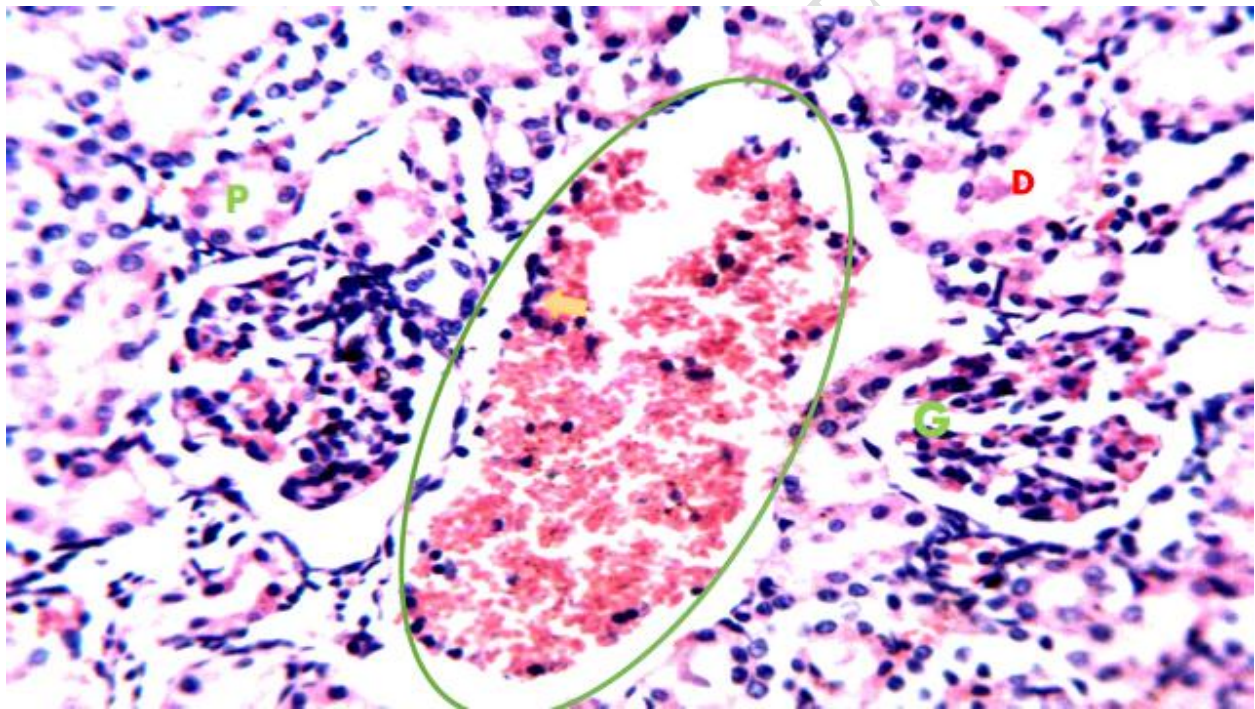
The renal photomicrographs of wistar rat in Group A revealed that the renal cortex presented apparently normal histological features of Malpighian renal corpuscle containing glomerulus and Bowman's space with slightly shrunken glomerulus. The proximal convoluted tubules had narrow lumina and were lined with cuboidal cells with rounded vesicular basal nuclei. The distal convoluted tubules had wider lumina and were also lined with cuboidal cells (Plate I).



**Plate I:** Photomicrographs of renal section from *T. brucei* infected rat administered 500 mg/kgb.wt of methanol extract of *A. boonei* (Group A). The renal cortex presents apparently normal histological features of Malpighian renal corpuscle containing glomerulus (G) and Bowman's space (arrowhead) with slight shrunken glomerulus. The proximal convoluted tubules (P) have narrow lumina and are lined with cuboidal cells with rounded vesicular basal nuclei. The distal convoluted tubules (D) have wider lumina and are lined with cuboidal cells. H&E x25

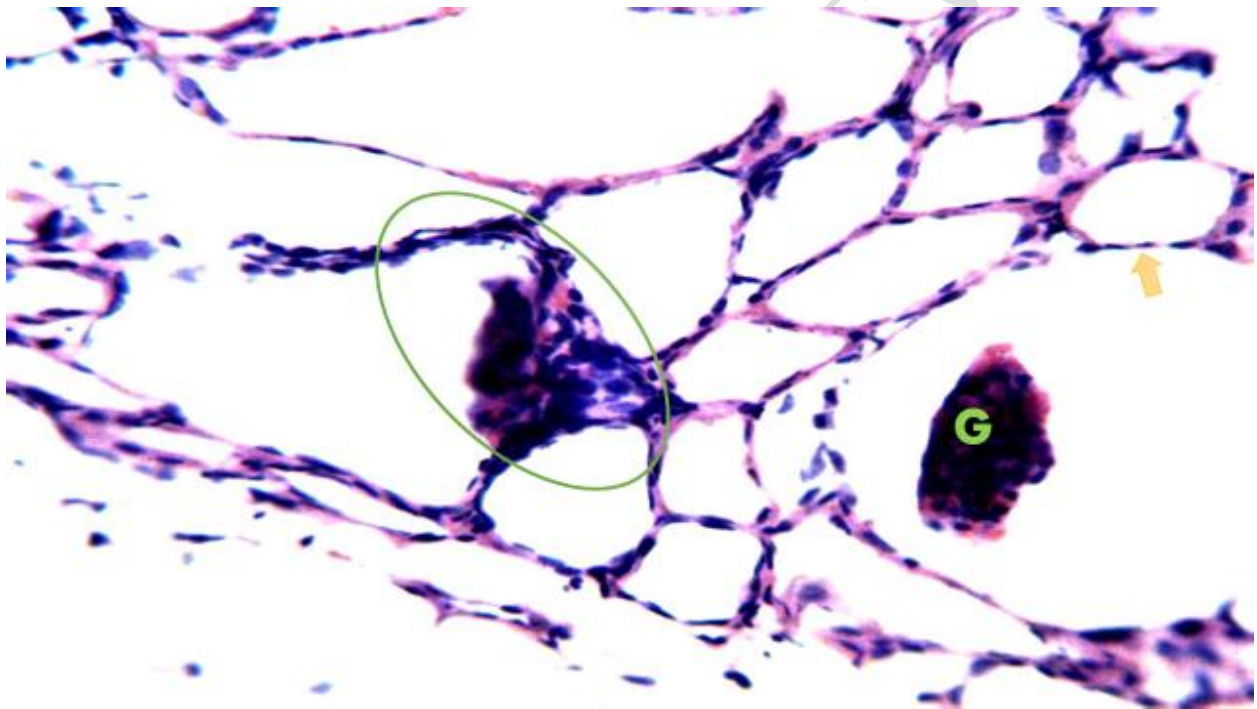
**Effect of 1000 mg/kgb.wt of the Methanol Leaf Extract of *Alstonia boonei* on Kidney Histology of *Trypanosoma brucei brucei* Infected Wistar Rats**

Erythrocytic remains of degenerated renal cells with scanty inflammatory cells were seen in the cortical region of kidney in the rats in Group B. However, the glomerulus, and the proximal and distal convoluted tubules presented normal histological features (Plate II).



**Plate II:** Photomicrographs of renal section of *T. brucei brucei* infected rats administered 1000 mg/kgb.wt of methanol extract of *A. boonei* (Group B). The renal cortex shows what appeared to be erythrocytic (circle) remains of degenerated renal cells with scanty inflammatory cells (arrowhead). The glomerulus (G), proximal (P) and the distal convoluted tubules (D) present normal histological features. H&E x250

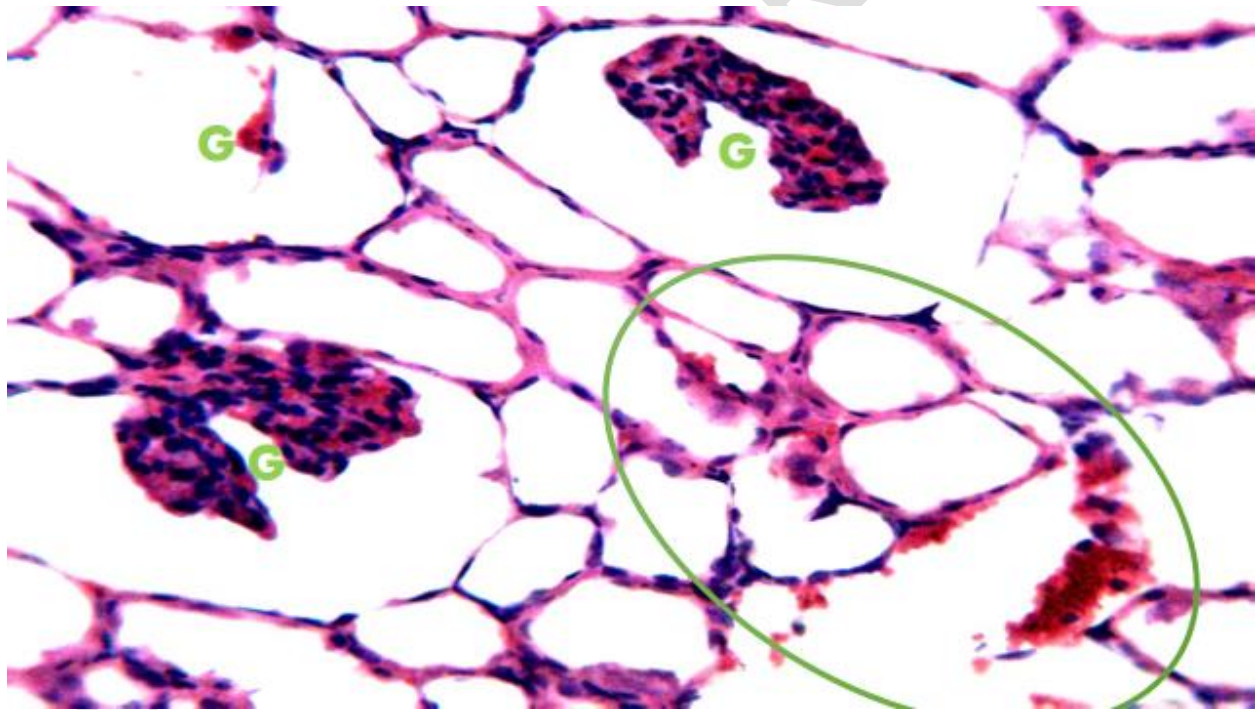
**Effect of 500 mg/kgb.wt of the chloroform extract of *M. lucida* on kidney histology of *T. brucei brucei* infected rats:** The renal cortex of the rat in Group C showed severe atrophy of the glomerular tuft; in addition, almost all the tubular cells showed degeneration. There was also focal aggregation of mononuclear cells around one of the glomeruli (Plate III).



**Plate III:** Photomicrographs of renal section *T. brucei brucei* infected rats administered 500 mg/kgb.wt of chloroform extract of *M. lucida* (Group C). The renal cortex shows severe atrophy of the glomerular tuft (G), with nearly all the tubular cells showing degeneration (arrow head). Note the focal aggregation of mononuclear cells around one of the glomerulus (circle). H&E x250

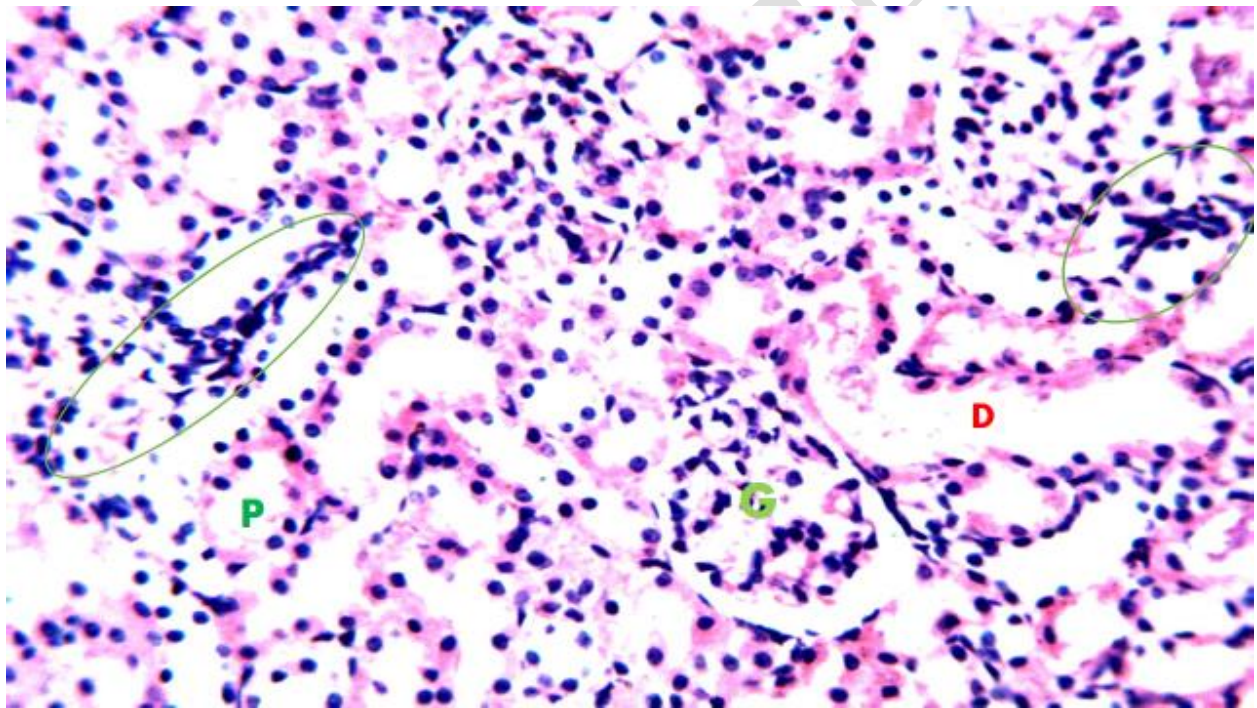
**Effect of 1000 mg/kgb.wt of the Chloroform Extract of *Morinda lucida* on Kidney Histology of *Trypanosoma brucei brucei* Infected Wistar Rats**

Renal section from *T. brucei brucei* infected rats treated with 1000 mg/kgb.wt of chloroform extract of *M. lucida* (Group D) showed features of cellular degeneration and shrunken glomerular tuft, as well as hemorrhage (Plate IV).



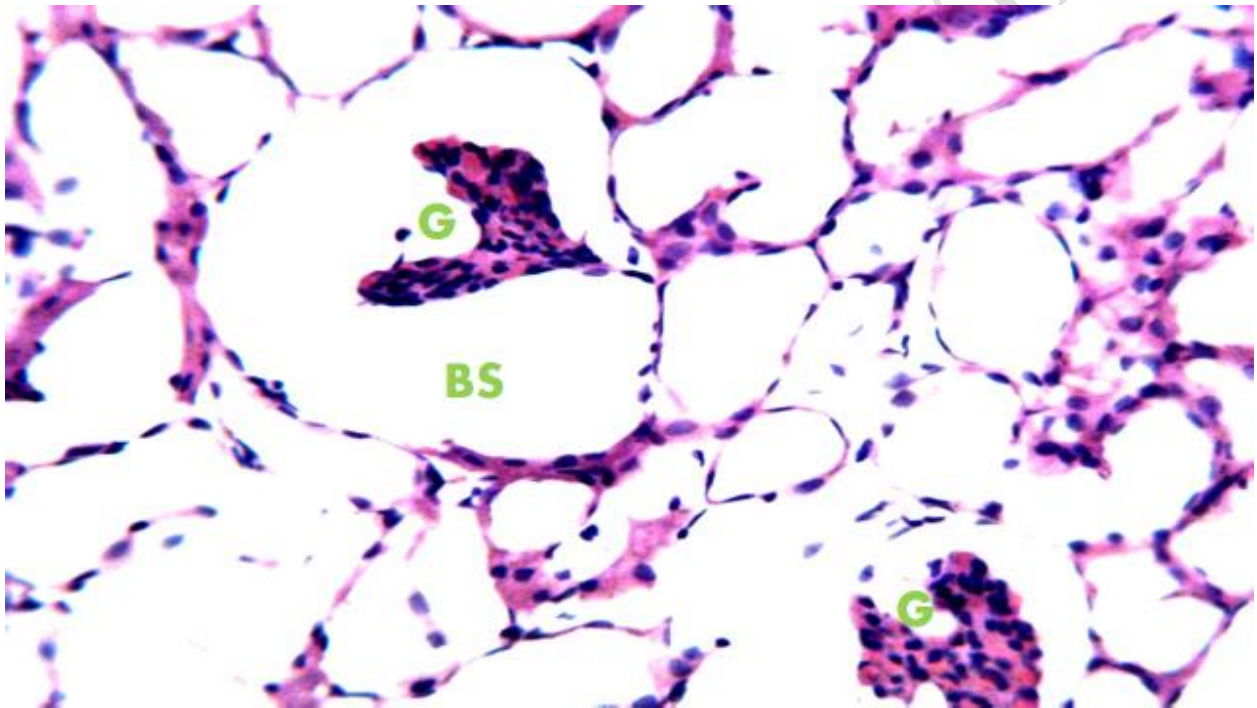
**Plate IV:** Photomicrographs of renal sections *T. brucei brucei* infected rats administered 1000 mg/kgb.wt of chloroform extract of *M. lucida* (Group D). The section is hemorrhagic (circle), showing features of cellular degeneration and shrunken glomerular tuft (G). H&E x250

**Effect of Diminazine aceturate (3.5 mg/kgb.wt) on kidney histology of *T. brucei brucei* infected rats:** The renal cortex of rats in Group E showed apparently normal renal corpuscle of glomerulus, proximal and distal convoluted tubules, with few focal aggregated mononuclear infiltrated cells (Plate V).



**Plate V:** Photomicrographs of renal section *T. brucei brucei* infected rats administered Diminazine 3.5 mg/kgb.wt (Group E). The renal cortex shows apparently normal renal corpuscle of glomerulus (G), proximal and distal convoluted tubules (P and D) with few focal aggregated mononuclear infiltrated cells (circle). H&E x250

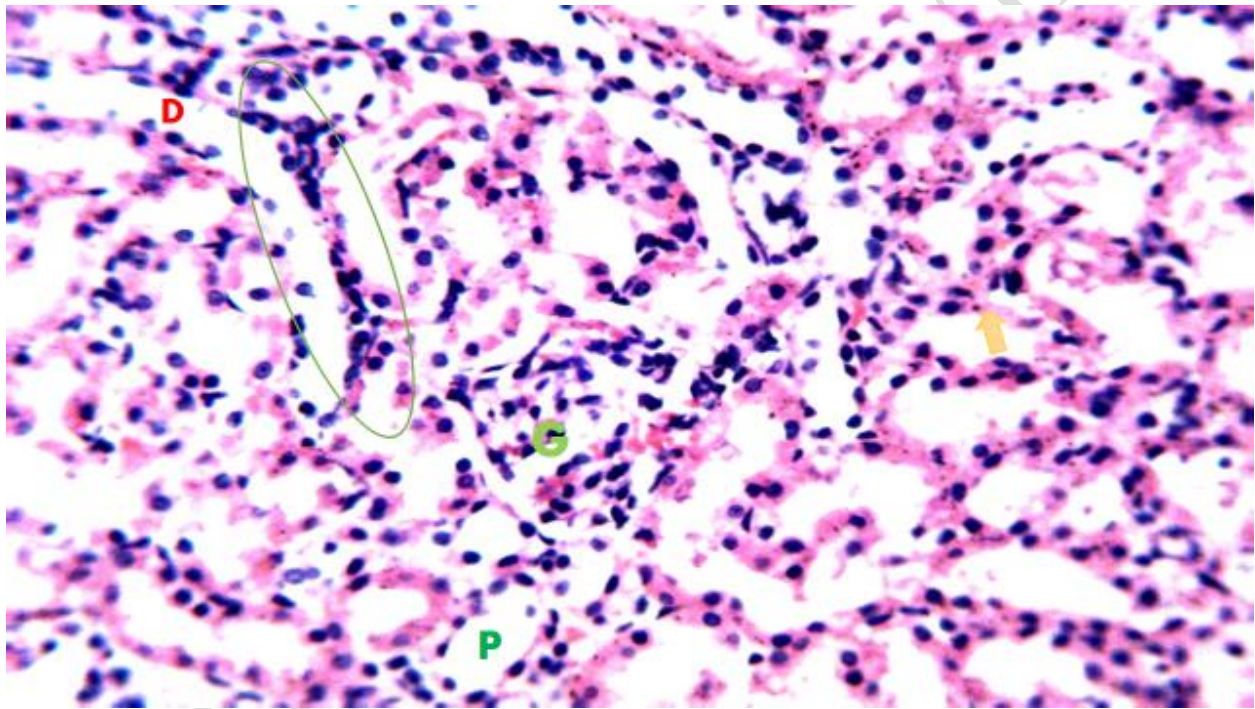
**Kidney histology of untreated *Trypanosoma brucei brucei* infected rats:** Severe cellular degeneration was seen in the renal cortex of *T. brucei* infected rats that received no treatment (Group F). Furthermore, the glomerular tufts were shrunken leaving a large Bowman's space (Plate VI).



**Plate VI:** Photomicrographs of renal section of untreated *T. brucei brucei* infected rats (Group F) The renal cortex is showing severe cellular degeneration and shrunken glomerular tufts (G) leaving a large Bowman's space (BS). H&E x250

**Kidney histology of uninfected rat:** The renal cortex of uninfected rat (Group G) revealed apparently normal glomerulus, proximal and distal tubules, with few infiltrated inflammatory cells (Plate VII).

### **Effect on Liver Histology**



**Plate VII:** Photomicrographs of renal sections of uninfected-untreated (Group G). The renal cortex shows renal corpuscle with apparently normal glomerulus (G), proximal and distal tubules (P and D) with few infiltrated inflammatory cells (circles). H&E x250

## DISCUSSION

The result from the phytochemical screening obtained in this study revealed the presence of bioactive components in the aqueous and chloroform extracts of the leaves of *A. boonei* which is in agreement with the reports of [11] who noted the presence of phytochemicals in the water and methanol leaf extracts of *A. boonei*. [12] had also reported the presence of some bioactive agents in the methanol stem bark and leaf extracts of the plant extracts. These reports indicated that *A. boonei* is an excellent source of chemical moieties that could find important medicinal and pharmacological applications. Similarly, extracts of *Morinda lucida* showed an array of phytoconstituents including alkaloids, tannins, flavonoids, and carbohydrates. This also agreed with the reports of [13,14] who had previously reported the presence of bioactive agents in solvent extracts of the stem bark and root of *M. lucida* (saponins, tannins, anthracenes, flavonoids, alkaloids, carbohydrate and protein).

The present results indicated that the class of phytochemicals varied between the two plants (*A. boonei* and *M. lucida*) and between the solvent used for extracting a particular plant. According to [15], the metabolic profiles of medicinal plants are mainly controlled by genetic factors, adding that variations in the levels of phytochemicals may represent long-term ecological and evolutionary interactions. Thus, the genetic differences between the two plants. The present results indicated that *T. brucei brucei* infection in rats is characterized by several histopathological derangements of visceral organs (liver) which may impair their functionality and result in death of untreated animals. The histopathological abnormalities observed in the kidney of untreated *T. brucei brucei* infected rats were consistent with the reports of other authors who had reported the effect of *Trypanosoma* infections in animals. Also, [16] had noted alterations in kidney, liver, lungs and spleen of mice infected with *T. brucei*. In that study the kidneys were characterized by congested intertubular spaces, and the lungs were seen with congestions of the blood vessels, interstitial expansion and emphysema in infected mice. Again, [17] who assessed the histological changes associated with infection with *T. evansi*, a phylogenetic close relative of *T. brucei*, noted marked changes in the visceral organs including cellular infiltration of the liver, myocardial necrosis, tubular necrosis of the nephrons and destruction of the Bowman's capsule. The changes in the visceral organs seen in trypanosome have been attributed to any one or a combination of the following factors: mechanical damage, increased vascular permeability, deranged immunological mechanisms, and/or the activities of trypanosome toxins [17].

The results of the histology tissue indicated that treatment with graded doses of either the methanol extract of *A. boonei* or the chloroform extract of *M. lucida* elicited varying effects on the kidneys of the infected animals. It was noted that *Alstonia boonei* ameliorated the effect of the infection on the kidney of the infected animals with the histology sections being comparable with those treated with the reference anti-trypanosomal drug (Diminazine aceturate) and the uninfected rats. The *M. lucida* extract was shown to exhibit lower tissue protective effect against *T. brucei brucei* infection when compared with *A. boonei*: in the *Morinda lucida* treated animals, the kidneys revealed gross pathologies that were also seen in the untreated rats. From the aforementioned postulations by [17] on the probable mechanisms of tissue damage seen with trypanosome infection, it may be inferred that *A. boonei* act to prevent or ameliorate the tissue damages by inhibiting several of these mechanisms. The results of the phytochemical screening of the methanol extract of *A. boonei* and the chloroform extract of *M. lucida* indicated that *A. boonei* contained phenols, saponins, steroids, and terpenes, in addition to alkaloids, tannins, and flavonoids which were detected in *M. lucida* [19,20]. These differences might lend credence to the reno-protective effects observed in the *A. boonei* treated rats.

## CONCLUSION

Our finding reveals that crude extracts of *Alstonia boonei* and *Morinda lucida* contain variety of phytochemicals which have documented antimicrobial effects. The crude extract of *Alstonia boonei* demonstrated ameliorative *in vivo* effects on parasitaemia and some histological lesions of wistar rats infected with *Trypanosoma brucei brucei*.

### Disclaimer (Artificial intelligence)

Author(s) hereby declare that NO generative AI technologies such as Large Language Models (ChatGPT, COPILOT, etc.) and text-to-image generators have been used during the writing or editing of this manuscript.

## REFERENCES

1. Buguet, A., Mpanzou, G. and Bentivoglio, M. (2014). Human African trypanosomiasis: a highly neglected neurological disease. *Neglected tropical diseases and conditions of the nervous system*, 165-181.
2. Maichomo, M. W., Orenge, C. O. and Gamba, D. O. (2021). Introduction of African Animal Trypanosomosis (AAT)/Nagana. In *Combating and Controlling Nagana and Tick-Borne Diseases in Livestock* (pp. 1-23). IGI Global.
3. Bashir, L., Shittu, O. K., Sani, S., Busari, M. B. and Adeniyi, K. A. (2015). African natural products with potential anti-trypanosomal properties: A review. *International Journal of Biochemistry Research and Review*, 7(2), 45-79.
4. Abd El-Ghani, M. M. (2016). Traditional medicinal plants of Nigeria: an overview. *Agriculture and Biology Journal of North America*, 7(5), 220-247.
5. Chukwudi, I. C., Omemgboji, O. C. and Anene, B. M. (2020). Efficacy of Isometamidium Combination with Verapamil, Chlorpromazine or Sodium-ethylenediaminetetra-acetic Acid in Treatment of Experimental Diminazene Aceturate-resistant Strain of *Trypanosoma brucei brucei* Infection in Rats. *Sahel Journal of Veterinary Sciences*, 17(4), 37-45.
6. Ungogo, M. A., Ebiloma, G. U., Ichoron, N., Igoli, J. O., De Koning, H. P. and Balogun, E. O. (2020). A review of the antimalarial, antitrypanosomal, and antileishmanial activities of natural compounds isolated from Nigerian flora. *Frontiers in chemistry*, 8, 617-648.
7. Boakye, Y. D., Agana, T. A., Oteng-Amankwah, E. A., Boamah, V. E. and Agyare, C. (2023). Evidence-based review of medicinal plants for the management of onchocerciasis. *Natural Products in Vector-Borne Disease Management*, 27-49.

8. Herbert, W. J. and Lumsden, W. H. R. (1976). Rapid estimation of trypanosome parasitaemias by matching. *Transactions of The Royal Society of Tropical Medicine and Hygiene*, 70(4), 282-282.
9. Sofowora, A. (1996). Research on medicinal plants and traditional medicine in Africa. *The Journal of Alternative and Complementary Medicine*, 2(3), 365-372.
10. Feldman, A. T. and Wolfe, D. (2014). Tissue processing and hematoxylin and eosin staining. *Histopathology: methods and protocols*, 31-43.
11. Omoya, F. and Oyebola, T. F. (2019). Antiplasmodial activity of stem bark and leaves of *Alstonia boonei* (De Wild). *Journal of Microbiology and Experimentation*, 7(5), 241-245.
12. Adotey, J. P. K., Adukpo, G. E., Opoku Boahen, Y. and Armah, F. A. (2012). A review of the ethnobotany and pharmacological importance of *Alstonia boonei* De Wild (Apocynaceae). *International Scholarly Research Notices*, (1), 58-71.
13. Akinseye, O. R., Morayo, A. E. and Olawumi, A. S. (2017). Qualitative and quantitative evaluation of the phytochemicals in dry, wet and oil extracts of the leaf of *Morinda lucida*. *J. Biol. Agric. Healthcare*, 7(7), 22-25.
14. Ogbuanu, C. C., Nwagu, L. N., Ezeh, C. N., Achara, N. I. and Onwuatuegwu, J. T. C. Proximate, nutraceutical composition and antimicrobial activities of *Uvaria chamea* (Udagu) seeds and oil.
15. Ahmadi, H., Fatahi, R., Zamani, Z., Shokrpour, M., Sheikh-Assadi, M. and Poczai, P. (2024). RNA-seq analysis reveals narrow differential gene expression in MEP and MVA pathways responsible for phytochemical divergence in extreme genotypes of *Thymus daenensis* Celak. *BMC genomics*, 25(1), 237.

16. Hussain, S., Sultana, T., Sultana, S., Hussain, B., Mahboob, S., Al-Ghanim, K. A., & Riaz, M. N. (2021). Seasonal monitoring of River through heavy metal bioaccumulation and histopathological alterations in selected fish organs. *Journal of King Saud University-Science*, 33(8), 101626.
17. Shuaibu, Z. A., Lawal, A. I., Samuel, F. U., Ereke, S. O., Sani, N. A., Ibrahim, M. A. and Fanaiye, G. O. (2018). Histopathological changes associated with *Trypanosoma congolense* infection in Albino rats.
18. Adeyemi, N. A., Wada, Y. A., Oniye, S. J., Hussaini, M., & Muhammad, A. D. (2024). Effects of *Trypanosoma brucei brucei* infection on haematological profile, testosterone level, and oxidative stress status in wistar rat (*rattus norvegicus*). *Bima Journal of Science and Technology*, 8(1), 30-38.
19. Ferreira da Vinha, A., Barreira, S., Castro, A. and Machado, M. (2013). Comparison between the phytochemical and antioxidant properties of plants used in plant infusions for medicinal purposes. *Journal of Agricultural Science*, 5(11), 11-19.
20. Dhawan, D. and Gupta, J. (2017). Research article comparison of different solvents for phytochemical extraction potential from datura metel plant leaves. *Int J Biol Chem*, 11(1), 17-22.