

Case report

Effect of photobiomodulation on postoperative pain of single visit endodontic treatment: A case report

ABSTRACT

Photobiomodulation (PBM), formerly known as low-level laser therapy (LLLT), is a therapeutic technique that utilizes light at specific wavelengths to promote biological effects in cells and tissues. It can be applied to alleviate postoperative pain, accelerate healing, and reduce inflammation. The study aimed to evaluate the effect of Photobiomodulation (PBM) on postoperative pain following the treatment of two maxillary molars in a single-visit endodontic procedure. A patient with pain in teeth 1.6 and 1.7, diagnosed with irreversible pulpitis, received single visit endodontic treatment, with PBM used as an analgesic alternative. Before treatment, assessments of spontaneous pain, palpation (vestibular and palatal), and percussion (vertical and horizontal) were performed. After standard treatment, PBM was applied to tooth 1.7, while tooth 1.6 underwent a simulated procedure without device activation. The patient received a Visual Analog Scale (VAS) to record pain at 4, 8, and 12 hours after treatment, along with Paracetamol 750mg for use only if needed, recording the time of use. After 24 hours, a reassessment was conducted. Despite an increase in all pain levels compared to baseline, there was a reduction of over 50% in spontaneous pain parameters at all time points, reaching zero at 4 hours. There was a significant reduction in horizontal percussion (over 50%) and vertical percussion (about 29%), and a 36% increase in palatal palpation. There was no need for analgesics in any case. It is concluded that PBM may be an analgesic alternative for post-endodontic instrumentation spontaneous pain, acting on the periodontal ligament and reducing local inflammation. Larger studies are needed for a more comprehensive analysis of pain, including palpation and percussion.

Keywords : Low-Level Light Therapy (LLLT), Pain, Pain Management, Endodontic Inflammation.

Introduction

Apical periodontitis (acute and chronic) stands among the most prevalent oral inflammatory diseases worldwide¹, with approximately 50% of the global adult population having at least one affected tooth².

While endodontic treatment aims primarily to address apical periodontitis¹, persistent post-instrumentation pain remains one of the main challenges³, with a prevalence ranging from 3 to 58%, being more intense within the first twenty-four hours post-intervention⁴.

Performing endodontic procedures in a single visit is associated with increased surgical trauma, often cited as a common cause of post-treatment pain^{1,5}.

Pain assessment, being subjective, presents significant difficulties in analysis. Researchers have developed analysis tools to standardize its intensity. The visual analog scale (VAS) is a type of one-dimensional instrument consisting of a 100 mm line with zero at one end representing "no pain" and ten at the other end representing "maximum pain". It is widely agreed that VAS is easy and quick to administer, readily understandable by patients, and represents an appropriate way to estimate pain intensity⁶.

For a more thorough assessment, the analysis should include clinical maneuvers to evaluate provoked pain and periapical tissue health. In endodontics, two key diagnostic tools are recommended: palpation and percussion. Palpation consists of gentle digital pressure on the apical region from both the vestibular and palatal sides to detect bone swelling, exudate, or changes in pain. Percussion involves applying vertical and horizontal pressure to the tooth to assess sensitivity changes in the affected area⁷.

Given the high prevalence and multifactorial etiology of post-endodontic instrumentation pain, studies have explored alternatives to overcome the limitations of existing systemic medication³. In this scenario, photobiomodulation (PBM) has emerged as a possibility due to its capacity to modulate the inflammatory process^{8,9,10}.

Thus, the objective of this study was to evaluate the effect of photobiomodulation (PBM) on spontaneous pain after endodontic treatment in distinct teeth performed in a single visit for the same patient.

Case Report

This study was approved by the Ethics Committee of Nove de Julho University (process: 5.495.496) and followed the CARE (Case Report Guidelines) checklist.

Patient K.M.C., male, 31 years old, without comorbidities, non-smoker, and non-drinker, sought treatment at the Dental Clinic of Nove de Julho University with significant spontaneous pain and no relief from medication in teeth 1.6 and 1.7. Clinical examination revealed two deep carious lesions, approaching the pulp chamber (Figure 1). Radiographically, both teeth showed no periapical lesions. In the thermal test, both exhibited exacerbated pain to cold and heat. With the diagnosis of irreversible pulpitis established, the patient was referred from the undergraduate program to the Master's program at Nove de Julho University, São Paulo, Brazil. Endodontic treatments were performed on both teeth. Photobiomodulation was randomized as an analgesic alternative for postoperative pain in one of the teeth.

Figure 1. Initial Radiograph



Clinical Features

The patient attended two separate dates for procedures, one for the treatment of tooth 1.6 and another for endodontic treatment of tooth 1.7. After the procedure appointments, the patient returned within 24 hours for clinical reassessment and delivery of completed pain assessment forms.

Before the start of each appointment, a baseline assessment was conducted, consisting of thermal testing, spontaneous pain index, pain upon vestibular and palatal palpation, and vertical and horizontal percussion pain. Both teeth in question exhibited positive thermal testing before endodontic treatment.

Both teeth were treated identically with the gold standard for the condition, starting with one cartridge of 2% mepivacaine (20 mg/mL) in combination with 1:100.000 epinephrine (0.01 mg/mL) (DFL®, Rio de Janeiro, Brazil). Following anesthesia, absolute isolation was achieved using a rubber dam (Angelus®, Londrina, Brazil) and gingival barrier (Top Dam® FGM Dental, FGM®, Joinville, Brazil) for optimal sealing. The involved clinical dental crown was disinfected with 2% chlorhexidine (Fórmula e Ação®, São Paulo, Brazil), and coronal access was performed.

The endodontic treatment proceeded with the following steps: Preparation of the coronal part of the root canal was performed using rotary Pre-Race files (FKG Dentaire®, La Chaux-de-Fonds, Switzerland) 35.08 at 600 rpm and torque of 3N with VDW Silver motor (VDW®, Munich, Germany); followed by instrumentation of the middle thirds using rotary instruments of taper 10.02, 15.02 and 20.02 (FKG Dentaire®, La Chaux-de-Fonds, Switzerland) for patency.

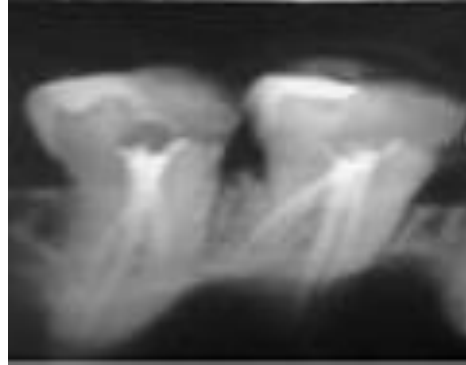
An apical locator APX1 (GNATUS®, Ribeirão Preto, Brazil) was used to determine the tooth length, with 1 mm subtracted for working length determination. Canal reshaping was conducted using reciprocating WaveOne Gold (DENTSPLY®, York, Pennsylvania, USA) with sizes 20.07 and 25.07, supplemented with 35.06 (as needed) on the VDW Silver motor (VDW®, Munich, Germany) set to the established WaveOne function. After each file change, abundant irrigation with Endo-Eze 1" Irrigator tips (Ultradent Products, Inc.®, South Jordan, Utah, USA) 2.5% sodium hypochlorite (Asfer®, São Paulo, Brazil) was performed. The total volume of irrigation through the instrumentation was standardized to 50 ml of 2,5% sodium hypochlorite.

After completion of chemical-mechanical canal preparation and shaping, the final irrigation protocol using EasyClean (Bassi®, Belo Horizonte, MG, Brazil) with rotation between 10,000 to 15,000 r.p.m. in 3 agitation cycles of 20 seconds each with 2.5% sodium hypochlorite, followed by 3 agitation cycles of 20 seconds each with 17% EDTA (Fórmula e Ação®, São Paulo, Brazil), and final irrigation with 2.5% sodium hypochlorite (Asfer®, São Paulo, Brazil)

The canals were dried using Capillary tips (Ultradent Products, Inc.®, South Jordan, Utah, USA) for suction, followed by sterile absorbent paper points (DENTSPLY®, York, Pennsylvania, USA). Obturation using the single cone technique matched to the final file size (DENTSPLY®, York, Pennsylvania, USA) used for root filling. A traditional lateral condensation technique with digital spreaders (DENTSPLY®, York, Pennsylvania, USA) was necessary until the canal filling was complete. The obturation stage was followed by restoration of the coronal portion using glass ionomer restorative (3M ESPE®, St. Paul, Minnesota, USA).

The elements' occlusion was thoroughly assessed and adjusted as necessary, preventing premature contact (Figure 2).

Figure 2. Final Radiograph



Photobiomodulation

It was observed that the majority of studies used a wavelength of 880nm^{11,12,13,14,15}. Therefore, we adapted the protocol, detailed in Fig 3¹³. To eliminate possible placebo effects, the patient remained unaware of the procedures, using the website <https://www.sealedenvelope.com> to determine which tooth would be treated with laser. Tooth 1.6 was the first tooth to be treated and underwent a photobiomodulation simulation, while tooth 1.7 received actual photobiomodulation treatment.

After the obturation and sealing of the cavity, the rubber dam was removed, and both the patient and the operator were equipped with protective glasses. For tooth 1.6, photobiomodulation simulation was applied using recorded sounds from the device. Meanwhile, for tooth 1.7, the protocol was applied with an 808nm laser at 3 points at the apical area, each point for 30 seconds, using the MMOptics device, totaling 90 seconds and 9J of total energy delivered as described in Fig 3(Dosimetric parameters)

Fig 3: Dosimetric Parameters



Parameters	Values
Wavelength [nm]	880
Operating Mode	Continuous
Power [mW]	100
Irradiance [mW/cm ²]	333,3
Output Area [cm ²]	0,3
Exposure time [s] per point	30
Radiant Exposure [J/cm ²] per point	10
Energy [J] per point	3
Total Energy [J]	9
Number of radiated points	3
Application	Contact
Application site	Apex Radicular
Number of sessions	Single

nm - nanometers, mW - milliwatts, W/cm² - watts per square centimeter, s - seconds, J/cm² - Joules per square centimeter

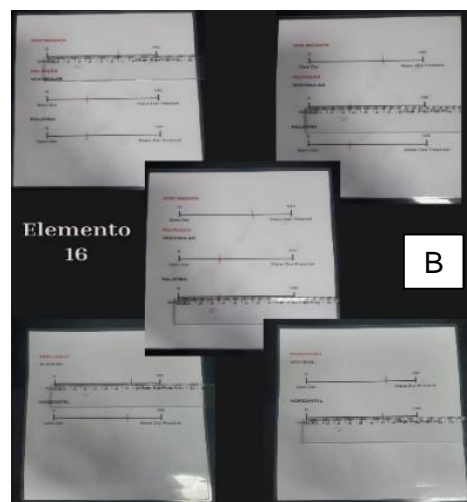

Pain assessment

The pain was measured using the visual analog scale (VAS), consisting of a 10 cm line, from 0 (no pain) to 10 (worst possible pain). The patient was instructed to mark a vertical line at the point that best corresponded to the intensity of pain at each moment: immediately before treatment (baseline) and at intervals of 4h, 8h, 12h, and 24h after treatment (Figure 4A).

Similarly, pain upon palpation (vestibular and palatal) and percussion (vertical and horizontal) were measured in both teeth immediately before treatment (baseline) and 24 hours after treatment (Figure 4B).

The amount of analgesic required was also analyzed by the patient's markings on the provided form if needed.

Figures 4 (A&B): Visual analog scale for assessment of intensity of pain



Results

All levels of pain (spontaneous, palpation, and percussion) in both teeth (PBM and Control) were increased compared to baseline. Regarding spontaneous pain, the patient reported reduced postoperative pain by more than 50% in tooth 1.7, which received endodontic treatment followed by photobiomodulation at all measured time intervals: 4, 8, 12, and 24 hours. (Table 1)

Table 1. Pains measured at time intervals of 4, 8, 12, and 24 hours

	TOOTH 1.6 (PBM sham)	TOOTH 1.7 (PBM)
Baseline	0 cm	0 cm
4 HOURS	3,5 cm	0 cm
8 HOURS	3,5 cm	1,4 cm
12 HOURS	5,8 cm	1,3 cm
24 HOURS	6,5 cm	3,1 cm

PBM-photobiomodulation

In the case of percussion, it was observed that tooth 1.7 (PBM) exhibited approximately a 29% reduction in pain on vertical percussion and over a 50% reduction in pain on horizontal percussion when compared to tooth 1.6 (Control). (Table 2)

Table 2. Percussion Pain compared between Tooth 1.6 (PBM Sham) and Tooth 1.7 (PBM)

	TOOTH 1.6 (PBM sham)		TOOTH 1.7 (PBM)	
	Vertical	Horizontal	Vertical	Horizontal
Baseline	0 cm	2,5 cm	0 cm	1,2 cm
24Hours	7,3 cm	6,9 cm	5,2 cm	3,1 cm

PBM-photobiomodulation; cmVAS (0-10)

Similarly, in palpation, both teeth showed an increase in pain intensity in both vestibular and palatal palpation 24 hours after the procedure. However, tooth 1.7 (PBM) exhibited a 36% increase in the palatal palpation index compared to tooth 1.6 (Control) and similar indices to the control in vestibular palpation. (Table 3)

Table 3. Palpation Pain compared between Tooth 1.6 (PBM Sham) and Tooth 1.7 (PBM)

	TOOTH 1.6 (PBM sham)		TOOTH 1.7 (PBM)	
	Vestibular	Palatal	Vestibular	Palatal

Baseline	0 cm	0 cm	0 cm	0 cm
24Hours	3,5 cm	3,5 cm	3,9 cm	4,9 cm

PBM-photobiomodulation; cmVAS (0-10)

In both treatments, the patient reported not needing to use the analgesic medication (Paracetamol 750mg) provided and instructed in case of maximum pain (level 10 on the Visual Analog Scale).

Discussion

This case report is unique as it involves a single individual with pulp involvement in teeth located within the same hemiarch, thereby minimizing the challenges of measuring and comparing postoperative pain across multiple distinct individuals.

The findings revealed an increase in all pain parameters (spontaneous pain and pain provoked by palpation or percussion) in both teeth when compared to baseline. These results suggest that single-session endodontic treatment may lead to elevated postoperative pain scores.^{1,5}

After treatment, only one session of photobiomodulation was applied (total time of 90 seconds), as also described by other authors^{11,12,15,16,13,17} with good results. A study on acute pain showed that a single session of photobiomodulation (lasting 30 to 60 seconds) is sufficient to cause analgesia³¹, however, not all semiotic tests were performed.

In terms of spontaneous pain, different indices were observed between the dental elements. Tooth 1.7 (PBM) showed a reduction of over 50% in all analyzed periods (4h, 8h, 12h, and 24h) compared to post-treatment of tooth 1.6 (control), reaching zero pain level within the first 4 hours.

Such reduction is found in several studies in the literature and appears to be directly associated with the modulation effect of the inflammatory process by PBM^{10,19}, reducing post-endodontic instrumentation pain^{16,33,26}, as demonstrated in Lopes, et al., 2018; Naseri, et al., 2020; Yildiz, E.D. et al., 2018; and Ismail et al., 2019. In Nabi et al., 2018, the laser group did not have a significant result compared to the group that ingested Ibuprofen 400mg associated with laser, but still had a significant reduction compared to the control group. Fazlyab et al., 2021 found positive results precisely at the 4 hours, as in this case report, but did not find statistical differences in the other analyzed periods.

Evidence has shown that elevated levels of inflammatory mediators induced in periapical tissue damage activate peripheral nociceptors causing pain. It has been observed that chemical, mechanical, or microbial lesions in the pulp and periapical tissues lead to increased expression of neuropeptides from C-type nerve cells present in the periodontal ligament, contributing to the pathophysiology of peripheral inflammation^{4,8,16,20}. Light at the infrared wavelength (880nm) has neural action specifically on A δ and C fibers, allowing it to be used for acute pain relief²⁰.

When percussion pain was analyzed, tooth 1.7 showed better scores compared to the control, with a reduction of over 50% in horizontal percussion and approximately 29% in vertical percussion. This result once again suggests the inflammatory modulation of photobiomodulation, especially when used at 880nm, which, due to its better penetration (up to 5mm) and reach of periapical cells, even considering light dispersion by tissue chromophores, promotes the effects of

photobiomodulation in the region, making it eligible to affect periapical tissues^{18,13,20,14}. However, some authors did not find statistical differences in percussion maneuver between the laser and control groups post-treatment^{11,9,17,15}.

In the semiotic maneuver of palpation, the results obtained are controversial. Besides the similar pain indices for vestibular palpation, the pain index for palatal palpation was found to be 36% higher for tooth 1.7 (PBM) compared to the control. Anatomical difficulties and the more posterior position of tooth 1.7 in relation to tooth 16 may have contributed to this result, as additional anesthesia was needed at the site. Only Yildiz et al., 2018 analyzed this outcome; however, they did not find a statistical difference between the groups.

Few clinical studies analyze pain more extensively, incorporating semiotic maneuvers such as palpation and percussion. Evaluations typically focus on spontaneous pain, and more robust studies utilizing these complementary assessment parameters are needed.

In addition to these analyses, evaluating the amount of oral analgesic medication required has been mentioned to assess PBM as an alternative for patients with medication restrictions^{19,17,14,15}. In the treatment of both dental elements in this study, the patient reported not reaching the maximum pain level, thus not requiring the use of the provided analgesic medication (Paracetamol 750mg), following the findings^{15,17}.

Some authors have found statistical differences, with the laser group showing a lower amount of medication use^{14,19}. Perhaps in a study with a larger sample size, this difference could be achieved.

Finally, the limitations of this case report lie in the subjective nature of pain assessment⁶, preoperative conditions such as increased patient anxiety, anatomical difficulties (intra-radicular and positioning of the elements in the arch), and the fact that it represents only one patient. However, it suggests evidence that the association of photobiomodulation after endodontic treatment may be used as an alternative in cases of post-instrumentation pain for maxillary molars treated in a single session, especially in the parameter of spontaneous pain.

Conclusion:

PBM may be an analgesic alternative for post-endodontic instrumentation spontaneous pain reducing local inflammation.

Disclaimer for Thesis/ preprint /repository

This paper is an extended version of a [preprint](#) document of the same author.

The [preprint](#) document is available in this link:

https://d197for5662m48.cloudfront.net/documents/publicationstatus/208950/preprint_pdf/55bf42ce559f9020db0dd92efaa01033.pdf

[As per journal policy, preprint /repository article can be published as a journal article, provided it is not published in any other journal]

Disclaimer (Artificial intelligence)

Author(s) hereby declare that NO generative AI technologies such as Large Language Models (ChatGPT, COPILOT, etc.) and text-to-image generators have been used during the writing or editing of this manuscript.

Ethical Approval:

This case report received approval from the Research Ethics Committee of Universidade Nove de Julho (UNINOVE), process: 5.598.425

Consent: The participants signed an Informed consent.

References

1. Siqueira JF Jr, Rôças IN. Present status and future directions: Microbiology of endodontic infections. *Int Endod J*. 2021 Dec 27. doi: 10.1111/iej.13677. Epub ahead of print. PMID: 34958494
2. Tiburcio-Machado, C.S., Michelon, C., Zanatta, F.B., Gomes, M.S., Marin, J.A. & Bier, C.A. (2021) The global prevalence of apical periodontitis: a systematic review and meta-analysis. *International Endodontic Journal*, 54, 712–735.
3. Guerreiro MYR, Monteiro LPB, Castro RF, Magno MG, Maia LC, Brandão JMS. Effect of low-level laser therapy on postoperative endodontic pain: an updated systematic review. *Complemento Ther Med* 2021;57:1-9.
4. Mekhdieva E, Del Fabbro M, Alovisei M, Comba A, Scotti N, Tumedei M et al. Postoperative pain following root canal filling with bioceramic vs. traditional filling techniques: a systematic review and meta-analysis of randomized controlled trials. *J Clin Med*. 2021;10(19):4509.
5. Manfredi M, Figini L, Gagliani M, Lodi G. Single versus multiple visits for endodontic treatment of permanent teeth. *Cochrane Database Syst Rev*. 2016 Dec 1;12(12): CD005296. doi: 10.1002/14651858.CD005296.pub3. Update in: *Cochrane Database Syst Rev*. 2022 Dec 13;12:CD005296. PMID: 27905673; PMCID: PMC6463951.
6. Martinez, José Eduardo, Grassi, Daphine Centola and Marques, Laura Gasbarro Analysis of the applicability of three pain assessment instruments in different care units: outpatient clinic, ward and emergency room. *Brazilian Journal of Rheumatology*. 2011, v. 51, n. 4, pp. 304-308. Available at: <>. Epub 11 Jul 2011. ISSN 1809-4570.
7. Leonardo, Mário R.; LEONARDO, Renato de T. Root Canal Treatment. chap.2, p.5-22; Group A, 2017 9788536702650. Available at: <https://integrada.minhabiblioteca.com.br/#/books/9788536702650/>. Accessed on: Apr 22, 2022.
8. Ahangar FA, Samoon A, Purra AR, Farooq R. Efficacy of nano-pulsed magneto infrared laser therapy with a fixed dose combination tablet of oral ibuprofen and paracetamol on the reduction of postendodontic pain: a clinical study. *Int J Contemp Med Res* 2017;4:1782-87.
9. Arslan H, Güven Y, Karataş E, Doğanay E. Effect of the simultaneous working length control during root canal preparation on postoperative pain. *J Endod*. 2017;43(9):1422-7.
10. Keskin C, Özdemir Ö, Uzun İ, Güler B. Effect of intracanal cryotherapy on pain after single-visit root canal treatment. *Aust Endod J*. 2017;43(2):83-8.
11. Arslan H, Doğanay E, Karataş E, Ünlü MA, Ahmed HMA. Effect of low-level laser therapy on postoperative pain after root canal retreatment: a preliminary placebo-controlled triple-blind, randomized clinical trial. *J Endod*. 2017;43(11):1765-9.
12. Asnaashari M, Mohebi S, Paymanpour P. Pain reduction using low-level laser irradiation in single-visit endodontic treatment. *J Lasers Med Sci*. 2011;2(4):139-43.
13. Lopes LPB, Herkrath FJ, Vianna ECB, Gualberto EC, Júnior, Marques AAF, Sponchiado Jr EC. Effect of photobiomodulation therapy on postoperative pain after endodontic treatment: a randomized, controlled, clinical study. *Clin Oral Investig*. 2019;23(1):285-92.
14. Naseri M, Asnaashari M, Moghaddas E, Vatankhah MR. Effect of low-level laser therapy with different locations of irradiation on postoperative endodontic pain in patients with

- symptomatic irreversible pulpitis: a double-blind randomized controlled trial. *J Lasers Med Sci*. 2020;11(3): 249-54.
15. Yıldız ED, Arslan H. Effect of low-level laser therapy on postoperative pain in molars with symptomatic apical periodontitis: a randomized placebo-controlled clinical trial. *Randomized Controlled Trial J Endod*. 2018;44(11):1610-5.
 16. Nabi S, Amin K, Masoodi A, Farooq R, Purra AR, Ahangar FA. Effect of preoperative ibuprofen in controlling postendodontic pain with and without low-level laser therapy in single visit endodontics: A randomized clinical study. *Indian J Dent Res* 2018;29:46-50
 17. Fazlyab, M. , Esmaeili Shahmirzadi, S. , Esnaashari, E. , Azizi, A. and Moshari, A. A. (2021) Effect of low-level laser therapy on postoperative pain after single-visit root canal retreatment of mandibular molars: a randomized controlled clinical trial . *International Journal of Endodontics* , 54 , 2006–2015 . <https://doi.org/10.1111/iej.13608>
 18. De Freitas L, Hamblin MR. Proposed mechanisms of photobiomodulation or low-level light therapy. *IEEE J Selected Topics Quantum Elect* 2016;22(3):1-9.
 19. Endo, Marcos Sergio et al. Single-visit or multiple-visit endodontics: a literature review. *RFO UPF* [online]. 2015, vol.20, n.3, pp. 408-413. ISSN 1413-4012.
 20. Chow R, Armati P, Laakso EL, Bjordal JM, Baxter GD (2011) Inhibitory effects of laser irradiation on peripheral mammalian nerves and relevance to analgesic effects: systematic review. *Photomed Laser Surg* 29:365–381. <https://doi.org/10.1089/pho.2010.2928>