

Ectopic Sweating Treated with Botulinum Toxin After Vapocoolant Spray

Abstract

Hyperhidrosis is most often characterized by excessive sweating of the axillae, palms, soles, and craniofacial area. BTX-A injections for the treatment of hyperhidrosis have shown good results in the afflicted areas. However, few studies have reported on the effects of the use of BTX-A injections using vapocoolant spray combined vibration techniques in the facial area, perianal and groin area, or scrotum. BTX-A 0.8 units/0.1 mL and 2 units/0.1 mL were injected in these region, respectively, using a 33G needle. As a result, sweating was significantly reduced in all patients. Side effects observed with this treatment modality consisted of local bleeding and tolerable to mild pain during injection.

Key Words: Sweating; Botulinum toxin; Vapocoolant; Vibration

Introduction

Hyperhidrosis is a condition that causes excessive sweating due to an overstimulation of the sympathetic nervous system, which can lead to severe disruption of daily activities due to loss of self-esteem, social isolation, and mental frustration, resulting in a diminished quality of life. (1) Globally, this disease has a morbidity of 3-5% in most countries and is passed down through the generations as a genetic tendency. (2, 3)

Despite a variety of therapeutic management approaches, patients continue to complain of excessive sweating. Nevertheless, because hyperhidrosis is not a progressive condition that gets progressively worse, it is often not recognized as a disease and is frequently ignored. In addition, hyperhidrosis is often under-recognized by the medical community because it is rarely malignant, life-threatening, or progressive. As a result, it is perhaps not taken as seriously as it should be, including by the patients themselves, who often do not seek medical care in time.

Hyperhidrosis is most often characterized by excessive sweating of the axillae, palms, soles, and craniofacial area. (3, 4) However, cases of sweating occurring in unusual places after sympathetic nerve surgery have been reported, as well as without surgery. In these cases, although antiperspirants or oral medications can be used, the patients often experience side effects coupled with a poor effectiveness. In this context, botulinum toxin type A (BTX-A) injections represent an alternative treatment that can be used as an effective long-term solution.

BTX-A injections for the treatment of hyperhidrosis have shown good results in the afflicted areas. However, few studies have reported on the effects of the use of BTX-A injections using vapocoolant spray combined vibration techniques in the facial area, perianal and groin area, or scrotum. (5)

Great difficulty, pain, and inconvenience are associated with the administration of BTX-A injections using conventional syringe techniques resulting from limitations imposed on local anesthetics, nerve blocks, and needle-free techniques. Vapocoolant spray (Pain Freezer[®]; BisonMedical, Seoul, Korea), whose main ingredients are HFC-245fa and HFC-134a, in combination with a T-shaped vibration device (24 K gold Massage[®]; Boluoyin, China) represents an alternative for the treatment of ectopic hyperhidrosis. A vapocoolant spray combined vibration can not only relieve pain in adults undergoing cosmetic procedures, but also does not cause serious side effects. (6,7) Topical anesthetic cream (EMLA[®]; AstraZeneca, Sweden) is another tool for pain relief, but one that has limitations, including the amount of time taken to produce a sufficient effect, a high cost, and the potential to cause allergic contact dermatitis. In this context, vapocoolant spray combined vibration appears to represent a better anesthetic technique as a non-invasive, inexpensive, and widely available treatment modality that rapidly anesthetizes the patient's skin.

Facial sweating, a form of craniofacial hyperhidrosis, affects the entire face, especially frontalis, nose, and upper lip, characterized by a flow of excess sweat down the face, although sweating on the paranasal area and upper lip is rare. (Fig. 1) Facial sweating has undesirable consequences and a detrimental effect on quality of life, particularly in the summer months. Topical glycopyrrolate, oral medications, and intradermal BTX-A are considered conservative treatments due to their efficacy and safety. BTX-A injections play an important role in the management of sweating in women for cosmetic reasons. Sympathectomy is considered the last option in craniofacial hyperhidrosis with a high risk of compensatory hyperhidrosis (Ch) and for those whose conditions are intractable to conventional therapy. Although intradermal injections of BTX-A, which is an effective, safe, and long-term treatment for focal hyperhidrosis, have been known to eliminate sweating, the

administration of a series of injections through the skin without regional block anesthesia or a conventional syringe injection, even when using a 33-gauge needle, can be painful and cause discomfort. Therefore, vapocoolant spray with vibration represents a great alternative way for the convenient delivery of series of injections.

A rare form of focal ectopic hyperhidrosis manifests in the pelvic region, including the buttocks, perianal area, groin, and scrotum, for which data on its prevalence and etiology are not widely available. Ch affecting in this region is recognized as the most and common side effect of endoscopic thoracic sympathectomy. This condition may occur alone without having history of sympathectomy. Excessive sweating around this region can cause serious stress with discomfort, eczema, and bad odor. Patients report disruption to their day to day lives, having to change out of sweat-soaked clothing two to three times per day in the summer months.

Ch is difficult to treat and lacks an efficient and readily available treatment modality. BTX-A can be safely and effectively used to treat Ch, and may play a significant role in its treatment as a second-line agent. (8) Although BTX-A injection is already an established treatment modality for hyperhidrosis, reports on its use for the treatment of Ch are scarce. Patients who reported acceptable minimal pain following BTX-A injections after vapocoolant combined with vibration were satisfied with treatment, and demonstrated improvements in social performance thanks to a reduction in sweating that persisted for up to 4-6 months (Fig. 2).

After the combination of alcohol swabbing and vapocoolant spray with vibration, BTX-A 0.8 units/0.1 mL and 2 units/0.1 mL were injected in the face and pelvic region, respectively, using a 33G needle. Wheals formed at 1-1.5 cm intervals across the entire target focal surface. BTX-A was then injected into the face, buttocks, perianal area, groin, and scrotum in a similar way. Antibiotic ointment was applied after the injections. Sweating was significantly

reduced in all patients. Side effects observed with this treatment modality consisted of local bleeding and tolerable to mild pain during injection.

Conclusion

In conclusion, the administration of BTX-A with vapocoolant and vibration represents a simple, safe, and effective treatment for localized ectopic hyperhidrosis.

Consent

All photos published here were taken with the patient's consent.

Ethical Approval:

As per international standards or university standards written ethical approval has been collected and preserved by the author(s).

Disclaimer (Artificial intelligence)

Option 1:

Author(s) hereby declare that NO generative AI technologies such as Large Language Models (ChatGPT, COPILOT, etc) and text-to-image generators have been used during writing or editing of manuscripts.

Option 2:

Author(s) hereby declare that generative AI technologies such as Large Language Models, etc have been used during writing or editing of manuscripts. This explanation will include the name, version, model, and source of the generative AI technology and as well as all input prompts provided to the generative AI technology

Details of the AI usage are given below:

1. **None**

2.

3.

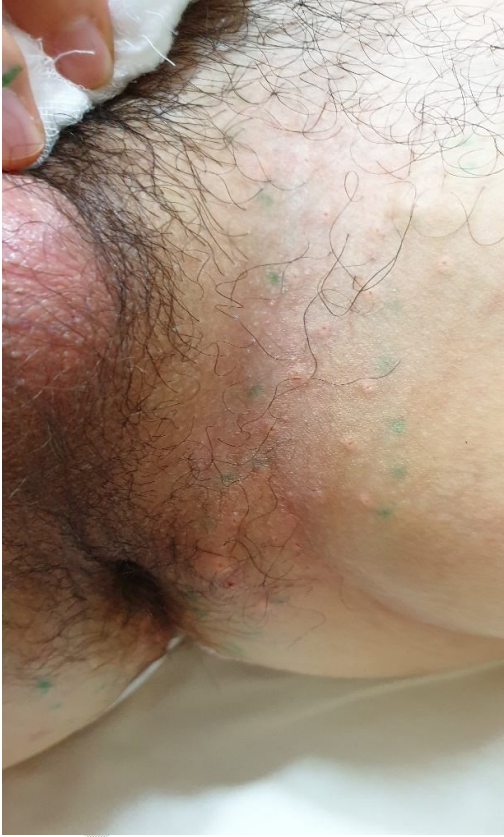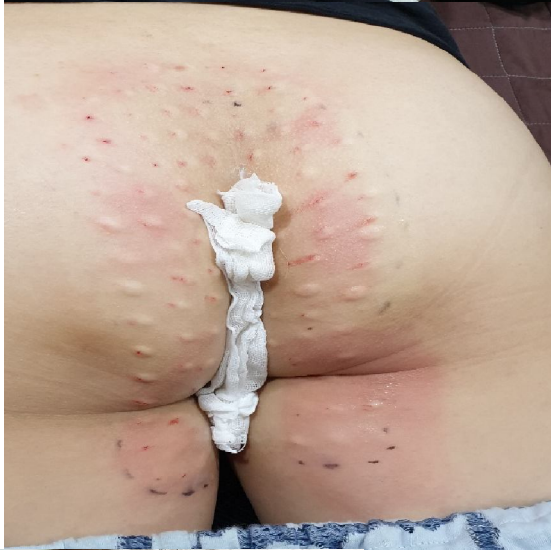References

1. Parashar K, Adlam T, Potts G. The impact of hyperhidrosis on quality of life: A review of the literature. *Am J Clin Dermatol.* 2023;24:187-198.
 2. Kjeldstrup Kristensen J, Grejsen D, Swartling C, Bygum A. In hyperhidrosis quality of life is even worse than in acne, eczema, or psoriasis. A comparison of Skindex-16 and Dermatology Life Quality Index (DLQI). *Int J Dermatol.* 2020;59:e392-e393.
 3. Henning MAS, Bouazzi D, Jemec GBE. Treatment of hyperhidrosis: An update. *Am J Clin Dermatol.* 2022;23:635-646.
 4. Nawrocki S, Cha J. The etiology, diagnosis, and management of hyperhidrosis: A comprehensive review: Etiology and clinical work-up. *J Am Acad Dermatol.* 2019;81:657-666.
 5. Kim WO. Treatment of focal hyperhidrosis with needleless injections of botulinum toxin into sites other than the axilla, palm, and sole. *Dermatol Surg.* 2017;43 Suppl 3:S367-S369.
 6. Zeiderman MR, Kelishadi SS, Tutela JP, Rao A, Chowdhry S, Brooks RM, Wilhelmi BJ. Vapocoolant anesthesia for cosmetic facial rejuvenation injections: A randomized, prospective, split-face trial. *Eplasty.* 2018 Feb 7;18:e6. eCollection 2018.
 7. Eichhorn MG, Karadsheh MJ, Krebiehl JR, Ford DM, Ford RD. Vibration for pain reduction in a plastic surgery clinic. *Plast Surg Nurs.* 2016;36:63-8.
 8. Kim WO, Kil HK, Yoon KB, Noh KU. Botulinum toxin: a treatment for compensatory hyperhidrosis in the trunk. *Dermatol Surg.* 2009;35:833-8.
-




Figure 1. Multiple injections of botulinum toxin-A after vapocoolant combined with vibration to the face can relieve severe and profuse sweating.

UNDER PEER REVIEW



PEER REVIEW

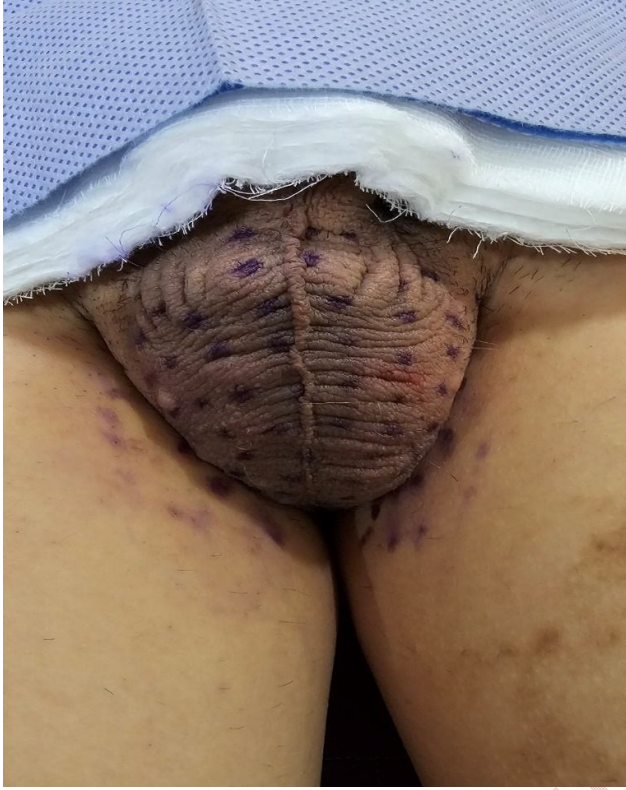


Figure 2. Focal injection of botulinum toxin-A after vapocoolant spray combined with vibration to the buttock, perianal, groin, and scrotum.