

A Giant Intra-Abdominal Small Intestinal desmoid tumor – A rare case report

Abstract

Desmoid tumors, also known as aggressive fibromatosis, are benign neoplasms originating from mesenchymal cells or fibroblasts. Despite their benign nature, these tumors are locally aggressive and do not metastasize distantly. They account for less than 3% of all soft tissue tumors and have an incidence of approximately 0.03% among all neoplasms.

Primary desmoid tumors of the small intestinal wall are particularly rare, with the most common site of origin being the mesentery, retroperitoneum, or small bowel wall. While extra-abdominal desmoid tumors occur in about 60% of cases, with 25% arising from the anterior abdominal wall and 15% being intra-abdominal, those originating from the small bowel are exceedingly uncommon. Such tumors often present as an abdominal mass. For preoperative diagnosis and surgical planning, abdominal CT and MRI are the preferred imaging modalities. Surgical resection with negative margins remains the cornerstone of effective treatment.

In this report, we present a rare case of a giant intra-abdominal desmoid tumor arising from the small intestine in a 45-year-old female. The diagnosis was confirmed via CT, and the patient is scheduled for open surgical resection.

Key words

Desmoid tumor, Familial adenomatosis polyposis, Gardner syndrome, Small intestine

Introduction

Desmoid tumors can be classified as extra-abdominal, abdominal wall, or intra-abdominal. Intra-abdominal desmoid tumors most commonly originate from the mesentery, retroperitoneum, and small bowel. About 80% of these tumors arise from the mesentery, while 10-20% originate from the small intestinal wall. [2,3,5]

Histologically, desmoid tumors are characterized by spindle cells and fibroblasts within a collagenous stroma. Several risk factors have been associated with their development, including female gender, pregnancy, estrogen exposure, and prior trauma or surgery. Approximately 30% of sporadic desmoid tumors are preceded by abdominal trauma, motor vehicle accidents, or caesarean sections. Additionally, there is a frequent association with familial adenomatous polyposis (FAP) and Gardner's syndrome in 10-15% of cases. [1,2]

Although desmoid tumors do not metastasize, they can cause significant morbidity and mortality due to local invasion. They have a local recurrence rate of 20-40%. Genetic mutations, particularly in the adenomatous polyposis coli (APC) gene or beta-catenin genes, are implicated in 10-15% of cases. Estrogen is believed to play a role in the development and

growth of desmoid tumors, as they are more common in multiparous women and those exposed to oral contraceptives. [2,3,6,8]

For evaluation and surgical planning of intra-abdominal desmoid tumors, CT and MRI are utilized. The primary treatment is complete surgical resection with negative margins, followed by careful monitoring due to the high recurrence rate. Post-surgery, CT and MRI are also used to detect recurrence and assess the tumors response to radiation and systemic therapy. [1,4,8]

Case Report

A 45 years old female, was admitted to our centre on 10-01-2020, with complains of abdominal lump, abdominal distension and pain in abdomen for 1 years. On physical examination, her abdomen was soft, with a large palpable intra-abdominal mass measuring 20x15x10 cm, located centrally in the umbilical region. Palpable mass was firm and non-tender and no signing of small intestinal obstruction. CT abdomen and pelvis revealed a large solid mass originating from the small intestine in the mid abdomen, measuring 20x15x10 cm in size with smooth margins, and heterogenous in nature. There were no features in intestinal obstruction on CT scan.

Her all laboratory investigation was normal and patient was planned to and explorative laparotomy and mass resection. The operation was carried out through a standard midline laparotomy. The large mass appeared to originate from the small bowel and it was freely mobile, no adhesions to the surrounding abdominal structures. The large tumor mass was resected with 5 cm proximal and distal ileal margin with ileo-ileal anastomosis. The patient tolerated the procedure well. The cut section revealed a glistening white surface with fascicular appearance.

On gross the specimen of 20x15x10 cm in size, lobulated with smooth surface and weighing 7 kg (15 pounds). Final pathology revealed a desmoid tumor originating from the small bowel with negative margin.

The patients post-operative course was uncomplicated and she is healthy after follow up 4 years after surgery, there was no evidence of disease recurrence and this case highlights a rare, treatable disease without radiation and chemotherapy. [Fig 1-10]

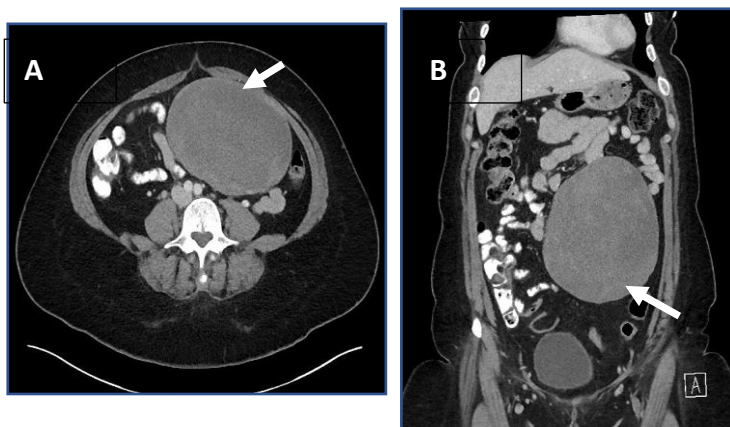


Fig-1 CT Abdomen A. Axial & B Sagittal showing a large intra-abdominal mass of size 25x15x10 cm (white arrows)

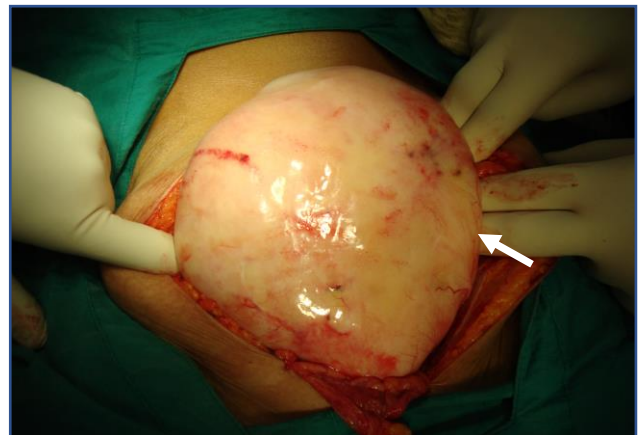

Fig-2 Intraoperative photograph showing an intra-abdominal large solid mass

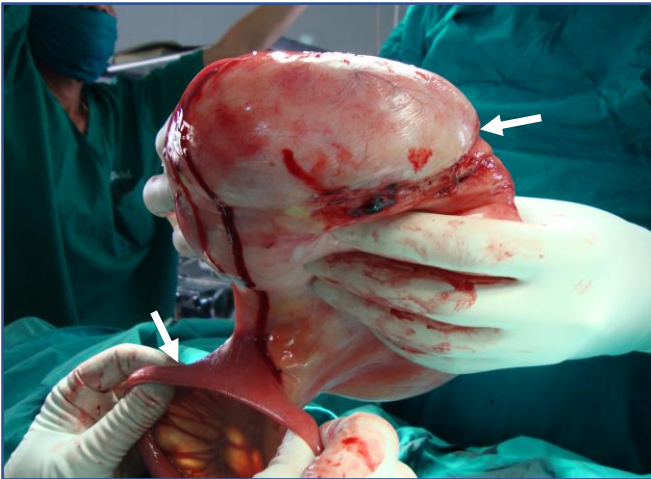


Fig-3 Intraoperative photograph showing an intra-abdominal large solid mass, arising from small bowel

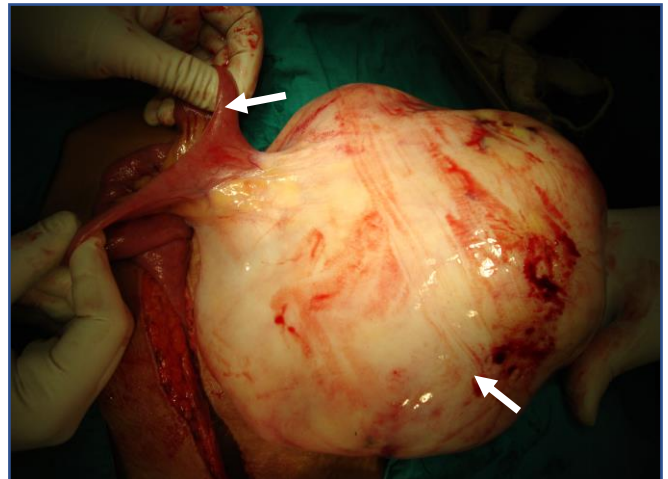


Fig-4 Intraoperative photograph showing a large solid mass, arising from small bowel

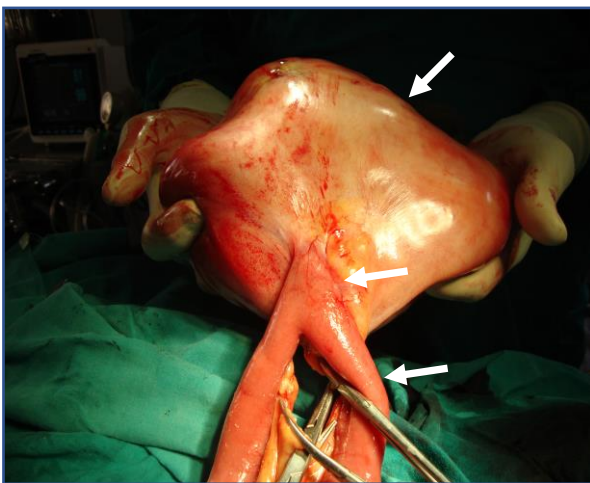


Fig-5 Intraoperative photograph showing a large solid mass, arising from small bowel

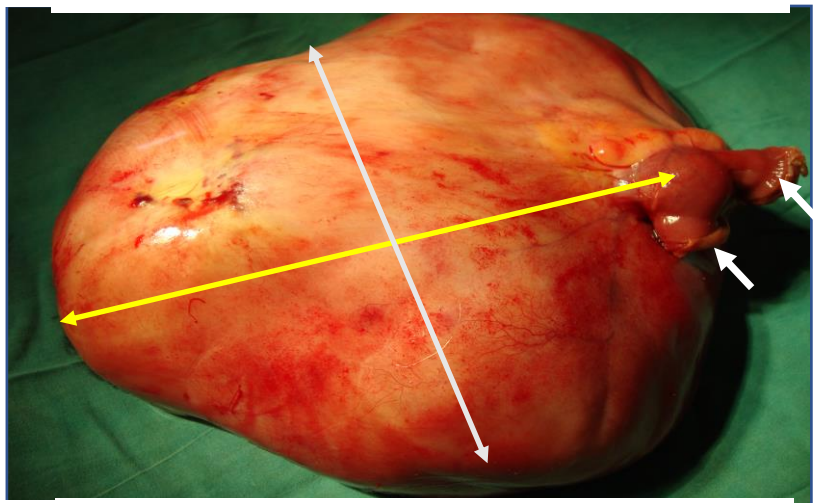


Fig-6 Photograph showing a large solid mass measuring of size 25x15x10 cm, weight 7 kg

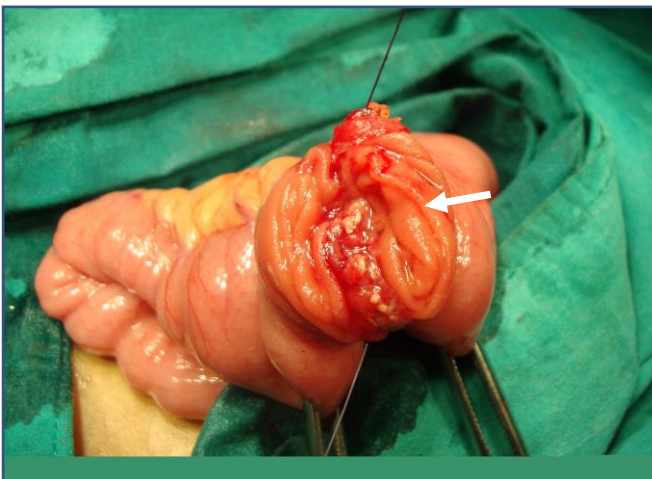


Fig-7 Intraoperative photograph showing ilio-ileal anastomosis

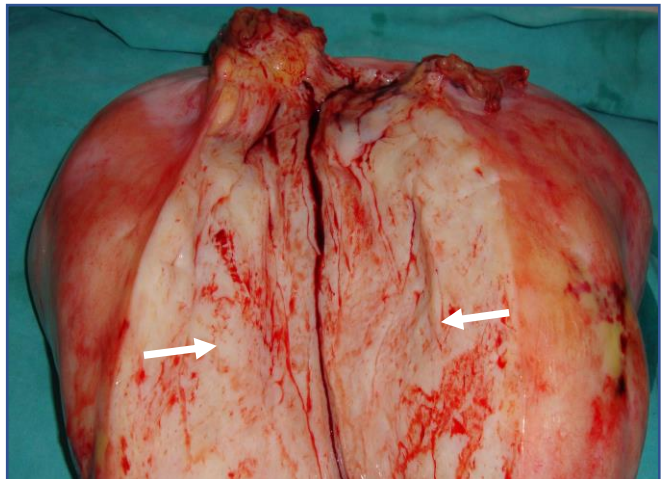


Fig-8 Cut section-revealed a glistening white surface with fascicular appearance

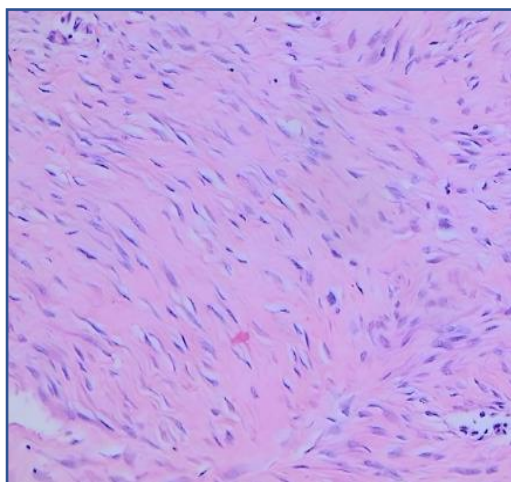


Fig-9 Hematoxylin and eosin staining, showing benign spindle shaped fibroblasts

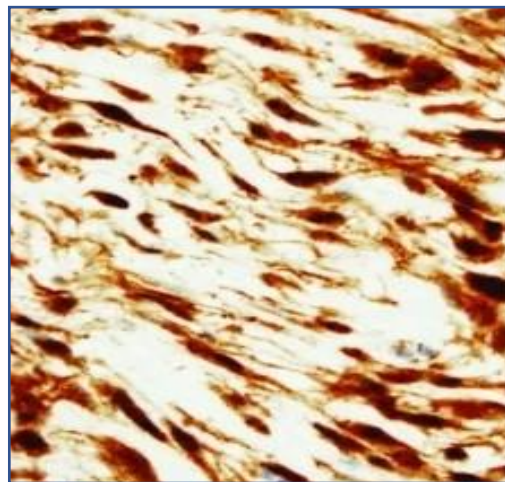


Fig-10 Immunostaining for B-catenin test positive

Discussion and Review

A comprehensive literature search was conducted on PubMed using the terms “Desmoid tumor and small intestine or mesentery or intra-abdominal,” yielding a total of 56 publications from 1980 to 2021. Intestinal obstruction has been described as a potential complication of intra-abdominal desmoid tumors, only 7 prior cases have been reported in the literature

Desmoid tumors have an incidence of 2-4 per million per year, constituting approximately 0.03% of all tumors and 3% of all soft tissue sarcomas. Of these, 8-15% are intra-abdominal, with 80% originating in the mesentery of the small bowel. About 30% of sporadic intra-abdominal desmoid tumors are preceded by abdominal trauma or pelvic surgery. Estrogen activity may play a role in their pathogenesis, contributing to the higher incidence in females (ratio 2:1). Additionally, genetic disorders such as familial adenomatous polyposis (FAP) and Gardner’s syndrome are associated with desmoid tumors in approximately 10-15% of patients. Mutations in the APC gene and CTNNB1 (beta-catenin) gene are implicated, leading to fibroblast proliferation and the development of desmoids or aggressive fibromatosis. [2,3,5]

Primary desmoids of the small bowel are rare and arise from mesenchymal cell lines, while desmoids are the most common primary tumor of the mesentery. There is limited number of reports of primary dermoid tumor originating from small bowel wall or fistulizing to the bowel. intestinal desmoids can causes surgical emergencies if bowel obstruction or perforation occur standardized treatment protocols for small bowel desmoids are not widely available. [1,2,3]

Clinically, desmoid tumors grow slowly, and many patients remain asymptomatic until the tumor is quite large. Symptoms vary based on the size and location of the tumor, with intra-abdominal desmoids presenting as abdominal distension, pain, mass, vomiting, or intestinal obstruction due to mechanical compression. Mesenteric desmoid tumors can cause complications such as bowel obstruction, perforation, bleeding, or, rarely, ureteral compression. Fistulisation to adjacent intestines may occur due to abscess formation[2,4,6]. Because of their slow growth, many desmoid tumors remain asymptomatic until they reach a substantial size. They can be mistaken for other conditions like gastrointestinal stromal tumors (GISTs), solitary fibrous tumors, retroperitoneal fibrosis, or mesenteric lymphoma. [5,8,9]

Evaluating desmoid tumors radiologically is challenging. Ultrasound, CT, MRI, and PET-CT are commonly used diagnostic tools. On ultrasonography, desmoid tumors typically appear as hypoechoic masses with internal homogeneity. On CT, they present as solid masses with homogeneous density and regular margins. MRI may be useful for diagnosing intra-abdominal recurrences. [2,3,]

Histologically, desmoid tumors and GISTs both exhibit spindle-shaped cell proliferation, making differentiation using routine haematoxylin and eosin staining difficult. Immunohistochemical analysis aids in distinction: GISTs are positive for CD117, CD34, DOG1, and PDGFRA, while desmoid tumors are positive for beta-catenin and vimentin. [1,2,4]

Complete surgical resection with negative microscopic margins is the primary treatment, but the local recurrence rate remains high at 20-40%. Radiotherapy may be beneficial in cases where tumors are unresectable, recurrent, or incompletely resected. [2,3]

Medical management options include tamoxifen combined with NSAIDs. Chemotherapy is reserved for aggressive, non-surgical tumors or those unresponsive to other treatments. Alternative approaches include radiotherapy, chemotherapy, methotrexate with vinblastine, and systemic hormone therapy, which yield an objective response in 20-75% of cases. Radiotherapy can control tumor growth in 40-80% of cases. Thus, clinically and radiographic follow up of patients should be performed biannually for at least 3 years and then annually. [2,9,10]

Conclusion

A Giant intra-abdominal desmoid is rare benign tumor that is notorious for benign aggressive and recurrence behaviour. Complete surgical resection with negative pathological margins is the first line management. Radiation and systemic drugs therapy used in cases of recurrence.

References

1. Eswaravaka SK, Deshpande SH, Chiranjeev R, Pandya JS. Intra-abdominal small intestinal desmoid tumour mimicking GIST. *BMJ Case Rep.* 2021 Feb 22;14(2):e237032. doi: 10.1136/bcr-2020-237032. PMID: 33619130; PMCID: PMC7903087.
2. Ebeling PA, Fun T, Beale K, Cromer R, Kempenich JW. Primary Desmoid Tumor of the Small Bowel: A Case Report and Literature Review. *Cureus.* 2019 Jun 17;11(6):e4915. doi: 10.7759/cureus.4915. PMID: 31423391; PMCID: PMC6692092.
3. Michaelides A, Ang A, ChinAleong J, et al Large desmoid tumour of the small bowel mesentery *BMJ Case Reports CP* 2022;15:e247935.
4. Martin D, Labgaa I, Petermann D, Di Mare L. Small bowel obstruction caused by a fast-growing desmoid tumor. *Clin Case Rep.* 2020; 8: 2318–2319. <https://doi.org/10.1002/ccr3.3162>
5. KOTA ARIMA, YOSHIHIRO KOMOHARA, TOMOYUKI UCHIHARA, KOHEI YAMASHITA, SHINICHIRO UEMURA, NORIHISA HANADA and HIDEO BABA *Anticancer Research* January 2022, 42 (1) 381-384; DOI: <https://doi.org/10.21873/anticanres.15496>
6. Faria, Silvana & Iyer, Revathy & Rashid, Asif & Ellis, Lee & Whitman, Gary. (2004). Desmoid Tumor of the Small Bowel and the Mesentery. *AJR. American journal of roentgenology.* 183. 118. 10.2214/ajr.183.1.1830118

7. Jambhekar A, Robinson S, Zafarani P, Rucinski J, Gudavalli P. Intestinal obstruction caused by desmoid tumours: a review of the literature. *JRSM Open*. 2018 May 4;9(5):2054270418763340. doi: 10.1177/2054270418763340. PMID: 29760935; PMCID: PMC5946608.
8. Kai Huang, Heather Stuart, Kirill Lyapichev, Andrew E. Rosenberg, Alan S. Livingstone, Mesenteric desmoid tumour presenting with recurrent abdominal abscess and duodenal fistula: A case report and review of literature, *International Journal of Surgery Case Reports*, <https://doi.org/10.1016/j.ijscr.2017.06.007>.
9. Schiessling S, Kihm M, Ganschow P, Kadmon G, Buchler MW, Kadmon M. Desmoid tumour biology in patients with familial adenomatous polyposis coli. *Br J Surg* 2013;100:694-703.
10. Coskun Polat, Fatma Aktepe, Serkan Turel, Burc Yazicioglu, Taner Ozkececi, Yuksel Arıkan, A Giant Mesenteric Fibromatosis Case Presenting with Mechanical Intestinal Obstruction and Successfully Resected with Partial Duodeno-Jejunectomy and Right Hemicolectomy, *Clinics*, <https://doi.org/10.1590/S1807-59322010000100017>.
11. Das S, Navlani S, Alawa A, et al. (August 04, 2023) Challenging Diagnostic Dilemma: Mesenteric Desmoid Tumor Masquerading as Perforated Peritonitis. *Cureus* 15(8): e42946. doi:10.7759/cureus.42946