

***In vivo* Antifungal Efficacy and Safety of Natural Compounds for Topical Treatment of Cutaneous Candidiasis**

ABSTRACT

In vivo toxicity and antifungal therapeutic evaluation of selected natural compounds for topical applications was analyzed using standard methods. The natural compounds, blue vitriol, brimstone, trona, alum, palm ash and black stone were hygienically selected and purchased at a local market in southeastern Nigeria. The test organisms were isolated from high vaginal swab specimens obtained from cases of cutaneous candidiasis. The isolates were identified based on their morphological, physiological and molecular characteristics. The toxicological screening of the test samples was done using Draize' skin irritancy test, Murine local lymph node assay (LLNA) and necropsy. The *in vivo* evaluation of antifungal activity of the solutions was done using eight-week-old albino rats weighing 120g – 150g. The animals were infected with the *Candida* isolates percutaneously; and treated using various formulations of the natural compounds. The skin sections were carefully observed for histopathological changes, before and after treatment. The total yeast counts of the infected skin tissues were also determined. The isolates include *Candida albicans*, *C. glabrata*, *C. parapsilosis* and *C. tropicalis*. Draize' skin test and Murine local lymph node assay showed no observable skin irritancy reaction ($P > 0.05$). The normal skin architecture of the infected animals was restored after 5 days of treatment with the test samples; while the total yeast count decreased from 10^8 CFU/mL to 10^2 CFU/mL. The findings have revealed that natural compounds are effective as well as non-toxic topically, in treatment of cutaneous candidiasis.

Keywords: *In vivo*, Toxicity, Antifungal, Topical, Histopathological.

1.0 Introduction

Fungal infections otherwise called mycoses, have significantly increased in recent decades, and have been important cause of morbidity and mortality, especially in immunocompromised patients [1]. Fungi can have devastating socio-economic impacts through human disease, crop disease, and food spoilage [2]. Human mycoses can be categorized as superficial, localized, or disseminated. Superficial mycoses are generally confined to the skin and nails, whereas localized mycoses include infections of the gastrointestinal, genitourinary, and respiratory tracts.

Disseminated, or deep, mycoses are characterized by fungal infections of the visceral organs, central nervous system (CNS), and/or generalized fungal septicemia. While the superficial infections can be a source of great discomfort, they are not life-threatening and are generally treatable with a variety of topical (or, in the same cases, oral) antifungal agents [3].

Antifungal drugs are the medications used to treat fungal infections. They may be administered orally, topically, or intravenously. The close relationship between fungal pathogens and human host has been a fundamental challenge towards the development of new antifungal drugs. Consequently, many small molecules that are toxic to yeast are also toxic to humans. As such, it is therefore not surprising that the five major classes of antifungal drugs target structures that are unique to fungi. Although several factors undoubtedly contribute to the estimated 1.5 million deaths due to fungal diseases each year, the relative paucity of antifungal drugs is likely to play a significant role. Five main antifungal classes are used: azoles, echinocandins, polyenes, allylamines and pyrimidine analogues. Moreover, the treatment of mycoses has several limitations, such as undesirable side effects, narrow activity spectrum, a small number of targets and fungal resistance, which are still of major concern in clinical practice [4].

Current antifungal therapies have only modest efficacy with significant toxicities. Newer antifungal formulations have been developed that ideally will reduce the occurrence of adverse effects associated with the original formulations [5; 6]. The discovery of new antifungals is mostly achieved by the screening of natural or synthetic/semi-synthetic chemical compounds [1].

Natural products are increasingly reported in inhibitor discovery programs. Natural products in cancer and infectious disease therapeutics already form the backbone of >50% of drugs being used today, either directly or indirectly [7; 8]. Natural compounds such as blue vitriol, brimstone, trona, alum, palm ash and black stone have been applied in treatment of bacterial and fungal infections [9].

This research aims at assessing the *in vivo* antifungal efficacy and safety of natural compounds (blue vitriol, brimstone, trona, alum, palm ash and black stone) for topical treatment of cutaneous candidiasis

2.0 Materials and Methods

2.1 Study area

The study was carried out at the Laboratory Unit of Applied Microbiology and Brewing Department, Nnamdi Azikiwe University, Awka, Anambra State, South-East geopolitical zone of Nigeria.

2.2 Samples Collection

Blue vitriol, brimstone, trona, alum, palm ash and black stone were hygienically selected and purchased at the Eke-Awka market in Awka South Local Government Area of Anambra State, Nigeria. They were transported to the laboratory for analysis after proper identification at the Laboratory unit of Department of Geological Sciences, Nnamdi Azikiwe University, Awka, Anambra State, Nigeria [9].

2.3 Isolation and Identification of the fungal organisms

The test organisms were obtained from high vaginal swab specimens and identified based on their morphological, physiological and molecular characteristics. The identification tests include sugar fermentation test, growth on cornmeal agar, germ tube test, growth on Chromogenic *Candida* agar, and nucleic acid sequence analysis [9; 10].

2.4 Toxicological screening of the test samples

Toxicological screening is very important for the development of new drugs and for the extension of the therapeutic potential of existing molecules.

2.4.1 The Draize' skin irritancy test

The Draize' skin irritancy test was used to measure the harmfulness of the natural compounds in murines. Various dilutions, 400mg/ml, 200mg/ml, 100mg/ml and 50mg/ml of the natural compounds each was applied to the skin surfaces (dorsally and ventrally) of healthy eight-week old albino rat. During the observation period (14 days), signs such as fissure, necrosis, erythema and edema were assessed and recorded as shown below. At the end of the study, the animals were sacrificed and pathological changes evaluated through detailed histological studies [11].

Grading of skin reactions during Draize's skin test

0 – None; 1 – Slight; 2 – Moderate; 3 – Severe.

2.4.2 Murine local lymph node assay (LLNA)

Various concentrations of the natural compounds each, ranging from 400mg/ml, 200mg/ml, 100mg/ml and 50mg/ml were applied on the surface of the ears of eight-week old albino rats for three consecutive days, and the proliferation of lymphocytes in the draining lymph node was measured at the end; and compared with a negative control. The lymphocyte counts before and after treatment was recorded [12].

2.4.3 Necropsy studies

This is postmortem examination of animals to determine the extent of a disease or the cause of death. Necropsy studies allow for a more detailed examination of the animal's skin surface. The rat skin was examined carefully to identify macroscopic findings and correlate them with in-life observations. Orientation marks (left, right, dorsal, and/or ventral) was made on the skin with

permanent marker to help orient the specimen(s). Various concentrations, 400mg/ml, 200mg/ml, 100mg/ml and 50mg/ml of the natural compounds each was applied to the skin surfaces (dorsally and ventrally) of healthy eight-week old albino rat weighing 120 – 150g. Untreated skin was sampled from the same general body area to serve as negative control and minimize result interpretation errors [13].

Grading of skin reactions during necropsy studies

Erythema; Edema; Atonia; Desquamation; Fissuring; Scab formation; Exfoliation: 0 - None; 1 – Slight; 2 – Moderate; 3 – Severe/marked.

Exfoliation: 0 - None; Sloughing of scabs/eschar tissue; P – Present; A - Absent

Tissue damage/Necrosis: 0 - None; Blanched or blackened dead tissue; Absence of necrosis (Auletta, 2014).

2.5 *In vivo evaluation of antifungal activity of the solutions*

The *in vivo* antifungal potentials of the natural compounds was carried out using albino rats. Seventy-two eight-week old healthy albino rats (males – 48; females – 24) weighing between 120 - 150g obtained from a private animal house at Awka, Anambra State, were used. The rats were caged and placed in a room with controlled cycles of 12 hours of light and 12 hours of darkness. Water and food were provided to the animals *ad libitum*. The animals were housed singly [14].

The rats were divided into four groups of twelve rats each as follow:

Group 1: Infected and treated rats

Group 2: Positive control A (Infected and Untreated rats)

Group 3: Negative control A (Infected Rats Treated with topical Antifungal Cream (Ketoconazole).

Group 4: Negative control B (Uninfected rats).

The experiment was conducted in accordance with the internationally accepted principles of laboratory animals' use and care.

2.5.1 *Animal inoculation (Infection)*

The experimental animals were infected percutaneously [14]. This was done carefully and aseptically to avoid contaminating the site. The dorsal area, just above the tail region, the perianal region, the penile and vaginal regions were gently disinfected with 70% (v/v) ethanol and shaved carefully using sterile surgical blades. The size of the shaved area was 2 x 2cm². This area was gently, aseptically and carefully inoculated with a loopful of the isolates (equivalent to 1x10⁸ cfu/g), by gently smearing the yeast cell emulsified with normal saline, on the shaved surface. The animals were well fed and carefully observed till they developed signs of infections, characterized by reddening or continuous peeling-off of the skin with tiny reddish rashes (1-

2.5mm diameter). The animals' behavior was carefully monitored immediately after the inoculation (infection).

2.5.2 Post inoculation Treatment and analysis

Koch's postulate analysis

This was done to establish Koch's postulate in the disease process. Skin scrapings were carefully and gently collected (using sterile surgical blades) from the infected areas. This was immediately inoculated on SDA and Nutrient agar and incubated aerobically at 25 °C for 24 hours. The colonies were further identified as described earlier based on their morphological and physiological characteristics [15].

2.5.2.1 Antimicrobial formulations

The natural compounds were formulated for treatment using Vaseline jelly as the carrier. This was done in the ratio of 4:1 (natural compound: Vaseline base) [16].

2.5.2.2 Treatment

The experimental animals were treated twice daily by gently and carefully cleaning the infected areas with the test agents soaked in absorbent cotton wool. The negative control A, were treated with topical ketoconazole and Vaseline jelly, while the negative controls B were left untreated. The animals were carefully monitored for two weeks till full recovery [14].

2.5.3 Total yeast count determination

The total yeast count from the infected skin tissue at three days intervals during treatment by collecting tissues from infected sites, and inoculating SDA plates supplemented with chloramphenicol (50 µg/mL). The medium inoculation was done after serially diluting the tissue specimen in sterile normal saline. The growth was recorded as colony forming unit per gram (CFU/g) of the tissue specimen [17].

2.6 Histological analysis

Skin tissues from the test sites were collected and transferred to 10% neutral buffered formalin (NBF) for 24 hours at 40 °C. The formalin-fixed tissues were then dehydrated through grades of alcohol and cleared in xylene, and then embedded in paraffin wax (60 °C). The tissue sections (5mm) were deparafinized, stained with hematoxylin and counterstained with eosin. Histological analysis of the test animals' skin tissues was done before, during and after the treatment regimen [18; 19].

3.0 RESULTS AND DISCUSSION

In vivo toxicity and antifungal therapeutic potentials of selected natural compounds (palm ash, potash alum, trona, blue vitriol, black stone and brimstone) for topical applications using albino rat model, was carefully analyzed.

Draize' skin irritancy test (Table 1), murine local lymph node assay (Table 2) and necropsy findings (Table 3) revealed that the natural compounds are probably safe for topical applications. As shown in table 1 and 2, histopathological signs such as scab formation, desquamation, necrosis, erythema, edema, atonia and fissuring were not observed in the test animals except slightly in few situations. Slight erythema and atonia were observed with potash alum and blue vitriol during necropsy; Slight desquamation was seen with blue vitriol; brimstone induced slight scab formation and exfoliation; while slight exfoliation was observed with palm ash as shown in Table 3.

The skin sensitization assay also showed the safety of the natural compounds in topical applications when compared with the negative control (sterile distilled water) as shown in table 3. There was no significant difference between day 1 and day 4. These findings also agreed with the report by Ismail *et al.* [20] who stated that sulphur-based drugs are well demanded nowadays due to their high efficacy, non-toxicity and low cost. On the same note, the histological studies by Al-Talib *et al.* [21] confirmed the safety of alum salt for mammalian consumption. Alzomor *et al.* [16] also reported that alum cannot be directly absorbed on the skin due to its negatively charged molecules which are unable to pass through the cell membrane and therefore, alum remains a harmless substance. However, higher concentrations of alum might cause nephrotoxicity and intestinal bleeding [22].

Table 1. Draize' Skin Irritancy Test

Parameters (signs)	Blue vitriol	Potash alum	Trona	Brimstone	Black stone	Palm ash	Control (H ₂ O)
Erythema	1	1	0	0	0	0	0
Edema	0	0	0	0	0	0	0
Atonia	1	1	0	0	0	0	0
Fissuring	0	0	0	0	0	0	0

None = 0, Slight = 1, Moderate = 2, Severe = 3 @200mg/ml

Table 2. Skin Sensitization Test (Murine local lymph node assay)

Parameters	Blue vitriol	Potash alum	Trona	Brimstone	Black stone	Palm ash	Control (H ₂ O)
Day 1 (Lymphocyte count %)	32.50±0.71	31.50±0.71	30.50±0.71	32.50±0.71	29.50±0.71	30.50±0.71	32.50±0.71

Day 4 (Lymphocyte count %)	35.50±0.71	33.50±0.71	29.50±0.71	30.50±0.71	29.50±0.71	28.50±0.71	30.50±0.71
P > 0.05 @200mg/ml							

Table 3. Necropsy Findings

Parameters (@200mg)	Blue vitriol	Potash alum	Trona	Brimstone	Black stone	Palm ash	Control (H ₂ O)
Erythema	1	1	0	0	0	0	0
Edema	0	0	0	0	0	0	0
Atonia	1	1	0	0	0	0	0
Desquamation	1	0	0	0	1	0	0
Fissuring	0	0	0	0	0	0	0
Scab Formation	0	0	0	1	0	0	0
Exfoliation	0	0	0	1	0	1	0
Necrosis	0	0	0	0	0	0	0

None = 0, Slight = 1, Moderate = 2, Severe = 3

The histological findings as described in the stained skin sections showed no observable histopathological signs as seen in the architecture of the collagen bundles, blood vessels and the sebaceous units (fig. 5 and 6). The *in vivo* toxicological analysis of the natural compounds showed that the agents are probably fit for topical applications.

The *in vivo* effectiveness of treatment using the various formulations of natural compounds was also evaluated. The various signs of cutaneous candidiasis observed included erythema, rash, exfoliation, desquamation and whitish discharge (for vaginal candidiasis) [23]. The signs gradually disappeared 5 – 7 days during treatment as also confirmed in the stained skin sections of fig. 2 to 4. All the test agents were very effective *in vivo*, in the treatment of various forms of cutaneous candidiasis as shown in fig. 2 to 4.

Histological analysis was performed on normal albino rat skin (negative control) and infected rat skins. The normal rat stained skin sections (fig. 1) showed the collagen bundles, blood vessel, sebaceous units and hair follicles in their normal size and forms. The stained infected rat skins sections (before treatment) showed an intense peri-adnexal infiltration of inflammatory cells, inflamed sebaceous units and malformed collagen bundles as shown in fig. 2. The histological results revealed that tissue regeneration was very much quicker in the treated groups compared to the negative control groups. The increased cellular infiltration of inflammatory cells observed may be due to the presence of pathogens (*Candida spp*), but the antimicrobial activities of the

natural compounds massively reduced the yeast population. This consequently resulted to reduction in number of the inflammatory cells (fig. 3 and 4). These findings are in line with the work done by Sasidharan *et al.* [14] on the wound healing potentials of *Elaeis guineensis* jacq leaves on infected albino rat model. Vaseline gelly was used as base in the drug formulation at ratio of 4:1. It was also used as the negative control (placebo) while ketoral (ketoconazole) was used as the positive control.

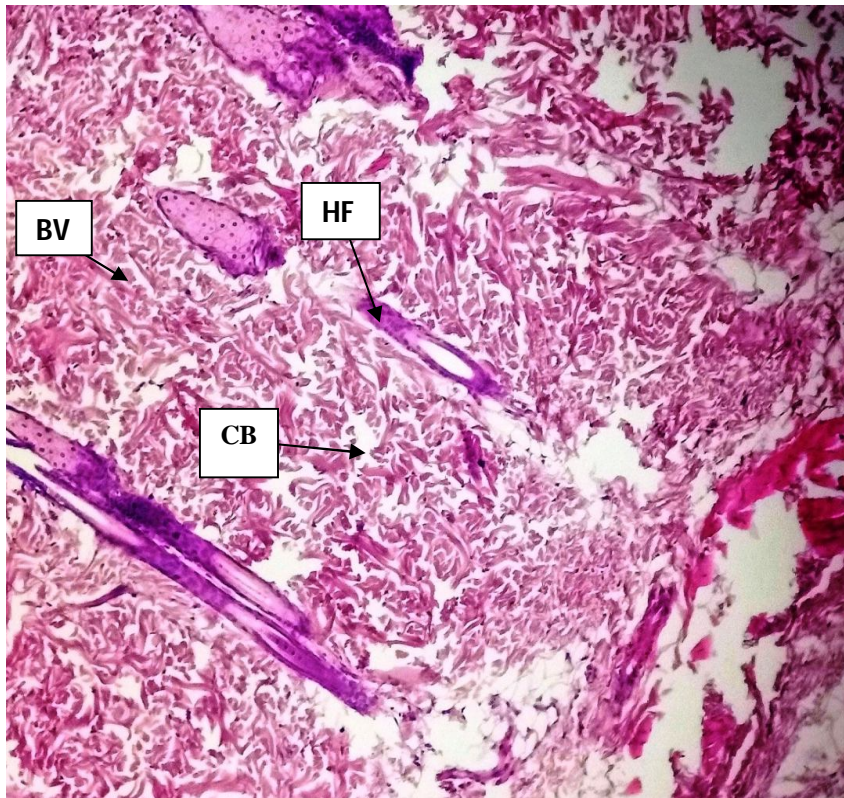


Fig. 1. Normal albino rat skin section before infection and treatment
Key: HF: Hair follicles, BV: Blood Vessels, CB: Collagen bundles

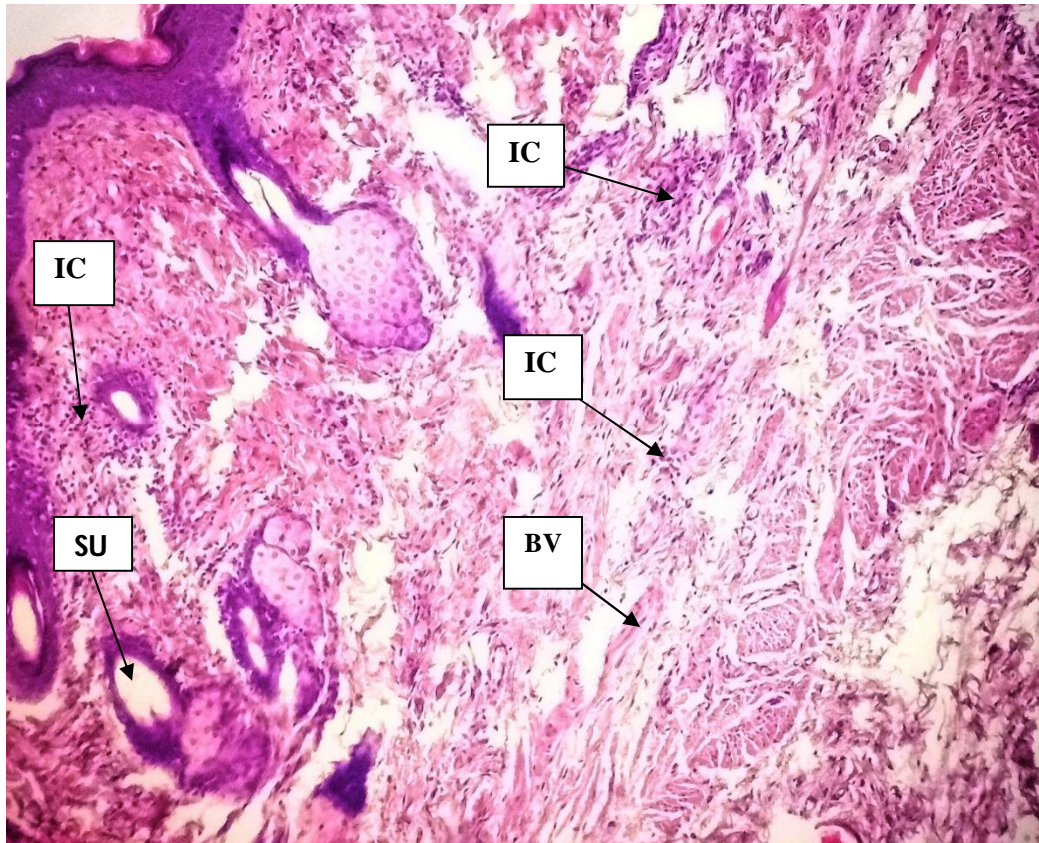


Fig. 2. Day 1 before treatment showing intense peri-adnexal infiltration of inflammatory cells, inflammation of the sebaceous units with drastic loss of hair follicles.

Key: IC: Inflammatory cells, BV: Blood Vessels, SU: Sebaceous Units

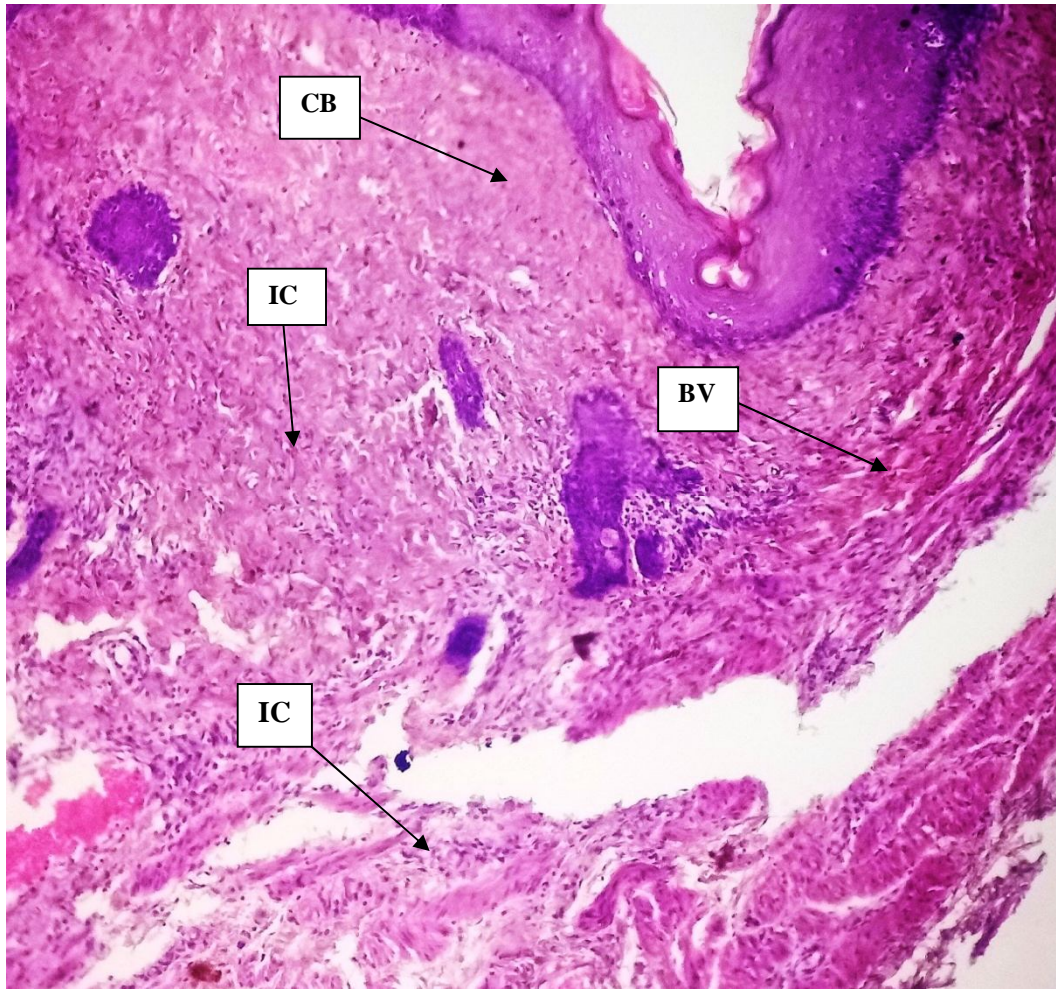


Fig. 3. Day 3 after treatment with Blue vitriol showing a gradual restoration of the skin architecture. The Collagen bundles are being restored with the gradual disappearance of the inflammatory cells (@200 mg/mL).

Key: CB: Collagen Bundles, IC: Inflammatory Cells, BV: Blood Vessels

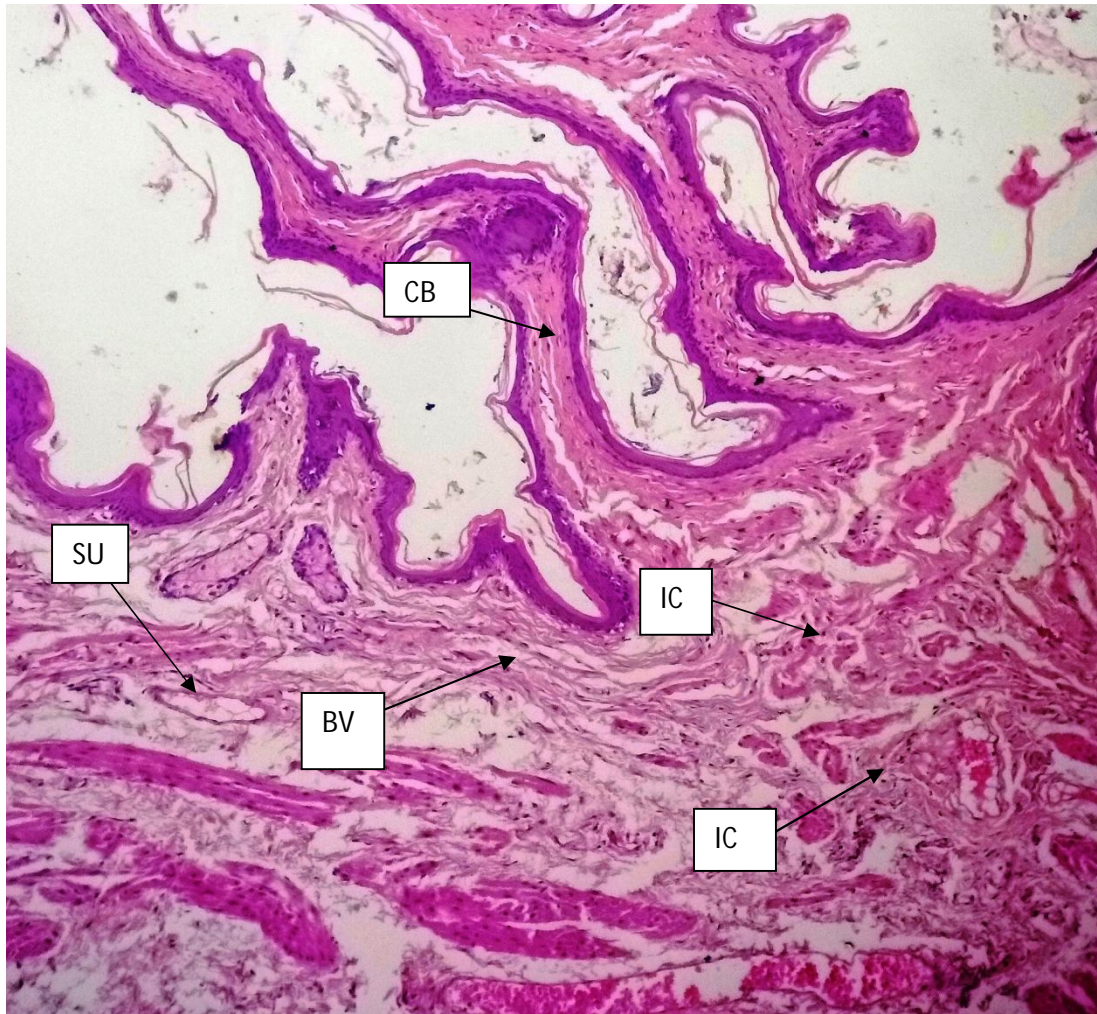


Fig. 4. Day 5 during treatment with blue vitriol showing almost complete restoration of the normal skin architecture, the blood vessels, collagen bundles, sebaceous units and with very little infiltrated inflammatory cells (lymphocytes) (@200 mg/mL).

Key: SU: Sebaceous Units, BV: Blood Vessels, IC: Inflammatory Cells

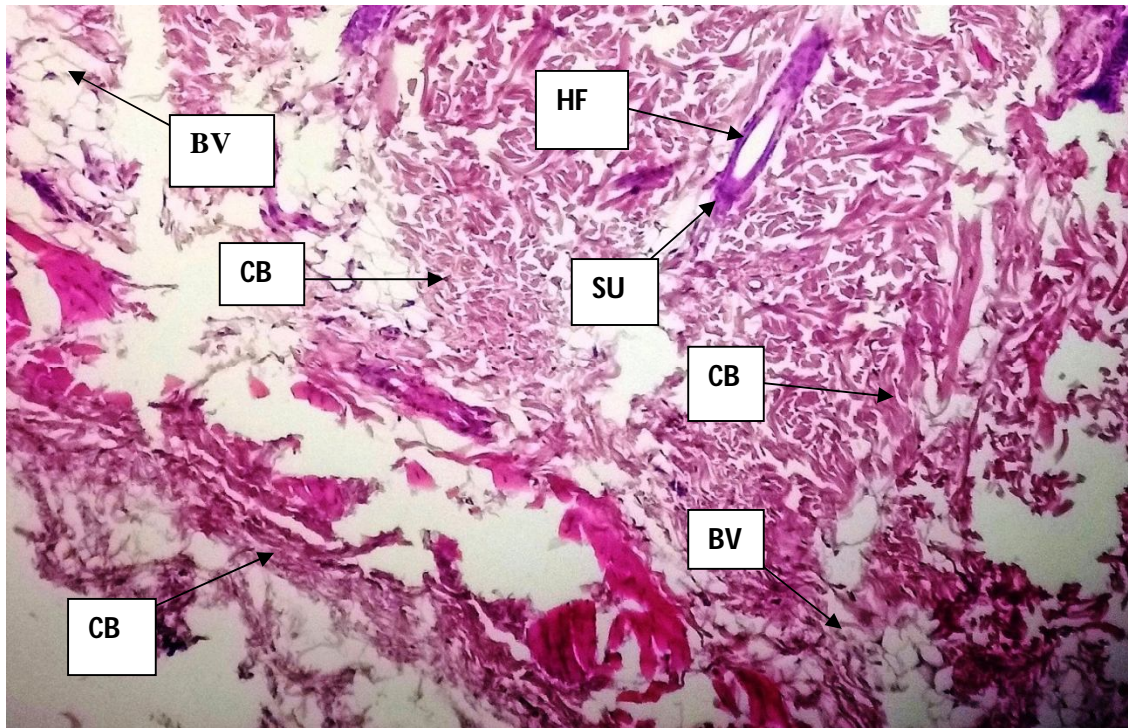


Fig. 5. Skin section for day 1 (pre-exposure) till day 5 (post-exposure) during toxicology (for blue vitriol, potash alum and Trona). No observable histopathological sign shown (@200 mg/mL).
Key: HF: Hair Follicles, BV: Blood Vessels, CB: Collagen Bundles, SU: Sebaceous Units

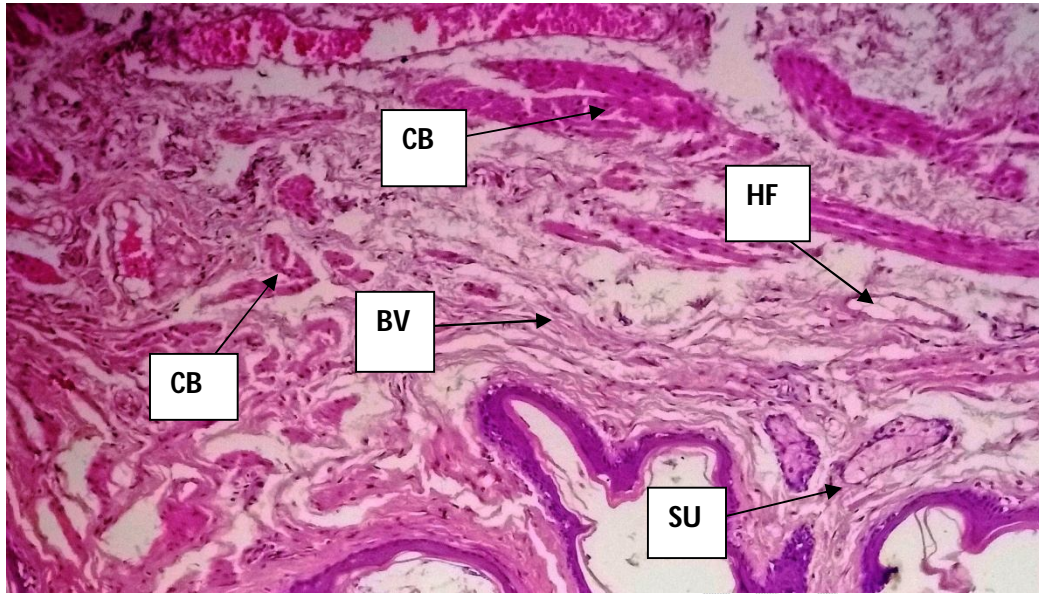


Fig. 6. Skin section for day 1 (pre-exposure) till day 5 (post-exposure) during toxicology (for brimstone, black stone and palm ash). No observable histopathological sign (@200 mg/mL). Key: CB: Collagen Bundles, BV: Blood Vessels, SU: Sebaceous Units, HF: Hair Follicles

Total yeast count was done at interval of three days during treatment (with blue vitriol) to evaluate the effectiveness of the agents in reducing the yeast population *in vivo*. It was observed that the yeast population declined gradually with time as shown in figure 7; thus, showing the *in vivo* effectiveness of the antimicrobial agents in treatment of cutaneous candidiasis when applied topically.

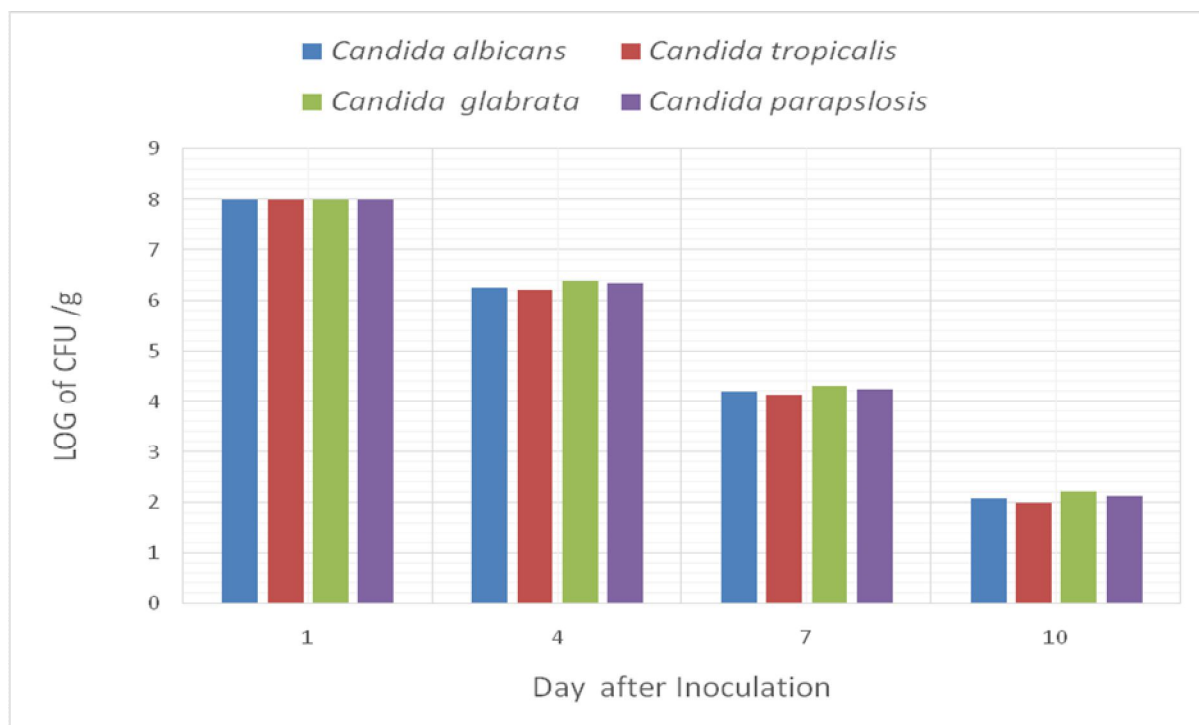


Fig. 7. Total yeast count (during treatment with blue vitriol)

4.0 CONCLUSION AND RECOMMENDATION

The findings revealed that naturally occurring compounds such as blue vitriol, brimstone, black stone, palm ash, trona and alum are potentially effective as topical antifungal agents in treatment of cutaneous candidiasis *in vivo*. This could bring about a paradigm shift in treatment of cutaneous mycoses. Further research on these compounds is therefore highly recommended especially to enhance their potency and likewise make them safer in topical and systemic applications.

Disclaimer (Artificial intelligence)

Author(s) hereby declare that NO generative AI technologies such as Large Language Models (ChatGPT, COPILOT, etc.) and text-to-image generators have been used during the writing or editing of this manuscript.

Disclaimer

This paper is an extended version of a preprint /repository/ Thesis document of the same author.

The preprint /repository/ Thesis document is available in this link: https://phd-dissertations.unizik.edu.ng/repos/81304045750_104069178560.pdf

[As per journal policy, preprint /repository article can be published as a journal article, provided it is not published in any other journal]

REFERENCES

1. Fuentefria AM, Pippi BD, Lana DF, Donato KK, de Andrade SF. Antifungals discovery: an insight into new strategies to combat antifungal resistance (Review). *Letters Appl Microbiol.* 2018;66(1): 2-13.
2. Almeida F, Rodrigues ML, Coelho C. The still underestimated problem of fungal diseases worldwide. *Front Microbiol.* 2019;10: 214.
3. Baron S. *Medical Microbiology*, 4th edition. Galveston, Texas, USA. 1996.
4. Ghannoum MA, Rice LB. Antifungal Agents: Mode of Action, Mechanisms of Resistance, and Correlation of These Mechanisms with Bacterial Resistance. *Clin Microbiol Rev.* 1999;12(4): 501–17.
5. Denning DW, Bromley MJ. Infectious Disease. How to bolster the antifungal pipeline. *Science*, 2015;347:1414 - 1416
6. Roemer T, Krysan DJ. Antifungal drug development: challenges, unmet clinical needs, and new approaches. *Cold Spring Harb. Perspect. Med.* 2014;4: a019703.
7. Newman DJ, Cragg GM. Natural products as sources of new drugs from 1981 to 2014. *J Nat Prod.* 2016;79: 629 - 61.
8. Rodrigues T, Reker D, Schneider P, Schneider G. Counting on natural products for drug design. *Nat Chem.* 2016;8: 531–41.
9. Udemezue OI, Alaebo CL, Udenweze EC, Okoli UO. Evaluation of Antimicrobial Effects of Trona and Alum on Dental Caries Isolates. *Intl J Res Innov Appl Sci.* 2023;7(9): 52 – 8.
10. Moya-Salazar J, Rojas R. Comparative study for identification of *Candida albicans* with germ tube test in human serum and plasma. *Clin Microbiol Infect Dis.* 2018;3(3):1-4.
11. Draize JH, Woodard G, Calvery HO. Methods for the study of irritation and toxicity of substances applied topically to the skin and mucous membranes. *J Pharmacol* 1944;82: 377–90.
12. Ramani T, Lin J, Savidge C, Jones T, Auletta C. Practicalities of dermal dosing: The practical aspects of dose administration in minipigs and rats. Poster session presented at 35th Annual Meeting of the America College of Toxicology, November 9–12, 2014, Orlando, FL.
13. Auletta CS, Derelanko MJ. General toxicology. In *Handbook of Toxicology* (3rd ed.). CRC Press, Boca Raton, FL. 2014;57–94.

14. Sasidharan S, Nilawaty R, Xavier R, Latha YL, Amala R. Wound Healing Potentials of *Elaeis guineensis Jacq* Leaves in an Infected Albino Rat Model. *Molecules*, 2010;15: 3186 – 99.
15. Byrd A, Segre J. Adapting Koch's Postulates. *Science*, 2016;351 (6270): 224 –26.
16. Alzomor AK, Moharram AS, Al Absi NM. Formulation and evaluation of potash alum as deodorant lotion and after shaving astringent as cream and gel. *Intl curr pharm j* 2014;3(2):228-33.
17. Cheesbrough M. *Laboratory Practice in tropical Countries* (2nd edition) Part 2. Cambridge University Press, Cambridge, United Kingdom. 2010.
18. Slaoui M, Fiette L. Histopathology Procedures: From Tissue Sampling to Histopathological Evaluation. *Drug Saf Eval Methods Mol Bio*. 2011;691: 69 –82.
19. Ross MH, Pawling W. *Histology: a text and atlas with correlated cell and molecular biology* (7th ed.). Wolters Kluwer. 2016; 984.
20. Ismail M, Yuri M, Farit U, Ahmed AI. Antifungal Activity of Inorganic Micro-and Nanoparticles Against Pathogenic Fungi Compared with Some Traditional Organic Drugs. *Am-Eur J Agric Env Sci*. 2016;16(4): 652–62.
21. Al-Talib HI, Mohd Nasir NIS, Yaziz H, Zulkafli NF, Adani NA, Noor Rashidi AI, Shaari SA. Potassium Aluminium Sulphate (Alum) Inhibits Growth of Human Axillary Malodor-Producing Skin Flora *in vitro*. *J Clin Health Sci*. 2016;1(1):259.
22. Bryan IA, Alta'ee AH, Kadhum NH. Antibacterial Activity of Aluminum Potassium Sulfate and *SyzygiumAromaticum* Extract Against Pathogenic Microorganisms. *J Nat Sci Res*. 2014;4(15): 11-14.
23. Ezeamalu CP, Udemezue OI, Ottong DJ, Udemezue OI, Ezeadila JO. Microorganisms implicated in vulvovaginitis among patients attending a teaching hospital in southeastern Nigeria. *International J Sci Res Arch*. 2024; 12(02): 2658–2664.