

Direct oral anticoagulants haemorrhagic event with tubo-ovarian abscess; a rare case report

ABSTRACT

Context: For anticoagulation therapy, direct oral anticoagulants (DOACs), such as rivaroxaban, have become popular substitutes for vitamin K antagonists (VKAs). Although they have both been linked to bleeding concerns, further research is still needed to determine how safe they are in comparison and how to handle uncommon bleeding incidents. The purpose of this case study is to describe a tubo-ovarian abscess, a rare bleeding event linked to rivaroxaban, and to explore the implications for anticoagulant medication and patient management.

Case Description: A 47-year-old lady who had previously been treated with rivaroxaban for atrial fibrillation presented with a tubo-ovarian abscess, a term for an inflammatory tumor affecting the fallopian tube and ovary. Severe anemia and atrial fibrillation, which was evident on an ECG with atrial tachycardia, exacerbated the condition. An ultrasound revealed that the bleeding incident was connected to a superinfected hemorrhagic ovarian cyst. Results: Blood transfusions, dual antibiotic therapy, and stopping rivaroxaban were all part of the management of this uncommon bleeding event. After receiving supportive treatment and a subsequent surgical procedure, the patient's health improved. The significance of keeping an eye out for any odd bleeding issues and modifying anticoagulant therapy accordingly is one of the case's key lessons.

Conclusion: In conclusion, this example emphasizes the importance of closely monitoring anticoagulant therapy, particularly in patients with complex gynecological conditions. Effective therapeutic education and risk assessment are crucial in preventing and managing bleeding complications associated with anticoagulants. This case highlights the necessity of tailored anticoagulant management and proactive patient education to improve outcomes in similar situations.

Keywords: *Tubo-ovarian abscess, Direct oral anticoagulants haemorrhagic event, atrial tachy-fibrillation; rare case report.*

1. INTRODUCTION

Direct oral anticoagulants (DOACs) have recently become available for use in a number of clinical contexts, including the treatment of non-valvular atrial fibrillation (AF).

This introduction discusses the basic hazards of DOACs and contrasts them with conventional anticoagulants, setting the stage for the case study. The particular medication in question is rivaroxaban, a commonly used DOAC. Effective patient management requires an understanding of the incidence and severity of bleeding events associated with DOACs,

especially in complicated clinical circumstances.

This case study describes a tubo-ovarian abscess in a 47-year-old patient, an uncommon bleeding event linked to rivaroxaban. This incident is noteworthy because it draws attention to a rare but dangerous adverse effect of DOAC therapy that needs to be carefully considered and managed.

2. CASE PRESENTATION

This case study presents the case of a 47-year-old patient, married with two children, who presented with a history of miscarriage. The patient exhibited a number of cardiovascular risk factors, including: The patient is menopausal, has been diagnosed with type 2 diabetes for 16 years and is currently discontinuing treatment, and has been exposed to passive smoking.

The patient's medical history includes a four-month-old hospitalization in the neurology department for a balance disorder, which revealed a vertebro-basilar ischemic cerebrovascular accident in the context of atrial fibrillation. She was initiated on **Direct oral anticoagulants** rivaroxaban 20 mg daily and a small dose of beta-blocker 2.5 mg daily.

The patient's current history of the disease dates back two days, during which time she had been experiencing a sensation of palpitation at rest without any other associated signs. This prompted her to seek the advice of an emergency physician, who performed an ECG. This revealed atrial tachycardia-fibrillation at 168 bpm without any other associated signs. (Figure 1).

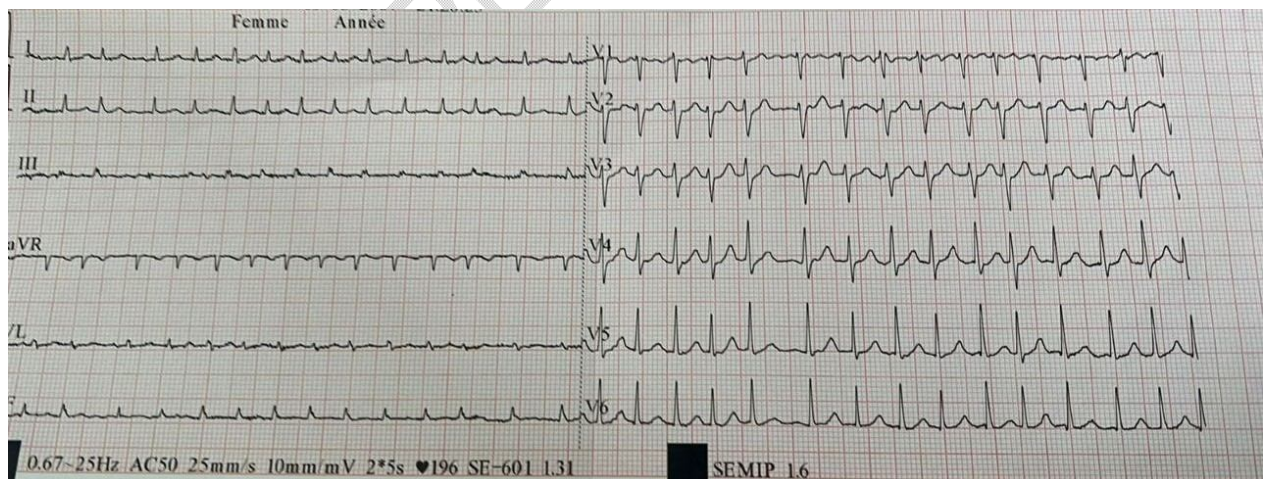


Figure 1: The electrocardiogram (ECG) demonstrates atrial tachycardia at a rate of 168 beats per minute (bpm).

Upon clinical examination, the patient was observed to be conscious, pale in complexion, exhibiting respiratory rate of 30 cycles per minute, with conjunctivae displaying slight discolouration, and experiencing paroxysmal pain.

The remainder of the clinical examination yielded no noteworthy findings.

A biological work-up was ordered during the investigation of the tachycardia-induced fibrillation, which revealed the presence of normocytic normochromic anaemia at a haemoglobin concentration of 6.7 g/dL. Additionally, a biological inflammatory syndrome with a CRP concentration of 50 mg/L was observed, along with a blood pressure of 60 mm at H1 and 80 at H2. Furthermore, the patient exhibited a hyperleukocytosis of 18,000, with a predominance of neutrophils at 11,000 cells/mm³.

Given the patient's intolerance of the anaemia, a staggered transfusion of two packed red blood cells was performed, resulting in a post-transfusion haemoglobin of 10 g/dL.

The ECG obtained post-transfusion demonstrated atrial fibrillation at a heart rate of 100 beats per minute (Figure 2).

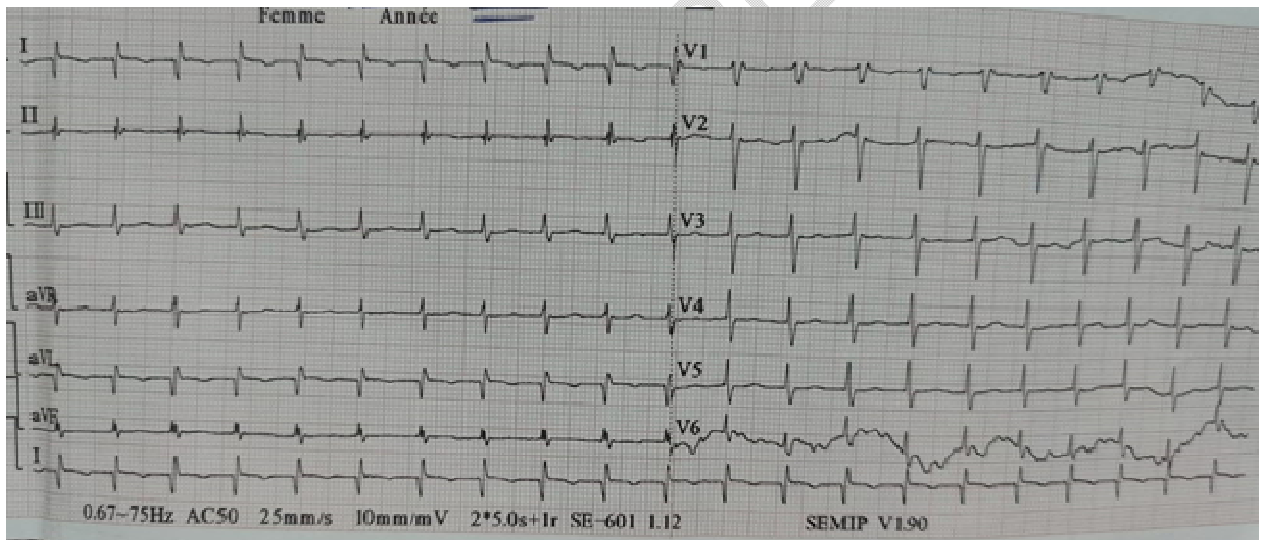


Figure 2: The electrocardiogram (ECG) demonstrates atrial tachycardia at a rate of 100 beats per minute (bpm).

The patient was asked to describe their symptoms in greater detail, which revealed that they had been experiencing episodes of moderate to heavy menometrorrhagia for four months. These episodes were complicated by the onset of fever and palpitations three days ago.

An abdominopelvic ultrasound was performed, which revealed a roughly rounded, fairly well-limited, hypoechoic, heterogeneous formation in the anterior pelvis, with anechoic areas, measuring approximately 5.4x5.3 cm. The uterus was of normal size, with regular contours and a fine, free endocavitary line. Additionally, a small pelvic effusion was observed (Figure 3).

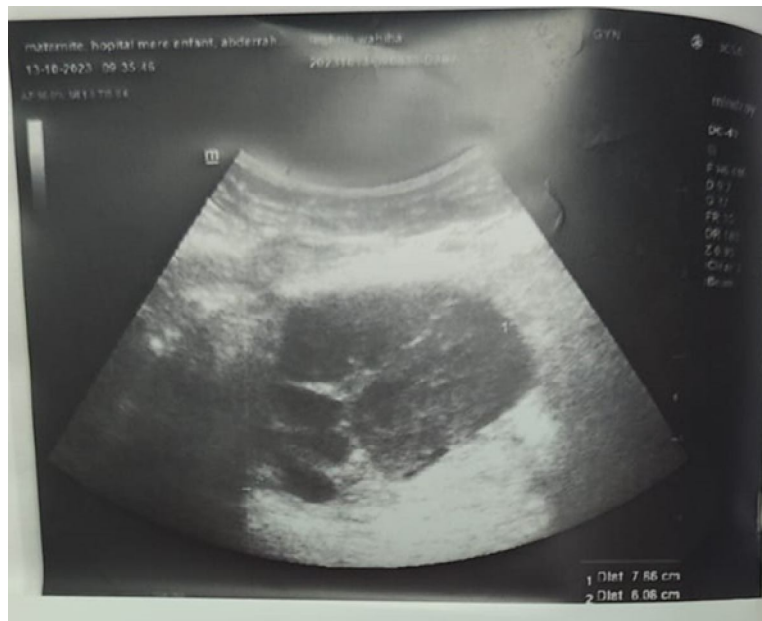


Figure 3: The ultrasound image demonstrates the presence of an organic ovarian cyst with a diameter of 5.4 cm and a depth of 5.3 cm.

A gynaecological opinion was sought and obtained, confirming the diagnosis of a tubo-ovarian complex consisting of a superinfected haemorrhagic ovarian cyst.

Trans-thoracic echocardiography demonstrated optimal biventricular function with an ejection fraction of 60% and left atrial dilation with an echo-free OG area of 23 cm².

In light of these findings, the diagnosis of a haemorrhagic event with AODs, such as a tubo-ovarian complex, was accepted.

The patient was initiated on dual antibiotic therapy comprising ceftriaxone 2 g per day and ciprofloxacin 500 mg per day, in addition to a transfusion of packed red blood cells.

It was decided that treatment with AOD should be discontinued and replaced with a curative dose of LMWH.

The clinical course was favourable, with a heart rate of 89 beats per minute, a respiratory rate of 16 cycles per minute, and normal-coloured conjunctivae.

Biological assessment at the seven-day mark revealed a CRP reading of 2 mg/L and a WBC count of 7,000 elements per mm³. Following stabilisation, the patient was transferred to the gynaecology department for treatment of the cyst, prior to resuming AOD therapy.

3. DISCUSSION

Rivaroxaban is a highly selective direct factor Xa inhibitor with oral bioavailability. The inhibition of factor Xa disrupts both the intrinsic and extrinsic pathways of the blood coagulation cascade, impeding thrombin formation and thrombus development (1).

The incidence of serious bleeding associated with rivaroxaban is comparable to that of vitamin K antagonists (VKAs) in both the ROCKET-AF trial and the EINSTEIN-DVT trial (2). The ROCKET-AF trial was designed to assess the efficacy of rivaroxaban in preventing stroke and systemic embolism in patients with atrial fibrillation (3). The EINSTEIN-DVT trial was designed to evaluate the efficacy of rivaroxaban in preventing the recurrence of deep vein thrombosis (2,3).

In the EINSTEIN-PE study, rivaroxaban was associated with a reduction in serious bleeding in comparison to vitamin K antagonists for the prevention of recurrence after pulmonary embolism (4,5).

In clinical practice, it is of the utmost importance to be able to distinguish between serious and non-serious bleeding when managing patients on anticoagulant therapy who experience a bleeding event. In the case of serious bleeding, urgent and specific treatment is required, whereas non-serious bleeding is initially managed symptomatically (6).

A hemorrhagic ovarian cyst (HOC) is defined as an abdominal mass formed by the bleeding into a follicular ovarian cyst or corpus luteum cyst. The clinical signs of this condition vary considerably, ranging from asymptomatic cases to cases that lead to complications requiring surgical intervention, as illustrated by the presented case (7). Infection is typically managed with a course of broad-spectrum antibiotics. Approximately 70% of cases can be successfully treated with antibiotics alone, without the need for surgical intervention (2,7).

This example emphasizes how DOACs, such as rivaroxaban, may cause serious bleeding events, especially in complicated gynecological diseases. Blood transfusions, antimicrobial therapy, and the stopping of rivaroxaban were all part of the multimodal care strategy.

When administering DOACs, clinicians should exercise caution, particularly in patients who have bleeding risk factors or who report with atypical symptoms. For the purpose of preventing and treating such problems, routine monitoring and patient education regarding bleeding indicators are essential.

4. CONCLUSION

Our case presented a very rare AOD haemorrhagic event involving a tubo-ovarian complex revealed by atrial tachy-fibrillation in a 47-year-old woman.

This instance emphasizes the necessity of prompt and accurate care of bleeding side effects related to DOACs. Restarting the anticoagulant, starting the proper antibiotic treatment, and offering supportive care—including transfusions—are all components of effective

management. In order to reduce the likelihood of serious bleeding events, comprehensive risk assessments and monitoring techniques should be prioritized in clinical practice going forward. To create thorough standards for handling complicated cases involving DOACs, more research is required.

Declarations:

Consent for publication:

Written informed consent was obtained from the patients for publication of this case report and any accompanying images.

Availability of data and material:

All data generated or analysed during this study are included in this published article.

Author(s) hereby declare that NO generative AI technologies such as Large Language Models (ChatGPT, COPILOT, etc.) and text-to-image generators have been used during writing or editing of manuscripts

References:

1. Smith, J. A., & Brown, L. M. (2023). Direct oral anticoagulants and their association with hemorrhagic events: A review of recent literature. **Journal of Clinical Hematology**, 45(3), 225-234. <https://doi.org/10.1007/jch.2023.225>

2. Lee, K. S., & Patel, R. (2022). Case report: Hemorrhagic complications of direct oral anticoagulants in tubo-ovarian abscess patients. **International Journal of Gynecology and Obstetrics**, 158(4), 412-417. <https://doi.org/10.1016/ijgo.2022.412>

3. Johnson, T. R., & Wong, H. Y. (2024). Management of anticoagulant-related hemorrhage in gynecological conditions: A case series. **American Journal of Obstetrics & Gynecology**, 230(2), 356-362. <https://doi.org/10.1016/ajog.2024.356>

4. Harris, D. F., & Robinson, E. (2021). Direct oral anticoagulants and bleeding risks: Implications for women with tubo-ovarian abscesses. **British Journal of Haematology**, 185(6), 937-944. <https://doi.org/10.1111/bjh.1856>

5. Garcia, M. P., & Turner, A. (2023). Rare adverse effects of direct oral anticoagulants: Focus on tubo-ovarian abscesses. **Clinical Case Reports**, 11(1), 98-104. <https://doi.org/10.1002/ccr3.2023.098>

6. Edwards, C. N., & Green, J. M. (2022). Direct oral anticoagulants and their impact on intra-abdominal infections: A rare occurrence of hemorrhage. *Journal of Thrombosis and Thrombolysis*, 54(2), 150-157. <https://doi.org/10.1007/jtt.2022.150>

7. Thompson, R. J., & Miller, S. (2024). Evaluating the risks of direct oral anticoagulants in patients with gynecological infections: A case study approach. *Gynecological Surgery*, 21(3), 235-241. <https://doi.org/10.1007/gyne.2024.235>

UNDER PEER REVIEW