

# Case report

## Recurrent Sigmoiditis Unveiling a Rare Entity: A Case Report of Cystic Lymphangioma

### ABSTRACT

---

*Abbreviations:* CL: Cystic lymphangioma; CT: Computed tomography; MRI: Magnetic resonance imaging; EUS: Endoscopic ultrasound; GI: Gastrointestinal

*Keywords:* Cystic lymphangioma, Colon, Benign tumor, Lymphatic system, Submucosal tumor, Diagnostic challenge, Endoscopic ultrasonography, Surgical resection

**Aims:**

To present a case of cystic lymphangioma (CL) in the sigmoid colon, highlighting the clinical presentation, and to discuss the diagnostic and therapeutic implications of this rare presentation arising from an atypical location within the gastrointestinal tract.

**Presentation of the case:**

A 31-year-old woman with a history of recurrent sigmoiditis underwent a prophylactic sigmoidectomy due to persistent abdominal pain despite antibiotic therapy. Histopathological examination of the resected specimen revealed a 4 cm cystic lymphangioma in the subserosa.

**Discussion:**

The diagnosis of intra-abdominal CLs is often delayed due to their nonspecific clinical presentation and rarity. Imaging modalities like ultrasound, CT, and MRI can aid in diagnosis, and only confirmed by histopathological examination. Surgical resection is the preferred treatment for symptomatic CLs.

**Conclusion:**

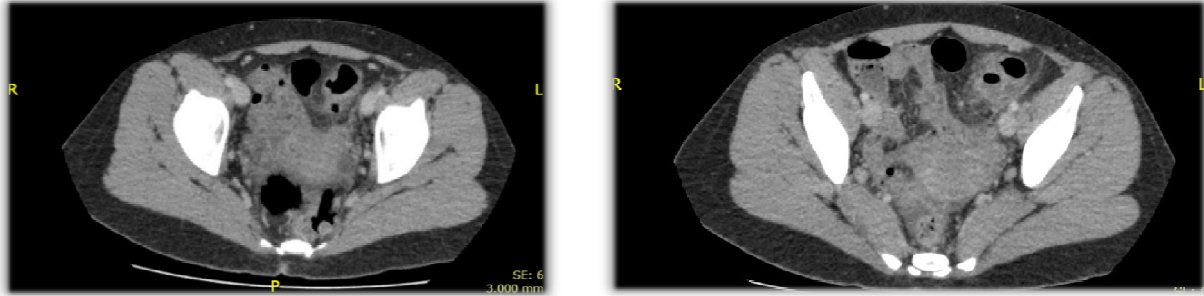
This case highlights the difficulty to diagnosis intra-abdominal cystic lymphangiomas due to their non-specific symptoms. Accurate imaging and histopathological analysis are the keys to an accurate diagnosis. Successful management and minimisation of the risk of recurrence depends on early detection and complete surgical resection.

**Introduction :**

Cystic lymphangiomas (CL), although typically associated with childhood and cervico-facial presentations, can occur in rare intra-abdominal locations, posing diagnostic and therapeutic challenges. The elusive nature of these benign lymphatic tumours, particularly in the colon or its mesentery, often leads to delayed diagnosis and potential complications. The aim of this case report is to highlight the clinical presentation, diagnostic work-up and management of a cystic lymphangioma arising in an atypical location of the gastrointestinal tract, emphasising the importance of maintaining a high index of suspicion for this rare entity.

**Case Presentation**

A 31-year-old female patient presented with a history of recurrent sigmoiditis. She had experienced two episodes: one in July (with a CT scan showing findings suggestive of sigmoiditis without any evidence of a cystic mass and a CRP of 133 mg/L) and another in December. The first episode was treated with 7 days of amoxicillin-clavulanate, extended for another 7 days due to persistent left iliac fossa pain. The second episode was managed with cefotaxime and metronidazole, resulting in a favorable outcome. The patient's beta-hCG tests were negative.

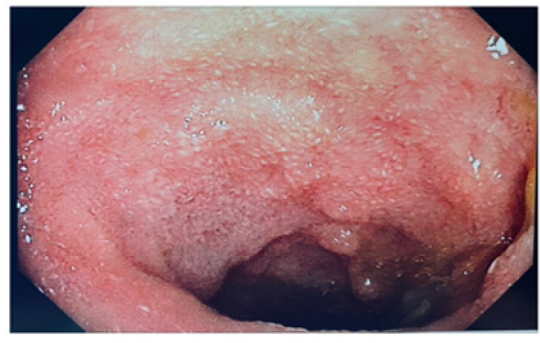


*Figure 1: Abdomino-pelvic CT scan (cross-section): Sigmoid diverticulitis with wall thickening and surrounding inflammation.No evidence of obstruction or perforation.*

Laboratory investigations during the second episode revealed a leukocyte count of 20.1 G/L, normal electrolytes, normal liver function tests, and a CRP of 113 mg/L. Repeat imaging showed localized thickening of the colon involving a few diverticula medial to the anterior superior iliac spine.

A colonoscopy performed in February revealed localized, uncomplicated diverticulosis in the sigmoid colon. The patient experienced another infectious flare in mid-April, treated with 10 days of antibiotics, which did not completely resolve her hypogastric pain.

Given the recurrent nature of her symptoms, a decision was made to proceed with a prophylactic sigmoidectomy. The procedure was performed laparoscopically in July, with an uncomplicated postoperative course. The patient was discharged on postoperative day 2 after resuming a normal diet and ambulation.

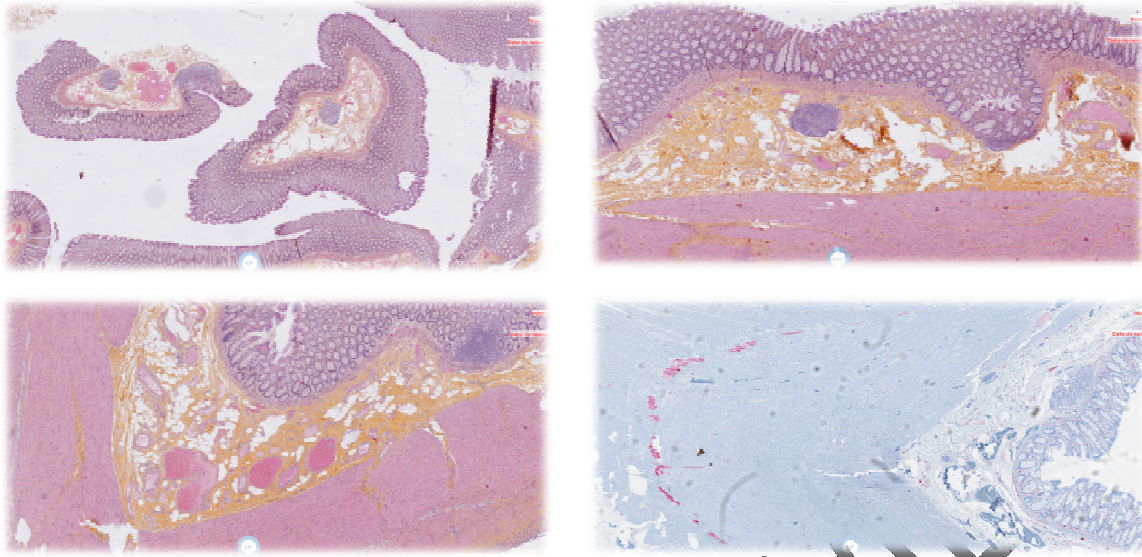


*Figure 2 : Colonoscopy revealing sigmoid diverticulosis*

Histological examination of the resected sigmoid colon segment revealed a 4 cm cystic lesion located in the subserosa. Microscopic examination showed congested sigmoid mucosa and a benign cystic lymphangioma filled with acellular material. The cyst was lined by a fibrous wall containing a resorptive inflammatory reaction rich in foreign body giant cells. The surgical margins were clear.

The final diagnosis was cystic lymphangioma associated with congested sigmoid mucosa.

The patient's postoperative course was uneventful, and she was discharged with a plan for clinical follow-up and a scheduled endoscopy in the coming months.



*Figure 3 : Histopathological images of Cystic lymphangioma.*

### **Discussion :**

Cystic lymphangiomas (CLs) are uncommon benign tumors that, while predominantly diagnosed in children, can manifest at any age. The most frequent locations for CLs are the cervical and axillary regions, accounting for 95% of cases. In contrast, CLs within the abdominal cavity, including the colon, are considerably rarer, representing less than 1% of all cases. The first documented case of colonic lymphangioma was reported in 1932, and despite 104 cases being documented in Japan by 1995, it remains an infrequent diagnosis in Western countries.[1][2]

The precise etiology of lymphangiomas is yet to be fully elucidated. The prevailing theory posits a congenital malformation within the lymphatic system during embryogenesis. This malformation disrupts the connection between lymphatic chains and the venous system, leading to the isolation and subsequent dilation of lymphatic capillaries, ultimately resulting in the formation of multiple cysts. Importantly, there is no evidence to suggest that lymphangiomas undergo malignant transformation.[4][5]

### **Clinical Presentation and Diagnosis**

The clinical presentation of cystic lymphangiomas (CLs) is often nonspecific and can vary depending on the size, location, and presence of complications. The majority of CLs are solitary lesions. Symptoms can range from abdominal pain, altered bowel habits (constipation, diarrhea, and tenesmus), and rectal bleeding to an asymptomatic presentation, as was the case with our patient who was hospitalized for diverticulitis. The potential for complications such as hemorrhage, infection, obstruction, or anemia underscores the importance of timely diagnosis and management.[5][9]

The diagnosis of intra-abdominal CLs is challenging due to the lack of specific clinical symptoms and the similarity of their imaging features to other cystic lesions. Colonoscopy may reveal a submucosal tumor covered with normal mucosa, but advances in colon ultrasonography have significantly improved the ability to diagnose colonic submucosal tumors, including CLs. The integration of clinical findings, imaging studies, and endoscopic ultrasound can enhance the accuracy of diagnosing intra-abdominal CLs, enabling prompt and appropriate management.[9][11]

Imaging modalities play a pivotal role in the diagnostic workup. Ultrasonography, often the initial imaging test, typically reveals a multilocular cystic mass with thin walls. The echogenicity of the mass can vary depending on the cyst content, which may be serous, chylous, or hemorrhagic. Computed tomography (CT) scans offer a more detailed visualization of the mass, demonstrating its homogenous, hypodense nature, the presence of thin septa, and the absence of enhancement after contrast administration. The relationship of the mass to surrounding anatomical structures can also be assessed. Magnetic resonance imaging (MRI), while not routinely used, can provide additional information about the cystic nature of the lesion and its precise anatomical relationships, particularly in complex cases or when the diagnosis remains uncertain.[4][11]

Despite the utility of imaging modalities, the definitive diagnosis of CLs often necessitates histopathological examination of the resected specimen. The characteristic microscopic features of CLs include a cystic structure with fibrous septa containing lymphoid tissue and smooth muscle, lined by a single layer of lymphatic endothelium.[9]

### **Therapeutic Strategies**

The management of colonic lymphangiomas has evolved over time. Traditionally, treatment involved open surgical procedures like partial colon resection or tumor resection. The advent of endoscopic techniques, particularly polypectomy, has offered a less invasive alternative, especially for pedunculated or semi-pedunculated lesions under 2 cm in diameter. This approach, as advocated by Karasawa et al.[6], aims to minimize complications such as wall perforation, which can occur during the removal of non-pedunculated lymphangiomas. The decision to proceed with endoscopic resection necessitates a thorough assessment of the lesion's characteristics, including its size, location, and relationship to the colonic wall, often aided by detailed ultrasonographic imaging.[3][7]

While non-surgical options like sclerosing therapy using agents such as Bleomycin can reduce the mass's size, they are associated with a high risk of recurrence, potentially reaching 100% in the long term. Consequently, these therapies are typically reserved for symptomatic management of unresectable lesions or those where complete surgical excision would necessitate extensive bowel resection.[3]

Surgical excision remains the gold standard for managing colonic lymphangiomas, particularly in symptomatic cases, due to the risk of lesion progression and complications. The goal is complete tumor removal to minimize recurrence, achievable through laparotomy or laparoscopy. The laparoscopic approach offers the advantages of reduced postoperative pain, shorter hospital stays, and faster recovery. Given the benign nature of lymphangiomas, the surgical approach should prioritize preserving surrounding organs and minimizing bowel resection. Meticulous attention to lymphatic drainage during surgery is crucial to prevent complications like lymphocele or chylous ascites.[2][10]

### **conclusion :**

The presented case underscores the diagnostic challenges posed by intra-abdominal cystic lymphangiomas, particularly in atypical locations like the sigmoid colon. The nonspecific clinical presentation and potential for mimicking other conditions can lead to delayed diagnosis. A high index of suspicion, coupled with the judicious use of imaging modalities and histopathological confirmation, is crucial for accurate diagnosis. Complete surgical resection remains the cornerstone of management, offering the best chance for cure and minimizing the risk of recurrence.

### **References**

[1]Allen JG, Riall TS, Cameron JL, Askin FB, Hruban RH, Campbell KA. Abdominal lymphangiomas in adults. J Gastrointest Surg. 2006 May;10(5):746-51

- [2]Bezzola T, Bülher L, Chardot C, et al. Le traitement chirurgical du lymphangiome kystique abdominal chez l'adulte et chez l'enfant. *J Chir.* 2008;145:238-243.
- [3]Sato K, Maekawa T, Yabuki K, et al. Cystic lymphangiomas of the colon. *J Gastroenterol.* 1999;34(5):520-524.
- [4]Tuan NA, Du NV, Hiep PV. Giant cystic lymphangioma of right mesocolon: A case report. *Int J Surg Case Rep.* 2021;86:106326. Published 2021 Aug 19.
- [5]Verdin V, Seydel B, Detry O, et al. Le lymphangiome kystique du mésentère. *Rev Med Liege.* 2010;65(11):615-618
- [6]Karasawa H, Miura T, Makino T, et al. Two cases of lymphangioma of the large intestine extracted by endoscopic polypectomy. *Prog Dig Endosc* 1985;26:330–4.
- [7]Wakabayashi T, Suzuki K, Tanabe M, et al. A lymphangioma of the ascending colon diagnosed by polypectomy. *Gastroenterol Ensoc* 1986;28:440.
- [8]Kashiwagi A, Matsuura A, Nakamura T, et al. Lymphangioma of the descending colon diagnosed by endoscopic ultrasonography. *Endosc Dig* 1993;5:843–7.
- [9]Mabrut JY, Grandjean JP, Henry L, et al. Les lymphangiomes kystiques du mésentère et du méso-colon. Prise en charge diagnostique et thérapeutique. *Ann Chir,* 2002, 127, 343-349.
- [10]Prabhakaran K, Patankar JZ, Loh DLSK, et al. Cystic lymphangioma of the mesentery causing intestinal obstruction. *Singapore Med J,* 2007, 48, 265-266.
- [11]Okamoto D, Ishigami K, Yoshimitsu K, et al. Hemorrhagic mesenteric cystic lymphangioma presenting with acute lower abdominal pain: the diagnostic clues on MR imaging. *Emerg Radiol,* 2009, 16, 327-330.