

Case report

Immediate And Successful Management Of Avulsed Teeth: A Case Reports

ABSTRACT

Avulsion and midroot fractures of teeth present significant challenges in dental trauma management. These case reports outline the successful management of avulsed teeth after a lapse of 2hrs in 1st case report and 24hrs in 2nd case report and midroot fractured tooth, focusing on immediate steps, long-term strategies, and clinical considerations. Midroot fractures often present with compromised structural integrity, necessitating stabilization and protection of the tooth to prevent further damage. Splinting techniques stabilize the tooth and promote healing of periodontal tissues. However, careful monitoring is crucial to assess for potential complications such as inflammatory root resorption and external root resorption. In both the cases extraoral root canal treatment was done for avulsed tooth and then reimplanted into the socket and stabilisation was done using splinting. Followup was done at regular intervals of one and 3 months which showed no resorption or perapical changes, lack of clinical symptoms

In conclusion, the management of avulsed and midroot fractured teeth requires long-term treatment strategies. Favorable outcomes can be achieved, preserving tooth function, and esthetics in patients with traumatic dental injuries.

Keywords: Tooth avulsion, Traumatic injury, Replantation.

INTRODUCTION:

Dental avulsion, the complete displacement of a tooth from its socket, is a traumatic dental injury that requires immediate attention. Dental avulsion most commonly occurs due to traumatic incidents such as sports injuries, falls, or accidents. Avulsion of permanent teeth is relatively rare and varies from 0.5% to 16% in all traumatic dental injuries.^[1] Maxillary central incisors are the most commonly involved teeth due to their prominent position in the arch. ^[1]Certain predisposing factors like protruded maxillary incisors and insufficient lip closure may affect the extent of the dental trauma.^[2] Replantation is, in most situations, the treatment of choice but cannot always be carried out immediately. Appropriate emergency management and a treatment plan are important for a good prognosis.^[3] Also, a retrospective

study in children has confirmed that the replantation procedure has a long-term survival rate (79.3%) in accordance with the treatment guidelines prescribed by the International Association of Dental Traumatology (IADT).^[1] General health of the patient, maturity of the root apex, storage medium, and extra-oral time are the factors that affect the successful outcome of the replantation procedure.^[1]

The primary goal in treating an avulsed tooth is to preserve and treat the supporting tooth tissues and to replant the avulsed teeth. The success of replantation depends on the patient's general health, the maturity of the root, the time the tooth is out of its socket, and storage medium. The period of extra-oral time and the storage medium have the most critical effect on the status of the PDL cells.^[4] Delay in the replantation of avulsed incisors increases the risk of dentoalveolar ankylosis and replacement root resorption.^[5]

Horizontal root fractures (HRFs) involve cementum, dentine, dental pulp, bone, and periodontium. HRFs predominantly occur in mature upper incisors. Predisposing factors of HRFs could be related to the person's anatomic features, i.e., an increased overjet and inadequate lip coverage of upper anterior teeth. When compared with other forms of dental injuries, the incidence of HRFs in permanent dentition is 7.7% of all kinds of dental traumas. HRFs are usually caused by direct physical impact to the tooth, i.e., sport activities, falls, and traffic accidents.^[6] Based on the location of the fracture line, HRFs can be classified as cervical, medium, and apical, with possible dislocation of fragments.^[6] The prognosis of fractured tooth depends on many factors like age of the patient, maturity of root formation; time elapsed between trauma and treatment, site of fracture and approximation of the fractured fragments. Fractures in the cervical 1/3rd have a guarded prognosis, while those in middle and apical third have a better prognosis. The immediate treatment involves splinting and stabilization of the fractured root and is successful in approximately 80% cases with middle and apical root fractures. Endodontic treatment may be required in cases with irreversible pulpitis, necrosis or when considerable time has elapsed between treatment and trauma.^[7]

MTA has widely changed the traditional approaches as it has shown good clinical results in the treatments of open apices, Root resorption, root perforations, and inflamed/exposed vital pulps^[7, 8] Currently, MTA is being used in endodontic procedures for the management of intra-alveolar HRFs and orthograde root filling approach.^[6]

Mineral Trioxide aggregate (MTA) has been used multifariously in endodontics especially in cases where regeneration of cemental tissues is required, as perforation repair and root end filling.^[6] MTA has also been used successfully in cases of root fractures, apexification, apexogenesis and reinforcing structurally weakened teeth having compromised radicular dentin thickness.^[7] Recently, MTA based root canal sealer (Fillapex, Angelus) has been introduced which has advantages like better handling, faster setting and good sealing ability.^[7]

The present case reports discusses the management and follow-up of an avulsed tooth and healing after the use of MTA based sealers in management of avulsed and horizontal root fracture cases.

Case Report 1 -

Patient of age 35 years reported to Department of Conservative Dentistry and Endodontics with avulsed tooth in upper front tooth region and complains of pain in the same region. Patient gives history of fall from 2 wheeler 2 hours back.

Medical History – No Relevant History

Clinical examination - showed empty socket-21(fig-1), tender on percussion -11 and 22. Laceration of the gingiva and lips are noted. Pulp vitality was negative for 11,21. Grade 1 mobility noted -22

Radiographic findings- empty socket without any root fragment was noted-21, Middle third root fracture -22(fig-2)

Treatment plan- Reimplantation of the avulsed tooth-21 followed by splinting from 13 to 23 , Root canal treatment -22

Procedure- Avulsed tooth(fig-3) was irrigated with saline to remove the dust and debris, by holding only the coronal portion of the tooth , the socket was irrigated with the saline , extraoral root canal treatment of 21 was done. After the completion of root canal treatment-21 the tooth was gently inserted back to the socket and radiograph was taken-21. After the radiographic confirmation of the position of the tooth and occlusion was checked to avoid any traumatic contact with the opposing teeth.(fig-4,5) Then the splinting was carried out from 13 to 23, Using splinting wire and the composite.(fig-6,7) Instructions were given to the patient and recalled next day for the treatment of 22.

2nd Appointment- radiograph was taken to confirm mid root fracture -22. The root canal treatment was carried out using MTA sealer -22 and temporized with ZOE.(fig-8) Instructions were given. Patient was asked to report back after 1 month for followup.

Follow-up -1 month followup radiograph showed non periapical changes -21,22. Laceration on the gingiva and lips were healed.(fig-9,10) And patient was symptom free. Patient asked to report back after 2 weeks for splint removal.

6 month followup showed no mobility and on radiographic examination no sign of resorption, no periapical changes noted. (Fig-11,12)

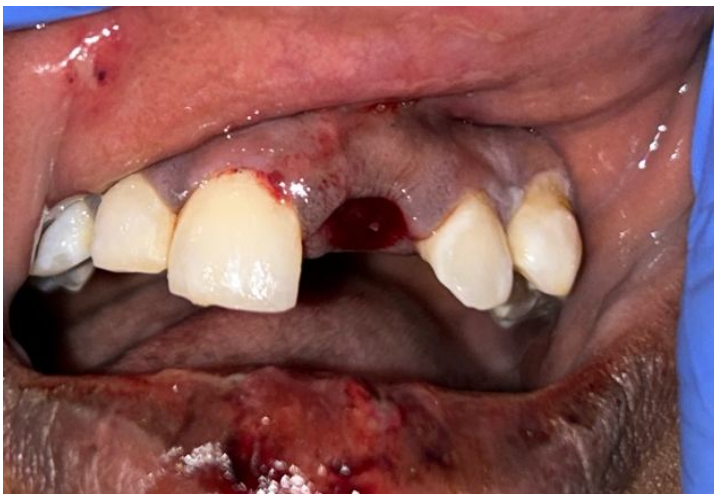

Fig 1- Preoperative picture of empty bleeding socket -21

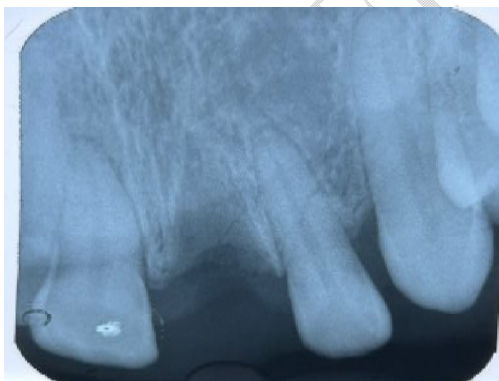


Fig 2 – preoperative radiograph showing empty socket without any root fragment-21, horizontal root fracture in middle third of -22

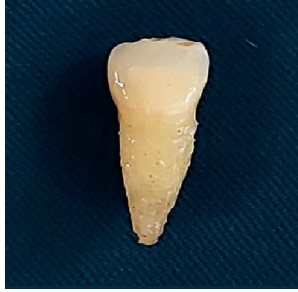

Fig3 – Avulsed tooth -22

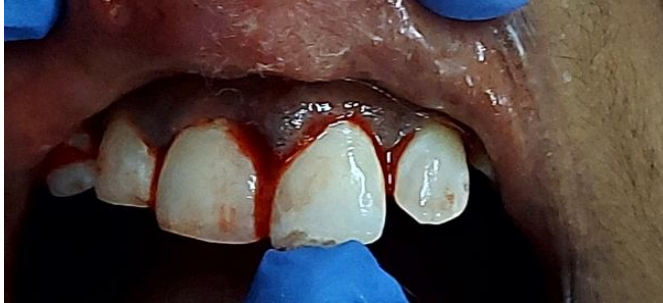

Fig 4 – Repositioning of the Avulsed tooth into the socket

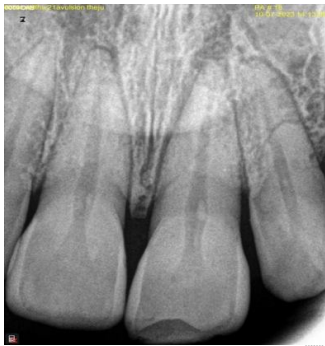

Fig- 5- Confirmation radiograph of repositioning of avulsed tooth -21

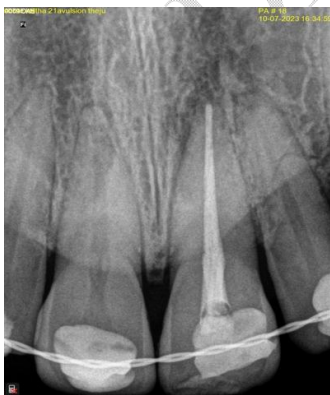

Fig -6 -Splinting from canine to canine

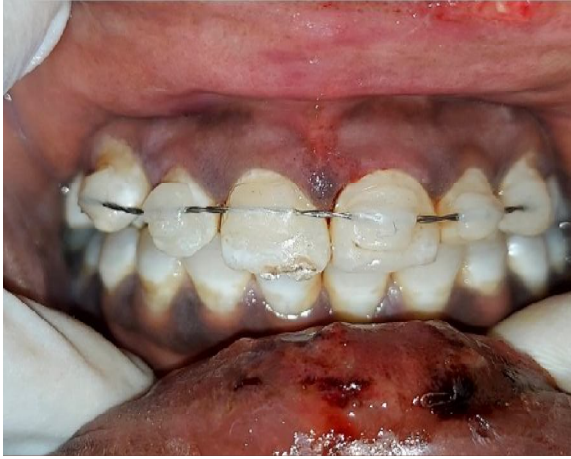

Fig-7 Intraoral picture of splinting from canine to canine

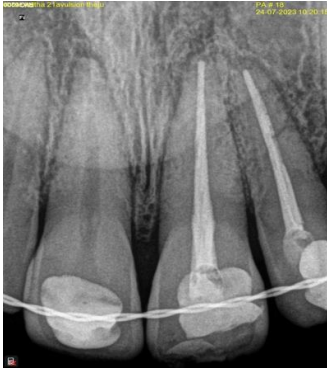

Fig-8 – root canal treatment completed -22

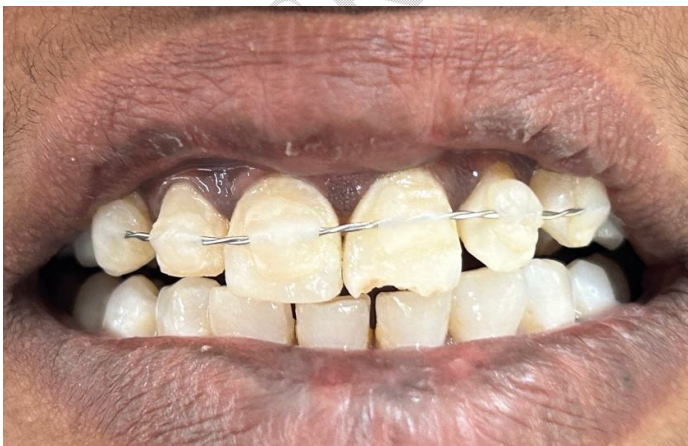

Fig – 9- One month post operative intraoral picture showing healing of lacerations

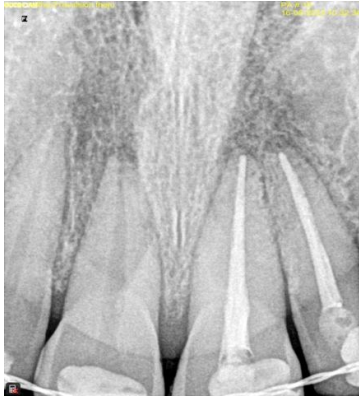

Fig-10 - One month followup radiograph

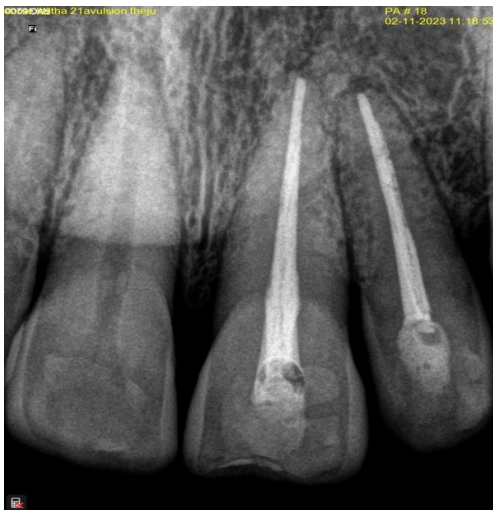

Fig-11 -3 months follow up radiograph with no periapical changes

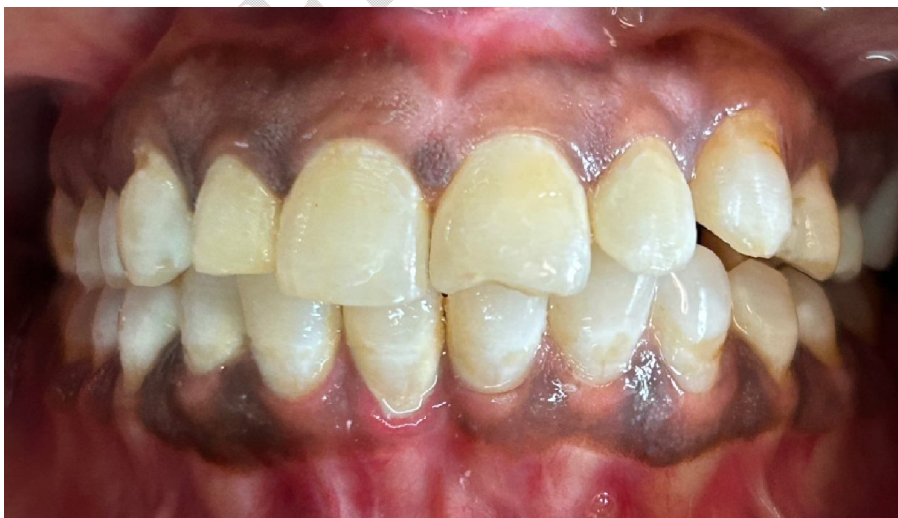

Fig-12 Intraoral picture after splint removal.

Case report 2 -

Patient of age 16 years reported to Department of Conservative Dentistry and Endodontics with avulsed tooth in upper front tooth region and complains of pain in the same region.

History - Patients gives history of fall 24 hours back. And kept the avulsed tooth in milk.

Medical History – No Relevant History

Clinical Examination showed empty socket with blood clot -22 . (fig-13.a)

Radiographic findings- empty socket without any root fragment was noted-22.(fig-13.b)

Treatment plan- Reimplantation of the avulsed tooth-22 followed by splinting from 12 to 23.

Procedure- Avulsed tooth(fig-13.c) was irrigated with saline to remove the dust and debris, by holding only the coronal portion of the tooth , the socket was irrigated with the saline , extraoral root canal treatment of 22 was done(fig-14). After the completion of root canal treatment-22 the tooth was gently inserted back to the socket(fig-15) and radiograph was taken-22(fig-16). After the radiographic confirmation of the position of the tooth and occlusion was checked to avoid any traumatic contact with the opposing teeth. Then the splinting was carried out from 12 to 23(fig-17), Using splinting wire and the composite. Instructions were given to the patient and recalled after 1 month for followup.

Follow-up- 1 month followup radiograph showed non periapical changes -22(fig-18). And patient was symptom free. Patient asked to report back after 2 weeks for splint removal. (fig-19) Next appointment – 3 months Followup radiograph(fig-20) was taken which showed no signs of resorption or radiolucency-22, Composite restoration done – 22(fig-21).

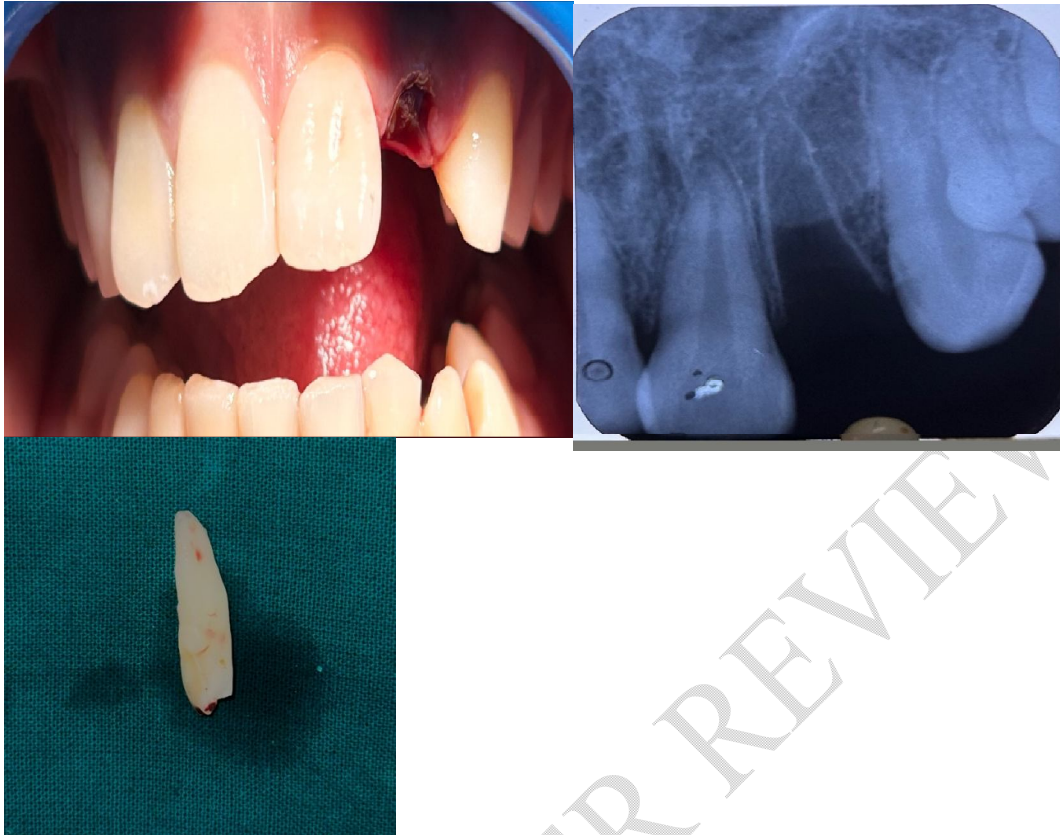

Fig 13.a preoperative picture showing empty space near 22 region 13.b shows empty socket without any fractured root fragment, 13.c Avulsed tooth

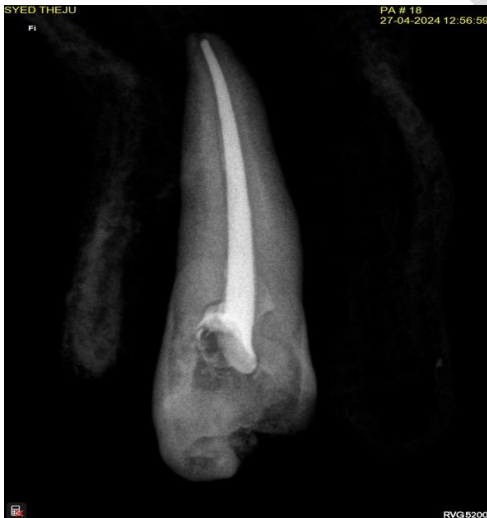

Fig 14- Extraoral RCT-22

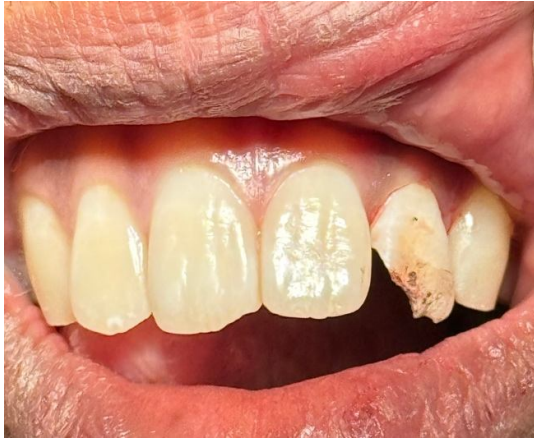

Fig-15 Reimplantation of 22 into the socket

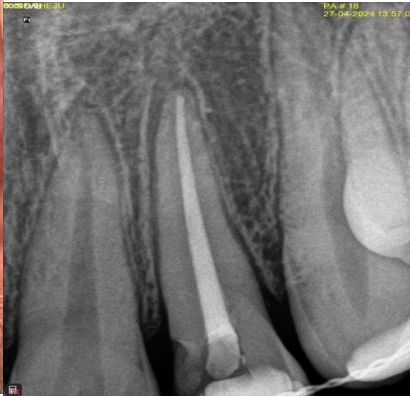

Fig-16 Radiographic confirmation of 22 position in the socket

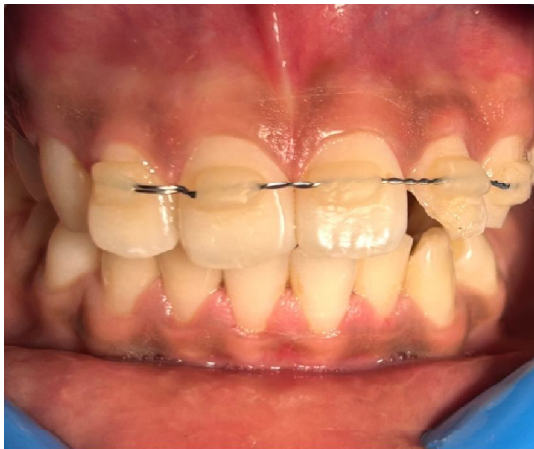

Fig -17 Splinting from 12 to 23

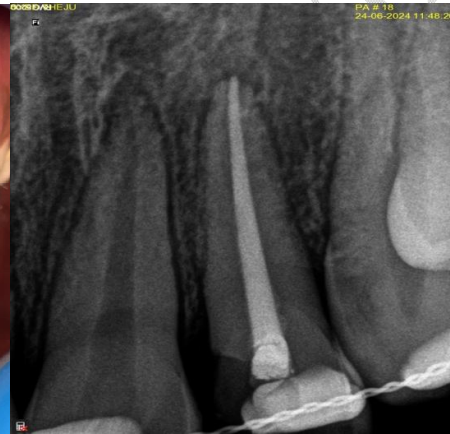

Fig 18- one month follow up

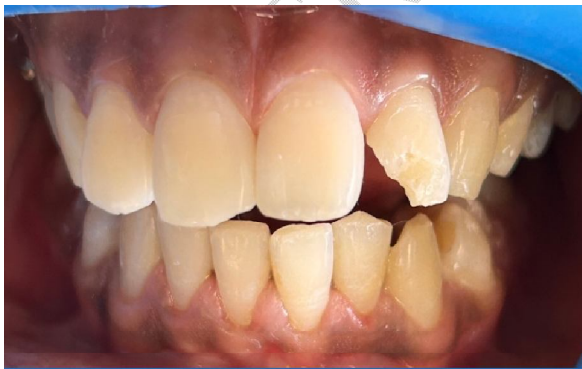

Fig - 19 Splint removal done after 6 weeks

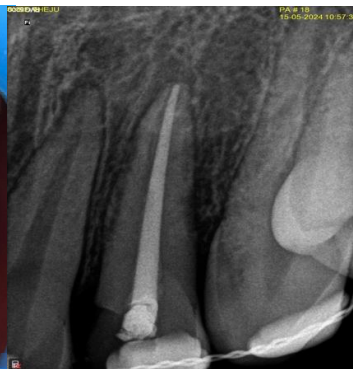

Fig-20 3months followup radiograph

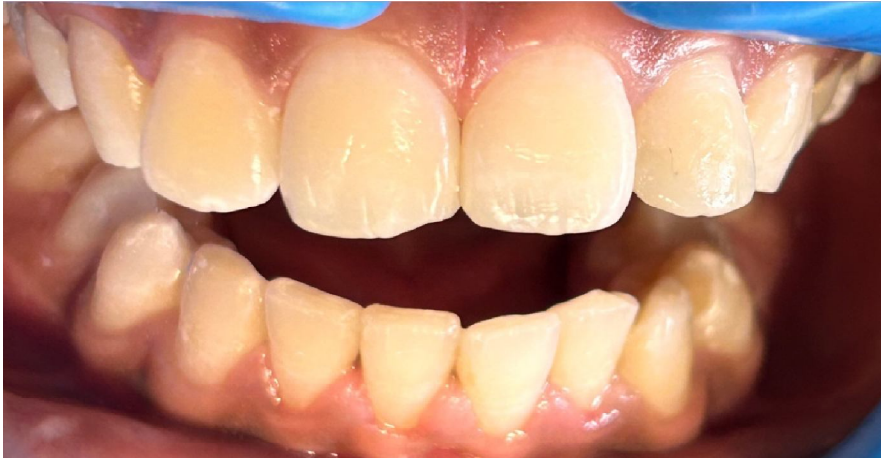

Fig-21 Composite restoration done -22

Discussion

The occurrence of dental avulsion, or the complete displacement of a tooth from its socket, is relatively low compared to other dental injuries. The prevalence of avulsion can vary based on several factors, including age, gender, and activities that carry a higher risk of dental trauma. Studies have reported that dental avulsion represents a small percentage of all dental injuries. The incidence is often higher in younger age groups, particularly in children and adolescents who are more active in sports and recreational activities. According to some studies, dental avulsion accounts for approximately 0.5% to 3% of all dental injuries.

Middle third root fractures pose unique challenges in dental traumatology, requiring precise management to preserve tooth and structural integrity. This article explains the comprehensive approach of utilizing Mineral Trioxide Aggregate (MTA) sealer in conjunction with a 6-week splinting protocol for effective management of middle third root fractures. Middle third root fractures typically involve the dental pulp and root canal space, often resulting from traumatic incidents. These fractures can compromise both the functional and aesthetic aspects of the affected tooth, necessitating immediate attention and an appropriate treatment strategy. Upon presentation of a patient with a middle third root fracture, a thorough clinical and radiographic assessment is crucial. This includes evaluating the extent of the fracture, the stability of the tooth, and the involvement of surrounding structures. MTA Sealer Application: Mineral Trioxide Aggregate (MTA), known for its

biocompatibility and sealing properties, has become a cornerstone in endodontic therapy. In cases of middle third root fractures, MTA sealer is applied strategically to achieve several objectives: Sealing the Fracture Line: Encouraging Dentin Bridge Formation:, Biological Compatibility. Splinting Protocol: A carefully planned splinting protocol plays a pivotal role in the success of middle third root fracture management. A 6-week splinting period is often recommended.

Immobilizing the fractured tooth is crucial to prevent further displacement and promote healing. A flexible splinting material is preferred to minimize stress on the injured tooth.

Regular clinical monitoring during the splinting period helps assess the healing progress, stability, and the need for any adjustments in the treatment plan.

Post-Splinting Evaluation: Following the 6-week splinting period, a comprehensive evaluation is conducted to assess the healing response, stability, and overall health of the tooth. Radiographic examinations are employed to confirm dentin bridge formation and the absence of periapical pathology.

The ideal splinting period for avulsion and middle third tooth fractures may vary depending on several factors, including the extent of the injury, the type of treatment rendered, and the individual patient's response to the intervention. Generally, splinting is employed to stabilize the affected tooth or teeth, allowing for healing and preventing further damage.

The use of a splint is determined by the stability of the tooth and the treatment rendered. In cases where a flexible splint is employed, the ideal splinting period is often around 4 to 6 weeks. This duration allows for initial healing and stabilization of the fractured tooth.

The post-splinting period involves clinical and radiographic evaluations to assess the tooth's response to treatment, including dentin bridge formation and resolution of any periapical pathology.

Conclusion -Dental avulsion is a dental emergency that requires immediate attention. Being aware of the causes, taking prompt action, and adopting preventive measures can contribute to better outcomes in cases of dental avulsion. Timely intervention , accurate diagnosis and appropriate management strategies are essential for achieving the best possible outcomes. As seen above even though the extraoral time was more, in 3 months follow up there was no signs of resorption or ankylosis. The treatment can be considered successful with favourable prognosis.

Ethical Approval:

As per international standards or university standards written ethical approval has been collected and preserved by the author(s).

Consent

As per international standards or university standards, patient(s) written consent has been collected and preserved by the author(s).

Disclaimer (Artificial intelligence)

Author(s) hereby declare that NO generative AI technologies such as Large Language Models (ChatGPT, COPILOT, etc.) and text-to-image generators have been used during the writing or editing of this manuscript.

References

1. Kadulkar N, Katak R, Deka A, Thonai S. Replantation of an Avulsed Tooth: A Case Report. Cureus. 2023 May 18;15(5):e39198.
2. Ram D, Cohenca N. Therapeutic protocols for avulsed permanent teeth: review and clinical update. Pediatric dentistry. 2004 May 1;26(3):251-5.
3. Fouad AF, Abbott PV, Tsilingaridis G, Cohenca N, Lauridsen E, Bourguignon C, O'Connell A, Flores MT, Day PF, Hicks L, Andreasen JO. International Association of Dental Traumatology guidelines for the management of traumatic dental injuries: 2. Avulsion of permanent teeth. Dental traumatology. 2020 Aug;36(4):331-42.
4. SelcukSavas, EbruKucukyilmaz, MerveAkçay, SerhatKoseoglu, "Delayed Replantation of Avulsed Teeth: Two Case Reports", Case Reports in Dentistry, vol. 2015, Article ID 197202,

5. SaharAmeli,KarimJafari,FirouzZadfatah,MehrdadBlurianandSomayehHekmatfar
Delayed Replantation of Avulsed Teeth: A Case Report. Zahedan Journal of Research
in Medical Sciences.;23(2):e95795.

6. Asgary S, Mirmohammadi H, Parhizkar A. Management of Symptomatic Horizontal
Mid-root Fractures after Unsuccessful Orthograde Endodontic Retreatments. Cureus.
2019 Aug 24;11(8):e5473. doi: 10.7759/cureus.5473. PMID: 32175201;

7. Rhythm Bains, Pranab Mishra,Kapil Loombaand Anju Loomba. Management of a
mid-root Horizontal fracture using Ni-Ti file and MTA based sealer: Twoyear follow-
up. Asian Journal of Oral Health & Allied Sciences 2014, Volume 4, Issue.