

# Case report

## Anatomical snuffbox lipomas: Particularities and Surgical management

---

### ABSTRACT

Lipomas are among the most common benign soft tissue tumors of the body. They are commonly encountered in neck, trunk and upper extremity. Hand localization remains rare and only represents 1% to 3.8% of cases.[1] Anatomical Snuffbox (Radial Fossa) lipoma are exceptional. Management of anatomical snuffbox lipomas may be challenging due to its particular anatomy.

In this article we will discuss the surgical approach to anatomical snuffbox lipomas through two cases.

*Keywords: Lipoma, Anatomical snuffbox, Radial Fossa, Tumor, Radial nerve, Radial Artery, Extensor.*

### 1. INTRODUCTION:

Lipomas are among the most common benign soft tissue tumors of the body. They are commonly encountered in neck, trunk and upper extremity. Hand localization remains rare and only represents 1% to 3.8% of cases.[1] Anatomical Snuffbox lipoma (ASL) are exceptional. Management of anatomical snuffbox lipomas may be challenging due to its particular anatomy.

In this article we will discuss, through two cases, the particularities and the surgical approach to ASL.

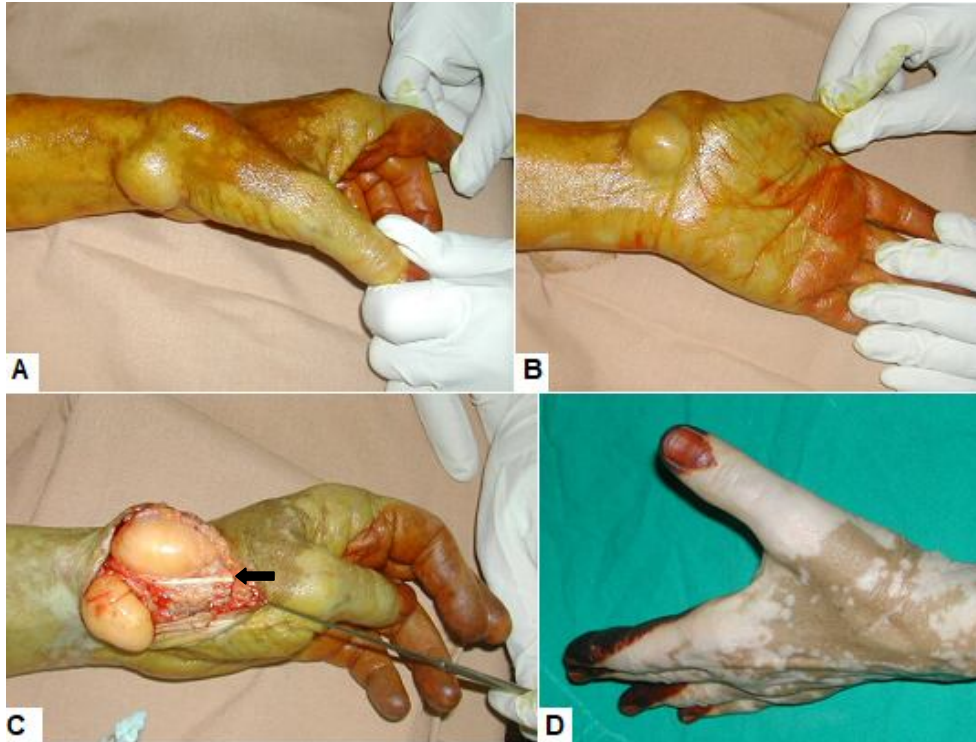
### 2. PRESENTATION OF CASES:

#### 2.1 Case 1:

A 71-year-old female patient with a history of vitiligo presents with a tumor of the anatomical snuffbox of the left hand, evolving for 2 years. Patient described paresthesia at the level of first web space.

Clinical examination showed a well-circumscribed, mobile soft tumor. Pseudo-Tinel sign (tingling sensation upon percussing the nerve) was positive. Posch sign (hardening and shrinking of the tumor after ice application) was positive. The X-ray of the hand was normal. Ultrasound examination suspected the diagnosis of lipoma.

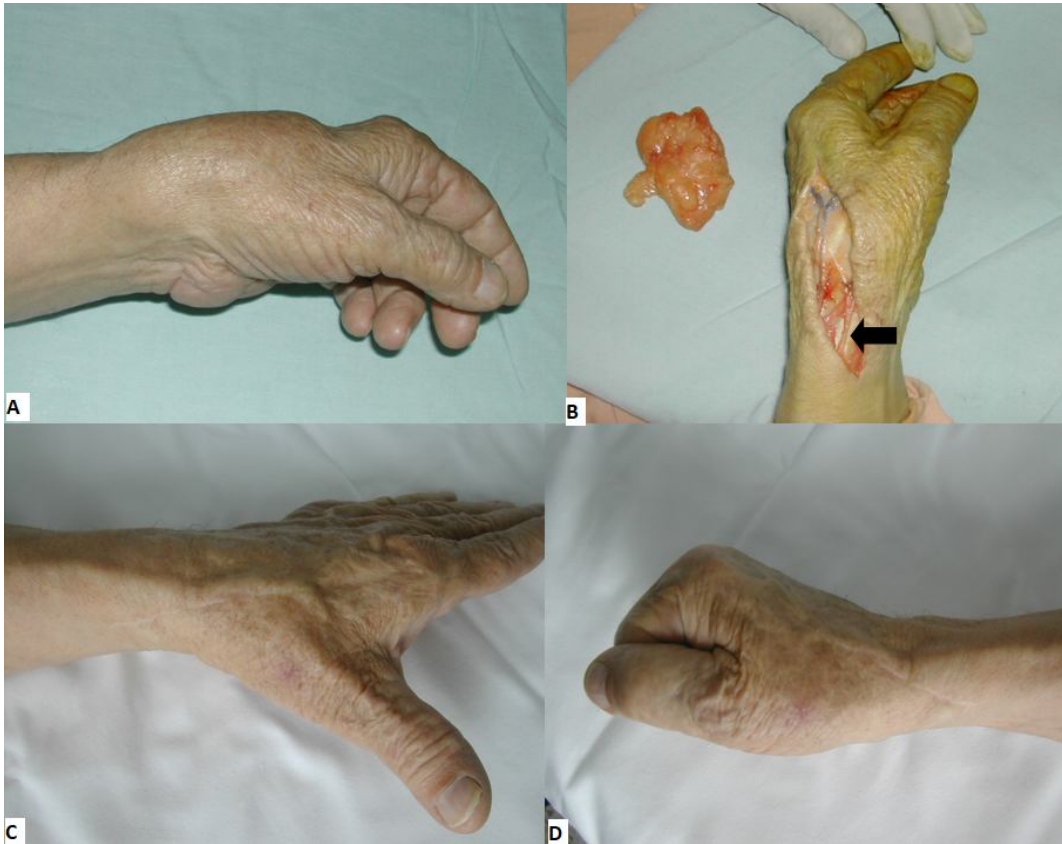Intraoperative findings revealed fatty yellowish tumor displacing the sensory branch of the radial nerve (SBRN). The histopathological examination confirmed the diagnosis of a lipoma.



**Fig. 1. A+B: Clinical presentation of a lipoma of the anatomical snuffbox  
C: Intraoperative findings: Lipoma Displacing the SBRN (Arrow). D: 3 months post operative.**

### **2.1 Case 2:**

A 68-year-old male patient with no prior medical history presents with a swelling in the anatomical snuffbox of the left hand. Patient complains of paresthesia at the level of the first web space. Clinical examination reveals a soft and mobile tumor. Posch and Tinel's sign were positive. Ultrasound examination suggested a lipoma. Intraoperative findings showed a fatty tumor displacing the SBRN. Histopathological examination confirmed a lipoma.



**Fig. 2. A: Clinical presentation of a lipoma of the anatomical snuffbox. B: Intraoperative findings: Lipoma Displacing the SBRN (Arrow). C+D: 1 year post operative.**

### **3. DISCUSSION:**

#### **3.1 History:**

The earliest description of the term anatomical snuff box comes from a text written by the French doctor Xavier Bichat in 1850. Afterwards, this term was introduced into anatomy textbooks as the “Tabatière anatomique de Cloquet” or the anatomical Snuffbox of Cloquet. The name comes from using this depression on the dorsum of the hand to place and inhale the powdered tobacco in 19th century.[2]

#### **3.2 Anatomy:**

The hand is a small, densely packed area containing a complex network of tiny and delicate structures. It is highly represented in Penfield’s Cortical Homunculus. The hands occupy a significant portion of both the motor and sensory cortices. This reflects the hand’s delicate and intricate anatomy.[3] Therefore, hand surgery requires a deep understanding of the hand’s complex anatomy and a high level of precision.

The anatomical snuffbox is a triangular hollow on the dorsum of the hand that becomes prominently visible upon thumb abduction and wrist extension and ulnar deviation.

It is bounded radially by the tendons of the *Extensor pollicis brevis* and the *Abductor pollicis longus*, and medially by the tendon of the *Extensor pollicis longus*. The floor is formed by the base of the first metacarpal bone distally, the styloid process of the radius proximally, scaphoid and trapezium bones. Through it passes the radial artery, the superficial branch of the radial nerve (SBRN) and the cephalic vein.[4]

SBRN is responsible of the innervation of the dorsum of the hand and of the two and a half digits from the radial aspect of the hand.[5]

### **3.1 Lipoma:**

#### **3.1.1 Diagnosis:**

Lipoma is a fatty tumor that is usually soft, mobile, painless, well-circumscribed and respects local structures.[6]

Histologically, lipomas appear as well-delineated masses composed of mature adipocytes separated by thin fibrous septa in within blood vessels may be present.[7]

On ultrasound, lipomas generally appear as well-defined, hypoechoic masses with a homogeneous echotexture. They are typically characterized by a smooth, lobulated margin and may have an echogenic capsule surrounding them. The internal structure is usually uniform, and there is often no significant vascularity within the lipoma on Doppler imaging.[8]

On MRI, lipomas typically appear as well-circumscribed, homogeneous masses with a signal intensity similar to subcutaneous fat across all imaging sequences. In STIR (Short Tau Inversion Recovery) sequences, the fat signal of lipomas is suppressed, which helps in differentiating them from surrounding tissues. Internal septa, if present, show low signal intensity on T1- and T2-weighted images.[9]

Etiology of Lipoma is still unknown, many theories including trauma, obesity and genetics are proposed.[10]

Posch described a test to guide the clinical diagnosis of lipoma. It consists on a hardening and shrinking of the tumor after ice application.[11]

Hand is an unusual localization of lipomas. They can appear anywhere on the hand, typically presenting on the palmar aspect of the hand.

Hand lipomas are usually small ranging from 3-5 cm. Giant lipomas are defined by a size greater than 5cm.[12]

Due to the intricate anatomy of the hand, Lipomas can cause paresthesia, discomfort and movement restriction when they grow near a nerve, a tendon or an articular zone.

Tinel sign is a tingling elicited by tapping on a nerve proximally with paresthesia in the corresponding cutaneous territory of the nerve. It indicated nerve irritation or injury.[13]

Depending on its location, lipoma can lead to: Carpal tunnel syndrome (Median nerve compression)[14,15], Guyon's canal syndrome (Ulnar nerve compression)[16], Digital nerve compression[17,18], Trigger finger (*flexor digitorum* tendon compression)...

When the size of the lipoma exceeds a functional unit of the hand, it can cause movement impairment : limited opposition of the thumb[19], limited flexion of finger[20]...

However, only one case report of anatomical snuffbox lipoma is reported.[21]

Patients with ASL may experience paresthesia in the first web space / dorsal aspect of the thumb, and mechanical discomfort due to the possible tendinous compression.

#### **3.1.2 Differential Diagnosis:**

Hand tumors comprise a vast array of lesions including cutaneous, cystic, nervous, vascular, fibrous ... tumors. The majority of tumors in the hand are benign.[6]

Some authors suggest an excision of giant lipoma ( $\geq 5\text{cm}$ ) due to its risk of transformation.[12]

The most common malignant differential diagnosis of adipocytic neoplasm is Liposarcoma.

Liposarcoma is mainly seen in middle-aged adults and clinically suspected in the case of a rapidly progressive tumor that invades local structures.[22]

MRI is valuable in case of malignancy suspicion. It evaluates the size and extension of the tumor to the adjacent structures. Liposarcoma contains less fat than benign Lipoma. It can contain multiple non-fatty nodules. Additionally, MRI allows for the analysis of the internal septa of the tumor: the septa of lipomas are very thin, slightly enhanced with gadolinium, corresponding histologically to fibrosis. In contrast, liposarcomas exhibit thickened septum-like septa corresponding to muscular fibers.[9]

Liposarcoma can be well-differentiated or poorly differentiated. Well-differentiated liposarcoma, or atypical lipomatous tumor (ALT), can have a misleading histological appearance that resembles a lipoma-like tumor.[12]

Advances in molecular biology have shed light on additional genomic alterations to differentiate benign Lipoma from ALT.[23–25]

Mouse Double Minute 2 (MDM2) is a protein that plays a significant role in regulating the p53 tumor suppressor pathway. It is a crucial tumor suppressor protein involved in regulating cell cycle, apoptosis, and DNA repair. MDM2 is often overexpressed and amplified in well-differentiated liposarcoma and dedifferentiated liposarcoma. This overexpression can lead to the inhibition of p53.[23–25]

Elevated levels of MDM2 can also be associated with a more aggressive disease course and poorer prognosis. MDM2 has been targeted in therapeutic approaches and are being explored as potential treatments for liposarcoma and other cancers with MDM2 overexpression. [26,27]

### **3.1.3 Surgical approach:**

in our cases, surgery is performed under locoregional anesthesia with the use of a tourniquet. General anesthesia or WALANT (Wide Awake Local Anesthesia No Tourniquet) surgery can be used.

WALANT surgery has evolved significantly in recent years. We did not use WALANT surgery due to the non-availability of Epinephrine Antidote.[28]

An arciform incision centered on the tumor is done.

Dissection is carried out to expose proximally the SBRN. A particular attention to not traumatize the nervous, arterial and tendinous structures. The dissection must follow the course of the normal nerve towards the lesion from proximal and distal directions. The nerve is then protected using a surgical loop or a fine Farabeuf retractor after its complete identification and exposure.

We recommend the use of magnification to preserve nerve structures and the use of small and precise instruments specially scissors (such as Steven's scissor) allowing delicate and fine dissection. Blunt dissection can be useful in some cases.

These recommendations can also be applied for tendinous and vascular structures

## **4. CONCLUSION**

Anatomical snuffbox lipomas are exceptional. surgical excision must be meticulous to avoid damaging the surrounding anatomical structures.

## **DISCLAIMER (ARTIFICIAL INTELLIGENCE)**

Author(s) hereby declare that NO generative AI technologies such as Large Language Models (ChatGPT, COPILOT, etc) and text-to-image generators have been used during writing or editing of manuscripts.

## CONSENT

As per international standards or university standards, patient(s) written consent has been collected and preserved by the author(s).

## ETHICAL APPROVAL

As per international standards or university standards written ethical approval has been collected and preserved by the author(s).

## REFERENCES

1. Lichon S, Khachemoune A. Clinical presentation, diagnostic approach, and treatment of hand lipomas: a review. *Acta Dermatovenerologica Alpina Pannonica et Adriatica* [Internet]. 2018 [cited 2024 Aug 19];27. Available from: <http://acta-apa.mf.uni-lj.si/journals/acta-dermatovenerol-apa/papers/10.15570/actaapa.2018.27/actaapa.2018.27.pdf>
2. Seidenberg AB, Halperin EC, Goldstein AO. It's time to snuff out the "anatomical snuff box." *Acad Med*. 2015;90:1003–4.
3. Gandhoke GS, Belykh E, Zhao X, Leblanc R, Preul MC. Edwin Boldrey and Wilder Penfield's Homunculus: A Life Given by Mrs. Cantlie (In and Out of Realism). *World Neurosurgery*. 2019;132:377–88.
4. Robson AJ, See MS, Ellis H. Applied anatomy of the superficial branch of the radial nerve. *Clinical Anatomy*. 2008;21:38–45.
5. Hallett S, Jozsa F, Ashurst JV. Anatomy, Shoulder and Upper Limb, Hand Anatomical Snuff Box. *StatPearls* [Internet] [Internet]. StatPearls Publishing; 2023 [cited 2024 Aug 24]. Available from: <https://www.ncbi.nlm.nih.gov/books/NBK482228/>
6. Mavrogenis AF, Panagopoulos GN, Angelini A, Lesenský J, Vottis C, Megaloikononimos PD, et al. Tumors of the hand. *Eur J Orthop Surg Traumatol*. 2017;27:747–62.
7. A C, Ce A, T B. Lipoma Pathology [Internet]. *PubMed*. 2024 [cited 2024 Aug 24]. Available from: <https://pubmed.ncbi.nlm.nih.gov/29493968/>
8. Rahmani G, McCarthy P, Bergin D. The diagnostic accuracy of ultrasonography for soft tissue lipomas: a systematic review. *Acta Radiologica Open*. 2017;6:205846011771670.
9. Drevelegas A, Pilavaki M, Chourmouzi D. Lipomatous tumors of soft tissue: MR appearance with histological correlation. *European Journal of Radiology*. 2004;50:257–67.
10. Lichon S, Khachemoune A. Clinical presentation, diagnostic approach, and treatment of hand lipomas: a review. *Acta Dermatovenerologica Alpina Pannonica*

et Adriatica [Internet]. 2018 [cited 2024 Aug 24];27. Available from: <http://acta-apa.mf.uni-lj.si/journals/acta-dermatovenerol-apa/papers/10.15570/actaapa.2018.27/actaapa.2018.27.pdf>

11. Pertea M, Lunca S, Filip A, Moraru DC, Carp C, Pinzaru R, et al. Atypical Sites of the Lipoma on the Hand and Fingers: Clinical and Imaging Features and Surgical Outcomes. *Diagnostics*. 2022;12:2286.

12. Fnini S, Hassoune J, Garche A, Rahmi M, Largab A. Lipome géant de la main : présentation d'un cas clinique et revue de la littérature. *Chirurgie de la Main*. 2010;29:44–7.

13. Ho T, Braza ME. Hoffmann Tinel Sign. StatPearls [Internet] [Internet]. StatPearls Publishing; 2022 [cited 2024 Aug 26]. Available from: <https://www.ncbi.nlm.nih.gov/books/NBK555934/>

14. Sbai MA, Benzarti S, Msek H, Boussen M, Khorbi A. Carpal tunnel syndrome caused by lipoma: a case report. *Pan Afr Med J [Internet]*. 2015 [cited 2024 Aug 24];22. Available from: <http://www.panafrican-med-journal.com/content/article/22/51/full/>

15. Barreira M, Marques N, Campos V, Marques G, Gonçalves S, Stefanova Alves S. A giant hand lipoma as a rare cause of secondary carpal tunnel syndrome - A case report. *International Journal of Surgery Case Reports*. 2020;77:538–42.

16. Rohilla S, Yadav RK, Dhaulakhandi DB. Lipoma of Guyon's canal causing ulnar neuropathy. *J Orthopaed Traumatol*. 2009;10:101–3.

17. Hu Z, Yue Z, Tang Y, Zhu Y. Lipoma of the middle finger: A case report and review of literature. *Medicine*. 2017;96:e8309.

18. Hu Z, Yue Z, Tang Y, Zhu Y. Lipoma of the middle finger: A case report and review of literature. *Medicine*. 2017;96:e8309.

19. Boussouga M, Bousselmame N, Lazrak K-H. Lipome compressif de la loge thenar. À propos d'une observation. *Chirurgie de la Main*. 2006;25:156–8.

20. Inamura E, Kitamura S, Maeda T, Yanagi T. A rare site of subcutaneous lipoma on the middle finger: Case report and analysis of affected sites in 126 cases at a single institution. *Dermatologic Therapy [Internet]*. 2021 [cited 2024 Aug 24];34. Available from: <https://onlinelibrary.wiley.com/doi/10.1111/dth.14973>

21. Amar MF, Benjelloun H, Ammoumri O, Marzouki A, Mernissi FZ, Boutayeb F. Lipome compressif de la tabatière anatomique. À propos d'un cas. *Annales de Chirurgie Plastique Esthétique*. 2012;57:409–11.

22. Mavrogenis AF, Panagopoulos GN, Angelini A, Lesenský J, Vottis C, Megaloikononimos PD, et al. Tumors of the hand. *Eur J Orthop Surg Traumatol*. 2017;27:747–62.

23. Sciot R. MDM2 Amplified Sarcomas: A Literature Review. *Diagnostics*. 2021;11:496.
24. Demicco EG. Molecular updates in adipocytic neoplasms☆. *Seminars in Diagnostic Pathology*. 2019;36:85–94.
25. Natella R, Varriano G, Brunese MC, Zappia M, Bruno M, Gallo M, et al. Increasing differential diagnosis between lipoma and liposarcoma through radiomics: a narrative review. *Exploration of Targeted Anti-tumor Therapy*. 2023;498–510.
26. Alaseem AM. Advancements in MDM2 inhibition: Clinical and pre-clinical investigations of combination therapeutic regimens. *Saudi Pharmaceutical Journal*. 2023;31:101790.
27. Makii C, Oda K, Ikeda Y, Sone K, Hasegawa K, Uehara Y, et al. MDM2 is a potential therapeutic target and prognostic factor for ovarian clear cell carcinomas with wild type TP53. *Oncotarget*. 2016;7:75328–38.
28. Moog P, Dozan M, Betzl J, Sukhova I, Kükrek H, Megerle K. WALANT–Epinephrine injection may lead to short term, reversible episodes of critical oxygen saturation in the fingertips. *Arch Orthop Trauma Surg*. 2021;141:527–33.