

# Case report

## Maxillary Acanthomatous Ameloblastoma in Dog: Case Report

---

### ABSTRACT

This report aims to describe a case of acanthomatous ameloblastoma in the central region of the left maxilla in a dog that had a history of sialorrhea and hyporexia. A 12-year-old Shih Tzu dog weighing 5 kg was treated at a veterinary clinic specializing in veterinary dentistry. The animal had an increase in volume in the left maxilla caused by a pink mass with irregular contours. The animal had difficulty eating and was progressively losing weight. Imaging tests revealed displacement of the teeth affected by the tumor mass, without bone involvement. In the histopathological examination the mass was compatible with acanthomatous ameloblastoma. The treatment of choice was surgical removal. In the postoperative evaluation the dog presented dehiscence of the suture and underwent reintervention to perform a new suture. In the immediate postoperative period, the animal remained active. Although adult dogs, of medium to large size, are the most affected by this type of tumor, this work demonstrates that small breeds can also develop the disease. The location of the tumor reported here also differs from that commonly reported in the literature. The full recovery of patients affected by acanthomatous ameloblastoma will depend on the ability to perform an appropriate clinical-surgical approach, seeking excision of the tumor with free margins and correct postoperative follow-up.

*Keywords: Odontogenic Tumors; Oral Neoplasms; Oral Surgical Procedures; Veterinary Surgery.*

### 1. INTRODUCTION

The oral cavity is the fourth most common site of neoplasia in dogs, accounting for 6% of all tumors affecting these species [1], and generally affects animals over 7 years of age [2], with no racial predilection [3]. Canine acanthomatous ameloblastoma (CAA) is an odontogenic tumor with high prevalence in dogs [4,5]. Although it is a common oral lesion, CAA can become a serious condition, behaving in a locally infiltrative and disfiguring manner [6].

Its emergence may occur peripherally from within the gingival tissue (more common), or arise centrally from the periodontal ligament tissues adjacent to the tooth and bone (less common) [7]. Although technically a benign lesion with non-metastatic behavior, AAC can behave in a locally aggressive manner, often requiring a surgical block resection involving bone and soft tissues [8, 9, 10].

CAA can occur in any region, but a prevalence of 50% is observed in the rostral region of the oral cavity [11]. Macroscopically, it behaves as an irregular, gray to pink, exophytic or verrucous mass that appears immediately adjacent to the teeth, and may vary markedly in other cases, being confused with other common oral lesions in dogs such as squamous cell carcinoma, amyloid-producing ameloblastoma, fibromatous epulis of periodontal ligament origin, proliferative gingivitis, odontogenic cysts or gingival hyperplasia [7, 11].

When affected, dogs may present clinical signs such as halitosis, hemorrhage (spontaneous or postprandial, ingestion of beverages, chewing or playing with objects), sialorrhea, maxillofacial deformity, difficulty or pain when opening the mouth and progressive weight loss [12, 13]. Diagnosis is based on the animal's history, clinical signs and complementary exams such as imaging exams and fine needle aspiration. Definitive diagnosis is achieved through histopathological examination [14, 15]. Even though treatment options such as radiotherapy and intralesional bleomycin have been described, surgical excision with a gross margin of 1 cm is preferred and provides a better chance of cure without recurrence [16, 17].

Reports of ACC in the canine maxillary region, especially in the central/caudal region of the oral cavity, are less frequent, especially when taking into account the relevant details of a clinical-surgical approach. This study aims to report a case of canine acanthomatous ameloblastoma in the central region of the maxilla, highlighting its diagnosis, treatment and resolution of post-surgical complications.

## **2. PRESENTATION OF CASE**

A 12-year-old Shih Tzu dog weighing 5 kg was admitted to a veterinary clinic specializing in veterinary dentistry. The animal had an increase in volume in the left maxilla caused by a pink mass with irregular contours (figure 1), causing the animal difficulty in eating, sialorrhea and progressive weight loss.

On physical examination, the animal presented vital parameters within normal limits for the species and age. On palpation, the anatomical structures of the head appeared symmetrical, the superficial lymph nodes, especially the mandibular ones, were of normal size and consistency and showed no signs of discomfort to the touch. On inspection of the oral cavity, an increase in volume was observed in the central region of the left maxilla near the palatine surface of tooth 208, corresponding to the 4th premolar, which was already displaced to the vestibular region and extended rostrally to teeth 206, 207, corresponding to the 2nd and 3rd premolar teeth respectively, and caudally to tooth 209, corresponding to the 1st molar, affecting 4 teeth in total.

Since surgical treatment was chosen, preoperative tests were requested, such as a complete blood count, serum biochemical tests (urea, creatinine, alanine aminotransferase, alkaline phosphatase, glucose), face and chest radiographs, computed tomography (CT), electrocardiography and echocardiography, for planning the left central maxillectomy. The facial radiograph showed the displacement of the teeth affected by the tumor mass, without bone involvement, as well as the absence of metastases in thoracic structures on chest radiograph.

Surgical excision of the mass was initiated by taking digital intraoral radiographs. To perform the left central maxillectomy, the soft tissues (gingiva, oral mucosa, and palate) were incised with a No. 15 scalpel, maintaining a 1 cm margin, dividing the mucosa, and sectioning the bone with a No. 701 dental drill. Bleeding was controlled by vessels ligation (arteries and veins), such as the left greater palatine and left infraorbital arteries, using a No. 4.0 synthetic monofilament absorbable suture (poliglecaprone 25). The resected portion of the maxilla, together with the mass, were placed in 10% formalin and sent to the histopathology laboratory.

In the post-surgical period, the animal presented suture dehiscence. During the correction, the edges of the surgical wound were debrided and a new suture was performed, in two layers, using isolated stitches in a swift and simple continuous pattern. At this time, it was decided to place a pharyngostomy tube for food and medication management, initially for a

period of 10 days. In the following weeks, the patient presented good clinical evolution, with adequate healing of the suture, and the tube was removed. The histopathological examination report confirmed the diagnosis of acanthomatous ameloblastoma (figure 2) without bone tissue involvement and with free margins.

### **3. DISCUSSION**

Medium to large adult dogs are most frequently affected by ACC. Although it is a common tumor in dogs of these breeds and sizes, the animal reported here does not follow the same characteristics, showing that it is possible for small breeds to be affected. There is no consensus in the literature regarding a predilection for sex [10, 13].

Regarding the age at which dogs are diagnosed, the literature reports a variation between 7 and 10 years of age [1], compatible with the age presented by the patient at the time of clinical-surgical care, although it is possible for the disease to occur at younger ages [5, 11].

Oral neoplasms are usually diagnosed late, when they are already at an advanced stage [1, 6], often making a more conservative approach and less invasive surgical interventions impossible. Because the lesion was in stage I, the clinical-surgical approach in this animal occurred without major complications, resulting in a resection with free margins, thus preventing the occurrence of local recurrences [7].

Surgical wound dehiscence is a postoperative complication that can occur in 7-33% of maxillectomy cases [4], and is caused by systemic or local factors, infection, suture rupture, ischemia or tension in the wound, and worsens with age, inadequate nutritional conditions, and concomitant diseases such as diabetes or cardiovascular diseases [18]. To correct the dehiscence, it is important to cover the area with a flap of buccal mucosa, divulsing enough to juxtapose the edges of the wound, which should come together without tension.

The edges must be debrided so that they can be coapted [17]. In a surgical reintervention, especially when performed in the immediate post-surgical period, the tissue must be handled with greater care, since the presence of granulation tissue at the site makes it more friable [7, 8]. At the time of the surgical reintervention in the reported case, it was decided to suture in two layers, one in a swift pattern, with the aim of avoiding contact of the tongue with the surgical knot, and the other in a simple continuous pattern, to provide greater stability.

Aesthetically, maxillectomy, in most circumstances, causes minor maxillofacial abnormality. In the present case, the patient presented with an acceptable cosmetic standard, without visual asymmetry of the head, good adaptation and minimal functional alteration, which allowed the gradual return of chewing. The animal continued to be monitored after removal of the neoplasm and until the last evaluation, and showed no signs of recurrences or metastases.

While the literature reports a higher incidence of AAC in the rostral region of the mandible of dogs, in this study the tumor was located in the central region of the left maxilla. Though the patient presented an adherent mass, pink in color and with irregular contours, suggestive of acanthomatous ameloblastoma, histopathological diagnosis should be requested for the effective diagnosis of ACC [10, 19].

### **4. CONCLUSION**

Canine acanthomatous ameloblastoma is a non-metastatic odontogenic tumor that can occur in small dogs. Its diagnosis should be made through histopathological examinations,

with immunohistochemical examination being appropriate to confirm the nature of the tumor tissue. Accurate diagnosis and adequate surgical technique of central maxillectomy with adequate margins, as well as resolution of post-surgical complications, allow for a better prognosis and reduce the possibility of recurrence. Although it occurs most frequently in the rostral and mandibular regions, ACC is also seen in more central or caudal areas of the oral cavity.

**DISCLAIMER (ARTIFICIAL INTELLIGENCE)**

Author(s) hereby declare that NO generative AI technologies such as Large Language Models (ChatGPT, COPILOT, etc) and text-to-image generators have been used during writing or editing of manuscripts.

**CONSENT**

It is not applicable.

**ETHICAL APPROVAL**

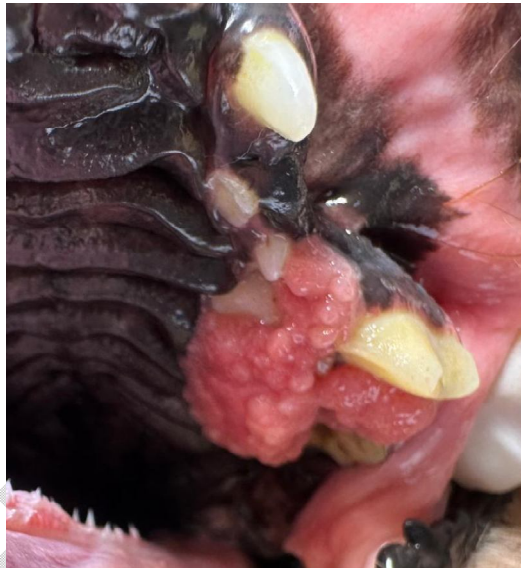Animal Ethic committee approval has been collected and preserved by the author(s).

UNDER PEER REVIEW

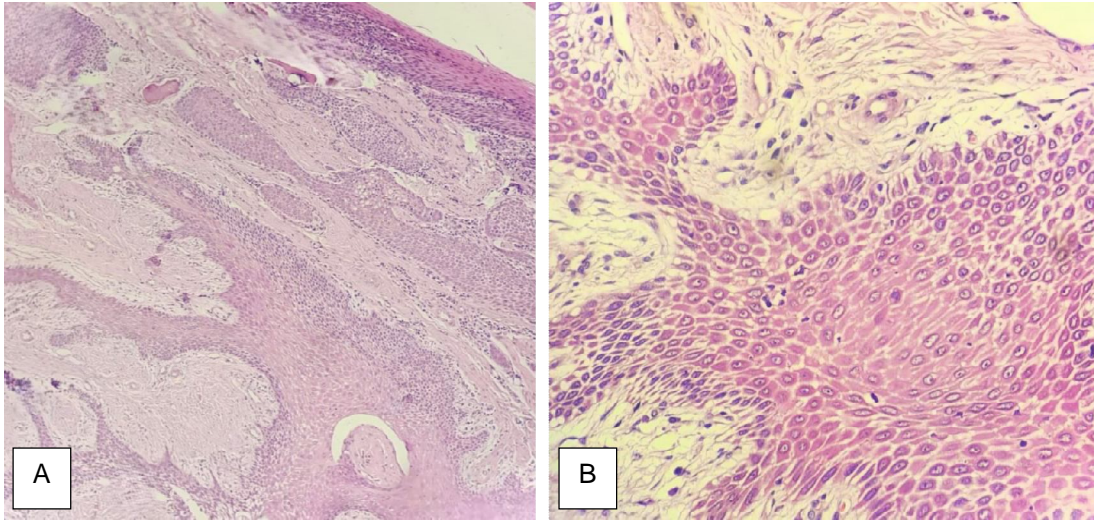
## REFERENCES

1. Pippi NL, Gomes C. Oral Cavity Neoplasias. In: Daleck CR, Nardi AB, editors. *Oncology in Dogs and Cats*. 2nd ed. Rio de Janeiro: Roca; 2016.
2. Smith MM. Oral and salivary gland disorders. In: Ettinger SJ, Feldman EC editors, *Textbook of Veterinary Internal Medicine*. 6th ed. Philadelphia: Elsevier Saunders ; 2005.
3. Gomes C, Oliveira LO, Elizeire MB, Oliveira MB, Ferreira KC, Oliveira RT, Cavalcanti R, Contesini, EA. Epidemiological evaluation of dogs with oral neoplasias treated at the veterinary clinic hospital of the Federal University of Rio Grande do Sul. *Brazilian Animal Science*. 2009;10(3):835-839. Portuguese.
4. Botelho RP, Silva MFA, Pinto LG, Magalhães AM, Lopes AJA, Carteiro F. Clinical and surgical aspects of mandibulectomy and maxillectomy in the treatment of oral pathologies in dogs (*Canis familiaris*). *Brazilian Journal of Veterinary Science*. 2002;9(3):127–132. Portuguese.
5. Arzi B, Verstraete FJM. Mandibular Rim Excision in Seven Dogs. *Veterinary Surgery*. 2010;39(2):226–231.
6. Dias FGG, Dias LGGG, Pereira LF, Santos PCD, Moraes CLD, Rocha JR. Acanthomatous epulis in dogs – literature review. *Electronic Scientific Journal of Veterinary Medicine*. 2013;20(11). Portuguese.
7. Romanelli G, Lewis JR. Management of oral and maxillofacial neoplasia. In: Reiter AM, Gracis M (editors). *Manual of Canine and Feline Dentistry and Oral Surgery*. 4th ed. England: BSAVA; 2018.
8. Requicha JF, Pires MA, Albuquerque CM, Viegas CA. Oral cavity neoplasms in dogs: Brief review. *Brazilian Journal of Veterinary Medicine*. 2015;37(1):41–46. Portuguese.
9. Figueira KD. Canine acanthomatous ameloblastoma: Clinical, diagnostic and therapeutic management. *Dogs and Cats Journal*. 2017;33(212):58–59. Portuguese.
10. Goldschmidt SL, Bell CM, Hetzel S, Soukup J. Clinical characterization of canine acanthomatous ameloblastoma (CAA) in 263 dogs and the influence of postsurgical histopathological margin on local recurrence. *Journal of Veterinary Dentistry*. 2017;34(4):241- 247.
11. Cray M, Selmic LE, Ruple A. Demographics of dogs and cats with oral tumors presenting to teaching hospitals: 1996–2017. *Journal of Veterinary Science*. 2020;21(5):1-7.
12. Chamberlain TP, Lommer MJ. Clinical behavior of odontogenic tumors. In: Verstraete MJF, Lommer MJ (editors). *Oral and Maxillofacial Surgery in Dogs and Cats*. Philadelphia: Saunders Elsevier; 2012.
13. Das S, Nath BK, Alim MA, Sikder S, Pallab MS. Acanthomatous ameloblastoma in a female Spitz dog with rare atypical histomorphology: A case study. *VeterinaryWorld*. 2013;6(4):219-222.
14. Gardner DG, Baker DC. The Relationship of the Canine Acanthomatous Epulis to Ameloblastoma. *Journal of comparative pathology*. 1993;108:47-55.

15. Malmberg JL, Hoxerth EW, Powers BE, Schaffer PA. Acanthomatous ameloblastoma with atypical foci in five dogs. *Journal of Veterinary Diagnostic Investigation*. 2017;29(2):154-159.
16. Kelly JM, Belding BA, Schaefer AK. Acanthomatous ameloblastoma in dogs treated with intralesional bleomycin. *Veterinary and comparative oncology*. 2010;8(2):81–86.
17. Kessler M. Mandibulectomy and maxillectomy as a treatment for bone invasive oral neoplasia in the dog – a retrospective analysis of 31 patients. *Kleintierpraxis*. 2003;5(48):289-300.
18. Silva CG, Crossetti MGO. Dressings for the treatment of abdominal surgical wounds: a systematic review. *Gaúcha Nursing Magazine*. 2012;33(3):182-189. Portuguese.
19. Wuerz J, Rooks JK, Griffin F. Diagnostic Imaging in Veterinary Dental Practice. *Journal of the American Veterinary Medical Association*. 2022;260(2):1-3.



**Figure 1.** Gross aspect of the mass in the left maxilla. Firm, friable mass, similar to gingival tissue, pink to red in color, multilobulated in appearance, with irregular contours, non-ulcerative, measuring approximately 1.5 x 1.5 cm.



**Figure 2.a)** Oral mucosa (gingiva): lamina propria expanded by a neoplastic mass of odontogenic epithelial cells, densely cellular, non-encapsulated, with inconspicuous margins, forming islands supported by thin myoepithelial stroma. H&E. Obj. 10x. **b)** Oral mucosa (gingiva): polygonal-shaped neoplastic cells, with broad eosinophilic cytoplasm, distinct borders and evident desmosomal junctions, sometimes arranged in a palisade and sometimes perpendicular to the basement membrane. Round nuclei, with finely granular chromatin and single evident nucleoli. Moderate anisocytosis and anisokaryosis with one mitotic figure per 40x field. H&E. Obj. 40x.

UNDER PEER