

Case Report

Vulvar Paget's Disease with inguinal lymph node metastasis: a case report

ABSTRACT

Vulvar Paget's disease is a clinical condition with an invariable course affecting women of advanced age, and is associated with a significant rate of recurrence and dissemination, especially in its invasive form, which has a high metastatic potential. Here we present details of a unique case involving a 77-year-old woman with a history of disease progression over more than a decade. She initially presented with an erythematous lesion in the vulvar region, which was later diagnosed as adenocarcinoma *in situ*. During follow-up, the affected area extended to the perineal and gluteal regions, indicating an invasive aspect of the tumor. Due to surgical oncology recommendations, tissue resection was not feasible. The patient experienced a significant worsening of symptoms, including local peeling of the affected region, and a biopsy confirmed Paget's disease in the vulvar region. Subsequently, imaging tests indicated changes in the volume of the inguinal lymph nodes. The patient underwent lymphadenectomy for histological analysis and to prevent systemic dissemination. Indicators of lymph node metastasis, suggestive of a gynecological primary site, were observed. Our case provides valuable insights for pathologists to consider the differential diagnosis of vulvar lesions.

Keywords: Women's Health, Gynecologic Cancers, Vulvar Paget's Disease, Lymph node metastasis, Case report.

1. INTRODUCTION

Vulvar Paget's disease (VPD) is a rare condition with unpredictable progression that primarily affects women in a postmenopausal period, typically between 60 and 70 years of age [1]. It is associated with cutaneous symptoms such as eczema, papules, and even ulcerations, and may present with perineal or vulvar irritation, along with intense itching and pain [2]. VPD can be asymptomatic, non-invasive, or invasive, with the invasive form having a worse prognosis, greater potential for metastasis, higher recurrence probability, and consequently, a high mortality rate [3]. The literature also indicates that lymph nodes and lymphatic circulation are potential targets of metastasis, directly impacting the anti-tumor immune response and enabling greater systemic dissemination of cancer cells [4].

In this case report, we describe the clinical course of a patient with VPD and metastasis in the inguinal lymph nodes, following cutaneous manifestations in the vulvar region. The patient underwent long-term follow-up with a multidisciplinary approach for the definition of the diagnosis. This case has been reported in line with current guidelines.

2. PRESENTATION OF CASE

A 77-year-old woman with a history of an extensive erythematous lesion in the right vulvar region, with an average evolution for 10 years. She sought medical attention in 2019 with a biopsy with a previous diagnosis of adenocarcinoma *in situ*. The gynecological examination confirmed the presence of the referred erythematous non-ulcerated lesion and observed its extension in the right perineum, affecting a large part of the lower vulvar region

bilaterally, extending to the gluteal region, especially in the right portion. At the time, an incisional biopsy was performed, which initially indicated a **microinvasive squamous cell carcinoma grade 2 (Clark 2, Breslow 0.2 mm)**. According to the evaluation of the oncological surgery, it was an unresectable lesion. She started treatment with Carboplatin AUC5 added to Paclitaxel for 4 cycles and, later, 3 cycles of Cisplatin associated with radiotherapy.

We started monitoring the patient in our service 3 years later, in early 2022, the site of the lesion was evaluated, finding an area of prurigo, with local scaling and significant worsening of the lesions on the right side. The anatomopathological examination indicated a malignant epithelioid intraepidermal neoplasm with “no other specification” (NOS) in the skin of the buttock, vulva, and labrum majora, ipsilateral to the right, disfavoring the previous clinical proposition of epidermoid carcinoma. Immunohistochemical (IHC) analysis confirmed a differential diagnosis of VPD.

To monitor the tumor progression, a total abdominal magnetic resonance imaging (MRI) was requested, which reported the presence of small foci of thickening of the epithelial lining of the introitus of the vaginal canal, enhanced by contrast, with measurements of 1.7 x 0.7 cm on the right and 1.2 x 0.6 cm on the left. At the same time, an increase in lymph nodes was found in the right external iliac chain measuring 2.2 x 1.1 cm and, on the left side, they were unchanged, measuring up to 1.0 cm; with evident absence of free fluid or lymph node enlargement in the rest of the abdominal cavity.

Analysis by positron emission computed tomography (PET-CT) monitored a numerical increase in the volume, of the lymph nodes in the regions: right inguinal, iliac, pericaval, left para-aortic, retrocruval, right prevascular, right para-aortic, paratracheal, low cervical and, finally, in the heterogeneous nodular area in the left thyroid lobe.

Near the end of 2022, she presented edema in the pubic region with projection to the lower limbs, especially on the right side, underwent a lymphadenectomy of the right pelvic chain, and the AP evaluation of the resected tissue pointed to the presence of an adenocarcinoma metastasis with a mucinous component in half of the pelvic lymph nodes (Figures 1-2), subsequently, the IHC analysis indicated positive GATA3, CEA, CK7, and CK9 suggesting a primary gynecological or mammary site. **By decision of the multidisciplinary team, considering the specific circumstances of the patient, treatment was initiated with** Paclitaxel and has shown significant improvement in edema in the lower limbs and responded, partially, to the reduction of vaginal lesions and pain perception.

3. DISCUSSION

The average age range for the initial diagnosis of VPD is between 60 and 70 years of age, with a variation for younger ages being more common, from 38 years in postmenopausal periods [1,2,5]. For the patient reported in the case, there is a late diagnostic confirmation, at 75 years old, also given by the slow and unpredictable progression of the disease that presents the manifestation of characteristic symptoms in an interval of 1 to 3 years [1]. In general, VPD is not lethal, but a more specific follow-up is recommended, especially in late diagnoses, given its high recurrence capacity [1]. Likewise, individuals with a history of the disease for a period more extended than 10 years are more prone to the development of invasive VPD and, consequently, a significantly worse survival [3,6].

The characteristics of the lesion presented by the patient are morphologically associated with VPD, mainly due to the presence of erythema, eczema, and desquamation [2,5]. The most affected areas are usually the labia majora and minora, clitoris, and perianal region [5]. Due to the nature of the signs, it is mistakenly diagnosed as dermatitis or fungal infection, and histological and AP evaluations are essential for eliminating these confounding factors and greater assertiveness in the diagnosis [2]. The use of IHC has been widely encouraged, especially where there is a progression of symptoms, manifestation of recurrence, and suspicion of invasiveness [2,6].

As support tools, there are imaging tests that can help in diagnostic analysis, in the staging of neoplastic cells, as well as in therapeutic support [7]. For vulvar carcinoma, MRI was defined as the best imaging method for detecting the involvement of surrounding structures and PET-CT showed high accuracy for detecting primary vulvar lesions [7]. The alterations found in the MRI in contrast to the patient indicated an epithelial hyperplasia representative of the advance of the local neoplasia. They led, in the first instance, to the hypothesis of involvement of the adjacent lymphatic pathways. The evaluation made by PET-CT, in turn, expanded the assumption of systemic neoplastic dissemination through the lymph node network, given the variations found in different regions.

Despite having a relatively slow development, VPD has a highly variable course and its main prognostic factor is the invasion of the underlying dermal tissue with subsequent lymphatic reach and, consequently, possible distant metastases [6,8]. In the colonization of lymph nodes, neoplastic cells exert an immunosuppressive activity, especially of the immune response mediated by T cells, reducing the potential of the organism's reaction against the progression of the disease and, even more, creating a pro-metastatic microenvironment [4,8]. Lymph node metastasis, originating from vulvar cancers in general, is associated with a low proportion of disease-free survival (DFS) and worse overall survival (OS), representing almost half of the rates of patients who do not present this condition [9].

In the reported case, it was decided to perform a regional lymphadenectomy both for the AP and IHC analysis and for defining the most accurate staging of the neoplasm. The most common site of dissection for cancers that reach the vulvar area is the lymph nodes of the inguinal region, which can be defined, in this context, as sentinel lymph nodes (SLN) [10]. There needs to be more consensus on determining the effective therapeutic benefits of SLN biopsy even though it is considered a standard method of treatment in several types of solid tumors [8]. Furthermore, such a removal technique requires further follow-up due to immunological impairment as well as the high risk of developing lymphedema [8,10].

IHC panel results were suggestive of a primary gynecological or breast site. The positivity for the CK7 marker was associated with high sensitivity for extramammary Paget's disease, also, positive CEA, present in more than 80% of reported cases [11] as well as for the combination CK7, CK20, and GATA3, the latter being, specific for cases of VPD [12]. Another marker highly correlated with immunohistochemical findings in the literature is GCDFP-15, a common indicator for cells of apocrine origin [6,12].

Subtypes of invasive Paget's disease, such as VPD in this case, and with such an advanced history of progression are rare and, therefore, **do not have a standardized treatment guideline** [13]. Patients treated with both radiotherapy and chemotherapy - on a regimen of Carboplatin and Paclitaxel - had a progression-free survival (PFS) time of approximately 170 days [13]. It was demonstrated that the combined therapy of Paclitaxel and Trastuzumab caused complete, albeit temporary, remission in a patient with VPD who clinically returned to present foci of lesions characteristic of the previous condition [14] indicating the need to maintain a follow-up after the therapeutic approach in the short and medium term.

4. CONCLUSION

In conclusion, we present the case of a 77-year-old female patient diagnosed with VPD with metastasis to the inguinal lymph nodes. **It is noteworthy that this is a disease with slow progression and poses challenges in achieving precise differential diagnosis due to the similarity of symptoms with other clinical conditions, which can lead to misdiagnosis.** Due to the uniqueness of the case, there is a limited number of publications that fit the reported context, and therefore, further clarification is required, particularly concerning diagnostic approaches, which may include molecular profiles analyses. Additionally, there is a need for effective and lasting therapeutic alternatives in situations where surgical resection is not

feasible. We emphasize **the important** of early biopsy. Our case provides **valuable** insights for pathologists to consider in differential diagnosis of vulvar lesions.

Ethical Approval:

As per international standards or university standards written ethical approval has been collected and preserved by the author(s).

Consent

As per international standards or university standards, patient(s) written consent has been collected and preserved by the author(s).

Disclaimer (Artificial intelligence)

Author(s) hereby declare that **NO generative AI technologies such as Large Language Models (ChatGPT, COPILOT, etc) and text-to-image generators have been used during writing or editing of manuscripts.**

REFERENCES

1. Loiacano RMR et al. Paget disease of the vulva: an analysis of 24 cases. *Medicine (Baltimore)* 2019; 98(41):1-4. <https://doi.org/10.1097/MD.00000000000017018>.
2. Van der Linden M et al. Vulvar Paget disease: A national retrospective cohort study. *J Am Acad Dermatol* 2019; 81(4):956-962. <https://doi.org/10.1016/j.jaad.2018.11.016>.
3. Liang S et al. Clinical characteristics and risk factors of invasion in extramammary Paget's disease of the vulva. *Arch Gynecol Obstet* 2021; 303(2):541-546. <https://doi.org/10.1007/s00404-020-05803-z>.
4. Zhou H et al. Progression of Metastasis through Lymphatic System. *Cells* 2021; 10(3):627-652. <https://doi.org/10.3390/cells10030627>.
5. Zhang CY et al. [Analysis of clinical characters of female vulvar Paget disease]. *Zhonghua Fu Chan KeZaZhi* 2018; 53(8):540-546. Chinese. <https://doi.org/10.3760/cma.j.issn.0529-567x.2018.08.006>.
6. Carton I et al. Paget's disease of the vulva: A challenge for the gynecologist. *J Gynecol Obstet Hum Reprod* 2021; 50(1):101896. <https://doi.org/10.1016/j.jogoh.2020.101896>.
7. Serrado MA. State of the art in vulvar cancer imaging. *Radiol Bras* 2019; 52(5):316-324. <https://doi.org/10.1590/0100-3984.2018.0072>.
8. Du Bois H et al. Tumor-draining lymph nodes: At the crossroads of metastasis and immunity. *Scimmunol* 2021; 6(63):eabg3551. <https://doi.org/10.1126/sciimmunol.abg3551>.
9. Mahner S et al. Adjuvant Therapy in Lymph Node–Positive Vulvar Cancer: The AGO-CaRE-1 Study. *JNCI* 2015; 107(3): dju426. <https://doi.org/10.1093/jnci/dju426>.
10. Rychlik A et al. Sentinel lymph node in vulvar cancer. *Chin Clin Oncol* 2021; 10(2):19-26. <https://doi.org/10.21037/cco-20-202>.

11. Zhao Y et al. Primary extramammary Paget's disease: a clinicopathological study of 28 cases. *Int J ClinExpPathol* 2019; 12(9):3426-3432.

12. Morbeck D et al. GATA3 expression in primary vulvar Paget disease: a potential pitfall leading to misdiagnosis of pagetoid urothelial intraepithelial neoplasia. *Histopathology* 2017; 70(3):435-441. <https://doi.org/10.1111/his.13086>.

13. Padrnos L et al. Mayo Clinic Cancer Center Experience of Metastatic Extramammary Paget Disease 1998-2012. *Rare Tumors* 2016; 8(4):142-145. <https://doi.org/10.4081/rt.2016.6804>.

14. Isnard C et al. Complete but transient clinical remission of vulvar Paget's disease with paclitaxel and trastuzumab. *Annales de Dermatologie et de Vénérologie* 2021; 148(1):47-48. <https://doi.org/10.1016/j.annder.2020.08.048>.

FIGURES

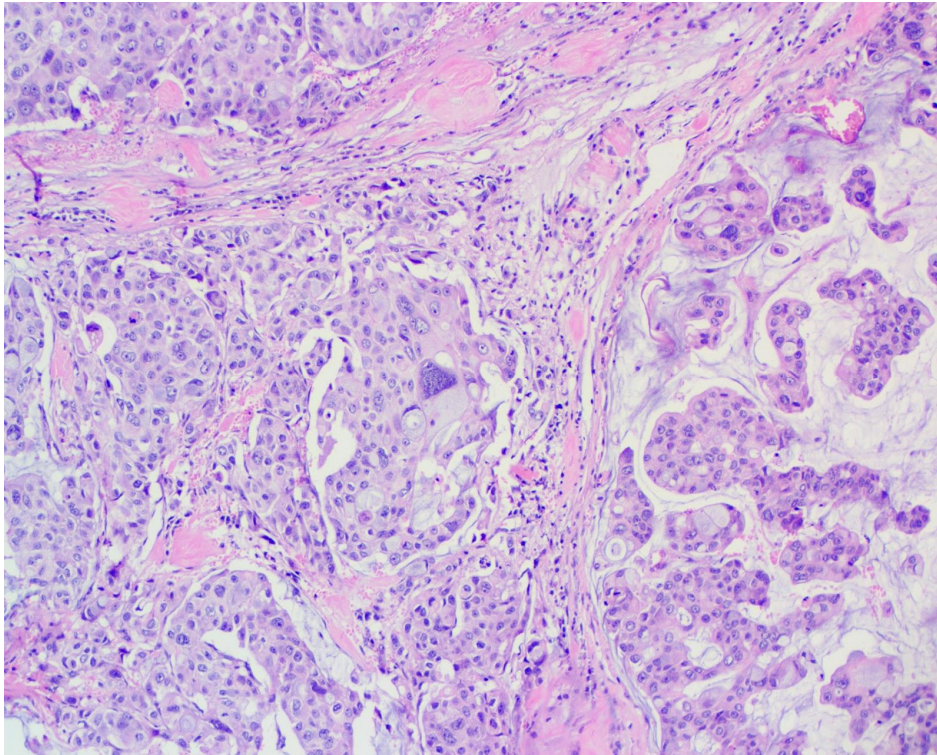


Fig. 01. Biopsy of the resected lymph node, stained with hematoxylin and eosin, shows a metastatic cluster characteristic of VPD and the presence of bizarre cells [100x magnification].

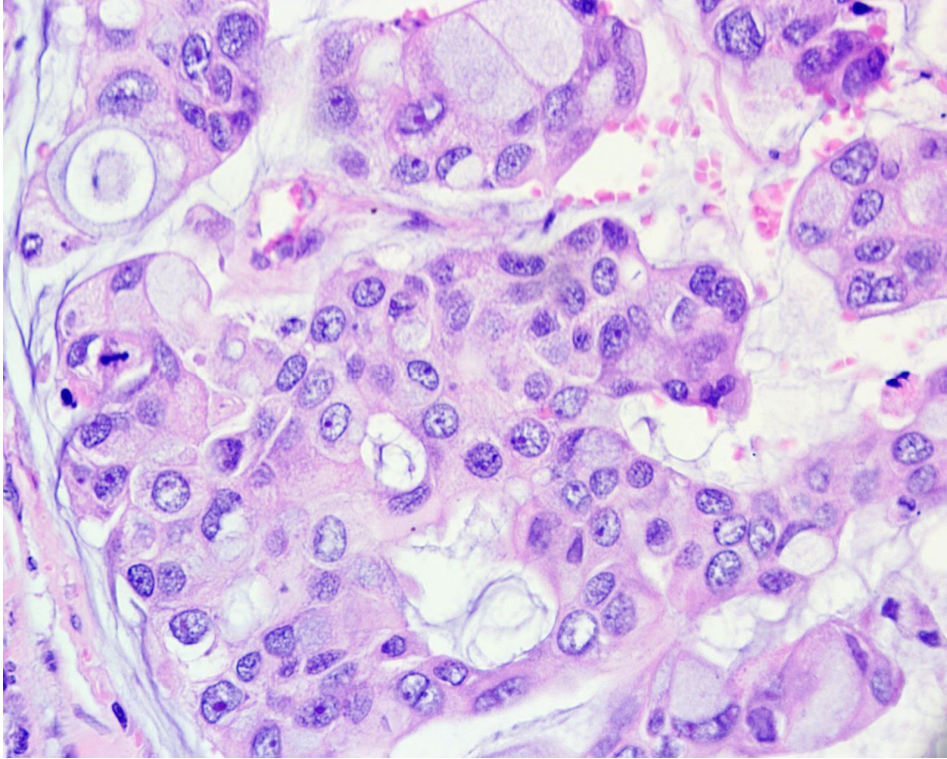


Fig. 02. Sections prepared with hematoxylin and eosin show a mucinous component associated with tumor cells with an epithelioid shape, with a high nuclear-cytoplasmic ratio and moderate mitotic activity [400x magnification].